

## *Communications*

# Diagnosis and management of ocular leprosy

D. P. CHOYCE

*From the Hospital for Tropical Diseases (University College Hospital), London*

Accurate statistics of leprosy are hard to come by, but Browne (1968, personal communication) estimated the world total to be 15 to 16,000,000 and increasing. A conservative estimate of those with ocular involvement is 25 per cent. (Somerset, 1962), which gives a total of at least 4,000,000 in need of skilled eye treatment.

### **Diagnosis**

The eyes may become involved in leprosy in three ways—as a complication of involvement of the facial and occasionally the trigeminal nerve(s); by invasion of the eyeball by large numbers of acid-fast bacilli in lepromatous leprosy; and by participation in the generalized allergic reaction, known as the reactive phase. It is curious that the eyeball is rarely, if ever, involved by direct spread from neighbouring lepromatous lesions. Bilateral symmetry of the eye lesions is common.

#### (1) EXTERNAL APPEARANCES

*Madarosis*, or loss of eyebrows and eyelashes, due to destruction of the resident hair follicles, is typical of the disease. The outer third is usually the first affected, but complete loss of all hair follicles is common later.

*Lagophthalmos and exposure keratitis* Involvement of the 7th cranial nerve is common and leads to imperfect closure of the lids. This is often accompanied by a slight widening of the palpebral aperture, is usually bilateral, and gives rise to the typical staring look. The lower part of the orbicularis muscle is mainly affected and this later leads to paralytic ectropion, eversion of the lower canaliculus and punctum, so that epiphora results. Later still the lagophthalmos will be exacerbated by atrophy of the skin and orbicularis. A very dangerous situation thus arises. Such eyes are very prone to exposure keratitis, corneal ulceration, and perforation, leading to loss of the eye.

An early indication of lagophthalmos is a reduction in the blinking rate which may initially be more noticeable in one eye than the other. These signs can be mimicked by an hysterical subject; one patient was about to undergo protective lateral tarsorrhaphies

for a day-time inability to close the eyelids (Fig. 1), when it was noted that they closed normally in sleep!

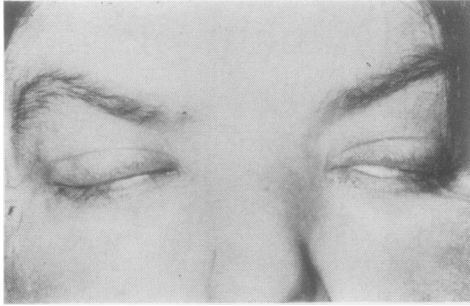

FIG. 1 *Hansen's disease. Day-time lagophthalmos; normal closure of lids in sleep*

## (2) EYEBALL LESIONS

For proper assessment of cornea, iris, and fundus lesions the minimum equipment is a  $\times 8$  monocular loupe and a good ophthalmoscope. Strictly speaking, a corneal microscope giving a magnification of  $\times 25$  should be obligatory and the recent production of special light-weight transportable models represents a helpful contribution to the diagnosis of leprosy; *e.g.* the Curpax transportable slit lamp\* weighs only 38 lb.

### (a) *Conjunctiva and episclera*

There is no true leprous conjunctivitis. Lepromata in the episclera may occur. They most commonly adjoin the limbus in the 3 or 9 o'clock position. These nodules may become quite large and overlap the cornea, or may even protrude between the eyelids. Unless secondary ulceration has occurred they are smooth, reddish, and painless. They can be expected to resolve gradually with modern sulphone therapy.

### (b) *Cornea*

The earliest sign concerns the corneal nerves. These enter the corneal stroma radially and the first abnormal sign is that they appear unduly prominent and beaded because of aggregations of leprosy bacilli accompanying the nerves.

Next, there is a slight reaction on the part of the corneal stroma to the presence of these bacilli, causing localized discrete, interstitial opacities. At this stage the cornea appears to be covered by milky, chalky deposits, and this type of avascular subepithelial punctate keratitis is pathognomonic of leprosy.

Pannus formation is common, extending round the entire corneal circumference in contradistinction to trachoma pannus, which only affects the upper third of the cornea. Although leprosy pannus will eventually spread right round the cornea, the superior limbus is usually first affected, and is the part to examine on routine examination of eyes thought to be so far unaffected by the disease.

Eventually the pannus formation leads to sclerosing keratitis which may extend right round the limbus. Ultimately this process interferes with corneal nutrition, producing characteristic folds in Descemet's membrane. Perforation of the cornea is unlikely to occur except as the result of secondary bacterial or viral infection. The corneal changes

\* Made by Curry and Paxton Ltd., London

in leprosy are very common and peculiar to that disease; once they are well established they are likely to be permanent. Symptoms are minimal until the late stages, when corneal ulceration has set in.

(c) *Sclera*

This may be diffusely affected, but not as an isolated lesion. Leprous scleritis is generally associated with leprous keratitis and leprous iridocyclitis.

(d) *Involvement of iris and ciliary body*

This is extremely common and occurs in four main forms:

(1) *Miliary lepromata or iris "pearls"* These are aggregations of leprosy bacilli or acid-fast material which are pathognomonic of leprosy and resemble the tiny white spots found in the cornea. They are found immediately adjoining the pupil margin and may be very numerous. In diameter they measure about 0.25 mm. and while they can sometimes be picked out with the monocular loupe they are more readily observed with the corneal microscope. They are probably present at an early stage of the disease, but become more evident as the overlying iris stroma atrophies. They may coalesce and become pedunculated and drop off into the anterior chamber, whence they are slowly absorbed without causing much reaction. They are not in themselves dangerous, but they serve as a useful guide to the diagnosis of ocular leprosy and they may coexist with the signs of plastic iridocyclitis. They never disappear, even in a patient in whom the disease eventually becomes extinct. Initially they consist of aggregations of recognizable acid-fast bacilli, but in the arrested case they are merely composed of deposits of amorphous acid-fast material.

(2) *Nodular lepromata* These are much less common; they are yellowish in colour, globular, sometimes flattened; they assume variable dimensions, and may occur anywhere on the iris.

(3) *Chronic plastic iridocyclitis* This is caused by the leprosy bacilli first irritating, and then slowly destroying, the ciliary body, with the result that this type of iridocyclitis is characterized by its insidious onset and extreme chronicity. This is the most frequent type of involvement of the iris and ciliary body, and the principal cause of blindness in ocular leprosy. In the early stages the eye is relatively quiet, and only later does the visual acuity gradually decrease. Iris adhesions at first are few, but they extend and will eventually involve the whole pupil circumference, causing seclusion of the pupil (Fig. 2). There will be lardaceous keratic precipitates on the back of the cornea, and exudates in the anterior chamber and on the anterior lens capsule, causing occlusion of the pupil. The pupil itself is usually small and irregular, and does not react to light or accommodation, being prevented from so doing by the multiple posterior synechiae which are present. Later still a complicated cataract will develop with vitreous opacities, retinal detachment, and phthisis bulbi. Acute secondary glaucoma is unusual in this type of iridocyclitis.

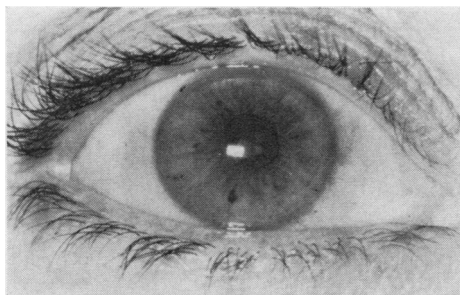


FIG. 2 *Hansen's disease. Chronic plastic iridocyclitis as shown by pupil seclusion, lardaceous keratic precipitates, and exudate on anterior lens capsule*

(4) *Acute diffuse plastic iridocyclitis* of sudden onset may occur in an otherwise healthy eye, and is not, strictly speaking, due to actual ocular leprosy. It is part of the reactive phase of the disease usually affecting both eyes, and is in the nature of a sensitization reaction on the part of the uveal tract to the breakdown products of leprosy elsewhere in the body. The condition is, therefore, especially likely to occur in the early stages of sulphone treatment in an active lepromatous case. The diagnosis is simple because the symptoms are so marked, in contradistinction to the chronic variety with its insidious onset.

Over the last decade a marked increase in both these types of iridocyclitis has been noted in our practice at the Hospital for Tropical Diseases. We attribute this to the increasing efficacy of the drugs used in the treatment of leprosy, which, by killing more and more acid-fast bacilli, release increasing quantities of foreign protein into the circulation to which the uveal tract becomes sensitized. We consider that this trend can only continue.

(e) *Lesions of the posterior segment*

Although ocular leprosy is basically an anterior segment disease, lesions of the posterior segment behind the ora serrata do occasionally occur by direct spread from the ciliary body. The incidence is low, about 1 per 20 cases of ocular leprosy. Two types of fundus lesion have been described. In the first, white, waxy, highly refractile deposits occur at the extreme periphery of the choroid and retina. The overlying retina is destroyed and the retinal vessels in the neighbourhood undergo sheathing and fibrosis. These lesions are mainly noticeable at the lower temporal quadrants of the fundus, the reason for this distribution being obscure (Choyce, 1961). They are present only when the rest of the eye is heavily infected, and this accounts for the difficulty with which these changes are seen, because the corneal opacities, iris atrophy, iris adhesions, and a complicated cataract all combine to make examination of the fundus most difficult. These lesions are undoubtedly caused by direct extension of the infection from the ciliary body, but fundus lesions behind the equator of the eyeball are even less common. In this, the second type of fundus lesion described, they take the form of discrete, circular, waxy, and occasionally pedunculated nodules on the retina, of about the same size and appearance as the iris lepromata or "pearls" (Elliott, 1949). Somerset and Sen (1956) examined 256 consecutive cases of leprosy, and found two cases with retinal lesions similar to those described by Elliott. Their origin from the retina itself has not yet been demonstrated histologically; they are transient, being present one week and not the next; and they leave no scar visible with the ophthalmoscope. It is quite possible that they have in fact originated on the pars plana of the ciliary body from whence they have been shed into the plane of cleavage between vitreous and retina, where they move around until absorbed. Leprous fundus lesions are not an important factor in the causation of blindness, except by acting as the starting-point of retinal detachment, of which we have seen two cases.

## Management

(1) ROUTINE EXAMINATION OF THE EYE

This should take place every 3 months, more frequently if the eyes are known to be affected. Ideally, this examination should be carried out by a properly trained ophthalmologist with experience of leprosy, but where such skilled advice is not available an observant leprologist with no special training in ophthalmology can do much valuable work. The basic equipment he needs is a good pocket torch with a focusing adjustment, a  $\times 8$  monocular loupe, and a good ophthalmoscope, together with some knowledge of what to look for. A corneal

microscope is essential. Having taken the visual acuity of each eye separately, the ocular adnexa should first be examined, any sign of lagophthalmos, corneal anaesthesia, or infection of the lacrimal sac being carefully noted. The conjunctiva, episclera, cornea, and iris should then be examined with the torch and the monocular loupe; next, the translucency of the media should be tested with the ophthalmoscope, and finally the fundus should be examined. Mydriatic drops should be used if there is the slightest suspicion of iritis. The presence of posterior synechiae between iris and lens capsule will then be revealed.

A difficulty arises if leprosy has *not* been diagnosed or even contemplated, because the examiner may confuse the corneal changes with those found in syphilitic interstitial keratitis; the Wassermann reaction and Kahn test are strongly positive in the large majority of cases of active lepromatous leprosy, and a serious error in diagnosis may thus occur. Anti-syphilitic treatment has no effect on the progress of leprosy and valuable time may be lost before the correct diagnosis is made. Ophthalmologists should have this diagnostic trap brought to their notice (Choyce, 1961).

## (2) LOCAL TREATMENT

### (a) *Exposure keratitis and neuroparalytic keratitis*

Lateral tarsorrhaphy, which often needs to be bilateral, is very effective in the earlier stages. Up to one-third of the outer portions of the upper and lower lids should be permanently united by surgical means. For the more advanced case, in which considerable atrophy of the lower lid and orbicularis has occurred, a temporalis-sling operation is strongly recommended by Somerset (1962).

### (b) *Leprous keratitis*

This does not respond either to local or systemic treatment.

### (c) *Iridocyclitis*

In the early stages the use of mydriatic and cortisone drops locally 2–3 times a day is sufficient. They must always be used once posterior synechiae are present. Use of the mydriatic drops will probably interfere with the patient's near vision and careful attention should be paid to the need for a spectacle correction for near vision, even in pre-presbyopic patients. In those uncommon cases in which the intraocular pressure is raised, Diamox

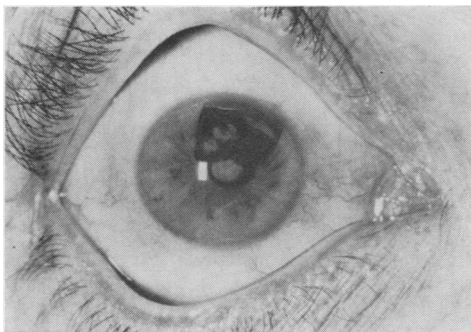


FIG. 3 *Hansen's disease. Chronic plastic iridocyclitis treated by complete iridectomy*

(acetazolamide) should be given, 250 mg. two or three times a day if the patient can tolerate it. When the posterior synechiae form a complete ring round the pupil, a *complete iridectomy is obligatory* (Fig. 3). This procedure eliminates the danger of secondary glaucoma from iris bombé, it slows down the production of complicated cataract, and, for some obscure reason, the iridocyclitis tends to become quieter and less acute. In recent years we have had to perform ten of these iridectomies on six of our patients at the Hospital for Tropical Diseases (four bilateral and two unilateral). The results have been most satisfactory. Lastly, should a complicated cataract form, this often becomes intumescent and again threatens to cause secondary glaucoma (Fig. 4). The lens should be extracted, if possible by the intra-capsular method, but the attendant synechiae very often require an extra-capsular operation (Fig. 5).

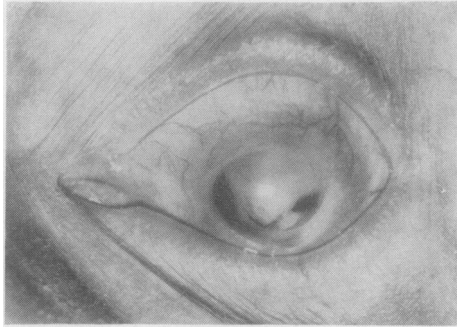


FIG. 4 Hansen's disease. Intumescent complicated cataract causing secondary glaucoma

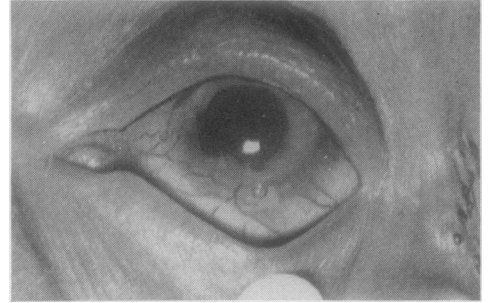


FIG. 5 Hansen's disease. Same case as in Fig. 4 after extracapsular cataract extraction. The injected appearance of this eye is in part due to treatment with B663

(d) *Acute uveitis*

The uveitis seen in the reactive phase requires a special note to itself. It may arise suddenly and dramatically, affecting the entire uveal tract of a patient whose eyes have been previously healthy. Its successful management requires the closest co-operation between leprologist and ophthalmologist. It is more likely to occur nowadays with increasing use of bactericidal drugs, such as B663, as opposed to the older bacteriostatic drugs, because of the additional amount of foreign protein liberated into the circulation, to which the uveal tract becomes sensitized. From the ophthalmic point of view, dilatation of the pupil and control of the intraocular pressure, if necessary by surgical means, are essential if the patient is not to be blinded. Systemic and local corticosteroids are invaluable in the management of this uncommon but serious complication.

(e) *Intercurrent eye disease*

This must be treated on its merits. Strangely, perhaps, the leprous eye stands up well to conventional surgical procedures. For example, the treatment of trichiasis and entropion resulting from trachoma; dacryocystorhinostomy; cataract surgery; lamellar and perforating keratoplasty; and even scleral resection in retinal detachment. One of my patients with known peripheral choroido-retinal degeneration developed an extensive retinal detachment which was successfully reposed by scleral resection. He is now back at work full-time as a gardener.

### Conclusion

Modern chemotherapy directed against leprosy is increasingly successful in reducing the bacterial count and this has led to increasing optimism amongst leprologists, but as an ophthalmologist I am gloomy about the future for two reasons:

(a) Fresh ocular lesions continue to arise in spite of the best of modern treatment which is being outwardly successful;

(b) There are not, and presumably never will be, anything like enough trained eye specialists to carry out the routine 3-monthly checks and the necessary procedures of ophthalmic treatment referred to above.

In my view, therefore, although I hope to be proved wrong, the number of blind leprosy patients will increase in the next 20 to 30 years.

### References

- CHOYCE, D. P. (1961) *Trans. ophthal. Soc. U.K.*, **81**, 418  
ELLIOTT, D. C. (1949) *Int. J. Leprosy*, **17**, 229  
SOMERSET, E. J. (1962) "Ophthalmology in the Tropics", p. 82. Baillièrre, Tindall and Cox, London  
SEN, N. R. (1956) *Brit. J. Ophthal.*, **40**, 167