

Visual prognosis after solar retinopathy

P. A. MACFAUL

Moorfields Eye Hospital, City Road, London, E.C.1

The possibility of visual damage after direct observation of the sun has been known since ancient times and the clinical features of solar retinopathy have been well described (Duke-Elder, 1954).

Eclipse watching is the commonest cause of solar retinopathy, but this form of eye injury has also been described in flying personnel, gunners and air observers (Flynn, 1952), as a result of religious rituals involving observation of the sun (Das, Nirankari, and Chaddah, 1956), after sunbathing (Ridgway, 1967), and after the application of the Bates method for strengthening the eye-sight (Knudtzon, 1948). Cases of deliberate self-inflicted retinal damage against a background of mental illness and drug-taking have recently been described by Eigner (1966) and Gilkes (1968).

When viewing conditions are suitable, each solar eclipse is still followed by cases of solar retinopathy. The purpose of this paper is to draw attention to the lasting visual damage which can follow a solar retinal burn, to stress the inadequacy or ineffectiveness of most so-called protective measures, and to advocate increasing public awareness of the possible dangers of sungazing so that the incidence of this avoidable and potentially serious form of eye injury may be reduced.

Material

This report is based on observation of a series of eighteen patients with retinal burns incurred during the partial eclipse of the sun on May 20, 1966. Weather conditions at the time permitted an excellent view of this phenomenon, which lasted for 2 hours from 9.20 to 11.20 a.m. A case of bilateral macular burns sustained during sunbathing is also described (Case 19).

All patients had a general ophthalmic examination with emphasis on scotometry and fundus appearance. They were followed up until the symptoms or signs had abated and again after 6 or 12 months.

Most patients received no special treatment other than mydriatics and dark glasses, but those with severe macular oedema were treated with systemic steroids. All were incapacitated from school or work for periods of a few days to several weeks.

NUMBER OF CASES

Including the case of bilateral sunbathing injury, nineteen cases were seen—thirteen males and six females. The clinical details of each case are summarized in Table I (opposite).

NUMBER OF EYES INVOLVED

A total of 29 eyes was studied. Both eyes were affected in ten patients, the right eye only in six, and the left eye only in three.

AGE

All the patients were between 9 and 24 years of age, except for one woman aged 45. Eleven of the eighteen cases of eclipse burn occurred in schoolchildren between the ages of 9 and 18 (61 per cent.).

Table I Nineteen cases of solar retinopathy

Case no.	Sex	Age (yrs)	Occupation	Eye involved	Protection	Visual acuity				Remarks
						Initial		Final		
1	M	18	School	Both	Dark glasses	6/9	6/9	6/6	6/6	Persistent paracentral scotomata
2	F	15	School	Both	Sun glasses	6/9	6/6	6/12	6/6	
3	M	13	School	Both	Smoked glass	6/9	6/18	6/6	6/9	Steroids Macular hole
4	M	12	School	Both	Closed lids	6/12	6/9	6/6	6/6	Normal maculae Scotomata persisted for 2 mths
5	M	22	Nil	Both	Nil	6/24	6/24	6/24	6/24	Psychotic
6	M	18	Carpenter	Both	Stained glass	6/9	6/9	6/9	6/9	Second episode
7	M	19	Nil	L	Sun glasses		6/9		6/9	
8	M	13	School	R	Nil	6/12		6/6		Paracentral scotomata 2 mths
9	F	19	Clerk	R	Nil	6/6		6/6		Macular burn
10	M	22	Painter	R	Nil	6/12		6/5		
11	M	25	Clerk	R	Nil	6/9		6/5		
12	M	14	School	R	Pinhole	6/12		6/6		Macular hole
13	F	15	School	R	Filter	6/36		6/18		Presented 3 wks after injury—steroids did not help
14	M	14	School	Both	Clouds	6/12	6/12	6/9	6/9	Persistent scotomata
15	F	14	School	Both	Old negatives	6/36	6/24	6/18	6/18	Severe oedema and macular burn
16	F	9	School	L	Nil		6/18		6/18	Presented 6 mths after injury
17	F	45	Barrister	Both	Smoked glass	6/9	6/9	6/5	6/5	Steroids
18	M	12	School	L	Nil		6/9		6/9	
19	M	23	Labourer	Both	Nil	6/18	6/18	6/9+	6/9+	Sunbathing injury

PREVIOUS HISTORY

No patient had any previous history of eye disease, apart from Case 6 who had had a previous episode of solar injury. There was one case of hypermetropic astigmatism in which the emmetropic fellow eye sustained a macular burn.

PROTECTION

In eight cases the sun was observed directly. The other eleven patients used various devices including sunglasses, stained glass, smoked glass, "filters", old photographic negatives, a pinhole, and partially closed lids; one relied on transient cirrus cloud formation to reduce the light intensity.

DURATION OF EXPOSURE

This was not known in nine cases but was generally short, being up to 5 minutes in six cases but over 10 minutes in two. It appeared that more severe damage was sustained by those who looked constantly for even a short period than by those who watched intermittently.

Case reports

The main features of the nineteen cases of solar burn are summarized in Table I, but the following cases are described in detail to bring out certain points of importance:

Case 1. An 18-year-old schoolboy watched the eclipse 3 days before sitting for his General Certificate of Education. Subsequent macular oedema reduced his visual acuity to 6/9 and the central scotomata interfered considerably with his ability to write his examination papers. Full recovery followed in 4 weeks.

Case 3. A 13-year-old schoolboy presented 3 days after the eclipse complaining of a central blind spot in the vision of the left eye. He had observed the eclipse for 30 seconds using smoked glass. The visual acuity was 6/9 in the right eye and 6/18 in the left. There was a slightly granular appearance at the right macula and a focal yellow burn at the left macula; 2 days later there was slight oedema of the right macula but the vision was still 6/9. The vision in the left eye, however, had worsened to 6/24 (partly) because of severe macular oedema.

Treatment was started with systemic steroids, prednisolone 5 mg, three times daily, and the macular oedema gradually subsided. After 6 days the visual acuity was 6/9 in the right eye and the macula appeared normal; the visual acuity in the left eye had also improved to 6/9. One month later the right eye was 6/6 but the left had not improved beyond 6/9; there was a persistent paracentral scotoma with pseudo-hole formation at the left macula.

Case 5. A 22-year-old man was a patient in a mental hospital for a psychotic illness and had no previous history of eye disease. He watched the eclipse constantly throughout its duration and when he was seen 3 days later the visual acuity was reduced to 6/24 in both eyes. There was extensive bilateral macular oedema with pseudo-hole formation. He was treated intensively with systemic steroids but 2 weeks later the visual acuity was still not more than 6/24. After one month the left eye showed a foveal reflex but no improvement in vision occurred on either side and he was subsequently placed on the partially sighted register.

Case 6. An 18-year-old carpenter looked directly at the eclipse with both eyes intermittently through stained glass for about one minute. After the initial glare had worn off he noticed difficulty in reading car number plates and was referred to hospital because an optician could not improve his vision with lenses. When he was seen for the first time 3 months after the injury, the visual acuity was 6/9 in each eye and both fundi showed flat, round punched-out lesions with irregular perimacular pigmentation (Fig. 1, opposite). This was the second episode of solar retinopathy in this patient, who had watched the eclipse 4 years previously with only transient visual disturbance.

Case 13. A 15-year-old schoolgirl sustained severe macular damage and permanent impairment of vision in one eye through observation of the eclipse with and without a filter for a short period. Shortly after the eclipse she noticed blurred vision in the right eye but did nothing about it. When she was seen 3 weeks later the visual acuity was 6/5 in the left eye but only 6/36 with severe

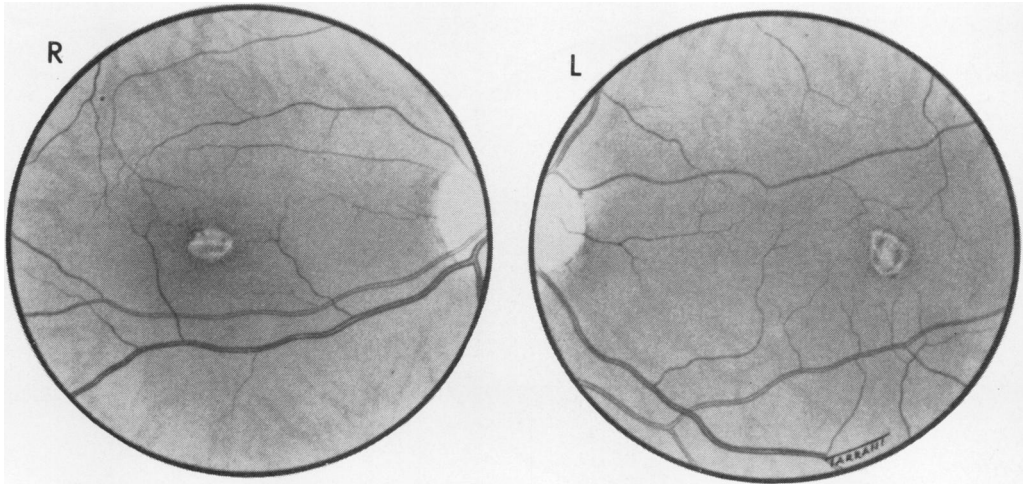


FIG. 1 Right and left fundi of Case 6. Fundus painting showing macular lesion resulting from bilateral solar retinopathy

macular oedema in the right. She was given prednisolone without much benefit. 6 months later the visual acuity in the right eye was still only 6/18, and could not be improved with lenses, and the foveal reflex was absent. Fortunately the left eye was completely normal.

Case 15. A 14-year-old schoolgirl observed the eclipse through dark glasses and an old film negative for about 3 minutes; 30 minutes later she noticed some difficulty with her vision, and 4 days later the visual acuity was 6/36 in the right eye and 6/24 in the left. She had bilateral posterior pole oedema with vesiculation at both maculae. The oedema settled fairly rapidly over a period of 2 weeks with recovery of vision to 6/18 in the right eye and 6/9 in the left. After 6 months the more severely affected right eye showed a small macular hole with visual acuity of 6/18 (partly). The left eye recovered to 6/6 and N.5 with some macular pigmentation.

Case 17. A 45-year-old female barrister, whose hobby was astronomy, observed the eclipse through smoked glass. She subsequently noticed difficulty in reading, and 3 days later had bilateral central scotomata, with visual acuity of 6/9 in each eye. The fundi showed bilateral perimacular oedema and central vesicles. She was given prednisolone 30 mg. daily for 2 weeks and the vision returned to 6/5 in each eye after 6 weeks, but a small paracentral scotoma could still be demonstrated in each eye.

Case 19. A 23-year-old labourer sustained severe bilateral macular burns as a result of sunbathing; 2 days before admission to hospital he had spent several hours lying in the sun and had gazed directly at the sky, without wearing sunglasses, intermittently for about 6 minutes. He was completely unaware of the possible risks of sungazing until he noticed later that day that his vision was poor. The visual acuity was 6/18 in the right eye, and 6/18 (partly) in the left, and could not be improved with spectacle lenses. He had bilateral central scotomata: both maculae showed exudative cystic vesicular lesions with extensive perimacular oedema and posterior vitreous haze. Treatment was started immediately with atropine drops and prednisolone 60 mg. daily by mouth; this was subsequently reduced to 40 mg. daily for one week, and 10 days later the visual acuity had improved to 6/9 in each eye. One month after the injury visual acuity was 6/6 (partly), but he still had bilateral central scotomata, which interfered considerably with reading, and the maculae showed scattered pigmentary changes (Figs 2 and 3).

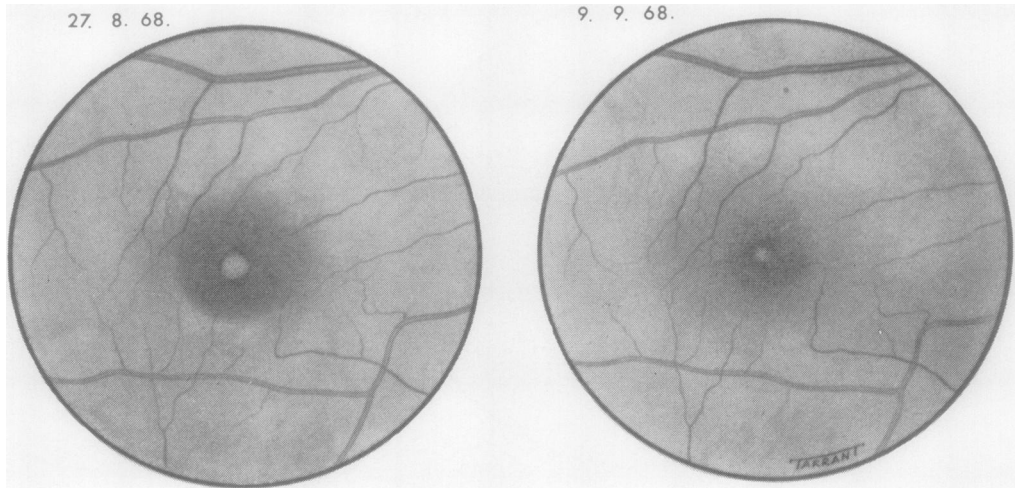


FIG. 2 *Right fundus of Case 19. Fundus painting showing appearance of right macula 3 days after exposure to the sun and the same eye 2 weeks later*

Table II *Initial and final acuity in 29 cases of solar retinopathy*

Visual acuity	Number of eyes	
	Initial	Final
6/60	0	0
6/36	2	0
6/24	3	2
6/18	4	2
6/12	6	2
6/9	9	9
6/6	5	10
6/5	0	4
Total no. of eyes	29	29

Final results

The visual acuities at the end of follow-up are recorded in Table II. Some patients recovered fairly rapidly but many sustained permanent visual damage; of the 29 eyes studied, fifteen had a final visual acuity of 6/9 or less, including two eyes with 6/18 and one patient who was left with a visual acuity of 6/24 in each eye.

Discussion

A retinal burn after exposure to the sun is caused by the destructive thermal effect of the visible rays and the short infrared rays reaching the retina. About 30 per cent. of the incident solar energy is filtered off by the cornea and lens, the remainder being focused on the retina where it is absorbed by the pigment epithelium with the liberation of heat (Verhoeff, Bell, and Walker, 1916).

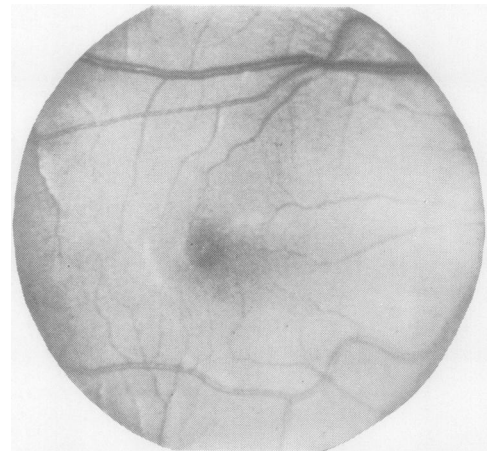

FIG. 3 *Case 19. Fundus photograph showing appearance of right macula 4 weeks after solar injury. Vision 6/6 (partly) with central scotoma*

Most cases of solar retinopathy are the result of eclipse watching and many reports in the literature have indicated the extensive visual damage done over the years (Corcelle, 1958). In spite of frequent warnings in the medical press (Gilkes, Macpherson, Osmond, Thorne, and Roberts, 1959; Gilkes, Roberts, Osmond, and Thorne, 1961), this form of avoidable eye injury still occurs. Ridgway (1967) drew attention to one of the risks of sunbathing in his case of unilateral macular damage with a permanent central scotoma following squinting at the sun whilst sunbathing, and Case 19 in the present series resulted from similar exposure causing bilateral macular burns.

Fig. 4 shows an excellent example of macular changes in the right eye of a meteorological worker, in which the visual acuity was reduced to 6/24. In this case the patient must have been well aware of the risks of injury from solar radiation.

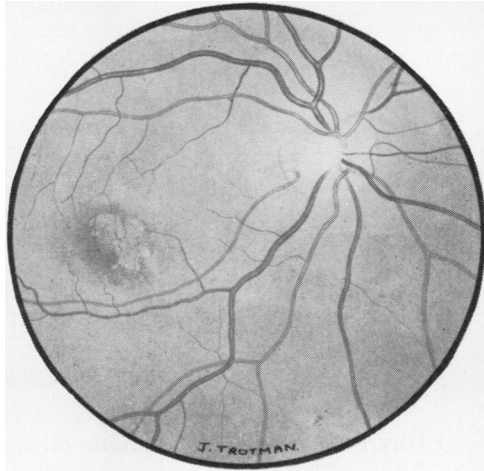


FIG. 4 *Fundus painting showing macular changes in the right eye of a 27-year-old man due to solar injury sustained during meteorological work. Visual acuity 6/24*

An eclipse of the sun is a dramatic natural event which generates great interest, particularly in the young. In this series of eighteen cases of eclipse burns, eleven (61 per cent.) were schoolchildren between the ages of 9 and 18 years. Fifteen cases, mostly children, with permanent retinal damage and impaired central vision were reported by Gilkes and others (1959), and nineteen of 47 cases followed up by Knudtzon (1948) were under the age of 20 years. It is obvious there is a great need for effective propaganda concerning the risks of gazing at the sun with the naked eye, particularly amongst schoolchildren.

Prognosis

There must be many mild cases of solar retinopathy which clear up rapidly with no lasting ill-effects, but of those more seriously affected who reach hospital, many are left with permanent retinal and visual damage with the possibility of late complications. The rate of recovery of visual acuity in the earliest stage is a better guide to prognosis than the degree of initial visual impairment, and if there is early improvement then full recovery can be expected within a month to 6 weeks. The quality and behaviour of the scotoma in the early stages is more important prognostically than the ophthalmoscopic appearance of the macula (Knudtzon, 1948).

Return of visual acuity to 6/6, however, cannot be regarded as recovery of normal vision, because in some cases small residual central or paracentral scotomata could still be detected. Some of these may well be permanent, contributing to persistent difficulty with reading or

close work, as pointed out by Pang (1965), who showed that seven out of 21 cases regained a normal visual acuity but had persistent scotomata. Penner and McNair (1966) recorded a final visual acuity of 6/6 in only 27 out of 52 cases examined after the solar eclipse of 1962. Late complications including obstruction of the central retinal vessels, retinal haemorrhages, retinal detachment, and optic atrophy were listed by Duke-Elder (1954), to which may be added macular degeneration in later life (Corcelle, 1958). Rosen (1948) considered that exposure to the sun may have been a causative factor in 23 cases of macular hole, and it is possible some cases of unexplained macular oedema may be due to the same cause.

Prevention

Duke-Elder (1954) reviewed the factors which tend to protect the eye against radiation damage under ordinary conditions. Injury is most likely to occur only on determined fixation, and even when this lasts for only a brief period permanent visual damage may result. There is no generally available means of protection against the injurious effect of radiation. The results of this and previous studies show that all the so-called protective devices, such as sun glasses, filters, smoked or stained glass, or old negatives do not give effective protection and may even facilitate injury by prolonging the time of exposure. Of the fifteen eyes in this series which did not improve beyond a visual acuity of 6/9, eleven had used one or other of the methods mentioned above. Cogan (1963) pointed out that the harmful rays include not only the visible rays but also the short infrared rays, so that to be effective a filter must also exclude the latter. Most Wratten filters transmit infrared radiation and are, therefore, unsuitable. Welders' goggles (BSS 679/1947), though suitable, are expensive and not easily available. A filter density of 4.5 which does not transmit more than 1 : 30,000 of the total solar radiation is effective and is achieved by the use of two appropriate gelatin filters.

The only way to avoid solar retinopathy is to refrain from looking directly at the sun. If it is desired to observe an eclipse this can safely be done using the indirect method advocated by Flynn (1960), which employs the principle of the pinhole camera. Two pieces of stiff cardboard are required. In the first piece a small central aperture is made. This card is held by the observer with his back to the sun, the image of which is then viewed directly on a second card held below the first.

Summary

A series of 27 eyes damaged by solar retinopathy following the solar eclipse of May 20, 1966, is reviewed, and one case is reported of bilateral macular burns following sunbathing.

The high incidence of eclipse burns in schoolchildren is stressed; eleven of the eighteen cases in this series (61 per cent.) were between the ages of 9 and 18 years.

Fifteen of the 27 eyes affected by eclipse burns had a final visual acuity of 6/9 or less.

Return of visual acuity to 6/6 does not always imply complete recovery, because persistent central or paracentral scotomata, especially if bilateral, may interfere with ability to see small detail.

The best prognostic guide is the quality and behaviour of the scotoma and the rate of return of visual acuity within the first month after injury. Treatment with systemic steroids may be required in cases seen early with severe macular changes or profound visual loss.

Apart from persistent scotomata late complications appear to be rare but macular degeneration may result.

Sunglasses, stained or smoked glass, and old film negatives do not protect against retinal damage following deliberate observation of the sun.

The only safe way to observe an eclipse is by looking at the image of the sun projected through a pinhole aperture on to a screen.

The risks to the eye from observation of the sun at the time of an eclipse and also when sunbathing should be more widely known to the public, especially schoolchildren.

I should like to thank the Medical Committee of Moorfields Eye Hospital for permission to publish details of patients under their care, Mr. Lorimer Fison for his particular interest in this study, Mr. T. R. Tarrant and the Department of Medical Illustration at the Institute of Ophthalmology for the illustrations, and Miss Heather Payne for secretarial assistance.

References

- COGAN, D. G. (1963) *Arch. Ophthalm. (Chicago)*, **69**, 690
CORCELLE, L. (1958) *Arch. Ophthalm. (Paris)*, **n.s. 18**, 555
DAS, T., NIRANKARI, M. S., and CHADDAH, M. R. (1956) *Amer. J. Ophthalm.*, **41**, 1048
DUKE-ELDER, S. (1954) "Text-book of Ophthalmology", vol. 6, p. 6494. Kimpton, London
EIGNER, E. H. (1966). *Amer. J. Ophthalm.*, **61**, 1546
FLYNN, J. A. F. (1952) *Trans. ophthalm. Soc. Aust.*, **12**, 7
——— (1960) *Brit. med. J.*, **1**, 563
KNUDTZON, K. (1948) *Acta ophthalm. (Kbh.)*, **26**, 469
GILKES, M. J. (1968) *Brit. med. J.*, **3**, 678
———, MACPHERSON, D. G., OSMOND, A. H., THORNE, B. T., and ROBERTS, D. ST. C. (1959) *Ibid.*, **2**, 1487
———, ROBERTS, D. ST. C., OSMOND, A. H., and THORNE, B. T. (1961) *Lancet*, **1**, 109
PANG, H. G. (1965) *Amer. J. Ophthalm.*, **55**, 383
PENNER, R., and MCNAIR, J. N. (1966) *Ibid.*, **61**, 1452
RIDGWAY, A. E. A. (1967) *Brit. med. J.*, **3**, 212
ROSEN, E. (1948) *Brit. J. Ophthalm.*, **32**, 23
VERHOEFF, F. H., BELL, L., and WALKER, C. B. (1916) *Proc. Amer. Acad. Arts Sci.*, **51**, 627