

Corneal lesions in myotonic dystrophy

PETER EUSTACE

Royal Eye Hospital, London

Myotonic dystrophy is a disorder of particular interest to ophthalmologists since some degree of cataract is almost universal and being manifest early in the course of the disease may first bring the patient to seek medical advice. Other ocular signs include ptosis, blepharitis, extraocular muscle palsies, macular or more widespread retinal disturbance, and (rarely) corneal lesions (Junge, 1966).

Corneal lesions were first described by von Szily (1918) and other case reports have appeared from time to time (Maillard, 1926; Birnbacher, 1927; Vena Rodriguez, 1963; Calmettes, Géraud, and Déodati, 1964). Several workers studying ocular involvement in a large series of patients with myotonic dystrophy have also reported corneal lesions (Klein, in 1958; Pendefunda, Cernea, and Dobrescu, 1964; Junge, 1966; Burian and Burns, 1967).

The following case is that of a patient with established myotonic dystrophy whose presenting symptoms were due to corneal lesions which progressed to such a degree as to require keratoplasty.

Case report

A 47-year-old woman complained of deteriorating vision and slight difficulty in walking for 14 years. At the age of 17 she was prescribed glasses for astigmatism. When she was 19 she was treated for several months for conjunctivitis. At the age of 20, she had meibomian cysts curetted in both upper lids. Two years later she had a corneal ulcer in the right eye cauterized and at the same time developed marginal ulcers in the left eye. About 3 years later she was admitted to hospital for one week and received pyrexial therapy for an ulcer in the right cornea. In 1963 when she was 33 years old she again had ulcers on both corneae and some blepharitis, and since then she has had regular supervision with a progressive superficial vascularizing keratitis. In 1961 and twice subsequently she has received x-ray treatment for this condition. She had no other complaints and her general health was good.

In September, 1966, she was admitted to the Medical Ophthalmology Unit of the Royal Eye Hospital where a diagnosis of myotonic dystrophy was made.

FAMILY HISTORY

Her mother and one maternal aunt and an uncle had cataracts. Her elder sister has confirmed myotonic dystrophy with cataracts, and a niece, the daughter of this sister, now aged 17, is mentally defective and has myotonic dystrophy. Her own daughter, aged 19, appears normal.

EXAMINATION

Ocular

The visual acuity was 6/60 in the right eye and hand movements in the left eye. The extraocular movements were normal and the pupil reflexes were present but sluggish. There was bilateral squamous blepharitis and ptosis. She was observed to blink only four times in 3 minutes. Some hyperaemia of the conjunctivae was present with a few small aneurysms of the conjunctival vessels. Corneal sensation was reduced in both eyes and the cornea was markedly vascularized principally with blood-filled superficial vessels. There was superficial and stromal scarring with irregularity and

thinning, the left cornea being more involved than the right. Advanced cataracts were present exhibiting the characteristic iridescent spots. No fundus details were apparent.

Schirmer's test gave 30 mm./2 minutes in the right eye and 30 mm./3 minutes in the left.

Goldmann applanation tonometry showed 10 mm. Hg in the right eye and 8 mm. Hg in the left.

General

She showed a typical myotonic facies (Fig. 1). There was widespread weakness and muscle atrophy, particularly of the sternocleidomastoids and shoulder girdle, and a myotonic hand-grasp. Tendon reflexes were absent and she had bilateral flexor plantar responses.

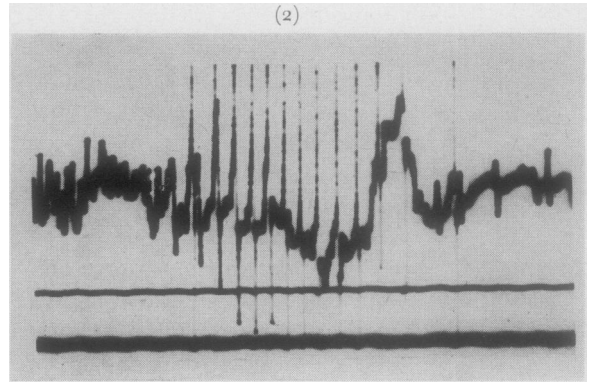
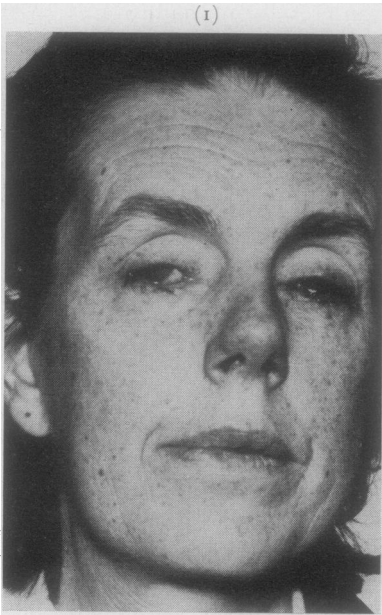


FIG. 2 *Electromyogram, showing "dive-bomber" potentials*

FIG. 1 *Full face view of patient*

Laboratory investigations

Electromyography—

Peroneal muscle biopsy—
 Serum phosphocreatine kinase—
 Haemoglobin and full blood count—
 Erythrocyte sedimentation rate—
 Serum albumin—
 Serum globulin—
 Electrophoresis—
 Serum uric acid—
 Serum cholesterol—
 Wassermann reaction and Kahn test—
 Toxoplasmosis dye test—
 Electrolytes—
 Waler-Rose test—
 Latex RA test—
 Brucella test—
 SGPT—
 SGOT—
 Radio-iodine uptake—
 Blood sugar—
 Serum alkaline phosphatase—

characteristics of myotonic dystrophy with "dive-bomber" potentials (Fig. 2)

"fibroadenose and nervous tissue only"

66.8 i.u./litre (normal 10 to 44)

14.6 g. normal differential

10 mm./first hour

4.5 g./100 ml.

3.0 g./100 ml.

Not abnormal

2.3 mg./100 ml.

230 mg./100 ml.

Negative

Negative

Normal

Negative

Negative

Negative

65 u./100 ml.

96 u./100 ml.

Normal range

70 mg./100 ml.

6.5 K.A. units/100 ml.

TREATMENT

A left 7 mm. penetrating keratoplasty was performed in September, 1967. Postoperatively x-ray treatment was necessary to inhibit vascularization of the graft. In January, 1968, a course of systemic steroids was begun because of slight graft oedema before a left intracapsular extraction which was performed in April, 1968.

RESULT

At the time of writing, the corrected visual acuity in the left eye is 6/24. There is some residual striate keratitis and systemic steroids have been withdrawn.

HISTOLOGICAL FINDINGS

Section shows a full-thickness disc of cornea. The epithelium is irregular and atrophic and there is destruction of Bowman's membrane. There is scarring and vascularization of the substantia propria. The histological features are those of an old keratitis (Fig. 3).

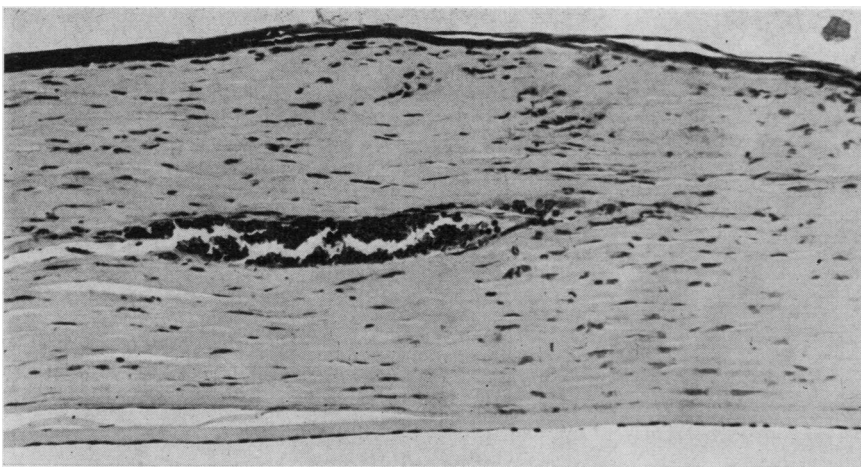


FIG. 3 *Photomicrograph, showing irregular atrophic epithelium and other features of an old keratitis.* × 100

Discussion

Myotonic dystrophy is a complex familial syndrome inherited as an autosomal dominant with varying penetrance and, it is suggested, showing anticipation in succeeding generations (Asseman, Biervacque, and Dufour, 1965). In addition to myotonia, muscle weakness, and cataracts, the patient may also develop alopecia, atrophy of gonads, abnormalities of endocrine function, carbohydrate metabolism (*B.M.J.*, 1966), and deficiency of immunoglobulins IgG (Wochner, Drews, Strober, and Waldmann, 1966).

Though myotonia resembles other forms of myopathy in respect of the muscular wasting, the myotonia is peculiar to this disorder and myotonia congenita. Myotonia congenita, however, begins early in life and is not associated with muscular wasting (Brain, 1962).

The widespread ocular involvement has led several workers to suggest that this condition belongs to that group of comprehensive abiotrophies such as Refsum's syndrome and the Lawrence-Moon-Biedl syndrome (Godtfredsen, 1949; Franceschetti, François, and Babel, 1963; Burian and Burns, 1967). This view is supported by reports of pigmentary retinal disturbance which resembles retinitis pigmentosa (Godtfredsen, 1949; Klein, 1958) and particularly by an abnormal electroretinogram, and dark-adaptation findings which leave no

doubt about the impairment of retinal sensation mainly of the rod system (Burian and Burns, 1966).

The exact nature of the corneal lesions which have been described is undecided, a frequent pattern being superficial recurrent inflammatory lesions and their sequelae. Junge (1966) felt that, in view of the variety of lesions reported, there was probably no causal relationship. Klein (1958), on the other hand, felt that corneal involvement was produced by disordered lid function and a neurotrophic factor, diminished corneal sensation being also reported by Maillard (1926), Verrey (1947), Pendefunda and others (1964), and Burian and Burns (1967).

Lacrimal secretion was investigated by Pendefunda and others (1964), and by Burian and Burns (1967). The former found Schirmer's test to be negative in all thirty patients of their series, although they did not state their criteria of abnormality. The latter found that, if a Schirmer's test of 10 mm. or less in 5 minutes is regarded as positive, twenty out of 36 patients tested gave a positive result, and they found four patients with some evidence of keratitis. They quoted the finding of Pendefunda and others (1964) of round cell infiltration of the lacrimal gland, and considered that the corneal lesions might be related to deficient tear secretion. They also postulated a neurotrophic factor, as evidenced by the finding of diminished corneal sensation in affected cases.

The corneal lesions in the case here described were severe and bilateral with approximate symmetry. Tear secretion was found to be normal and there was no staining evidence of kerato-conjunctivitis sicca. The patient did, however, have some squamous blepharitis and also an unusually slow rate of blinking; these two factors did not seem sufficient *per se* to produce the severe corneal lesions but could possibly have been contributory factors. The reduction in corneal sensation was no more than consistent with the corneal changes and were therefore quite possibly secondary features. The histological examination provided no clue to the aetiology.

It is postulated, therefore, that the corneal lesions may be explained on the basis of involvement of the corneal epithelium by the same dystrophic process affecting the crystalline lens, which is likewise of ectodermal origin.

Recurrent corneal lesion and ulceration are typical of many corneal dystrophies, particularly Reis-Bucklers' dystrophy (Rice, Ashton, Jay, and Blach, 1968) and lattice dystrophy, but they are also seen in Groenouw Types I and II (Duke-Elder and Leigh, 1965), so that the history of recurrent ulceration in this case is quite in keeping with a dystrophic process involving the cornea.

Summary

A case of myotonic dystrophy which presented with corneal lesions is described. Histological examination of one cornea was possible after a penetrating keratoplasty. The aetiology of corneal lesions in association with myotonic dystrophy is discussed.

I wish to thank Miss D. A. Birks for permission and encouragement to report this case and Dr. J. Harry of the Institute of Ophthalmology for the pathological report.

References

- ASSEMAN, R., BIERVACQUE, A., and DUFOUR, D. (1965) *Bull. Soc. Ophthal. franç.*, **65**, 896
 BIRNBACHER, T. (1927) *Z. Augenheilk.*, **62**, 44
 BRAIN, W. RUSSELL (1962) "Diseases of the Nervous System", 6th ed., pp. 741-747. Oxford University Press, London

- Brit. med. J.* (1966) Leader, **2**, 1025
- BURIAN, H. M., and BURNS, C. A. (1966) *Amer. J. Ophthalm.*, **61**, 1044
- , ——— (1967) *Ibid.*, **63**, 22
- CALMETTES, L., GÉRAUD, J., and DÉODATI, F. (1964) *Rev. Oto-neuro-ophthal.*, **36**, 60
- DUKE-ELDER, S., and LEIGH, A. G. (1965) "System of Ophthalmology", vol. 8, pt. 2, pp. 926-944. Kimpton, London
- FRANCESCHETTI, A., FRANÇOIS, J., and BABEL, J. (1963) "Les hérédodégénérescences chorio-rétiniennes", vol. 2, pp. 1079-84. Masson, Paris
- GODTFREDSSEN, E. (1949) *Acta psychiat, neurol. (Kbh.)*, **24**, 435
- JUNGE, J. (1966) *Docum. ophthalm. (Den Haag)*, **21**, 1
- KLEIN, D. (1958) *J. Génét. hum., Suppl.* **7**
- MAILLARD, K. M. (1926) *Klin. Mbl. Augenheilk.*, **77**, 647
- FENDEFUNDA, C., CERNEA, P., and DOBRESCU, G. (1964) *Oftalmologica (Buc.)*, **8**, 219
- RICE, N. S. C., ASHTON, N., JAY, B., and BLACH, R. K. (1968) *Brit. J. Ophthalm.*, **52**, 577
- VENA RODRIGUEZ, A. (1963) *Arch. Soc. oftal. hisp.-amer.*, **23**, 387
- VERREY, F. (1947) *Ophthalmologica (Basel)*, **114**, 281
- VON SZILY, V. (1918) *Klin. Mbl. Augenheilk.*, **61**, 358
- WOCHNER, R. D., DREWS, G., STROBER, W., and WALDMANN, T. A. (1966) *J. clin. Invest.*, **45**, 321