

Experimental study of cartilage setons

M. BLUMENTHAL,† L. S. HARRIS,* AND M. A. GALIN*

*From the *Department of Ophthalmology, New York Medical College, New York, N.Y., and the †Hadassah Medical School, Jerusalem, Israel*

Approximately 10 to 20 per cent. of primary external fistulizing procedures fail to effect long-term reduction in intraocular pressure (Nadel, 1966). Because of this failure rate, the introduction of foreign materials including silk sutures, gold wires, and hairs to maintain patent sclerostomies has been attempted (Rollet and Morean, 1906; Zorab, 1912; Mayon, 1912). A conductive seton was introduced by Stefansson (1925), who used a tube to connect the anterior chamber and subconjunctival space.

Recently, newer plastics and silicone setons have been used in experimental filtration procedures (Bietti, 1955; La Rocca, 1962; Ellis, 1960; Richards and Van Bijsterveld, 1965). Their advantage has been the very slight foreign body reaction, but as with other foreign materials, there is still a tendency for the seton to slip into the anterior chamber or to be extruded from the wound (Ellis, 1960).

The current investigation was designed to produce an experimental seton model in rabbits, using tubes fashioned from autogenous rib cartilage. Since this substance should be well tolerated and integrated into surrounding tissues, the problems of rejection and slippage should be negligible. In addition, the production of successful filtering blebs by this method might provide an experimental tool to explore the histopathology and mechanism of bleb production and failure.

Material and methods

Albino and pigmented rabbits were anaesthetized with intravenous pentobarbitone. Fur was clipped from the chest, the underlying skin was sterilized, and 1.5 cm. lengths of either eighth or ninth rib cartilage were removed through longitudinal paramedian incisions. Cartilagenous tubes 3 to 6 mm. in length with external diameters of 1.5 mm. and lumina of 1 mm. were then fashioned by appropriate drilling.

Broad superior limbus-based conjunctival flaps were then created and the anterior chamber was opened for a diameter of 3 mm. at the limbus. The autogenous cartilage tube was then inserted 1 to 2 mm. into the anterior chamber, the remainder resting in the subconjunctival space. No fixation was used. Before the conjunctival incision was closed with a continuous 6-0 black silk suture, heparin was injected through the tube to reduce aqueous coagulation.

All eyes were examined periodically with the slit lamp, and intraocular pressures were measured by Schiötz tonometry. Gonioscopy was carried out on all eyes before enucleation.

Adequacy of filtration and demonstration of patency of the fistulae were demonstrated in two ways. If a thin polycystic bleb formed, the Seidel test was sufficient to demonstrate filtration. When diffuse blebs were noted, methylene blue was injected into the anterior chamber and the bleb site inspected with the slit lamp for the appearance of the dye. Fig. 1 (opposite) demonstrates a cartilagenous tube *in situ*.

Results

Autogenous cartilage setons were inserted into 57 rabbit eyes which were observed for varying periods up to 6 months. 33 eyes were enucleated for histological study within 2

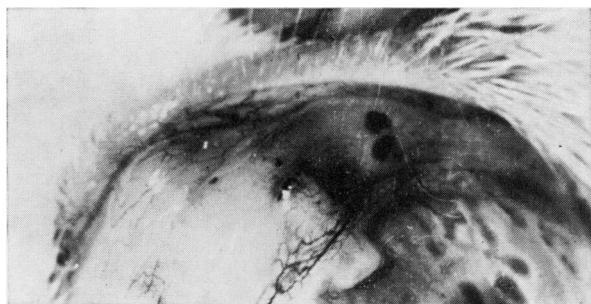


FIG. 1 *Cartilagenous tube in situ 10 days after implantation. Note filtering bleb*

months while the blebs were still actively filtering (Table I), and 22 eyes were enucleated within the week after filtration ceased (Table II). Two eyes with well-functioning blebs 6 months after surgery were retained in order to continue clinical observation.

Table I *Time between date of surgery and enucleation of 33 eyes with functioning blebs*

<i>Number of eyes</i>	<i>Days</i>
11	10-20
11	20-30
11	30-40

Table II *Interval between date of surgery and clinical evidence of bleb failure in 22 eyes, which were then enucleated within one week*

<i>Number of eyes</i>	<i>Days</i>
3	7
5	15
4	21
4	27
3	35
3	48

In no case did the seton become dislocated into the anterior chamber. No relationship was noted between the length of the implanted tube and the success of filtration.

Clinically, most eyes showed mild transient inflammatory reactions about the implant which usually resolved within a week. In only two instances did considerable corneal oedema and vascularization develop at the operative site. In most cases, slight iris atrophy was noted at the site of iris contact with the inner end of the tube. In twelve of the 57 eyes studied, gonioscopy revealed iris tissue in contact with the inner end of the tube, but this did not preclude successful filtration.

Histological examination of eyes in which bleb closure developed revealed the growth of vascularized connective tissue from the episclera into the seton (Fig. 2, overleaf). In no case, however, did proliferation continue into the anterior chamber. The inner surface of most tubes developed a cellular lining resembling endothelium (Fig. 3, overleaf). Although this cellular lining advanced further than the connective tissue, it did not reach the anterior chamber in any case.

Examination of eyes with patent fistulae also revealed an ingrowth of connective tissue with a similar endothelial-like lining, but in these cases, the connective tissue remained peripheral and did not obstruct the lumen.

Discussion

The rationale for autogenous material as an experimental seton was to preclude an immune cause of rejection (Craigmyle, 1955). Cartilage was chosen as the experimental tissue

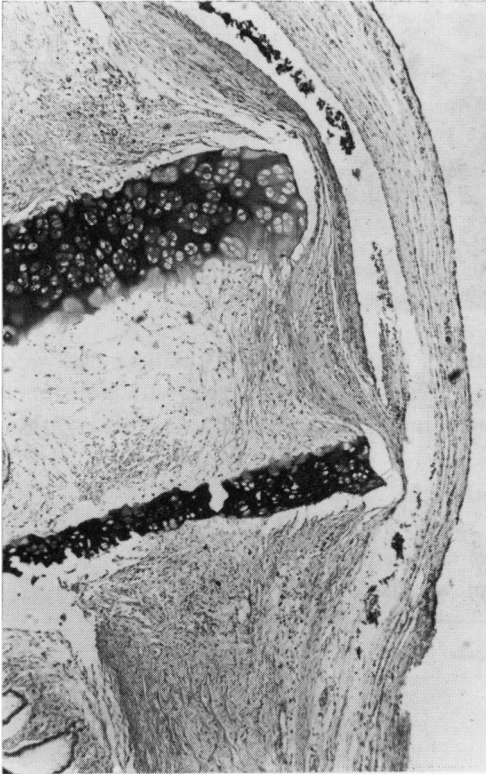


FIG. 2 Oblique section of tube near outer end. Note early ingrowth of connective tissue. $\times 100$

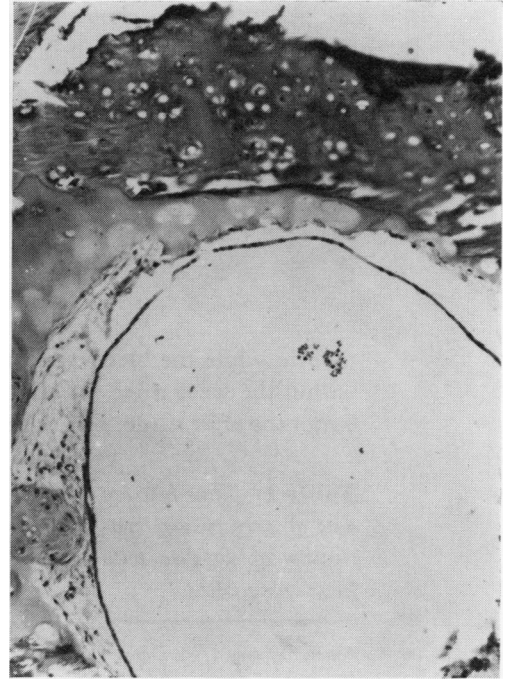


FIG. 3 Cross-section of tube, demonstrating mild connective tissue proliferation with endothelial-like lining. $\times 100$

because it is readily available, is avascular, does not swell or change its texture, is not too hard, is malleable, and lends itself to working with drills and other tools (Davis and Gibson, 1956; Peer, 1955). Living tissue could also be expected to be incorporated into surrounding tissues, precluding the need for fixation. Yet, in this study, 24 of 26 eyes had failed within 6 months and, presumably, the majority of the remaining 33 eyes would have failed had they not been enucleated while the blebs were operative during the early post-surgical phase. These latter fistulae, though patent at the time of enucleation, permit analysis of the process of bleb closure.

It has been inferred that either endothelium or endothelial-like cells form a protective barrier which prevents aqueous from causing digestion of scleral collagen (Teng, Chi, and Katzin, 1959). It is possible that a sclerostomy lined with such an endothelial covering would preclude the progressive polycystic formation noted after certain types of filtering procedures. In particular, it has been observed clinically that the iridencleisis operation does not usually result in a polycystic bleb. This may be due to the epithelial or endothelial covering of the tract provided by the iris, even though it is presumed that iris endothelium is more permeable to aqueous than corneal endothelium. There is little evidence to support the view that aqueous stimulates a fibrotic response of the subconjunctival tissues (Epstein, 1959). The aqueous pathway, after an iridencleisis, would be similar to the conductive mechanism provided by a physiological seton as in this study.

Iridencleisis procedures, then, are physiological seton procedures. They provide an endothelial-like conductive covering, about a non-conductive seton, the iris. Atrophy of the iris substance occurs and a lined sclerostomy results (Spaeth, 1932).

Autogenous cartilage follows a similar route in certain details. The tube becomes lined with endothelial-like cells, probably derived from episcleral tissue. The cartilagenous walls become surrounded by connective tissue but are always identifiable. The main difference, of course, is that the tube is continually conductive while the iris eventually is not. This latter difference may explain the reason for eventual seton failure. Aqueous leaking about an iris wick has an opportunity to initiate scleral collagen digestion. The conductive seton, however, limits scleral aqueous contact and does not lay the groundwork for what appears to be the common denominator of fistula success—an adequate opening bathed in aqueous.

The cause of fistula failure is considered to be due primarily to proliferation of episcleral connective tissue. If this connective tissue becomes lined and thereby protected from the effect of aqueous, the chances of failure are high. With destructive sclerostomies (burning, excision, etc.), little to no endothelial covering of the sclerostomy site results. Instead, a spongy type of tissue frequently fills the gap, behind which a layer of granular sludge is present. These tissues provide little resistance to aqueous passage.

This seton study demonstrates well that episclera will proliferate rapidly and follow close behind an advancing endothelial-like edge. It is interesting that these endothelial-like cells will not continue into the anterior chamber as in the case of epithelial downgrowth.

Most likely, these are endothelial-like cells modified from a pluri-potential anlage while epithelial downgrowth results from a more definitive cell type such as conjunctiva.

It would appear, then, that even with conductive non-immunogenic setons, fistula failure will result if an endothelial-like covering precludes or reduces aqueous contact with surrounding connective tissue and scleral collagen.

Summary

Setons of autogenous rib cartilage were used to connect the anterior chamber and the subconjunctival space to study the mechanism of bleb formation and failure. Connective tissue invades the tube, covered by an endothelial-like lining. This lined conductive system prevents aqueous from reaching the scleral collagen, and polycystic blebs, if formed, do not persist. The histological findings of this study support the concept that polycystic bleb formation requires an adequate sclerostomy continually bathed in aqueous.

The authors wish to thank Dr. I. Michaelson for his assistance in this project.

References

- BIETTI, G. B. (1955) *Acta ophthalm. (Kbh.)*, **33**, 337
 CRAIGMYLE, M. B. L. (1955) *Brit. J. plast. Surg.*, **8**, 93
 DAVIS, W. B., and GIBSON, T. (1956) *Ibid.*, **9**, 177
 ELLIS, R. A. (1960) *Amer. J. Ophthalm.*, **50**, 733
 EPSTEIN, E. (1959) *Brit. J. Ophthalm.*, **43**, 641
 LA ROCCA, V. (1962) *Ibid.*, **46**, 404
 MAYOU, M. S. (1912) *Ophthalmoscope*, **10**, 254
 NADEL, A. J. (1966) *Amer. J. Ophthalm.*, **62**, 955
 PEER, L. A. (1955) "Transplantation of Tissues", vol. 1, p. 97. Williams and Wilkins, Baltimore
 RICHARDS, R. D., and VAN BIJSTERVELD, O. P. (1965) *Amer. J. Ophthalm.*, **60**, 405
 ROLLET, and MOREAU (1906) *Rev. gén. Ophtal. (Paris)*, **25**, 481
 SPAETH, E. B. (1932) *Arch. Ophthalm. (Chicago)*, **8**, 550
 STEFANSSON, J. (1925) *Amer. J. Ophthalm.*, **8**, 681
 TENG, C. C., CHI, H. H., and KATZIN, H. M. (1959) *Ibid.*, **47**, 16
 ZORAB, A. (1912) *Ophthalmoscope*, **10**, 258