

# Ocular leprosy in Malawi

## Clinical and therapeutic survey of 8,325 leprosy patients

U. TICHU AND I. BEN SIRA

*Eye Department, Hadassah Medical Centre, Jerusalem, Israel*

Ocular involvement in leprosy is reported to be very common: Harley (1946) 30 per cent.; Kirwan (1955) up to 100 per cent.; Landau and Gabbay (1955) 90 per cent.; Woods (1961) 60 to 90 per cent. The eye lesions may be due to direct infection by *Mycobacterium leprae*, to exposure and secondary infection consequent to Vth and/or VIIth cranial nerve palsy, or to a sensitivity reaction to leprosy activity elsewhere in the body.

Since the introduction of the sulphones, most cases of leprosy are amenable to treatment. The value of sulphones in the treatment of ocular leprosy and of steroids in leprosy reactions are well known, although no full statistical data is available.

The incidence of leprosy in Malawi is one of the highest in the world according to the World Health Organization (1958), and there were 8,325 registered patients in Southern Malawi in October, 1968. We surveyed all these patients in order to determine the prevalence of ocular involvement, to describe the eye manifestations, and to assess the therapeutic influence of sulphones and steroids on the ocular lesions.

### **Material and methods**

Patients affected by leprosy were examined in the villages (from mobile units),\* in dispensaries, and in leprosaria.

Of the 8,325 registered patients, 7,653 were registered in the villages, 190 in the dispensaries, and the rest in the leprosaria. All were examined either by a leprosy specialist or by a well-trained medical assistant. The Vth and VIIth cranial nerve function and the condition of the anterior segment of the eye were carefully examined. Scrapings were taken for bacteriological examination. Recordings were made (on IBM cards) of the clinical manifestations of the lesions, duration of disease, and treatment. The disease was classified according to the clinical manifestations and the presence of bacilli into the three groups. Lepromatous type was recorded when the profuse areas of granulation tissue contained bacilli. Tuberculoid type was recorded when the lesions were relatively stable and localized and bacilli seldom found. Borderline cases were those in which the clinical appearance was intermediate between the lepromatous and tuberculoid types. The smears in these cases were sometimes mildly positive.

Affected patients were sent by the leprosy specialist or medical assistant to Queen Elizabeth Central Hospital, Blantyre, where they were examined by two ophthalmologists. Ophthalmoscopy, if the state of the media allowed, and slit-lamp examination were performed. If necessary the patients were admitted into the leprosy or the eye department.

An eye was considered to be blind when the corrected visual acuity was 3/60 or below.

## Results

5,827 patients (70 per cent.) had tuberculoid leprosy, 1,914 (23 per cent.) were lepromatous, and 582 (7 per cent.) were borderline cases. Of the 8,325 patients, 532 (6·3 per cent.) had ocular lesions (203 lepromatous, 250 tuberculoid, and 79 borderline: Table I).

Thirty eyes (0·3 per cent. of the 8,325 patients) were found to be blind; twenty of these eyes were lepromatous, eight tuberculoid, and two borderline. The prevalence of ocular manifestations in the three types of leprosy is summarized in Table I.

**Table I** Findings\* in 532 leprosy cases with ocular change, by type of leprosy

Type of leprosy	Eye conditions											
	All		Corneal anaesthesia		Lagophthalmos		Keratitis		Iridocyclitis		Blind	
	No.	Per cent.	No.	Per cent.	No.	Per cent.	No.	Per cent.	No.	Per cent.	No.	Per cent.
Lepromatous (1,914)	203	11·0	55	2·9	50	2·6	36	1·8	129	6·7	20	1·0
Borderline (582)	79	14·0	26	4·5	23	4·0	4	0·7	9	1·5	2	0·4
Tuberculoid (5,827)	250	4·3	167	2·9	198	3·4	47	0·8	5	0·1	8	0·1
Total (8,325)	532	6·3	248	3·0	261	3·1	87	1·0	143	1·8	30	0·3

\* Multiple findings are included separately

There was a difference in ocular involvement in the three types. Most of the cases of iridocyclitis were found in cases of lepromatous leprosy, while most cases of corneal anaesthesia and lagophthalmos were found in the tuberculoid group. The prevalence of iridocyclitis in the borderline group was intermediate between that in the lepromatous and tuberculoid groups.

130 patients (24 per cent.) with ocular complications were known to have been affected by leprosy for periods of less than 5 years, while in 402 cases\* (76 per cent.) the disease was of longer duration. This shows a correlation between the overall prevalence of ocular findings and the duration of the disease. The tuberculoid cases tended to show ocular lesions earlier than the lepromatous ones (Table II), sometimes even in the first months of the disease.

**Table II** Duration of leprosy in 532 patients with ocular lesions, by type of leprosy

Duration (yrs)	Type of leprosy	Under 5		Over 5	
		No.	Per cent.	No.	Per cent.
	Lepromatous (203)	30	15	173	85
	Borderline (79)	25	32	54	68
	Tuberculoid (250)	75	30	175	70
	Total (532)	130	24	402	76

Among the 203 lepromatous cases with ocular lesions, 170 (74 per cent.) were untreated; only twelve (6 per cent.) presented ocular lesions while under dapsone treatment. The rest (20 per cent.) had formerly been treated but the treatment had been discontinued.

\*The duration recorded was, in general, derived from the patient's statement, except in cases where it differed grossly from the clinical manifestations, in which case an estimate was made.

Among the 250 tuberculoid cases with ocular lesions, 85 (34 per cent.) were untreated and 102 (41 per cent.) were receiving appropriate systemic treatment (Table III).

**Table III** *Effect of treatment on prevalence of ocular manifestations, by type of leprosy*

<i>Treatment</i>		<i>Untreated</i>		<i>Formerly treated</i>		<i>Currently treated</i>	
		<i>No.</i>	<i>Per cent.</i>	<i>No.</i>	<i>Per cent.</i>	<i>No.</i>	<i>Per cent.</i>
Type of leprosy	Lepromatous (203)	150	74	41	20	12	6
	Borderline (79)	32	41	29	37	18	22
	Tuberculoid (250)	85	34	63	25	102	41
	Total (532)	267	50	133	25	132	25

#### CLINICAL MANIFESTATIONS

The ophthalmic division of the Vth cranial nerve is affected mainly in the tuberculoid type and results in corneal and conjunctival anaesthesia. Vth nerve involvement was found in 248 patients, of whom only 47 had neuroparalytic KERATITIS.

Palsy of the superior division of the VIIth cranial nerve leads to LAGOPHTHALMOS. This was present in 251 (47 per cent.) of patients with ocular manifestations, 198 (79 per cent.) of the tuberculoid and forty (20 per cent.) of the lepromatous patients being affected. Most of these patients had previously been known to be borderline or tuberculoid cases.

In a few patients a mechanical lagophthalmos was produced by lid infiltration by a lepromatous mass. In one of these, the infiltration, proved histologically, occurred in the lower lid; this has not previously been demonstrated.

CORNEAL INVOLVEMENT was found in 87 patients, 47 affected by exposure keratitis and forty presenting superficial punctate keratitis. In five cases there was PANNUS FORMATION around the whole circumference, resembling an exaggerated arcus senilis (Fig. 1).

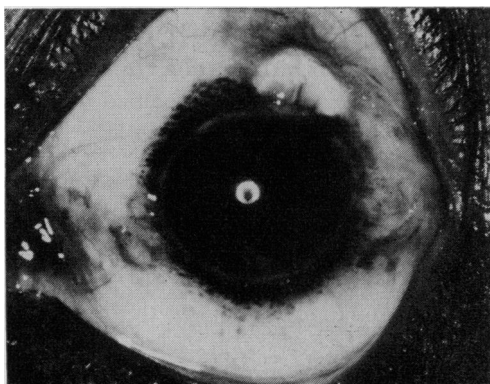


FIG. 1 *Lepromatous leprosy. After filtering operation for glaucoma. Note pannus formation circling the cornea resembling arcus senilis*

IRIS AND CILIARY BODY INVOLVEMENT was a common finding in the lepromatous group and proved to be the main cause of BLINDNESS. It was found in 129 (63 per cent.) of this group. The path of invasion is still uncertain. It could be due to a bacillaemia which is known to be present in the acute reactions, or to invasion through the branches of the Vth nerve. Direct spread from neighbouring structures is unusual. The iridocyclitis is,

however, probably usually due to a uveal sensitivity to leprous breakdown products elsewhere in the body. It can appear spontaneously, or after a new drug is started, and this should be taken into account. It is usually controlled with corticosteroid treatment and with it recovery may be obtained even in desperate cases.

Two types of IRIDOCYCLITIS were found:

(a) *Chronic plastic iridocyclitis* The eye remains completely quiet and synechiae form, leading sometimes to seclusion of the pupil. Lens opacities are common in such cases. In a few cases miliary iris lepromata are found at the pupillary margin, while larger iris nodules are found elsewhere on the iris.

(b) *Acute diffuse iridocyclitis* This condition, which is usually bilateral, has a clinical course characterized by relapses and remissions. Lid swelling, circumcorneal congestion, keratic precipitates, and a plastic unorganized exudate are present. The plastic exudate may fill the anterior chamber. The viscous nature of the exudate permits it to accumulate in the angle of the anterior chamber, without necessarily being affected by gravity (see Fig. 2).

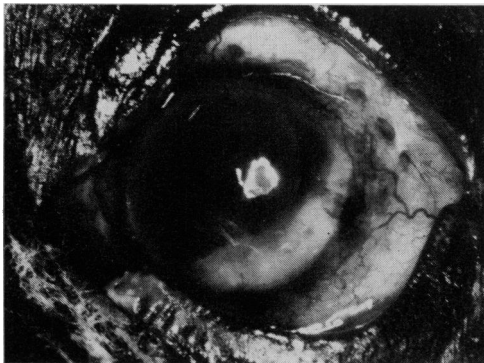


FIG. 2 *Lepromatous leprosy. Plastic iridocyclitis with a viscous exudate not influenced by gravity*

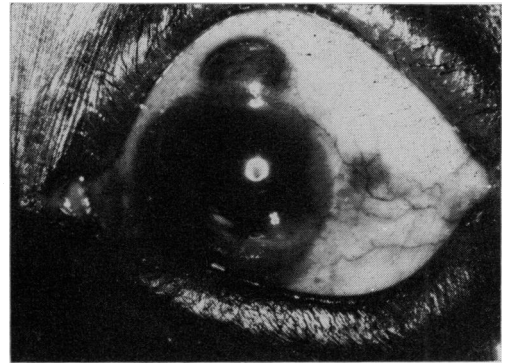


FIG. 3 *Lepromatous leprosy. Plastic iridocyclitis with spontaneous scleral perforation and subconjunctival uveal prolapse accompanied by a filtering bleb*

The iridocyclitis resulted in GLAUCOMA in four patients.

In one lepromatous patient a spontaneous SCLERAL PERFORATION took place near the limbus. A subconjunctival iris prolapse developed, accompanied by a filtering bleb, which resulted in lowering of the previously raised ocular tension (Fig. 3).

If the media allowed, the fundus was examined in the patients who were referred because of lid, conjunctival, corneal, and anterior segment lesions. Occasionally non-specific peripheral CHOROIDITIS was found, but choroiditis was not found at the posterior pole as previously reported by Siqueria de Carvalho (1948) and Aparisi (1950).

### Discussion

The presence of ocular involvement in 6.3 per cent. and of blindness in 0.3 per cent. of 8,325 patients with leprosy is very low in comparison with the figures reported by Harley (1946), Kirwan (1955), Landau and Gabbay (1955), and Woods (1961).

Two factors must be considered in investigating ocular involvement in leprosy.

(1) Duration of disease, to which the ocular affection was found to be in direct relation. Of the 532 patients with ocular manifestations, 402 (76 per cent.) had had leprosy for

more than 5 years. The duration of disease was of greater significance in the lepromatous than in the tuberculoid cases. Some tuberculoid cases were found to have eye complications even after a few months, while in lepromatous cases the eyes were never affected until 2 to 3 years had passed. This is probably related to the slow intraocular invasion of lepra bacilli in lepromatous cases; secondary infection superimposed on cranial nerve lesions in tuberculoid cases occurs sooner.

(2) Systemic treatment. Of the 532 affected cases, 267 (50 per cent.) were untreated and only 25 per cent. were being currently treated. This appears to suggest that systemic treatment helps to prevent ocular involvement. The difference in prevalence of eye lesions between this report and those presented 10 years ago is due to the recent wide use of sulphones. The therapeutic effect of sulphones was found to be higher in lepromatous than in tuberculoid cases. Only 6 per cent. of the lepromatous cases with eye manifestations were currently receiving treatment compared with 41 per cent. of the tuberculoid patients. The sulphones have a specific bacteriostatic effect which prevents intraocular invasion by lepra bacilli, but have no influence on secondary infection superimposed on cranial nerve palsy in tuberculoid cases.

### Summary

The ocular condition in 8,325 Malawi leprosy patients was surveyed; 6.3 per cent. were found to suffer from eye lesions and only 0.3 per cent. were blind.

The patients are classified into lepromatous, borderline, and tuberculoid groups. In lepromatous patients eye lesions occur in the later stages of the disease, and in tuberculoid patients at an earlier stage. Lepromatous patients are affected mainly by iridocyclitis and superficial punctate keratitis. Tuberculoid patients suffer mainly from lagophthalmos and corneal anaesthesia due to nerve palsy (Figs 4 and 5).

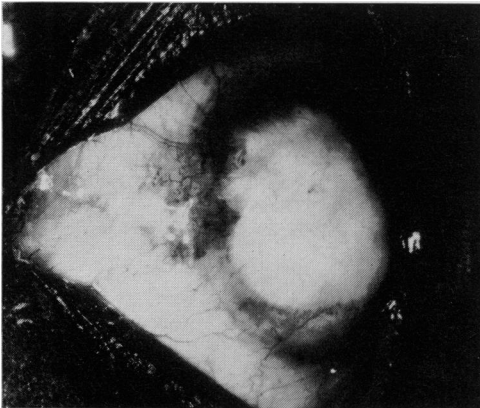


FIG. 4 Tuberculoid leprosy. Total leucoma due to exposure and corneal anaesthesia

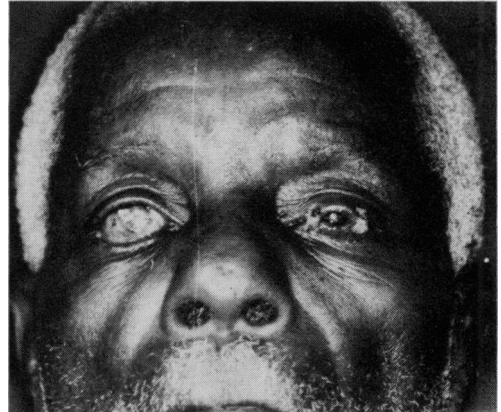


FIG. 5 Tuberculoid leprosy. Lagophthalmos due to VIIIth cranial nerve palsy. Left eye post-tarsorrhaphy

The low incidence of ocular manifestations is considered to be due in part to the wide use of sulphones; this is especially true in the lepromatous group, in which only 6 per cent. had eye lesions while under dapsone treatment. In tuberculoid patients under current treatment eye manifestations were present in 41 per cent.

Steroids are highly effective in controlling hypersensitivity reactions of the uvea.

**References**

- APARISI, T. (1950) *Arch. Soc. ofтал. hisp.-amer.*, **10**, 107
- CHOYCE, D. P. (1955) *Proc. roy. Soc. Med.*, **48**, 108
- (1964) In "Leprosy in Theory and Practice", ed. R. G. Cochrane and T. F. Davey, 2nd ed., p. 310. Wright, Bristol
- HARLEY, R. D. (1946) *Amer. J. Ophthalm.*, **29**, 295
- KIRWAN, E. W. O'G. (1955) *Proc. roy. Soc. Med.*, **48**, 112
- LANDAU, J., and GABBAY, A. (1955) *Acta med. orient.*, **14**, 129
- LOWE, J. (1955) *Proc. roy. Soc. Med.*, **48**, 107
- PRENDERGAST, J. J. (1940) *Arch. Ophthalm. (Chicago)*, **23**, 112
- SIQUERIA DE CARVALHO, J. (1968) *Rev. bras. Oftal.*, **7**, 31
- SOMERSET, E. J., and SEN, N. R. (1956) *Brit. J. Ophthalm.*, **40**, 167
- WOODS, A. C. (1961) "Endogenous Inflammations of the Uveal Tract", p. 74. Williams and Wilkins, Baltimore
- W.H.O. MAP (1958) *Cited by Choyce* (1964), p. 8-9