

Communications

Radiation retinopathy after the application of a cobalt plaque

Report of three cases

M. A. BEDFORD, C. BEDOTTO*, AND P. A. MACFAUL

Moorfields Eye Hospital and St. Bartholomew's Hospital, London

Radiation damage to the retinal vascular system has been held responsible for small vessel occlusion, neovascularization, haemorrhages, and exudates when the whole eye has been involved during the course of therapeutic irradiation for the treatment of retinoblastoma (Martin and Reese, 1945; Howard, 1966), basal cell carcinoma of eyelids or nose, and carcinoma of the paranasal sinuses (Perrers-Taylor, Brinkley, and Reynolds, 1965; Chee, 1968; Gass, 1968).

Local radiation treatment for intraocular neoplasms was introduced by Foster Moore (1935) using radon seeds. From 1948 onwards, the physical principles established by Innes (1964), working in conjunction with Stallard, led to the development of the cobalt 60-applicators, which are now used in many centres throughout the world, not only for the treatment of retinoblastoma but also in certain cases of malignant melanoma of the choroid (Stallard, 1968).

Retinal vascular complications after this form of therapy have been noted in the literature (Stallard, 1961, 1966) but have received little emphasis. However, in a recent study from this unit of ocular complications associated with various types of therapeutic irradiation (MacFaul and Bedford, 1970), attention was drawn to certain vascular lesions which, in some cases, may result in loss of vision in the treated eye.

The purpose of this paper is to report three cases of choroidal malignant melanoma treated with a cobalt 60-applicator and investigated by fluorescein angiography, in which delayed visual loss was associated with retinal vascular occlusions of varying degree.

Case reports

Case 1, a 50-year-old man, was first seen in June, 1967, with an elevated pigmented lesion and associated serous retinal detachment in the infero-nasal quadrant of the left eye about 1.5 mm. from the optic disc; the corrected visual acuity was 6/5. The right eye was normal. Fluorescence fundus angiography showed a pattern compatible with the clinical diagnosis of malignant melanoma of the choroid.

On August 23, 1967, a 7.5 mm. circular cobalt plaque was applied over the base of the tumour and left in place for 14 days, giving an estimated dose of 8,000 r to the summit of the tumour. Over the next 2 months the serous detachment cleared completely and 6 months after treatment the

tumour was noted to be flat and apparently inert. In May, 1968, 9 months after treatment, haemorrhages were observed close to the optic disc. In July, 1968, the fundus showed retinal haemorrhages, cotton-wool spots, and oedema supero-temporal to the optic disc (Fig. 1); angiography showed evidence of occlusion of the small vessels in the upper temporal quadrant, but the main arterial and venous channels were still patent (Figs 2 and 3). In October, 1968, there were haemorrhages and exudates along the inferior temporal vessels, the visual acuity having dropped to 6/18.

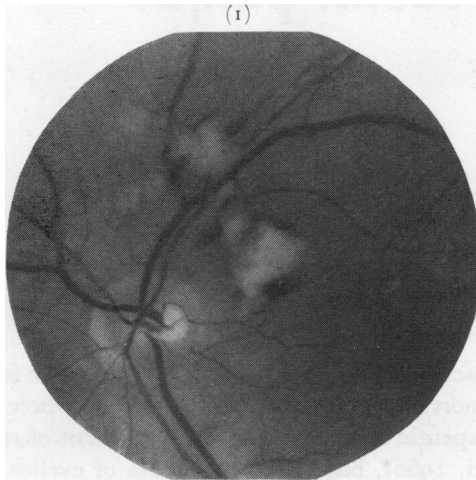


FIG. 1 Case 2. Fundus photograph, 11 months after treatment, showing haemorrhages and cotton-wool spots along superior temporal vessels, the site of the tumour being infero-nasal

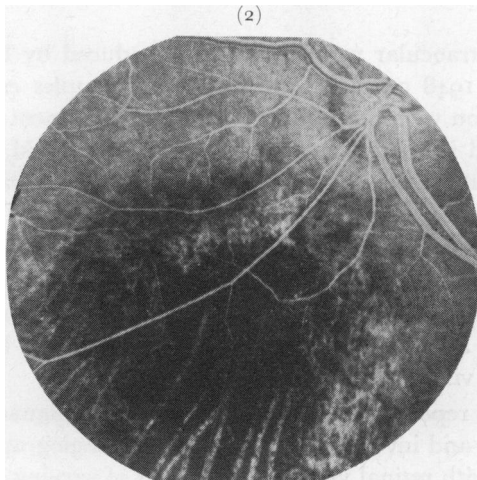


FIG. 2 Case 1. Angiogram, showing choroidal atrophy in treated area and patency of major retinal vessels

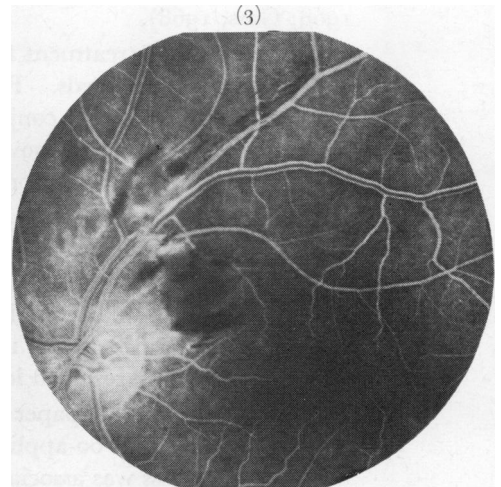


FIG. 3 Case 1. Angiogram, showing patency of large supero-temporal vessels with evidence of occlusion of the small vessels and early fluorescein leakage into the infarcted area of the retina

In May, 1969, 21 months after irradiation, the visual acuity was still 6/18 and, although the supero-temporal vascular changes had regressed, considerable changes were still present in the lower temporal quadrant; angiography at this time demonstrated the patency of the major infero-temporal vessels but also showed extensive areas of capillary closure and telangiectasia (Figs 4 and 5, opposite).

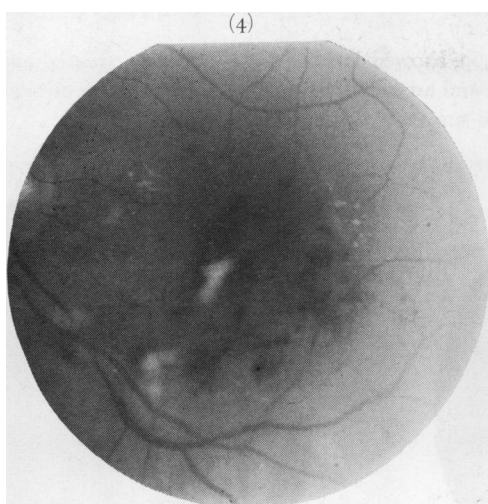


FIG. 4 Case 1. Fundus photograph, 21 months after irradiation, showing oedema with haemorrhages and exudates along the inferior temporal vessels, extending towards the macula

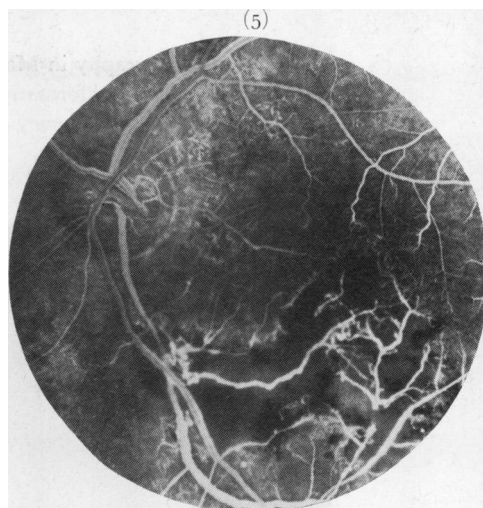


FIG. 5 Case 1. Angiogram, showing patency of major retinal vessels, capillary occlusion, telangiectasia, and new vessel formation in lower temporal quadrant

Case 2, a 51-year-old woman, was first seen in May, 1964, complaining of blurred vision in the right eye for 3 weeks; the visual acuity was 6/9 and there was a lower temporal visual field defect. A diffuse, slightly elevated pigmented lesion was seen almost surrounding the optic disc. The left eye was normal. Although a malignant melanoma of the choroid seemed the most likely diagnosis, it was decided to observe the lesion as a metastasis could not be ruled out. Over the next 9 months visual acuity fell to 6/24; the appearance of a secondary serous retinal detachment and slow extension of the lesion towards the macula favoured the diagnosis of malignant melanoma.

In August, 1965, a C-shaped cobalt plaque was applied to the posterior pole of the eye and left in position for 16 days, giving an estimated dose of 8,000 r to the summit of the tumour; 3 months later the visual acuity was 6/6 and the serous detachment had disappeared. In June, 1966, the area of the tumour was flat and showed radiation scarring. In June, 1967, visual acuity had dropped to 6/60: although the tumour was still inert, haemorrhages and exudates were present below the optic disc and white sheathing of the upper nasal retinal vessels was subsequently noted. In November, 1968, visual acuity remained at 6/60 and the eye was divergent; the retinal vessels showed marked radiation changes with extension of the sheathing out to the periphery (Fig. 6).

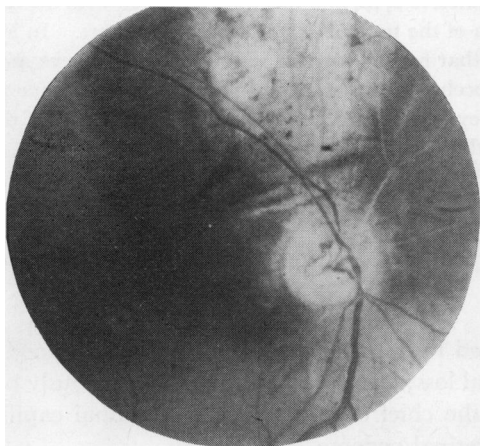


FIG. 6 Case 2. Fundus photograph, 3 years after irradiation, showing extensive choroidal atrophy in treated area and occlusion of superior nasal vessels

Fluorescein angiography in May, 1969, showed loss of capillaries in the treated area with microaneurysms and new vessel formation on and around the optic disc (Fig. 7) and occlusion of the supero-nasal retinal vessels but patency of the supero-temporal vessels (Fig. 8).

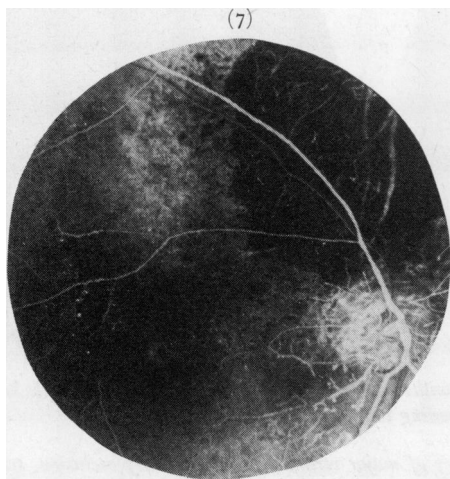


FIG. 7 Case 2. Angiogram, showing extensive capillary occlusion, microaneurysms at the edge of the treated area, and new vessel formation on and around the optic disc

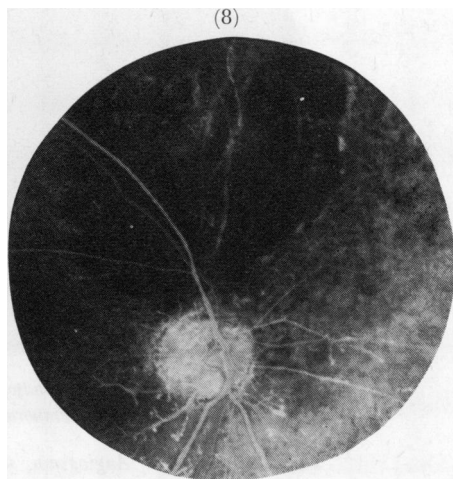


FIG. 8 Case 2. Angiogram, showing occlusion of superior nasal artery and to a lesser degree of the vein; there is extensive choroidal vascular occlusion in the treated area

Case 3, a 53-year-old man, was first seen in February, 1967, with a 3-month history of loss of the temporal visual field in the right eye. On examination the visual acuity was 6/5 and the temporal field defect was confirmed. In the supero-nasal quadrant of the right fundus a large lightly-pigmented tumour was seen and clinical diagnosis of malignant melanoma of the choroid was made. The left eye was completely normal.

In February, 1967, a 15 mm. circular cobalt plaque was applied over the base of the tumour and left in place for 14 days, giving an estimated dose of 8,000 r to the summit of the tumour. During the next 6 months the tumour regressed and in September, 1967, the visual acuity was still 6/6 but a haemorrhage was observed close to the optic disc on the nasal side. In March, 1968, a year after treatment, the visual acuity had deteriorated to 6/18, and this was associated with the onset of marked retinal vessel changes, although the area of the tumour remained flat and inert. In May, 1968, the patient found on waking one morning that he had lost the vision of the right eye and, when seen, the fundus appearance was that of an occlusion of the central retinal artery. Since then there has been no perception of light in the right eye, with signs of optic atrophy, sheathing of the vessels near the disc, and telangiectatic changes in the peripheral retina.

The appearance of the posterior pole in February, 1969, is shown in Fig. 9 (opposite); fluorescein angiography showed the picture of an occlusion of the central retinal artery and no evidence of active tumour (Fig. 10, opposite).

Discussion

These three cases show that localized radiation damage to the retinal blood vessels near the optic disc can lead to severe visual loss; less severe damage has previously been reported after irradiation of the whole eye, the chief defects comprising retinal capillary damage with haemorrhages, exudates, and retinal oedema.

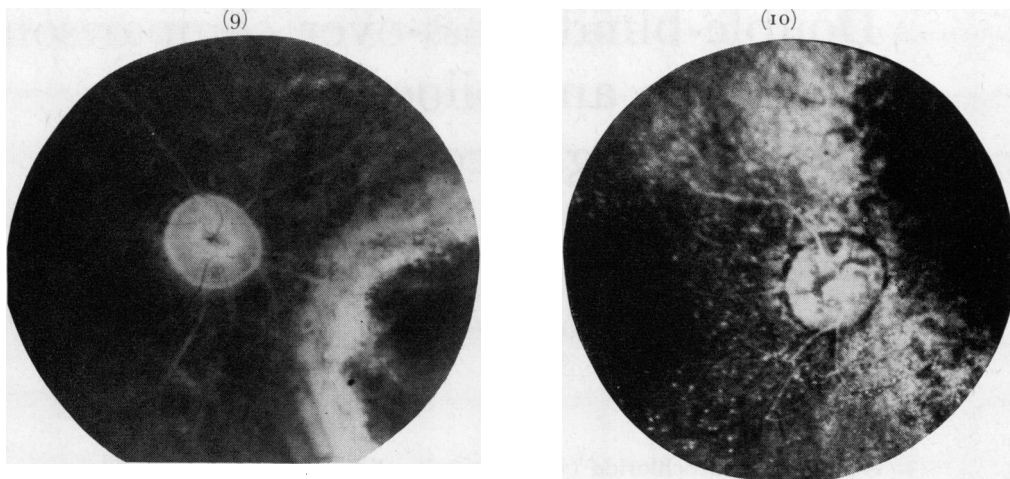


FIG. 9 Case 3. Appearance of the fundus, 2 years after application of a cobalt plaque, showing occlusion of central retinal artery and marked pallor of optic disc

FIG. 10 Case 3. Angiogram, showing almost complete occlusion of central retinal artery

Our cases were treated with cobalt 60-applicators, which deliver a massive dose of gamma rays to a small area: a tumourcidal dose of approximately 8,000 r to the summit of the tumour necessitates about 40,000 r to the sclera and choroid over the base of the tumour in 2 weeks. It is now apparent that these high levels of radiation will damage not only capillaries but also the larger retinal vessels; when a large vessel in or near the optic disc becomes occluded the visual loss can be profound. For this reason, therefore, we feel that a cobalt plaque should not be placed within 5 mm. of the optic disc unless the patient is prepared to accept the possibility of permanent severe loss of vision.

Summary

Three cases of retinal vascular occlusion of varying degree following the treatment of malignant melanoma of the choroid with cobalt 60-applicators are described; the limitations of this form of treatment for melanomata close to the optic disc are discussed.

We should like to thank the Medical Illustration Department at the Institute of Ophthalmology, London, for help with the illustrations and Miss Heather Payne for secretarial assistance.

References

- CHEE, P. H. Y. (1968) *Amer. J. Ophthalm.*, **66**, 860
 GASS, J. D. M. (1968) *Arch. Ophthalm. (Chicago)*, **80**, 606
 HOWARD, G. M. (1966) *Ibid.*, **76**, 7
 INNES, G. S. (1964) In "Ocular and Adnexal Tumors", ed. M. Boniuk p. 142. Mosby, St. Louis.
 MACFAUL, P. A., and BEDFORD, M. A. (1970) *Brit. J. Ophthalm.*, **54**, 237
 MARTIN, H., and REESE, A. B. (1945) *Arch. Ophthalm. (Chicago)*, **33**, 429
 MOORE, R. FOSTER (1935) *Trans. ophthalm. Soc. U.K.*, **55**, 3
 FERRERS-TAYLOR, M., BRINKLEY, D., and REYNOLDS, T. (1965) *Acta radiol. Ther. Phys. Biol.*, **3**, 431
 STALLARD, H. B. (1961) *Ann. roy. Coll. Surg. Engl.*, **29**, 170
 ——— (1966) *Brit. J. Ophthalm.*, **50**, 147
 ——— (1968) *Mod. Probl. Ophthalm. (Basel)*, **7**, 16