

Acute keratoconus in mongols

DERMOT PIERSE AND PETER EUSTACE

Croydon Eye Unit

Acute keratoconus is the term applied to the sudden development of a gross degree of corneal oedema in a patient with a pre-existing keratoconus. This rare condition was probably first described by Terrien (1906). An association between mongolism and acute keratoconus has recently been observed, the first two cases having been reported by Hoffmann (1956). Three cases (two bilateral) are reported below.

Case reports

Case 1, a 17-year-old low-grade mongol boy, was seen at the Croydon Eye Unit on July 29, 1959. His right eye had been red and photophobic for 3 weeks.

Examination

It was not possible to assess the visual acuity. The right eye was hyperaemic and the cornea was thickened, opaque, and oedematous, bulging forward in a globular fashion. The left eye showed early keratoconus.

Treatment

This consisted initially of gutt. atropine 1 per cent. twice daily and a firm pad and bandage. On August 12, 1959, since there had been no substantial change, the main intracorneal bulla was punctured and gutt. hydrocortisone 2-hrly was started. By August 19, 1959 (Figs 1, 2, 3, opposite) an improvement was apparent.

Course

On August 30, 1959, he attended again as an emergency having developed a similar acute keratoconus in the left eye. This eye also was treated with gutt. hydrocortisone 2-hrly and by September 23, 1959, it had virtually recovered.

After 6 weeks the patient was discovered to have a spontaneously-sealed left corneal perforation. A 5 mm. penetrating keratoplasty was carried out on March 13, 1960, but this, although initially clear, subsequently became opaque and vascularized.

Termination

The patient died suddenly at home on April 26, 1962.

Case 2, a 21-year-old mongoloid boy, presented at the Croydon Eye Unit on July 31, 1961. His right eye had been red and photophobic for 9 days.

Examination

It was difficult to assess visual acuity because of lack of co-operation. The right eye was hyperaemic and the right cornea, in about its central two-thirds, was thickened and oedematous, protruding forward in a cone. The left eye showed early signs of keratoconus.

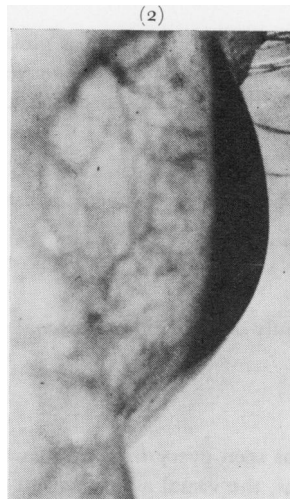
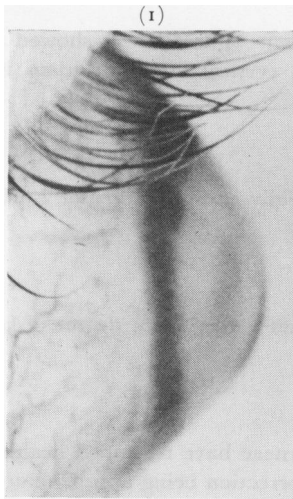


FIG. 1 *Case 1. Lateral view of right eye 3 weeks after onset of keratoconus.*

FIG. 2 *Case 1. Lateral view of right eye 2 weeks later.*

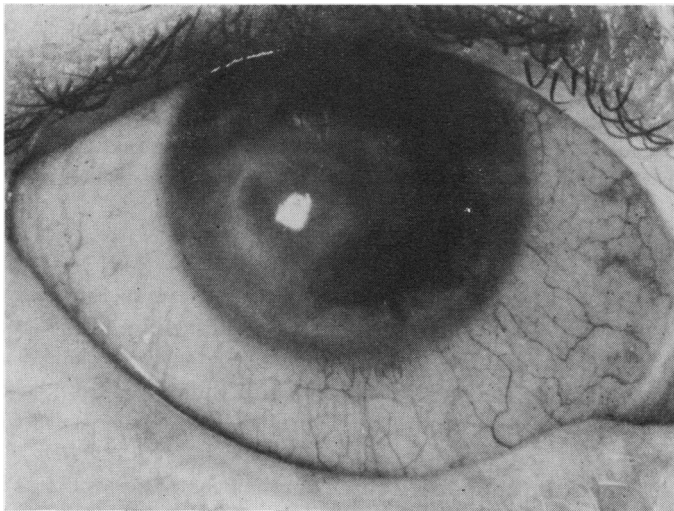


FIG. 3 *Case 1. Anterior view of right eye also 5 weeks after onset.*

Treatment

The affected eye was treated with gutt. atropine 1 per cent. once daily, oculentum chloromycetin once daily, and firm bandaging.

Result

By August 16, 1961, the oedema had almost resolved and when he was last seen on March 10, 1962, the corneae were almost of normal thickness with only slight evidence of keratoconus. There was a small linear superficial scar in the right cornea.

Follow-up

At this time the patient is alive and well and has had no further ocular trouble.

Case 3, a 27-year-old mongol girl, presented at the Croydon Eye Unit on February 22, 1962, with a 4-day history of pain and redness of the left eye.

Examination

The visual acuity appeared very reduced. The right eye was hyperaemic and the cornea was

thickened and oedematous, bulging in a globular fashion. The left eye showed some signs of keratoconus, particularly prominence of corneal nerves, vertical linear striations in the stroma, and a slight coning of the cornea infero-nasally.

Treatment

Initially this comprised gutt. atropine 1 per cent. twice daily and gutt. Predsol 2-hrly, with a firm pad and bandage.

Result

By April 18, 1962, only a small linear stromal opacity and a very slight degree of keratoconus remained.

Course

Subsequently she was seen every 6 months and both corneae have remained healthy with a slight degree of keratoconus, the visual acuity with a myopic correction being approximately the same as it was before the acute episode. After 8 years, however, on January 3, 1970, she again attended as an emergency with a history that her right eye had been red and irritable for the past week. The eye was red and watering and a greyish, thickened cornea was bulging in a globular fashion with considerable corneal oedema. Treatment was started with oculentum Betnesol-N four times a day. For the next 7 weeks there was very little clinical change, but quite suddenly the oedema started to disappear rapidly. There is now only a slight degree of central corneal oedema and the cornea does not appear to be unduly thinned.

Discussion

Acute keratoconus presents as a photophobic watering red eye of relatively acute onset. Visual acuity is greatly reduced. The conjunctiva is hyperaemic. The cornea is cloudy grey, protruding in a globular fashion, and is seen to be greatly thickened with oedema. Often there are large bullae in the stroma and beneath the epithelium, so that the term "acute corneal hydrops" is perhaps more appropriate. Some degree of keratoconus is usual in the other eye.

The development of an acute episode is a rare complication of keratoconus in the normal individual and occurs much more frequently as a complication of keratoconus in mongols and those with other forms of mental deficiency. In 52 cases of acute keratoconus collected from the literature by Appelmans, Michiels, Nelis and Massa (1961), seven were mentally defective and ten were mongoloid. Eye rubbing has been blamed (Ridley, 1961; Cashell, 1962), and other conditions in which eye rubbing is a prominent symptom are known to be associated with keratoconus. Bietti and Ferraboschi (1958) proved the statistical relationship with vernal catarrh, and atopic eczema was shown to be associated with keratoconus by Brunsting, Reed, and Bair (1955). Since Hoffmann (1956) described the first two cases of acute keratoconus in mongols, many other reports have appeared (Leffertstra, 1959; Wilde, 1959; Woillez and Dansaut, 1960; Appelmans and others, 1961; Stanković and Biga, 1961; Kalt, 1962; Grayson, 1963; Dienstbier, 1965; Sédan, 1966). A series of eight cases was discussed by Slusher, Laisbon, and Mulberger (1968). The syndrome of mongolism is now known to be caused by chromosomal aberrations, of which three types have been found: trisomy of chromosome 21 (Lejeune, Gauthier, and Turpin, 1959), reciprocal translocation, one of the 13-15 group being attached to the extra chromosome 21 (Polani, Briggs, Ford, Clarke, and Berg, 1960), and mosaicism, the abnormal cells with trisomy 21 (Clarke, Edwards, and Smallpeice, 1961).

The following ocular features of mongols were listed by Skeller and Öster (1951) in a review of 81 patients: an upward, outward slope of the palpebral aperture 71 per cent., epicanthus 21 per cent., blepharoconjunctivitis 67 per cent., blue or grey iris 88 per cent., Brushfield's spots 86 per cent., lens opacities 46 per cent., convergent strabismus 31 per cent., keratoconus 6 per cent., divergent strabismus 3 per cent., and nystagmus 1·7 per cent. This incidence of keratoconus is in accord with that found by other workers (Wuillez and Dansaut, 1960; Cullen and Butler, 1963), and is very much greater than in the general population (1/40,000—Jonkers, 1950). Rados (1948), who first reported the association of mongolism and keratoconus, quoted Geyer (1939) as having described two similar cases. It seems likely that a dystrophic process involves the epithelium of the cornea and probably also the lens. Histopathological examination shows that the essential changes in early keratoconus are confined to the basal layers of the epithelium and this was well demonstrated by the electron microscopic studies of Teng (1963). In its early stages he found fragmentation of the basement membrane with fibrillation, breaks in Bowman's membrane, and death of basal epithelial cells. He postulated the release of proteolytic and autolytic enzymes from the dead epithelial cells which affect the substance of the stroma leading to loss of collagen. Eventually breaks occur in Descemet's membrane and the endothelium, leading to the development of acute corneal oedema. Eye rubbing could lead to an increased release of these enzymes and thus be an important factor in the development of acute keratoconus.

That rupture of Descemet's membrane and damage to the endothelium is the essential explanation for the sudden development of corneal oedema was first suggested by Terrien (1906); it is now widely accepted, and there has since been ample histological confirmation (Böke and Conrads, 1957; Günther, 1958; Zajác, 1963; Blodi and Braley, 1967). Wolter, Henderson, and Clahasse (1968) described a case in which three acute attacks had been observed to correlate with splits in Descemet's membrane. When the cornea was examined microscopically these splits were revealed by rolled edges with newly-formed membranes between. The newly-formed membranes differed in thickness, suggesting deposition at different times. However, it is common clinical experience that not all splits in Descemet's membrane (such as those that follow unintentional damage during surgery) produce corneal oedema. It would seem reasonable that there must be some additional factor, perhaps previous damage to the collagen of the stroma produced by autolytic enzymes. Experimentally this possibility was supported by Straub, Sautter, and Velten (1958), who were unable to produce corneal oedema after causing splits in Descemet's membrane in rabbits, whereas Appelmans and others (1961) produced a picture resembling acute keratoconus after the intracorneal injection of chymotrypsin, a proteolytic enzyme.

Acute keratoconus is essentially a self-limiting condition; thus treatment needs only to be supportive and should consist of padding the eye as a protective measure and probably the topical use of a steroid-antibiotic preparation. Keratoplasty does not seem to be indicated in the acute phase and is only subsequently advisable if the cornea becomes grossly thinned or the patient's visual requirements demand it; corneal grafting is not indicated to prevent a recurrence. Obviously, when dealing with mongols or other mental defectives, protective measures become more important and one is even less inclined to undertake keratoplasty. Many other forms of treatment have been tried: anterior chamber paracentesis, puncture of the main fluid-containing bulla, cautery to the tip of the cone, tarsorrhaphy, keratoplasty during the acute phase, pressure bandaging, and Diamox to lower the intraocular pressure. Pressure bandaging is widely held to be

an important element in the treatment of acute keratoconus, but it is difficult to see what influence it can have on the healing of Descemet's membrane and the corneal endothelium. Topical steroids may lessen any tendency to corneal scarring, but against their use is the risk of accelerating the thinning process and, more seriously, of inducing a rise in intra-ocular pressure in susceptible subjects.

Of the five eyes dealt with in this paper, four resolved completely with a variety of treatments. The fifth eye perforated after resolution of the acute episode during a period away from medical observation. The behaviour of these eyes bears out the self-limiting nature of the condition and the need for only supportive treatment.

In the past acute keratoconus has been regarded as an extreme rarity. Now, with the increased life expectancy of mongols, ophthalmologists should be prepared to see more examples of this dramatic condition.

Summary

Three cases of acute keratoconus in mongols are described. Possible aetiological factors and management are discussed.

References

- APPELMANS, M., MICHIELS, J., NELIS, J., and MASSA, J. M., (1961) *Bull. Soc. belge Ophthal.*, **128**, 249
 BIETTI, G. B., and FERRABOSCHI, C. (1958) *Bull. Soc. franç. Ophthal.*, **71**, 185
 BLODI, F. C., and BRALEY, A. E. (1967) *Trans. Amer. ophthal. Soc.*, **65**, 146
 BÖBE, W., and CONRADS, H. (1957) *v. Graefes Arch. Ophthal.*, **159**, 277
 BRUNSTING, L., REED, W. B., and BAIR, H. L. (1955) *Arch. Derm. (Chicago)*, **72**, 237
 CASHELL, G. T. W. (1962) *Trans. ophthal. Soc. U.K.*, **82**, 419
 CLARKE, C. M., EDWARDS, J. H., and SMALLPEICE, V. (1961) *Lancet*, **1**, 1028
 CULLEN, J. F., and BUTLER, H. G. (1926). *Brit. J. Ophthal.*, **47**, 321
 DIENSTBIER, E. (1965) *Čs. Oftal.*, **21**, 200
 GEYER, H. (1939) "Zur Aetiologie der mongoloiden Idiotie". Thieme, Leipzig
 GRAYSON, M. (1963) *Amer. J. Ophthal.*, **56**, 300
 GÜNTHER, G. (1958) *Klin. Mbl. Augenheilk.*, **133**, 40
 HOFFMANN, H. (1956) *Ibid.*, **129**, 756
 JONKERS, G. H. (1950) *Ned. T. Geneesk.*, **94**, 1312
 KALT, M. (1962) *Bull. Soc. Ophthal. Fr.*, p. 520
 LEFFERTSTRA, L. J. (1959) *Ophthalmologica (Basel)*, **137**, 432
 LEJEUNE, J., GAUTHIER, M., and TURPIN, R. (1959) *C. R. Acad. Sci. Paris*, **248**, 602
 POLANI, P. E., BRIGGS, J. H., FORD, C. E., CLARKE, C. M., and BERG, J. M. (1960) *Lancet*, **1**, 721
 RADOS, A. (1948) *Arch. Ophthal. (Chicago)*, **40**, 454
 RIDLEY, F. (1961) *Brit. J. Ophthal.*, **45**, 631
 SÉDAN, J. (1966) *Bull. Soc. Ophthal. Fr.*, p. 1031
 SKELLER, E., and ÖSTER, J. (1951) *Acta ophthal. (Kbh.)*, **29**, 149
 SLUSHER, M. M., LAIBSON, P. R., and MULBERGER, R. D. (1968) *Amer. J. Ophthal.*, **66**, 1137
 STANKOVIĆ, I., and BIGA, S. (1961) *Bull. Soc. franç. Ophthal.*, **74**, 394
 STRAUB, W., SAUTER, H., and VELTEN, H. (1958) *v. Graefes Arch. Ophthal.*, **160**, 26
 TENG, C. C. (1963) *Amer. J. Ophthal.*, **55**, 18
 TERRIEN, F. (1906) *Arch. Ophthal. (Paris)*, **26**, 9
 WILDE, S. (1959) *Klin. Mbl. Augenheilk.*, **134**, 410
 WOILLEZ, M., and DANSAUT, C. (1960) *Arch. Ophthal. (Paris)*, **20**, 810
 WOLTER, J. R., HENDERSON, J. W., and CLAHASSEY, E. G. (1967) *Amer. J. Ophthal.*, **63**, 1689
 ZAJĄCZ, M. (1963) *Klin. Mbl. Augenheilk.*, **143**, 503