

# Traumatic optic pathway degeneration

## Antegrade and retrograde

GEORGE H. KURZ, JUN OGATA, AND ELLIOT M. GROSS

*From the Departments of Ophthalmology, Pathology, and Forensic Medicine, New York University*

In the case to be presented degeneration of the optic pathway occurred in both antegrade and retrograde fashion after injury to both optic nerves. In the left eye and possibly in the right as well, not only did the ganglion-cell layer degenerate, but the inner nuclear layer of the retina was also involved. This exemplified retrograde trans-synaptic degeneration.

### Case report

**A 33-year-old white man** was shot in the head in December, 1955, with a .22 calibre bullet. He denied loss of consciousness, but stated that he felt "as if the lights had gone out". A wound of entry was present 2-2½ cm. posterior to and on a level with the external bony angle of the left orbit. His peripheral neurological examination was essentially negative. He noted a mild numb sensation about the left eye. There was a subconjunctival haemorrhage of the left eye. Horizontal ocular movements of the left eye were absent. Only slight superior rectus action remained. There was ptosis of the left upper eyelid. On the left side corneal sensation was reduced and sensation to pinprick was moderately decreased over the ophthalmic branch of the trigeminal nerve. There was slight fuzziness of the edges of the left optic disc; the veins inferiorly were full; no retinal haemorrhages or papilloedema were seen. Both pupils were dilated and did not react to light. There was no light perception in either eye.

In the right eye ocular motility was intact and the retina and optic nerve head appeared normal. Skull *x* rays showed a tract through the posterior orbital cavity on the left and a missile just past the midline to the right side at the level of the ethmoid, just above the medial portion of the superior orbital fissure.

On the day of admission the orbits were unroofed surgically, and haemorrhages and oedema of the periorbital tissues were found on the left. The left optic nerve was intact, but the neurosurgeon did not elevate or rotate the nerve to see if its inferior surface was damaged. He felt that the bullet had passed beneath the left optic nerve. The bullet was found on the right side adjacent to the medial wall of the right optic canal.

In June, 1956, it was reported that the patient had no light perception, no pupillary reaction, and total bilateral optic atrophy.

The patient died at the age of 45 in November, 1968, nearly 13 years after being shot, having been found unconscious in his apartment.

### PERTINENT AUTOPSY FINDINGS

Adhesions were present on the under surface of the brain in the region of the optic chiasm. The olfactory nerves and the optic nerves, chiasm, and tracts were intact, but atrophic and flattened. The proximal portions of the remaining cranial nerves were grossly unremarkable. The base of both frontal lobes showed evidence of old contusion. Both orbital plates were absent. The anterior

clinoid processes and posterior aspect of the cribriform plate were shattered and fibrous tissue was adherent to them.

The remainder of the autopsy showed no unusual findings. Toxicological analysis of the liver revealed barbiturates in the amount of 16.5 mg./100 g., and death was attributed to acute barbiturate poisoning.

#### *Gross examination of eyes*

The left eye measured  $25 \times 24 \times 24$  mm. The cornea was clear and the anterior chamber depth normal. There was a small freckle on the iris near the pupillary border at 3.30 o'clock.

The eye was opened horizontally. There was an oval macular hole and a pigmented chorioretinal scar below the macula.

The right eye measured  $25 \times 25 \times 24.5$  mm. The cornea was clear and the anterior chamber unremarkable. The eye was opened vertically. The lens, retina, and vitreous were in place. The optic nerve head was unremarkable.

#### *Microscopical examination*

##### LEFT EYE:

In some sections a chorioretinal scar was seen at the posterior pole (Fig. 1), while in other sections there was a zone of severe retinal thinning involving all but the outer nuclear layer (Fig. 2). In this zone the inner limiting membrane was somewhat wrinkled. Still other sections showed the macular hole (Fig. 3). In all sections the ganglion-cell and nerve-fibre layers were markedly atrophic and there was thinning of the inner nuclear layer (Fig. 4). A few inconspicuous cystic spaces were present in the inner nuclear layer.

##### RIGHT EYE:

There were scattered small lymphocytes in the iris. Many small vacuoles were present in the superficial lens cortex. The ganglion-cell and nerve-fibre layers of the retina were markedly atrophic

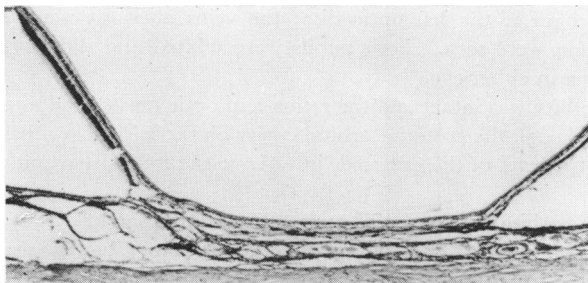


FIG. 1 Chorioretinal scar below macula of left eye. Haematoxylin and eosin.  $\times 23$

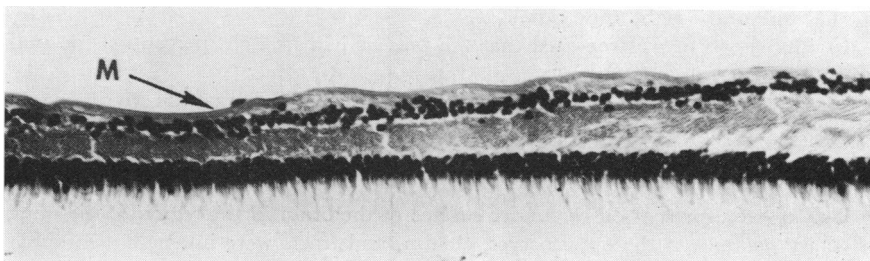


FIG. 2 Retina near posterior pole of left eye, showing loss of nerve-fibre and ganglion-cell layers and severe thinning of inner nuclear layer. Inner limiting membrane (M) is wrinkled. Haematoxylin and eosin.  $\times 224$

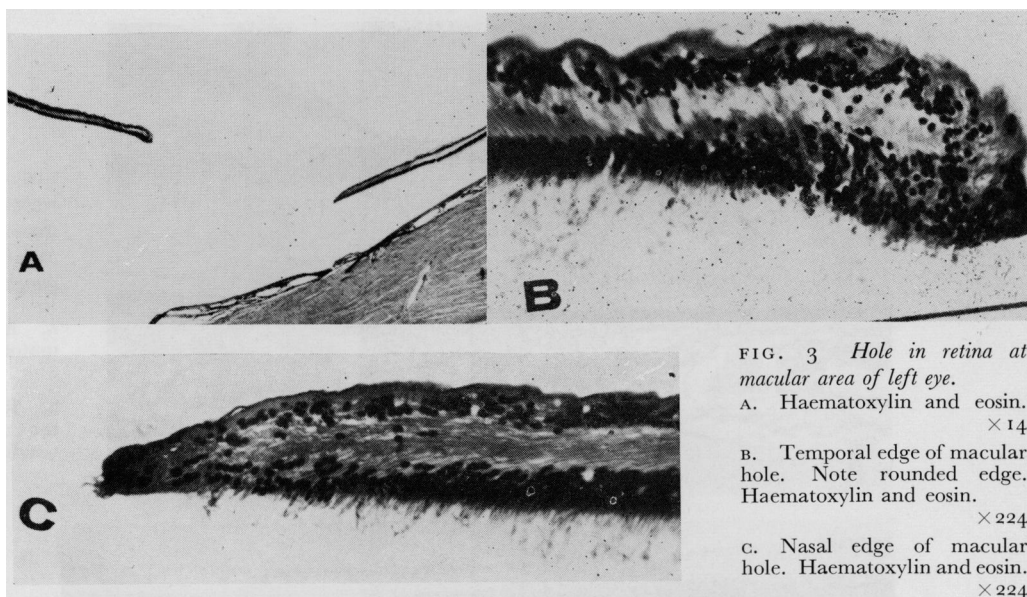


FIG. 3 Hole in retina at macular area of left eye.

- A. Haematoxylin and eosin.  $\times 14$   
 B. Temporal edge of macular hole. Note rounded edge. Haematoxylin and eosin.  $\times 224$   
 C. Nasal edge of macular hole. Haematoxylin and eosin.  $\times 224$

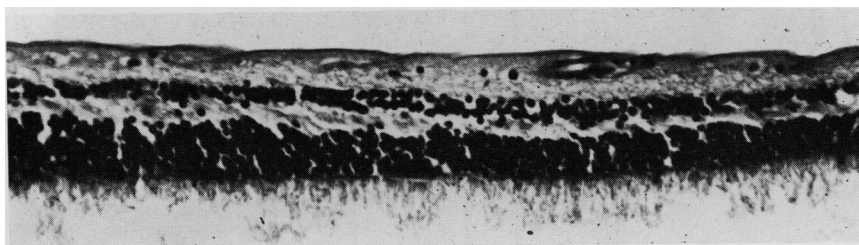


FIG. 4 Retina on nasal side of left eye. Note loss of ganglion cells and diffuse thinning of inner nuclear layer. Haematoxylin and eosin.  $\times 224$

(Fig. 5, overleaf, p. 236). Some of the nuclei in the inner nuclear layer had a washed-out, vacuolated appearance. In addition, there were numerous small empty spaces in this layer (Fig. 6, overleaf, p. 236).

Trypsin digests of both retinæ demonstrated preservation of retinal capillaries, their endothelial cells and intramural pericytes (Fig. 7, overleaf, p. 237). There were a few strands representing degenerated capillaries.

#### OPTIC PATHWAYS

The optic nerves, chiasm, and tracts showed almost complete loss of myelin and axis cylinders (Fig. 8, overleaf, p. 237).

Only rare axis cylinders remained in these areas. There was marked proliferation of astrocytes and their fibres, and fibrosis of reticular spaces around intraneural blood vessels and in the arachnoid.

Both lateral geniculate bodies were shrunken to  $3/4$  of the diameter of a normal control. The laminar pattern of their cells was well preserved (Fig. 9, overleaf, p. 238). All laminae were diminished in size. There was some decrease in number of nerve cells in all laminae, but cell density was increased in laminae 3 to 6. Nerve cells were shrunken in all laminae (Fig. 10, overleaf, p. 238). The Nissl substance of the nerve cells was unremarkable. Nerve fibres in the lateral geniculate bodies were decreased in number. Marked proliferation of fibrillary astrocytes was present (Fig. 11, overleaf, p. 239).

Cells of the various laminae in the central vision projection areas of the left lateral geniculate body were measured in  $15\text{-}\mu$  paraffin-embedded coronal sections. The means of the longest and shortest

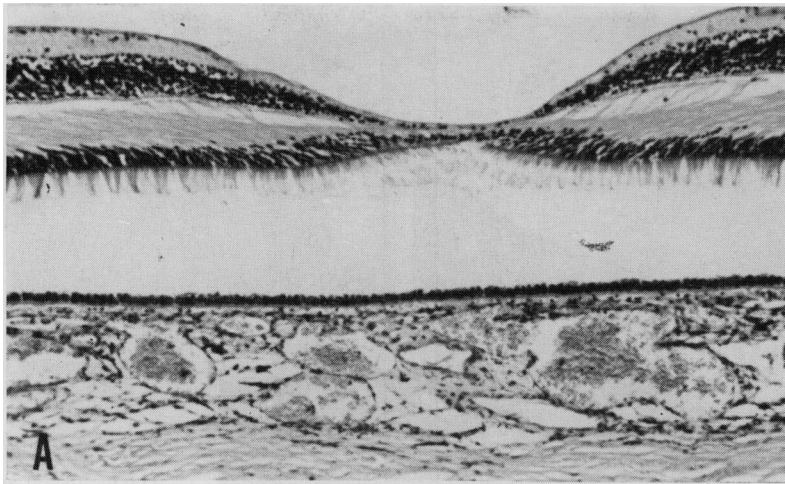


FIG. 5 *Retina of right eye, showing extreme thinning of nerve fibre layer and loss of ganglion cells.*

A. Macula. Haematoxylin and eosin.  $\times 56$

B. Retina near macula. Haematoxylin and eosin.  $\times 56$

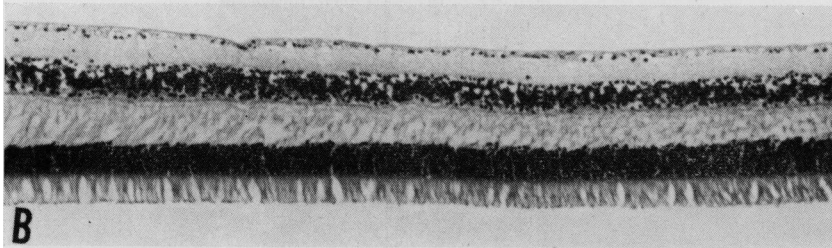


FIG. 6 *Inner nuclear layer of retina of right eye*

A. Multiple cystic spaces (arrows). Haematoxylin and eosin.  $\times 240$

B. Nuclei with washed-out vacuolated appearance (arrows). Haematoxylin and eosin.  $\times 600$

diameters of thirty cells in each lamina, measured by means of a screw micrometer eyepiece, were compared with a normal control from a slightly older man (Table, overleaf, p. 239). Shrinkage of cells to between 74 and 87 per cent. of normal was observed. The measurements of Chacko (1949) are presented for comparison.

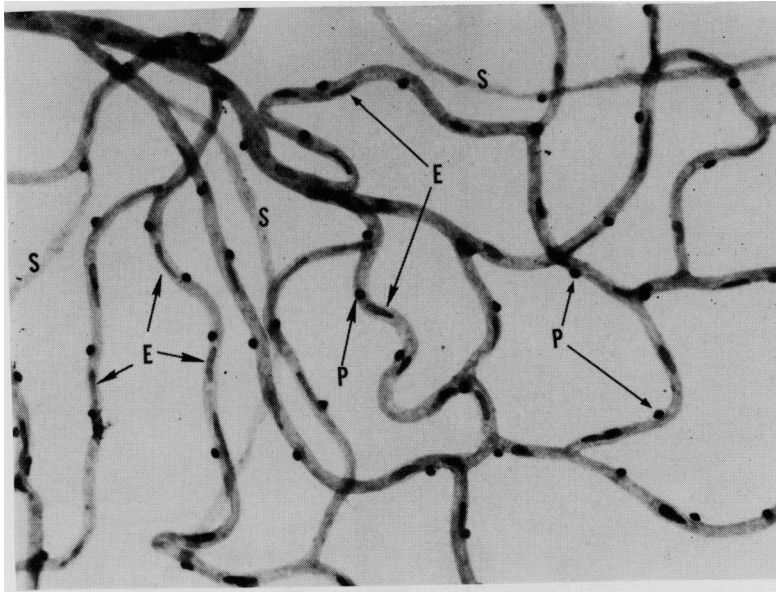


FIG. 7 *Trypsin digest preparation of retina, showing preservation of capillaries, endothelial cells (E), and intramural pericytes (P). Only a few acellular strands (S), representing degenerated capillaries, are seen. Right eye. PAS.  $\times 214$*

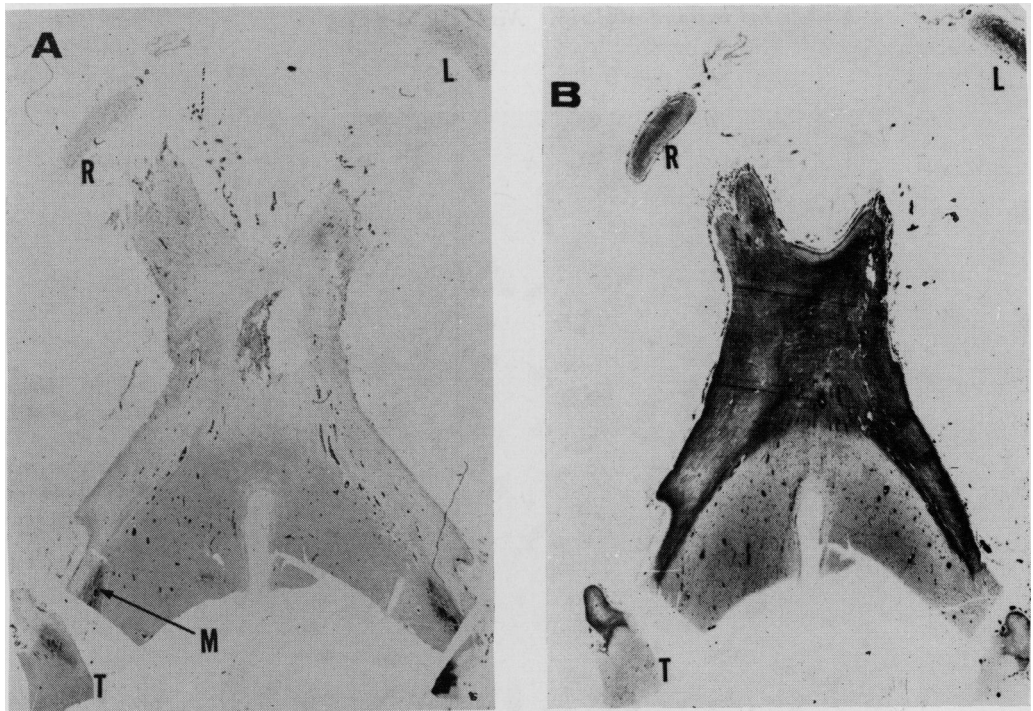


FIG. 8 *Optic nerves, chiasm, and tracts, showing total loss of myelin and severe gliosis. Normal myelin staining (M) is seen in hypothalamus. Cross-section of flattened right (R) and left (L) optic nerves. Cross-section of right optic tract (T).*

- A. Combined PAS-Luxol fast blue for myelin.  $\times 5$
- B. Holzer for glial fibres.  $\times 5$

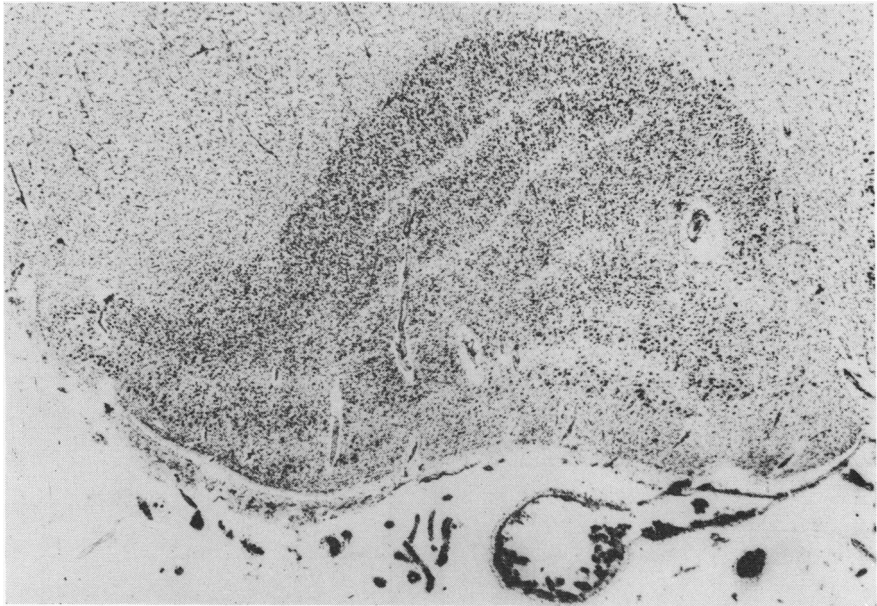


FIG. 9 *Coronal section of left lateral geniculate body. Shrinkage of lateral geniculate body as a whole and increased cellularity. Nissl, 15 $\mu$ .  $\times$ 22.5*

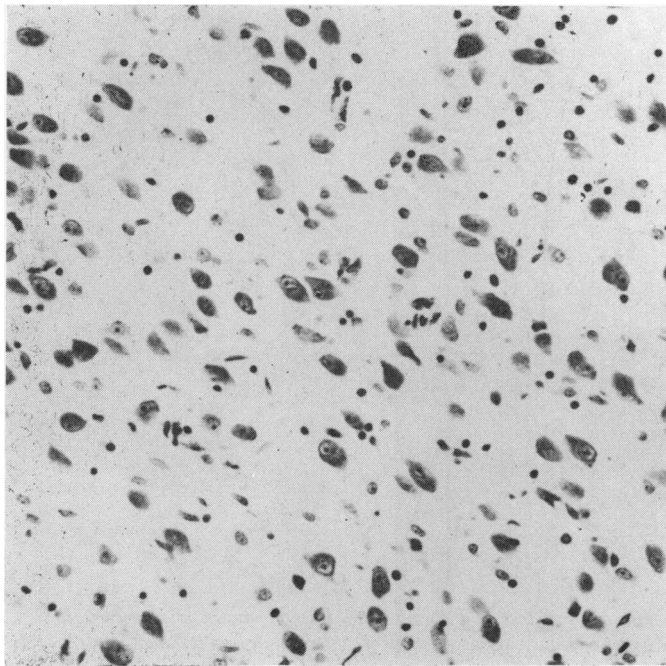


FIG. 10 *Higher power view of lamina 3 of left lateral geniculate body. The nerve cells are atrophic and the nerve and glial cells increased in number. Nissl stain, 6 $\mu$ .  $\times$ 260*

Both geniculo-calcarine tracts had slight proliferation of astrocytes and some rarefaction of nerve fibres. The visual cortex showed no specific changes.

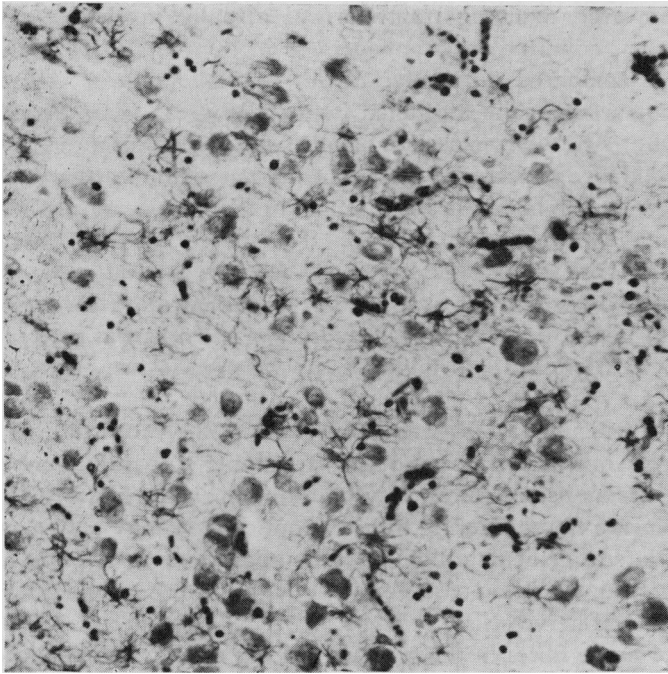


FIG. 11 *Astrocytes, showing proliferation and formation of fibres in lamina 3 of left lateral geniculate body. Holzer stain, 10 $\mu$ .  $\times$  260*

**Table** *Cells of lateral geniculate body. Means of diameters of cells in microns (with standard deviations) in different laminae in central vision area*

<i>Lamina</i>	<i>Present Case</i>	<i>Control*</i>	<i>Chacko (1949)</i>
1	17.8 $\pm$ 3.8	23.0 $\pm$ 3.9	23.1
2	20.0 $\pm$ 3.0	24.0 $\pm$ 3.4	24.0
3	14.2 $\pm$ 1.7	17.0 $\pm$ 2.0	18.9
4	14.3 $\pm$ 1.8	16.8 $\pm$ 2.0	17.1
5	14.3 $\pm$ 2.2	19.4 $\pm$ 3.2	15.9
6	15.2 $\pm$ 1.6	17.5 $\pm$ 2.3	14.7

\*52-year-old male

### **Comment**

#### *(a) Antegrade degeneration*

Antegrade trans-synaptic degeneration of neurons is well exemplified in degeneration of cells in the lateral geniculate bodies after the enucleation of an eye.

Goldby (1957) studied the lateral geniculate bodies of a 59-year-old man who died 36 to 40 years after enucleation of one eye. He observed considerable shrinkage of each affected lamina compared with the corresponding normal lamina of the opposite side. Cell density was approximately the same in the atrophic as in the normal laminae, but the remaining cells of the atrophic laminae exhibited a diminution in the size of the perikaryon of the neurons and a variable loss of Nissl granules. Glial proliferation was also observed.

Kupfer (1965), however, studying transneuronal atrophy in the lateral geniculate nuclei of seven patients, noted no apparent increase in the number of glial elements in atrophied laminae as compared qualitatively with normal laminae. He observed no indication of loss of neurons in the atrophied laminae before 2 years had elapsed after unilateral enucleation. After longer periods of time, cell loss did occur.

In spite of the abundance of reported cases showing antegrade trans-synaptic degeneration of the lateral geniculate bodies in cases of unilateral optic nerve involvement, cases of bilateral optic nerve involvement are lacking. This may be partially explained by the difficulty of evaluating the lateral geniculate body when the selective laminar atrophy seen in unilateral cases is missing. Shrinkage of the lateral geniculate bodies as a whole was the most distinguishing feature. Although the density of the cells was increased, the total number of neurons was decreased and there was a reduction in size of the perikaryon of the remaining neurons.

Gliosis of the lateral geniculate bodies was another prominent feature of this case. Precise measurements may be impossible because the stretching of paraffin-embedded brain tissue which usually occurs in processing may be reduced by the gliosis. It is also conceivable that loss of nerve fibres entering from the optic tracts may play a major role in the shrinkage of the lateral geniculate bodies. The gliosis seen in the lateral geniculate bodies could be largely an extension of the optic tract gliosis rather than entirely reactive gliosis secondary to loss of nerve cells.

Slight reduction of nerve fibres in the geniculo-calcarine tracts secondary to the loss of neurons in the lateral geniculate bodies is another feature of the antegrade trans-synaptic degeneration.

(b) *Retrograde degeneration*

Van Buren (1963) demonstrated experimentally antegrade and retrograde trans-synaptic degeneration in three monkeys. In two of the animals section of the optic chiasm was followed by degeneration of layers 1, 4, and 6 of the lateral geniculate bodies (antegrade trans-synaptic) and extensive loss of ganglion cells in the nasal side of the retinae. The retrograde degeneration crossed the synapses between the ganglion cells and bipolar cells, as shown by cystic changes in the inner nuclear layer. The time interval was 20 months. In the third animal 4 years after ablation of the right occipital lobe there was marked atrophy of the lateral geniculate body on the same side (retrograde degeneration), shrinkage of the right optic tract to 44 per cent. of the cross-sectional area of the left, and loss of ganglion cells on the right side of the fovea of both eyes (trans-synaptic retrograde degeneration).

The slow progress of degeneration of the central stump of a severed axon as compared to the peripheral stump (Wallerian degeneration) has long been recognized (Cole, 1968). The central stump may undergo a more subtle but definite atrophy. The astrocytic and microglial reaction accompanying Wallerian degeneration stands in marked contrast to the paucity of reaction in the central stump.

For degenerative changes to appear in the neuron preceding the injured one in the pathway of the impulses (trans-synaptic retrograde degeneration) much longer periods of time are undoubtedly required. Van Buren (1963) postulated the presence of a feedback system as the explanation for retrograde degeneration across a synapse. Wolter and Lund (1968) presented evidence for centrifugal fibres in the nerve-fibre layer of the retina. Altered activity in these might play a role in degeneration of cells in the inner nuclear layer.



Numerous reports of retrograde degeneration in the visual pathways occurring in man have been well summarized by Gills and Wadsworth (1967). These include optic atrophy after long-standing occipital injury, loss of retinal ganglion cells in patients with tumours of the optic chiasm and tracts, and complete absence of ganglion cells and signs of degeneration in some cells of the inner nuclear layer in a patient with an optic nerve tumour. In the last case the electroretinogram was essentially normal despite total amaurosis for more than 5 years.

Kupfer (1963) commented that within 6 months a lesion of the optic nerve fibres at the level of the chiasm results in retrograde degeneration of the corresponding retinal ganglion cells. Cell degeneration, he postulated, ensues because of lack of collaterals from the main axon trunk.

Gills (1966) noted larger electroretinographic responses in eyes of two humans with sectioned optic nerves than in their companion eyes, supporting the concept of centrifugal fibres in the optic nerve that may be inhibitory.

In nine autopsied eyes with lesions of the optic nerve of more than 2 years' duration, Gills and Wadsworth (1967) observed a significant reduction in the cellularity of the inner nuclear layer. They pointed out the possibility that inner-layer nuclear changes might be a consequence of a secondary or tertiary mechanism rather than any direct effect on the connecting neuron by the degenerating ganglion cell.

Retrograde degeneration in our case is most readily demonstrated by the absence of retinal ganglion cells. Cross-sections of the optic nerves 9 and 16 mm. posterior to the globes also showed severe atrophy. Retrograde trans-synaptic degeneration was indicated by the reduction in cellularity of the inner nuclear layer, especially in the left eye, and possibly the empty spaces and vacuoles in the inner nuclear layer of the right eye. Similar empty spaces are present but much less conspicuous in the thinned inner nuclear layer of the left eye. It is difficult to be certain, however, that these empty spaces and vacuolated nuclei were not due to *post mortem* changes rather than to true degeneration. They were similar to the cystic changes observed in the monkey reported by van Buren (1963) and the human case reported by Gills and Wadsworth (1967). The retrograde changes, as expected, were not accompanied by gliosis.

The left eye, in addition, contained a zone of severe retinal thinning, a chorioretinal scar, and a macular hole. We believe these findings, not present in the right eye, can be accounted for as follows: on the side of entry of the bullet a much greater effect was undoubtedly produced on the orbital tissues than on the opposite side where the bullet came to rest adjacent to the optic canal. The path of the bullet came much closer to the left eye than to the right. A concussion wave travelled through the semi-fluid orbital contents. The concussion effect on the left eye resulted in retinal oedema and ultimately in the structural changes noted above.

The exact cause of blindness must remain partly unexplained, since neither optic nerve was mechanically trans-sectioned. The concussion effect of the bullet as it passed beneath the left optic nerve and came close to the right optic nerve may have produced its damage in various ways: tearing of axons; compression of axons by oedema or haemorrhage into the optic nerve meninges or the nerve itself; ischaemia from tearing of small pial vessels or vessels within the nerve itself (Duke-Elder, 1954). The result was immediate total and permanent blindness.

The finding of an intact retinal vascular pattern as demonstrated by trypsin digestion may seem surprising in view of the long-standing degeneration of the inner retinal layers. It is consistent, however, with the conclusions of Gerstein and Dantzker (1969) and Dantzker

and Gerstein (1969) that vascular degeneration occurs after exposing the retina to procedures which are destructive to the outer cell layers. The resulting proximity of the choroidal capillaries to the inner layers leads to an increased oxygen tension which has a vasoconstrictive and degenerative effect on the retinal microvasculature.

Henkind, Charles, and Pearson (1970) likewise found normal cellularity of digest preparations in a patient who had ischaemic optic neuropathy with retrograde degeneration of ganglion cells in one eye.

We cannot rule out transient spasm of the central retinal arteries as a possible contributory factor in the retinal findings of our case. Reinecke, Kuwabara, Cogan, and Weis (1962) demonstrated experimentally that retinal changes produced by ischaemia in the cat for periods less than 1½ hours were reversible. After longer periods of retinal ischaemia the digest preparations eventually showed a network of acellular capillary strands. Endothelial cells and intramural pericytes had virtually all disappeared.

### Summary

A 45-year-old man had been totally blind following a gunshot wound which injured both optic nerves nearly 13 years previously. *Post mortem* examination revealed degenerative changes in the injured neurons (retinal ganglion cells and distal and proximal stumps of their axons) as well as antegrade trans-synaptic degeneration (lateral geniculate body) and retrograde trans-synaptic degeneration (inner nuclear layer). A macular hole and a chorioretinal scar were also present in one eye. The retinal vascular pattern remained intact.

We wish to express our appreciation to Charles E. Corcoran, M.D., for providing the clinical history and to Gleb H. Budzilovich, M.D., for help in interpreting neuropathological findings.

### References

- CHACKO, L. W. (1949) *J. Anat. (Lond.)*, **83**, 254
- COLE, M. (1968) "Retrograde degeneration of axon and soma in the nervous system", in "The Structure and Function of Nervous Tissue", ed. G. H. Bourne, vol. 1, chap. 7, p. 269. Academic Press, New York
- DANTZKER, D. R., and GERSTEIN, D. D. (1969) *Arch. Ophthalm. (Chicago)*, **81**, 106
- DUKE-ELDER, S. (1954) "Textbook of Ophthalmology", vol. 6, Injuries. Kimpton, London
- GERSTEIN, D. D., and DANTZKER, D. R. (1969) *Arch. Ophthalm. (Chicago)*, **81**, 99
- GILLS, J. P., JR. (1966) *Amer. J. Ophthalm.* **62**, 287
- and WADSWORTH, J. A. C. (1967) *Invest. Ophthalm.*, **6**, 437
- GOLDBY, F. (1957) *J. Neurol. Neurosurg. Psychiat.*, **20**, 202
- HENKIND, P., CHARLES, N. C., and PEARSON, J. (1970) *Amer. J. Ophthalm.*, **69**, 78
- KUPFER, C. (1963) *Arch. Ophthalm.*, **70**, 256
- (1965) *J. Neuropath. exp. Neurol.*, **24**, 653
- REINECKE, R. D., KUWABARA, T., COGAN, D. G., and WEIS, D. R. (1962) *Arch. Ophthalm. (Chicago)*, **67**, 470
- VAN BUREN, J. M. (1963) *J. Neurol. Neurosurg. Psychiat.*, **26**, 402
- WOLTER, J. R., and LUND, O. E. (1968) *Amer. J. Ophthalm.*, **66**, 221