

Haemorrhagic glaucoma

Comparative study in diabetic and nondiabetic patients

P. H. MADSEN

From the Departments of Ophthalmology and Internal Medicine, the University Hospital, Aarhus, Denmark

Haemorrhagic glaucoma occurs in patients with many different basic diseases. It is most common in diabetics and in patients with thrombosis of the central retinal vein, but may also be seen in those patients with 'pure' arterial occlusions without visible concomitant affection of the retinal veins.

Most authors have described haemorrhagic glaucoma after one of these disorders, but only few have recorded comparative examinations.

A comparative study of haemorrhagic glaucoma in diabetic and non-diabetic patients seen in the Department of Ophthalmology, Aarhus Kommunehospital, during the period 1963-1968 is reported below. All patients admitted to the department for haemorrhagic glaucoma in the 5-year period are included in the study.

Material

The series consists of seventy patients with haemorrhagic glaucoma, most of whom were examined by the author.

Thirty suffered from diabetes mellitus, and the other forty were nondiabetics. In 26 of the nondiabetics thrombosis of the central retinal vein was observed either in the department or by the referring ophthalmologist. Three patients without diabetes had severe arteriosclerosis or sequelae of previous arterial embolism, but no signs of thrombosis of the central vein; in eleven the fundus could not be inspected because of opacities in the refracting media.

In the great majority of the patients retinal arteriosclerosis was observed in one or both eyes.

The age distribution of the diabetic and nondiabetic patients is given in the Table (opposite). The average ages of the two groups were 49.2 and 66.9 years respectively. This difference is statistically significant ($P < 0.001$).

There were slightly more women than men in the diabetic group, and a definite male preponderance among the nondiabetics.

Findings

Complicating diseases affecting general health

Vascular complications were fairly common among the diabetics, symptoms from the brain, heart, or lower extremities being present in nine. Similar symptoms were seen in five of the nondiabetics. In both groups, a systolic blood pressure exceeding 150 mm.Hg was recorded in more than half the patients, and a severe blood pressure increase (diastolic

Table Age and sex distribution of seventy patients with haemorrhagic glaucoma

Series		Diabetics	Nondiabetics
Age (yrs)	-29	5	3
	30-39	6	1
	40-49	3	1
	50-59	8	1
	60-69	5	10
	70-79	3	20
	80-89	-	4
	Total	30	40
Average		49.2 ± 2.3	66.9 ± 2.6
Sex	Male	12	29
	Female	18	11
	Total	30	40

pressure exceeding 100 mm.Hg) was observed in 13 per cent. of the diabetics and 15 per cent. of the nondiabetics. Proteinuria was present in seventeen of the diabetics, but only in one patient without diabetes.

Diabetic group

Of the thirty diabetics, 29 were long-term diabetics, and 24 had proliferative retinopathy in one or both eyes. Serum creatinine was studied in 24 diabetics and in four the levels exceeded 1.5 mg. per cent.

Central vein thrombosis was observed in six of the diabetics, including four with proliferative retinopathy. The appearance of the central vein thrombosis in these six diabetics did not differ from that seen in the 26 nondiabetic patients.

Ocular changes

The haemorrhagic glaucoma showed the same clinical picture and course in both diabetics and nondiabetics.

During the period of observation bilateral haemorrhagic glaucoma occurred in six diabetics, but in only one nondiabetic with central vein thrombosis.

Intraocular pressure

In most patients in the two groups the pressure was within the range from 45 to 50 mm.Hg, but pressures about 30 mm.Hg were also recorded in both groups.

The mean values were 47.0 ± 2.2 mm.Hg (30 diabetics) and 49.6 ± 1.6 mm.Hg (40 nondiabetics).

It should be noted that there was no correlation between the level of the intraocular pressure and subjective discomfort. Some patients showed relatively low pressures and had fairly intense pain, while others had only slight discomfort although the pressure was extremely high. In some of the diabetics, who were examined at intervals of a few weeks

or months, it was observed that the increase in intraocular pressure occurred gradually in step with the development of abnormal vessels on the anterior iris surface and in the chamber angle.

It is worthy of note that pain developed in two diabetics while the pressure was still very low (approx. 10 mm.Hg).

Visual acuity

Almost complete loss of vision occurred in nearly all the eyes with haemorrhagic glaucoma.

Only in one case was vision preserved. The patient was a woman aged 44 with bilateral haemorrhagic glaucoma after central vein thrombosis. The intraocular pressure returned to normal after operation, and on discharge she could count fingers at 1 m. with the right eye, the visual acuity of the left eye being 0.4.

Simple glaucoma

There was a distinct difference between diabetics and nondiabetics. None of the diabetics had, or had had, simple glaucoma, but it was found in 42 per cent. of the nondiabetics. In patients with proliferative diabetic retinopathy, the intraocular pressure is usually low. In nine out of twelve hypotonic eyes with intraocular pressures of 10 mm.Hg or less, in which haemorrhagic glaucoma of either sudden or more gradual onset subsequently occurred, rubeosis iridis was observed.

Rubeosis iridis

In nearly all eyes with haemorrhagic glaucoma, distinct rubeosis iridis was observed, with dilated vessels involving the entire anterior iris surface, both centrally and peripherally. The vessels were of the same appearance in the two groups.

When the patient was admitted to hospital, the pupil was usually small, but it became dilated in the course of the disease, and uveal ectropion then very often occurred.

Pigment deposits were occasionally observed on the posterior surface of the cornea, sometimes accompanied by aqueous flare. Occurrence of synechiae between the iris and lens was a frequent finding, equally common in the two groups. The depth of the chamber was normal in nearly all cases.

In eighteen eyes in sixteen patients, previously examined, rubeosis occurred before the development of haemorrhagic glaucoma. Fourteen of the patients had diabetes, one central vein thrombosis, and another arteriosclerosis. The time interval between the observation of rubeosis iridis and the occurrence of haemorrhagic glaucoma was more than 12 months in eleven of the eyes.

However, rubeosis iridis did not lead to glaucoma in all cases. *Nine diabetics* had at previous examinations revealed rubeosis iridis in eyes in which haemorrhagic glaucoma had not yet developed. In six of these eyes the rubeosis remained unchanged, for periods of from 2 to 6 years. In three eyes, rubeosis iridis was previously observed, but disappeared again. *One nondiabetic* with haemorrhagic glaucoma after central vein thrombosis had unchanged rubeosis iridis in the nonglaucomatous eye for a period of 4 years.

The patients considered here had primary rubeosis as defined by Ohrt (1967), *i.e.* rubeosis iridis occurs first and is then followed by haemorrhagic glaucoma after varying lengths of time.

In the present series, there was only one patient, a 68-year-old nondiabetic man with central vein thrombosis, who did not have rubeosis iridis when he was admitted to hospital

with haemorrhagic glaucoma. The rubeosis which later occurred in this patient must be regarded as secondary. Otherwise, it is very difficult to say when a rubeosis is of the secondary type, since this requires the patient to be under observation at the time of onset of haemorrhagic glaucoma.

Gonioscopy

In the eyes WITH haemorrhagic glaucoma the following gonioscopic observations were made at the first examination in the two groups:

<i>Observation</i>	<i>Diabetics</i>	<i>Nondiabetics</i>
Open angle with vessels	15	15
Closed angle (with vessels on the periphery of the iris)	7	8
Hyphaemia	4	3
Narrow angle	—	1
Open angle with synechiae	—	2
Could not be inspected	10	12
Total	36	41

Generally, it was not possible to find any difference in the chamber angle between diabetics and nondiabetics.

In the eyes WITHOUT haemorrhagic glaucoma, a normal open chamber angle was observed in most cases. Five diabetics had delicate vessels in the chamber angle at the first examination. In three of these, haemorrhagic glaucoma subsequently developed. Two nondiabetics with central vein thrombosis of the opposite eye had a narrow chamber angle, but the dilatation test did not reveal any increase in the intraocular pressure.

Treatment

Treatment of haemorrhagic glaucoma is an unrewarding task both in diabetics and nondiabetics. In nearly all cases, vision is lost, and the only objective of the treatment is to relieve the pain, which is often very intense. If the pain is intractable, enucleation of the eye is necessary.

In eighteen of the eyes, conservative treatment (pilocarpine, Diamox, and oral glycerine) or retrobulbar injection of alcohol resulted in subsidence of pain, so that further measures were unnecessary.

X ray irradiation, given in three cases, proved ineffective.

Primary enucleation of the eye was performed in two cases.

Fifty four eyes (24 in diabetics, thirty in nondiabetics) were subjected to some type of operation. The most common procedure was Preziosi's filtering operation with galvanocauterization (Merté, 1963). The postoperative course did not seem to differ in the two groups.

In spite of treatment, eleven eyes had to be removed. Histological examination showed the same changes in the anterior segment of the eye in diabetics and nondiabetics suffering from widely different diseases such as central vein thrombosis, arteriosclerosis without venous changes, retinal detachment, and dysplasia and melanoma of the choroid. Examples of the changes in the chamber angle are shown in Figs 1 to 3 (overleaf). Malignant melanoma was found in two of the eyes.

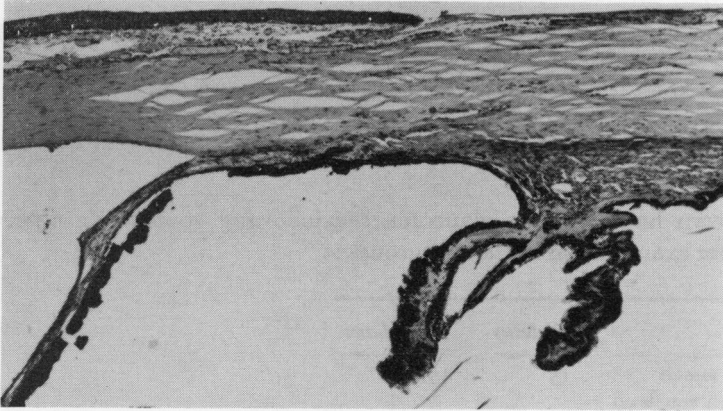


FIG. 1 *Obliterated chamber angle and atrophic iris and ciliary body in a 72-year-old man with central vein thrombosis*

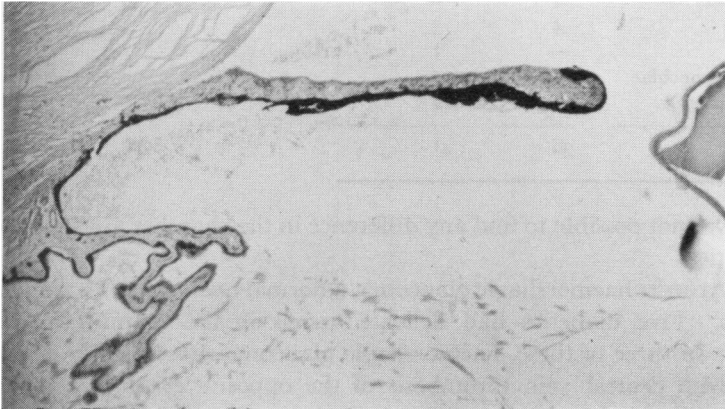


FIG. 2 *Anterior chamber in a 30-year-old woman with diabetes of 19 years duration*

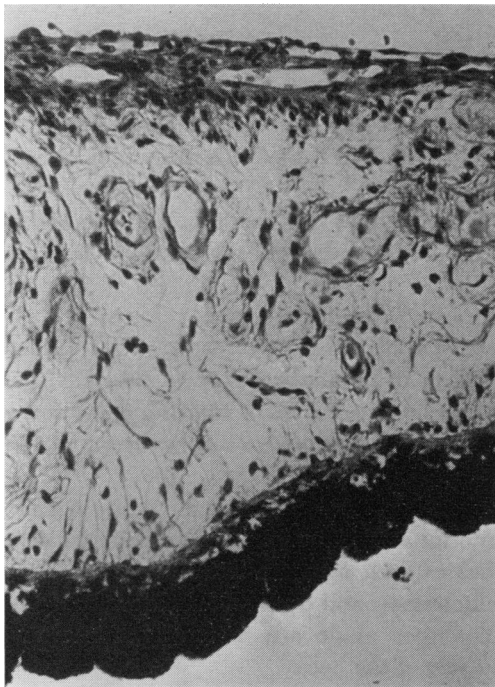


FIG. 3 *Rubeosis of the iris in a 18-year-old youth with dysplasia and detachment of the retina*

Discussion

Haemorrhagic glaucomata of identical appearance may occur in patients with widely different basic diseases. In the present study of seventy patients with haemorrhagic glaucoma admitted to an eye department during a 5-year period, there was no difference in the appearance and course of the disease in thirty diabetics and forty nondiabetics.

Special attention was paid to the changes in the anterior segment of the eye in order to disclose any possible difference between the diabetic and nondiabetic patients, but no such difference was found. Rubeosis of the iris and neovascularisation in the chamber angle are crucial features in haemorrhagic glaucoma, whether in cases of diabetes, thrombosis of the central retinal vein, or arterial occlusion. The present study showed no difference in the appearance of the vessels in the iris and chamber angle in the patients who suffered from these different diseases.

There is some difference of opinion about the type of rubeosis seen in patients with diabetes and central vein thrombosis. A few authors (François, 1955; Mylius, 1961) have distinguished between diabetic rubeosis of the iris, which was regarded as true neovascularization, as distinct from rubeosis-like vessels in central vein thrombosis which were regarded as pre-existing.

Most other authors have found no difference between the rubeosis which occurs in association with diabetes and that which follows central vein thrombosis (Sugar, 1942; Holm, 1945; Bonnet, 1949; Braendstrup, 1950; Krüger, 1961; Becker and Shaffer, 1965; Ohrt, 1967). Furthermore Wise (1956), Cucco (1961), Kadlecová (1966), and Schulze (1967) did not regard rubeosis iridis as a symptom of any specific disease, but as a sequela of a severe, long-continued vascular occlusion leading to tissue hypoxia and anoxia. Experimental occlusion of the long ciliary arteries in cats resulted in rubeosis of the iris (Schulze, 1967).

Besides the presence of rubeosis iridis and neovascularization in the chamber angle, most of the patients, both diabetics and nondiabetics, showed vascular changes in the form of retinal arteriosclerosis and, often, also venous congestion. This might support the theory that hypoxia is a causative factor in the development of rubeosis of the iris and haemorrhagic glaucoma.

Summary

A series of seventy patients with haemorrhagic glaucoma (30 diabetics and 40 nondiabetics) was studied. Among the nondiabetics, 26 had recognized thrombosis of the central retinal vein. The average ages of the diabetics and nondiabetics were 49 and 67 years, respectively. 57 per cent. of the diabetics had proteinuria, but this abnormality was present in only one nondiabetic patient.

The clinical course of the haemorrhagic glaucoma was identical in the two groups of patients. In most cases, the intraocular pressure was about 45–50 mm.Hg. Six diabetics and one patient with thrombosis of the central retinal vein had bilateral haemorrhagic glaucoma, whereas the glaucoma was unilateral in the remaining 63 patients.

Simple glaucoma did not occur among the diabetics, but was observed in about 40 per cent. of the nondiabetics.

Rubeosis iridis and vascular changes in the chamber angle were seen before or simultaneously with the onset of haemorrhagic glaucoma in 69 of the patients, whereas secondary rubeosis was encountered in only one case, *viz.* a nondiabetic patient with central vein thrombosis.

There was no difference in the clinical appearance of the anterior chamber in the patients of the two groups; it is noteworthy that the changes in the iris vessels in the diabetics as compared with those in the nondiabetic patients showed no particular characteristics.

References

- BECKER, B., and SHAFFER, R. N. (1965) "Diagnosis and Therapy of the Glaucomas", 2nd. ed., p. 208. Mosby, Saint Louis
- BONNET, P. (1949) *Ophthalmologica (Basel)*, **118**, 575
- BRAENDSTRUP, P. (1950) "Central retinal vein thrombosis and hemorrhagic glaucoma". *Acta ophthal. (Kbh.)*, Suppl. 35
- CUCCO, G. (1961) In "I Congr. Soc. europ. Ophtal., Athènes, 1960: Le glaucome secondaire", ed. J. François, p. 597. *Ophthalmologica (Basel)*, **142**, Supplement
- FRANÇOIS, J. (1955) *Progr. Ophtal.*, **4**, 19
- HOLM, E. (1945) *Acta ophthal. (Kbh.)*, **23**, 343
- KADELCOVÁ, V. (1966) *Čs. Oftal.*, **22**, 40
- KRÜGER, K. E. (1961) In "I Congr. Soc. europ. Ophtal., Athènes, 1960: Le glaucome secondaire", ed. J. François, p. 604. *Ophthalmologica (Basel)*, **142**, Supplement
- MERTÉ, H. J. (1963) *Klin. Mbl. Augenheilk.*, **142**, 548
- MYLIUS, K. (1961) In "I. Congr. Soc. europ. Ophtal., Athènes, 1960: Le glaucome secondaire", ed. J. François, p. 609. *Ophthalmologica (Basel)*, **142**, Supplement
- OHRT, V. (1967) "Diabetic Iridopathy", p. 83. Universitetsforlaget, Århus
- SCHULZE, R. R. (1967) *Amer. J. Ophthal.*, **63**, 487
- SUGAR, H. S. (1942) *Arch. Ophthal. (Chicago)*, **28**, 587
- WISE, G. N. (1956) *Trans. Amer. ophthal. Soc.*, **54**, 729