

# Conservative management of retinal breaks

## A follow-up study of subsequent retinal detachment

E. NEUMANN AND S. HYAMS

*From the Eye Department of the Rothschild Municipal-Government Hospital, and the Abba Khoushy Medical School, Haifa, Israel*

The following report presents the results of a 1 to 6 year follow-up study of 153 untreated retinal breaks in 108 eyes, with regard to the development of retinal detachment. This is the first series with a water-tight follow-up. Most of the breaks under study were dangerous according to the accepted criteria.

A review of the literature reveals only isolated cases in which a long-standing retinal break has led to the development of a retinal detachment. The present paper emphasizes the role of fresh, as opposed to old, breaks in the pathogenesis of retinal detachment.

### Material and methods

All cases of full-thickness retinal breaks seen at the Rothschild Municipal-Government Hospital, Haifa, between July, 1965, and July, 1970, are included in the study: there were 179 breaks in 127 eyes of 121 patients.

In nineteen eyes, there were 26 breaks which were treated by various methods for one of the following reasons: presence of glaucoma (3 eyes); myopia, aphakia with vitreous loss (3 eyes); subluxation of the lens (1 eye); because the patient insisted on being treated (4 eyes); large, fresh hole with vitreous haemorrhage (4 eyes); giant hole in an only eye (2 eyes); multiple retinal breaks in more than one quadrant (2 eyes).

In 108 eyes of 102 patients there were 153 breaks which received no treatment. These 108 eyes had been examined because the fellow eye had a retinal detachment (20 eyes, 9 of them myopic), because the patient complained of recent photopsies and/or entopsies (25 eyes, 15 of them myopic), or because of vitreous haemorrhage (3 eyes). In sixty eyes retinal breaks were discovered on routine examination (myopia in 45 eyes, aphakia in 8 eyes, myopia-aphakia in 6 eyes).

Of the patients with untreated retinal breaks 55 were males and 47 were females. The age of the 102 patients is shown in Table I. The size and shape of the 153 untreated retinal breaks are shown in Table II.

Fig. 1 shows the distribution of the 46 horseshoe breaks and Fig. 2 shows the distribution of the 107 round breaks; 31 of the horseshoe breaks and 51 of the round breaks were equatorial\*

Received for publication August 13, 1971

Address for reprints: Dr. E. Neumann, M.D., Eye Department, Rothschild Hospital, Haifa, Israel

Much of the material in this paper was presented at the Jerusalem Seminar on the Prevention of Blindness (II Conference of the International Society of Geographical Ophthalmology) on August 23 and 24, 1971

\*According to Rutnin (1967), the peripheral retina extends from the middle of the pars plana backwards to a distance of 6 disc diameters from the ora serrata. It consists of an oral region and an equatorial region, separated by a line 2 disc diameters posterior and parallel to the ora serrata

**Table I** Age of 102 patients with untreated retinal breaks

Age (yrs)	No. of cases
Less than 31	7
31 to 40	15
41 to 50	25
51 to 60	31
61 to 70	19
Over 70	5
Total	102

**Table II** Size and shape of 153 untreated retinal breaks

Size (disc diameter)	Break	
	Horseshoe	Round
Up to $\frac{1}{4}$	14	88
$\frac{1}{4}$ to $\frac{1}{2}$	12	13
$\frac{1}{2}$ to 1	11	4
More than 1	9	2
Total	46	107

**Table III** Follow-up period for 108 eyes with untreated retinal breaks

Follow-up (yrs)	No. of eyes
1-2	25
2-3	28
3-4	27
4-5	23
5-6	5
Total	108

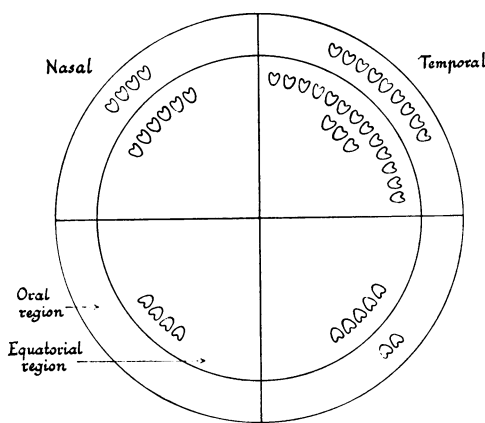


FIG. 1 Distribution of 46 untreated horseshoe retinal breaks

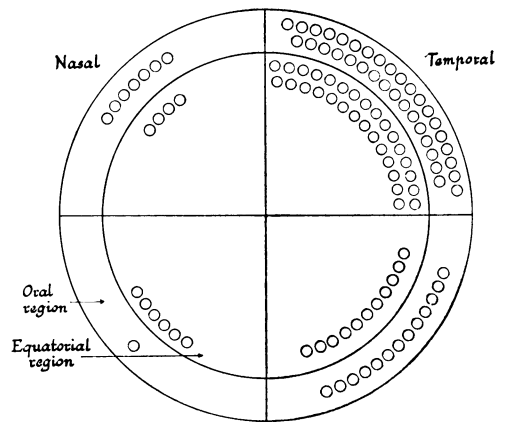


FIG. 2 Distribution of 107 untreated round retinal breaks

Some patients were told that they had a retinal condition which did not require treatment and others were not informed of their condition. Patients with fresh retinal breaks, as evidenced by haemorrhage in the retina or vitreous, were advised to refrain from reading and physical work for 3 to 6 weeks. In cases with severe vitreous haemorrhage, the patient remained in bed until an exact fundus examination could be made.

In June, 1970, a list of all patients with untreated retinal breaks was checked by the organizing secretary of the Israel National Study in the Prevention of Retinal Detachment (Michaelson, Stein, Felsenthal, Hauer, Ivry, Kallner, Kurz, Sachs, and Sinai, 1962, 1966) to see if any of them had been treated or had developed a detachment without our knowledge.

Table III shows the follow-up period for the 108 eyes with untreated retinal breaks. The average follow-up was 37 months.

**Results**

Three of the 108 eyes with untreated retinal breaks developed a detachment (Cases 1 to 3 below). None of the remaining 105 eyes had been treated or had developed a detachment at the time of writing in June, 1971.

### Case reports

**Case 1, a 43-year-old woman**, came for examination because some disinfectant had splashed into the left eye. The visual acuity in the affected eye was 6/15 with correction of  $-15$  D. There was minimal injection of the conjunctiva, and fundus examination revealed a giant horseshoe tear occupying the whole of the lower nasal quadrant. The posterior vitreous face was attached to the operculum of the tear. 6 weeks later there was a detachment of the lower half of the retina. A total buckle operation was performed with restoration of 6/15 vision.

**Case 2, a 62-year-old man**, had noticed blurred vision earlier the same day. In the right eye the visual acuity was 6/6 with correction  $-0.75$  D. There was a slight, diffuse, vitreous haemorrhage and three horseshoe tears at the equator in the upper temporal quadrant. The largest tear was slightly larger than 1 disc diameter and the smallest tear  $1/3$  of a disc diameter. 5 days later there was a retinal detachment in the upper temporal quadrant, extending 2 disc diameters central to the tears. A lamellar scleral resection was performed with re-attachment of the retina.

**Case 3, a 63-year-old man**, presented with a dense vitreous haemorrhage in the left eye. 2 weeks after the onset of symptoms the vitreous was sufficiently clear to enable two large horseshoe breaks to be seen in the upper nasal quadrant. The central edge of each break reached the equator and the vitreous was attached to each operculum. The patient remained in bed, but 1 week later there was a detachment of the nasal half of the retina. A total buckle operation was performed with re-attachment of the retina. The final visual acuity was 6/9 with correction  $-4.5$  D.

### Discussion

The prophylactic treatment of retinal breaks is based upon a premise that at least the more dangerous-looking breaks may cause a detachment, irrespective of the age of the break at the time of its discovery. A chorioretinal scar is easily produced by photocoagulation or cryopexy, and the treated eye is assumed to have been cured of a dangerous condition. Unfortunately, no reports concerning the prophylactic treatment of retinal breaks have contained an adequate control series.

The failure and complication rate of preventive treatment is as high as 5 per cent. in some series (Colyear and Pischel, 1960; Meyer-Schwickerath, 1963; Söllner, 1964; Mortimer, 1966; Merin, Feiler, Hyams, Ivry, Krakowski, Landau, Maythar, Michaelson, Scharf, Schul, and Ser, 1971). Furthermore, the most dangerous-looking breaks are not amenable to treatment by photocoagulation or simple cryopexy, but require more extensive surgery with the concomitant higher risk of complications.

The literature on the fate of untreated retinal breaks is sparse and often fails to distinguish between fresh and old breaks: Gonin (1934) reported an eye with a retinal break which did not cause a detachment during the 3 years it was under observation. Knapp (1943) reported five cases of retinal breaks with a follow-up period of 3 months to 7 years. One eye developed a detachment 6 months after diagnosis of the retinal break.

Vogt (1943) studied three eyes with retinal detachment which occurred 1 to 4 years after trauma to the eye. He assumed that a retinal break has occurred at the time of the trauma, although he did not see any of the patients until they presented with their detachment. Granström (1943) reported an eye with a retinal break which developed a detachment 1 year later, following trauma.

Sédan-Bauby (1950) observed a retinal break without detachment for 3 years. A retinal detachment occurred after diathermy of the break.

Colyear and Pischel (1956) studied 26 eyes with retinal breaks: eleven eyes were treated and fifteen eyes, twelve of them with vitreous haemorrhage, were not treated. Five of

the fifteen untreated eyes developed a retinal detachment during a follow-up period of 9 to 99 months, but in no case was the detachment caused by an old retinal break. In three of these five eyes the detachment occurred 5 to 13 days after the discovery of a fresh break. In one eye (Case 11), a pigmented retinal break was observed for 2½ years, but the detachment which eventually occurred was associated with the formation of three fresh breaks near the old one. The fifth eye (Case 12) was under observation because of a retinal vessel which was pulled into the vitreous near a choroidal focus in the upper temporal quadrant: no retinal break was visible. The patient presented with a fresh vitreous haemorrhage and a retinal detachment 2½ years later, and at surgery a hole was found near the choroidal focus.

Byer (1967, 1971) studied 270 retinal breaks with a follow-up period of up to 8 years. None of the breaks caused a detachment, but, as Byer pointed out, it was impossible to establish a water-tight follow-up. The author compared the prevalence of eyes with retinal breaks in the general population with the prevalence of retinal detachment as worked out by Böhringer (1956) and found a ratio of 83 : 1.

The prevalence of retinal breaks in various groups of eyes is between 2.4 and 19 per cent. (Okun, 1961; Halpern, 1966; Av-Shalom, Berson, Gombos, Landau, Michaelson, and Zauberman, 1967; Byer, 1967; Foos and Allen, 1967; Rutnin and Schepens, 1967; Hyams and Neumann, 1969; Merin and others, 1971), but none of these reports contains a follow-up study. Okun (1961) compared the prevalence of retinal breaks in *post mortem* eyes with Böhringer's figures for the prevalence of retinal detachment and found a ratio of 70 : 1.

In the present study, 153 retinal breaks in 108 eyes were followed up for a period of 1 to 6 years. Most of these breaks were dangerous according to generally accepted criteria: 26 breaks were larger than ½ disc diameter, 46 were horseshoes, 82 were equatorial, and all were in "high risk" eyes, such as fellow eyes, myopia, aphakia, and eyes with recent vitreous detachment or vitreous haemorrhage.

Only three eyes developed a detachment during the period of the study. In two cases a detachment occurred less than 3 weeks after the discovery of a fresh retinal break accompanied by vitreous haemorrhage, and in the third case the detachment occurred 6 weeks after the discovery of a horseshoe break occupying an entire quadrant. The follow-up with regard to retinal detachment is complete, because all cases of retinal detachment and all cases treated for detachment retinopathy in Israel are recorded centrally as part of the National Cooperative Study in the Prevention of Retinal Detachment (Michaelson and others, 1962, 1966). During the same period eleven eyes with retinal breaks were treated for reasons not connected with the nature of the break itself (presence of glaucoma, vitreous loss, subluxation of the lens, or the insistence of the patient). Eight additional cases were treated because of vitreous haemorrhage (4), a giant break in an only eye (2), and multiple breaks (2).

A study of the literature reveals only two fully-documented cases in which an old retinal break has caused a detachment. In one of these cases trauma was a precipitating factor. The present series adds one more case (Case 3). In view of the paucity of recorded evidence to the contrary, one must consider the possibility that the majority of detachments occur only a short time after the formation of a retinal break and that the "freshness" of a retinal break may be the decisive factor in determining the need for preventive treatment. The scale of present-day prophylactic treatment, with its occasional failures and complications, emphasizes the need for more information regarding the role of old, as opposed to fresh, retinal breaks in the aetiology of retinal detachments.

## Summary

153 untreated retinal breaks in 108 eyes were followed up for a period of 1 to 6 years. The majority of the breaks were dangerous according to the accepted criteria. Three eyes developed a retinal detachment: in two cases the detachment occurred within 3 weeks of the discovery of a fresh retinal break, and in the third case the detachment occurred 6 weeks after the discovery of a horseshoe break occupying an entire quadrant.

The literature contains only two fully-documented cases in which an old retinal break has caused a retinal detachment.

It is suggested that the "freshness" of a retinal break may be the decisive factor in determining the risk of development of retinal detachment. More information is needed concerning the role of old retinal breaks in the pathogenesis of this condition.

## References

- AV-SHALOM, A., BERSON, D., GOMBOS, G. M., LANDAU, L., MICHAELSON, I. C., and ZAUBERMAN, H. (1967) *Amer. J. Ophthalm.*, **64**, 387
- BÖHRINGER, H. R. (1956) *Ophthalmologica (Basel)*, **131**, 331
- BYER, N. E. (1967) *Trans. Amer. Acad. Ophthalm. Otolaryng.*, **71**, 461
- (1971) Personal communication
- COLYEAR, B. H., and PISCHEL, D. K. (1956) *Amer. J. Ophthalm.*, **41**, 773
- (1960) *Trans. Pacif. Cst oto.-ophthal. Soc.*, **41**, 193
- FOOS, R. Y., and ALLEN, R. A. (1967) *Amer. J. Ophthalm.*, **64**, 643
- GONIN, J. (1934) "Le décollement de la rétine: Pathogénie-traitement", p. 77. Payot, Lausanne, (Cited by Colyear and Pischel, 1956)
- GRANSTRÖM, K. O. (1944) *Acta ophthalm. (Kbh.)*, **21**, 204
- HALPERN, J. I. (1966) *Amer. J. Ophthalm.*, **62**, 99
- HYAMS, S. W., and NEUMANN, E. (1969) *Brit. J. Ophthalm.*, **53**, 300
- KNAPP, A. (1943) *Arch. Ophthalm. (Chicago)*, **30**, 585
- MERIN, S., FEILER, V., HYAMS, S., IVRY, M., KRAKOWSKI, D., LANDAU, L., MAYTHAR, B., MICHAELSON, I. C., SCHARF, J., SCHUL, A., and SER, I. (1971) *Amer. J. Ophthalm.*, **71**, 477
- MEYER-SCHWICKERATH, G. (1963) *Trans. Canad. ophthalm. Soc.*, **26**, 9
- MICHAELSON, I. C., STEIN, R., FELSENTHAL, W., HAUER, I., IVRY, M., KALLNER, G., KURZ, O., SACHS, R., and SINAI, E. (1962) "XIX Concilium Ophthalmologicum", vol. 2, p. 1356
- , ———, ———, ———, ———, ———, ———, ———, ———, ——— (1966) *Mod. Probl. Ophthalm.*, **4**, 135 (Bibliotheca Ophthalmologica, Fasc. 70)
- MORTIMER, C. B. (1966) *Canad. J. Ophthalm.*, **1**, 206
- OKUN, E. (1961) *Amer. J. Ophthalm.*, **51**, 369
- RUTNIN, U. (1967) *Ibid.*, **64**, 821
- and SCHEPENS, C. L. (1967) *Ibid.*, **64**, 1063
- SÉDAN-BAUBY, S. (1950) *Bull. Soc. franç. Ophthalm.*, **63**, 163
- SÖLLNER, F. (1964) *Ber. dtsh. ophthalm. Ges.*, **66**, 327
- VOGT, A. (1934) *Klin. Mbl. Augenheilk.*, **92**, 577