

Ocular features of hypothyroidism

R. S. MAHTO

Bath Eye Infirmary, Bath, Somerset

Hypothyroidism is due to deficient thyroid function; myxoedema is due to diminished thyroid function associated with solid oedema. Since hypothyroidism develops very gradually and not all cases exhibit solid oedema, diagnosis is very often missed. As the incidence of this condition is more common in females than males and the age at onset corresponds to that of the menopause, diagnosis is very often confused with the menopausal syndrome or symptoms attributable to old age.

Hypothyroidism may occur spontaneously in middle age or be associated with goitre, thyroidectomy, or radioactive iodine treatment.

Clinically, the ocular complications of hypothyroidism are loss of eyelashes and eye brows, especially on the temporal side, puffiness of eyelids (Gull, 1874), ocular irritation, corneal changes (Treacher Collins, 1907), and cataract (Goulden, 1928).

In the past 2 years, six patients with previously undiagnosed hypothyroidism presented at the Bath Eye Infirmary with various ocular complaints. Although on questioning they had other symptoms, such as sensitivity to cold, weakness, tiredness, muscular pain, loss of scalp hair, and dry skin, the patients had not sought advice about them but had accepted these symptoms as part of the change of life associated with the menopause or had regarded them as due to old age. It was only when ocular symptoms appeared that they sought medical advice.

Hypothyroidism was suspected from answers to further questions, ocular complications, facial features, slow pulse, and relatively low blood pressure.

Clinical diagnosis was confirmed by serum thyroxine iodine, free thyroxine index, cholesterol, and electrocardiogram. The ocular findings and results of laboratory investigations in these six patients are set out in the Table.

Case reports

Case 1, a 66-year-old woman, presented in June, 1970, complaining of loss of eyelashes for the past 6 months. Other symptoms were loss of scalp hair and eyebrows, a burning sensation in the eyes, excessive cold, and lassitude.

Examination

The visual acuity in each eye was 6/6, with correction. There was loss of eyelashes on both lower lids on the temporal side, and the eyebrows were also sparse (Fig. 1). There were wedge-shaped spokes of opacity in the right lens. The left lens was clear.

The skin was dry and there was no solid oedema. The scalp hair was thin and dry. The thyroid gland was palpable and firm with a slightly enlarged lateral lobe. The ankle jerk was normal.

Case 2, a 55-year-old woman, presented in July, 1970, with irritation in the left eye. She also complained of stiffness of the back.

Examination

The visual acuity in each eye was 6/5, with correction; there was proptosis more marked on the left. There were small bluish dots and flake-like opacities in the superficial cortex of both lenses.

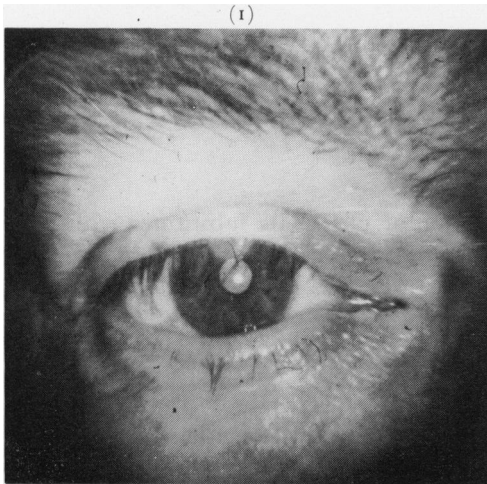
Table *Salient features of six cases*

| Case no. | | 1 | 2 | 3 | 4 | 5 | 6 |
|---------------------------------------------|---------------------------------------------------|-------------|--------|--------|---------|-----------------------------------|-------------|
| Ocular findings | Puffiness of eyelids | — | — | + | — | — | + |
| | Loss of eyelashes | + | — | — | + | — | — |
| | Loss of eyebrows | + | — | + | + | — | — |
| | Cataract | + | + | + | + | + | + |
| | Irritation of eyes | + | + | — | — | — | — |
| | Corneal changes | — | — | — | + | — | — |
| Laboratory investigations | Pulse rate/min. | 64 | 56 | 74 | 58 | 64 | 96 |
| | Blood pressure | 160/94 | 140/80 | 130/80 | 160/110 | 130/80 | 240/140 |
| | Hb per cent. | 76 | 95 | 89 | 102 | NR | 90 |
| | Cholesterol (mg./100 ml.) | 345 | 360 | 350 | 295 | 310 | 560 |
| | Serum thyroxine iodine ($\mu\text{g./100 ml.}$) | 2.7 | 1.4 | 1.7 | 1.6 | 1.3 | less than 1 |
| | Free thyroxine index ($\mu\text{g./100 ml.}$) | 3.2 | 1.4 | 1.1 | 1.2 | NR | less than 1 |
| Electrocardiogram | NR | Flat T wave | NR | NR | NR | Flat ST segment Enlarged heart | |
| Erythrocyte sedimentation rate (mm./1st hr) | 2 | 6 | 5 | 11 | NR | 65 | |

NR = Not recorded

She had had a thyroidectomy in 1961 for thyrotoxicosis. Her voice was deep and her skin was dry. There was no solid oedema. The deep tendon reflexes showed a delay in relaxation.

Case 3, a 52-year-old woman, presented in December, 1969, with swelling of the eyelids for the past 16 months. On questioning she admitted feeling very cold, weak and tired. She was a typist and her fingers used to get so tired that she was unable to work. Her mother had myxoedema.

FIG. 1 *Case 1. Right eye*FIG. 2 *Case 4. General appearance*

Examination

The visual acuity in each eye was 6/5 with correction. There was puffiness of both lids and cheeks. Brows and scalp hair were sparse. There were small bluish dots and flake-like opacities in the superficial cortex of each lens.

The skin was dry, the patient had muscular pain in her arms and thighs and there was solid oedema. There was a delay in relaxation of the deep tendon reflexes.

Case 4, a 60-year-old woman, came in April, 1971, for a routine check-up. She had had a thyroidectomy in 1967 for thyrotoxicosis and was so sensitive to cold that she needed a fire even in the summer.

Examination

The visual acuity was counting fingers at 1 metre in the right eye and 6/18 in the left. There was complete loss of eyelashes and brows, and she was wearing a wig to conceal extensive loss of hair (Fig. 2). The right eye was proptosed and divergent. There was long-standing iritis, epithelial oedema of the cornea, keratic precipitates, and advanced cataract in this eye. The left showed punctate corneal opacities.

The skin was coarse and dry and the ankle jerk was absent.

Case 5, a 61-year-old woman, came in February, 1970, for a routine check-up. She had first been seen in June, 1964, with poor vision due to bilateral cataracts which were removed in 1966 and 1968. On questioning she admitted to feeling excessively cold.

Examination

The visual acuity was 6/9 in the right eye and 6/60 in the left. Her poor vision in the left eye was due partly to pupillary block glaucoma after cataract operation.

She was moderately obese with puffiness of the eyelids and pallor.

Case 6, a 70-year-old woman, presented in September, 1970, with poor vision. She had been treated with radioactive iodine for thyrotoxicosis in 1962.

Examination

The visual acuity was 6/24 in the right eye and 6/60 in the left, the poor vision being due to cupuli-form cataract and nuclear sclerosis.

She looked myxoedematous and had coarse dry hair.

Treatment

All patients were treated with thyroxine or one of its substitutes with the exception of Case 6. This patient had high blood pressure together with hypothyroidism, and it was thought that myxoedema would have a protective action on the heart against very high blood pressure.

Discussion

The incidence of hypothyroidism is more common in females than in males—about 4:1 (Meadows, 1963). In the present series all six patients were females above the age of 50 years.

Loss of eyelashes was the presenting symptom in Case 1, a woman aged 66 who was worried about her cosmetic appearance. She has now received thyroxine treatment for a year but her eyelashes are still stunted and sparse, suggesting a permanent degeneration of

most of the eyelash follicles. Case 4 had extensive loss of eyelashes, which was suggestive of hypothyroidism. According to Ord (1878), the root-sheaths of the hair show narrowing and irregular protrusions, possibly due to constriction, so that the follicles degenerate and the hair falls out.

Puffiness of eyelids as a complication of myxoedema, first described by Gull (1874), is due to deposition of myxoedematous tissue in the lid. This was the presenting symptom in Case 3, and it disappeared after treatment with thyroxine. In Case 5 this was one of hypothyroid the signs which first led to suspicion of myxoedema.

Cataract as a complication of hypothyroidism was described by Goulden (1928). In this series two patients presented with poor vision due to cataract. Case 5 was 54 years old when she developed a nearly mature cataract, and as this was a relatively early age hypothyroidism was later considered to be a causative factor. Case 6 had cupuliform cataract and nuclear sclerosis at the age of 70 years. These were considered to be senile changes possibly enhanced by hypothyroidism. Cases 2 and 3 had small bluish dots and flake-like opacities in the superficial cortex of the lens. Goulden (1928) mentioned only bluish dots and not flake-like opacities. Case 4 had complicated cataract in the right eye due to long-standing anterior uveitis and white punctate opacities in the superficial cortex of the left eye, unrelated to hypothyroidism. Irritation in the left eye was the presenting symptom in Case 2, and a burning sensation was a secondary complaint in Case 1. The results of Schirmer's test in Case 2 were right eye 20 mm. and left eye 5 mm. This irritation was not relieved by thyroxine but responded well to Hypromellose drops. Possibly deposition of myxoedematous tissue in and around the lacrimal and accessory lacrimal gland causes degeneration of these glands and loss of tears.

Corneal changes were first described by Treacher Collins (1907) as small discrete globular-looking spots in the central portion of the cornea in its anterior layer. In the present series Case 4 had epithelial oedema and degenerative changes in the endothelium of the right eye. This eye had chronic uveitis of 15 years' duration. These changes were degenerative in nature and unrelated to hypothyroidism.

Bilateral retrobulbar neuritis and optic atrophy were described by Fournier and Helguera (1934). In the present series these complications were not observed.

Summary

Six cases of hypothyroidism with ocular complications were described. They were all women above the age of 50 years. Their symptoms were puffiness of eyelids, loss of eyelashes, ocular irritation, and poor vision due to cataract. One patient had marked high blood pressure as well as hypothyroidism and cataract.

I should like to thank Mr. Quinn, Mr. Kelly, and Mr. Jones for allowing me to study and publish these cases, and my wife Janet for her help in preparing this paper.

References

- COLLINS, E. TREACHER (1907) *Trans. ophthal. Soc. U.K.*, **27**, 47
GOULDEN, C. (1928) *Trans. ophthal. Soc. U.K.*, **48**, 97
MEADOWS, S. P. (1963) 'Endocrine Disorders', in 'Modern Ophthalmology', ed. A. Sorsby, vol. 2, pp. 337-366. Butterworth, London
MUSSIO FOURNIER, J. C., and LAROSSA HELGUERA, R. A. (1934) *Endocrinology*, **18**, 527
GOULDEN, C. (1928) *Trans. ophthal. Soc. U.K.*, **48**, 97
GULL, W. W. (1874) *Trans. clin. Soc. Lond.*, **7**, 180
ORD, W. M. (1878) *Med.-chir. Trans.*, **61**, 57