

# Sinus trabeculectomy

## Preliminary results of 100 operations

A. P. NESTEROV, N. V. FEDEROVA, AND Y. E. BATMANOV

*Department of Ophthalmology, Kazan Medical Institute, Kazan, USSR*

During the last few years several techniques of trabeculectomy have been described. The first was developed by Cairns (1968, 1969). After conjunctival incision a lamellar scleral flap was prepared, under which an incision was made into the deep scleral layers at the level of the scleral spur. Through the incision a portion of the trabecular meshwork with the underlying canal of Schlemm is excised, and the scleral and conjunctival flaps are then replaced and sutured. The operations by Krasnov and Kolesnikova (1969) and by Linnér (1969) are based on a similar principle. Watson (1969) preferred to make the incision of the deep layers of the sclera just behind the scleral spur which had to be previously identified.

The basic idea of these operations is very attractive. After the operations the aqueous humour flows through the internal fistula directly into Schlemm's canal; this prevents the trabecular obstruction from affecting the facility of aqueous outflow and the blockade of Schlemm's canal by its inner wall.

However, the operative technique seems to be very complicated. It is not easy to identify the position of the scleral spur in every case. It is often difficult and sometimes even impossible to excise the trabecular meshwork properly when making the incision of the deep scleral lamella through the scleral spur. The scleral spur is known to be situated beneath the posterior portion of Schlemm's canal. When performing the incision along the line of the scleral spur, one divides Schlemm's canal and the trabeculae into anterior and posterior portions. Only the anterior portion of the canal and trabecular meshwork can then be excised. Moreover, in many cases, especially in eyes with closed-angle glaucoma, Schlemm's canal is situated posteriorly, so that much of it lies behind the anterior border of the ciliary body (Fig. 1, overleaf). In such cases the aperture in the inner wall of Schlemm's canal is possibly too small for the intraocular pressure to be controlled. In glaucomatous eyes obliteration of the anterior portion of Schlemm's canal occurs earlier than that of the posterior portion. It thus seems to be more important to excise the posterior rather than the anterior portion of the meshwork.

There is another reason against the wide use of trabeculectomy for treating glaucomatous eyes. It has been shown that in advanced glaucoma Schlemm's canal may be obliterated (Duke-Elder, 1969). In such cases the "pure" trabeculectomy seems to be a useless procedure.

To simplify the operative technique and to increase its reliability, two modifications were developed (Nesterov, 1971). The first was called "simple sinus trabeculectomy" and the second "filtering sinus trabeculectomy". A description of the techniques and a report of the results in 100 eyes of 97 patients form the subject of the present paper.

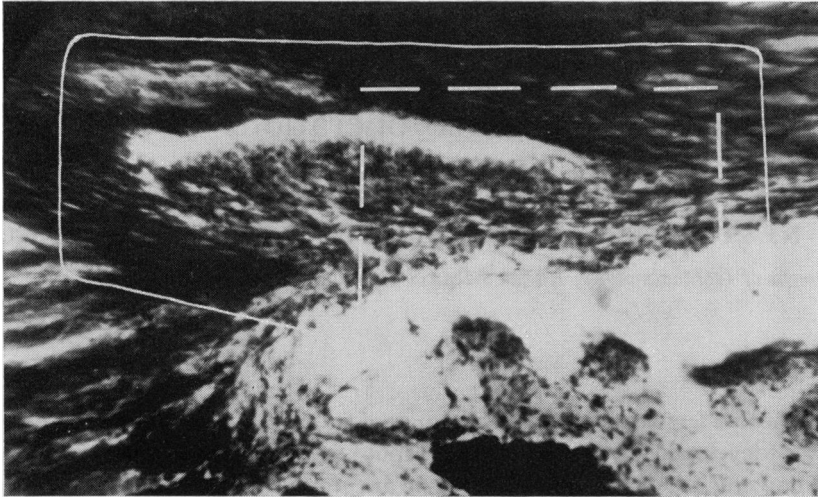


FIG. 1 Broken line indicates portions of Schlemm's canal and trabeculae which are excised if the conventional trabeculectomy technique is used. Solid line indicates corneal scleral area which is removed by the new technique

## Technique

### *Simple sinus trabeculectomy*

Anaesthesia and akinesia are obtained in the usual fashion using novocain. The operating microscope was employed in most cases, but the procedure can be carried out without any magnification. An 8 mm. conjunctival-tenon flap is prepared. A limbal-based scleral flap is marked out. The flap is 5 to 6 mm. long and 5 mm. wide. It is laminated at the level of about one-half of the thickness of the sclera. Two or three pre-placed sutures are inserted (Fig. 2*a*).

The cornea at the temporal side of the horizontal meridian is punctured by a narrow knife moistened with a 1 per cent. solution of fluorescein.

A 5 mm. incision is then made through the deep layers of the sclera 3 mm. behind the limbus. The incision is gradually deepened until it reaches the ciliary body (Fig. 2*b*). At the length of 4 to 5 mm. cyclodialysis is performed with a spatula (Fig. 2*c*). A piece of deep scleral lamella measuring 5 × 3 mm. is excised with corneal scissors (Fig. 2*d*); this contains the deep scleral layers, the canal of Schlemm, the scleral spur, and the trabecular meshwork throughout their whole diameters.

Peripheral iridectomy is then performed. If hyphaema appears it is removed by washing out the anterior chamber with saline. For this purpose a thin needle connected to a syringe filled with saline is introduced into the anterior chamber through the puncture at the temporal side of the cornea. The external scleral flap is replaced and the preplaced sutures are tied. The conjunctival-tenon incision is next closed by an uninterrupted suture (Fig. 2*e*). The anterior chamber is restored with saline or air injected through the corneal puncture.

### *Filtering sinus trabeculectomy*

The procedure is the same as has been described above, but a small portion of the external scleral flap is excised before the conjunctival-tenon incision is closed. This portion has a triangular shape measuring 1 to 1.5 mm. on each side. It is more convenient for the surgeon to excise this from the right side of the flap just behind the limbus. The conjunctival flap is then sutured (Fig. 2*f*). Air is injected into the anterior chamber through the corneal puncture. Some of the air usually passes through the scleral aperture beneath the conjunctival flap. This procedure has three aims: restoration of the anterior chamber, removal of blood from the scleral aperture, and separation of the conjunctival-tenon flap from the sclera.

Penicillin and hydrocortisone solutions are injected beneath the conjunctiva and Syntomyacin ointment and 1 per cent. atropine solution are instilled.

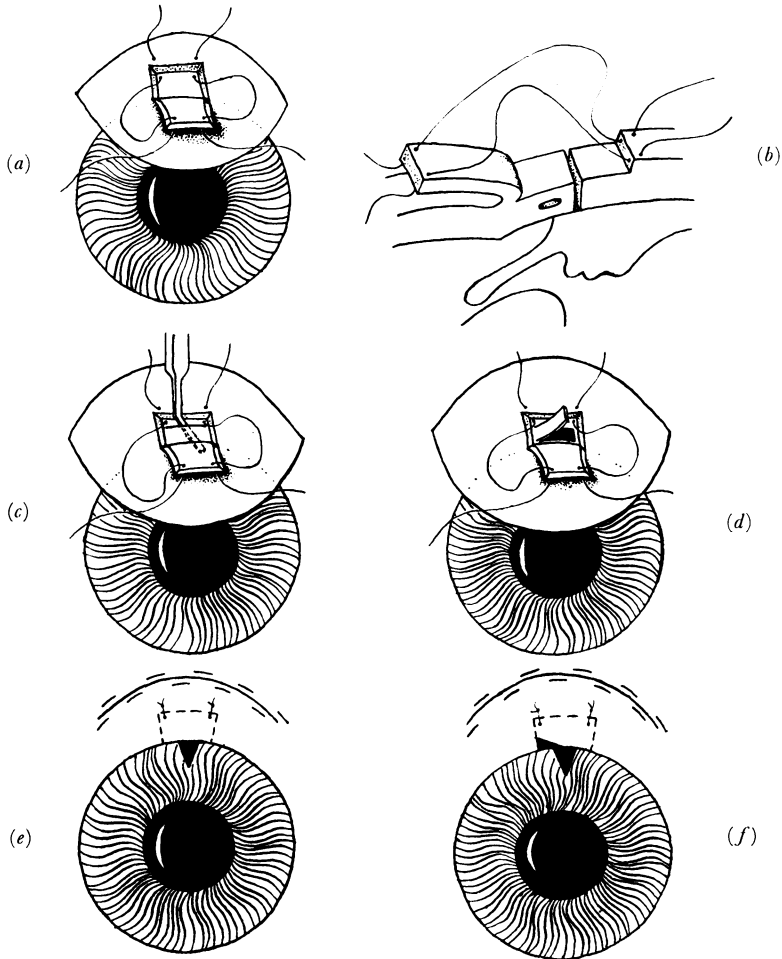


FIG. 2 (a-f) *Technique of sinus trabeculectomy. For explanation see text*

## Results

### *Simple sinus trabeculectomy*

The operation was performed in 25 eyes of 24 patients. Sixteen of the eyes had chronic simple glaucoma, and five secondary glaucoma. The last group included two eyes with traumatic recession of the anterior chamber angle and three cases of aphakic glaucoma.

Four eyes had histories of unsuccessful glaucoma surgery. In fifteen cases the operation was performed in the upper segment of the eye and in ten in the lower segment.

No serious complications were observed during and after the operation. The eyes routinely remained very quiet. Hyphaema appeared in four cases and mild iridocyclitis occurred in four. There was no case of choroidal detachment, hypotony, or persistent flat anterior chamber after this operation.

The results 3 to 4 weeks after surgery are given in Table I. In all but two cases (92 per cent.) the intraocular pressure was controlled by surgery alone. The mean intraocular pressure and facility of aqueous outflow are shown in Table II.

**Table I** Results of sinus trabeculectomy in control of pressure

Techniques	No. of eyes in which pressure was controlled			
	(a) by surgery alone		(b) by surgery + miotics	
	No.	Per cent.	No.	Per cent.
Simple sinus trabeculectomy	23	92	2	8
Filtering sinus trabeculectomy	73	97	2	3
Total	96	96	4	4

**Table II** Intraocular pressure and aqueous outflow facility before and in 3 to 4 weeks after surgery

Technique	IOP (mm.Hg)				C-values (mm. <sup>3</sup> /min./mm. Hg)			
	No.	Mean	S.D.	Range	No.	Mean	S.D.	Range
Simple sinus trabeculectomy								
(a) before surgery	25	38.95	6.12	29-52	23	0.086	0.042	0.02-0.16
(b) after surgery	25	13.20	3.84	7-26	18	0.295	0.096	0.14-0.44
Filtering sinus trabeculectomy								
(a) before surgery	75	46.26	11.92	29-83	71	0.064	0.038	0.01-0.13
(b) after surgery	75	12.53	3.72	6-22	47	0.302	0.100	0.12-0.60

In each case the intraocular pressure was measured twice a day for 4 to 5 successive days with the Maklakov tonometer both before and after surgery. The pressure was considered to be controlled if it was always less than 21 mm. Hg. The average value of the intraocular pressure for each eye was calculated, and the results are given in Table II.

Flat filtering blebs appeared in five eyes (20 per cent.). Gonioscopy showed an aperture in the trabecular band and the groove behind it. It was often possible to observe that the canal of Schlemm opened into the groove.

#### *Filtering sinus trabeculectomy*

The operation was performed in 75 eyes of 73 patients; 51 had chronic simple glaucoma, 19 chronic angle-closure glaucoma, and five secondary glaucoma.

The last group included four cases of uveal glaucoma and one of traumatic glaucoma.

Two eyes had histories of unsuccessful glaucoma surgery. In 72 cases surgery was performed in the upper segment of the eye and in three in the lower segment.

The results 3 to 4 weeks after the operation are summarized in Tables I and II. In all eyes but two (97 per cent.) the intraocular pressure was controlled by surgery alone. In seven cases the filtering bleb did not appear, but in five of these both the intraocular pressure and the C-value were normal. The most common complication was hyphaema, which occurred in twelve cases (16 per cent.). Choroidal detachment was observed in three eyes (4 per cent.) and mild iridocyclitis in nine (12 per cent.). Flat chamber was observed in only one eye; this occurred on the seventh day after surgery and was combined

with choroidal detachment, but the anterior chamber reformed after posterior sclerectomy. Hypotony occurred in eight eyes (11 per cent.); in these cases the intraocular pressure was about 7 to 9 mm. Hg. In all of these eyes there were no signs of irritation and the visual function was stable. A complicated cataract developed in one eye and the vision was reduced from 0.6 to 0.1.

#### *Follow-up*

Prolonged follow-up was rather difficult in many of our patients as most of them were country dwellers, but 59 patients were examined 3 to 12 months after surgery (Table III). 54 eyes (91.5 per cent.) had good results, with normal intraocular pressure without miotics (8–19 mm. Hg) and a normal C-value (0.12–0.48 mm.<sup>3</sup>/min./mm. Hg).

**Table III** *Duration of observation of 59 eyes*

<i>Duration of observation (mths)</i>	<i>Technique</i>		
	<i>Simple</i>	<i>Filtering</i>	<i>Both</i>
(1) Longer than 3, less than 6	3	10	13
(2) Longer than 6, less than 9	5	9	14
(3) Longer than 9, less than 12	6	26	32

An increase in the intraocular pressure occurred in one single eye 3 months after the simple sinus trabeculectomy had been performed, and in one eye after the filtering sinus trabeculectomy. The intraocular pressure was controlled with pilocarpine and epinephrine drops. Hypotony occurred in three eyes examined 9 to 12 months after filtering sinus trabeculectomy had been performed. Although the intraocular pressure was low (6–7 mm. Hg), there were no signs of irritation of the eyeball, retinal oedema, or cataract formation. In one eye anterior uveitis developed 5 months after the filtering sinus trabeculectomy had been performed, and this was cured with the help of antibiotics.

#### **Discussion**

The technique of sinus trabeculectomy described above includes some features of the sclerectomy reported by Nakajima, Kanki and Takayama (1961) and of the trabeculectomy reported by Cairns (1968) and Watson (1969). However, the new techniques appear to have some advantages. They are very simple and can be easily performed by any surgeon with or without the operating microscope. There is no need to identify the canal of Schlemm and the scleral spur, and it is almost impossible not to excise the canal of Schlemm and the trabecular meshwork properly. We examined histologically eighty scleral pieces which had been excised during surgery, and found the canal of Schlemm and the trabeculae throughout their whole diameter in each piece (Figs 3 and 4, overleaf).

The rate of complications was low. A good control of the intraocular pressure was obtained without miotics in 96 per cent. of all the cases 3 to 4 weeks after surgery. In 3 to 12 months after surgery the intraocular pressure had increased in only two cases (3.4 per cent.) of the 59 examined. The new techniques thus seem to be extremely efficient, but a longer period of observation is necessary before final conclusions can be reached.

After successful simple sinus trabeculectomy the aqueous humour seems to flow through the aperture in the trabecular meshwork into Schlemm's canal and its outlets. The




FIG. 3 *A case of chronic simple glaucoma. The piece of corneo-scleral tissue removed contains the canal of Schlemm, the scleral spur, and the trabecular meshwork throughout their whole diameters. Van Gieson stain  $\times 42$*

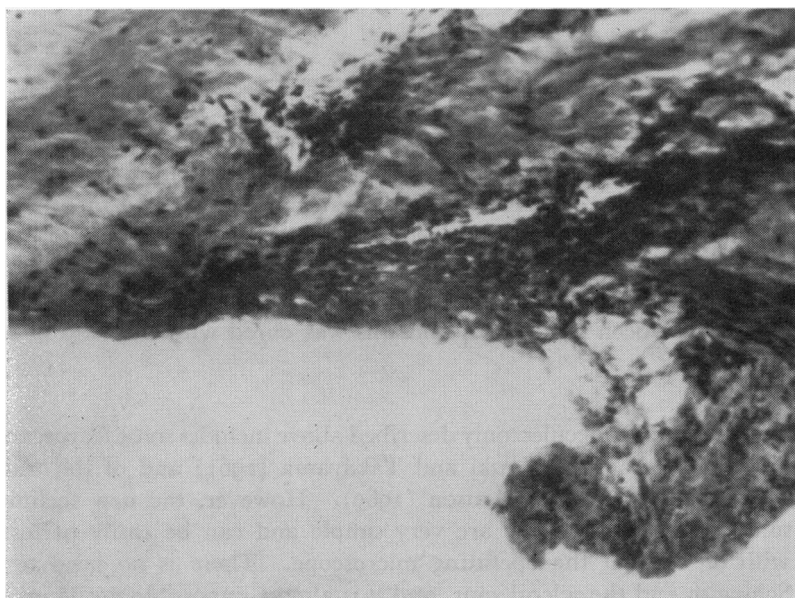


FIG. 4 *Section of corneo-sclera in a case of chronic simple glaucoma. Note the portion of weal tissue in the lower right-hand corner. Van Gieson stain.  $\times 56$*

pressure gradient between the anterior chamber and the canal becomes negligible and the possibility of functional blockade of the canal disappears. One may suppose that the effect of sinus trabeculectomy on the pathogenic mechanism of the rise in intraocular pressure in chronic simple glaucoma is similar to the effect of iridectomy on the mechanism of primary closed-angle glaucoma.

After filtering sinus trabeculectomy the aqueous humour also flows at least partially through Schlemm's canal and its exit channels. This may be concluded from the

following. Gonioscopy showed that the canal of Schlemm opened into the groove which had been formed by the removal of a piece of scleral tissue including the trabecular meshwork. In several cases after a successful operation a stream of clear fluid was observed in the aqueous veins. The filtering blebs were often flat after surgery in spite of the high C-value and the low intraocular pressure. In eyes in which Schlemm's canal was functioning well, the filtering blebs either disappeared some weeks after surgery or did not form at all.

The indications for simple sinus trabeculectomy have not been fully established. We now prefer to perform this operation in the early stages of chronic simple and closed-angle glaucoma. In the far advanced stages of the disease the filtering technique is the more reliable procedure. In the advanced stage of primary glaucoma the aqueous outflow facility (C-value) should be taken into account. If the C-value is relatively high (more than 0.10 mm.<sup>3</sup>/min./mm. Hg), one cannot expect Schlemm's canal to be closed by adhesions to a considerable extent. In such a case simple sinus trabeculectomy seems to be sufficient to improve the outflow facility and to control the intraocular pressure. In eyes with low C-values, filtering sinus trabeculectomy is preferable.

The simple technique seems to be of great value in cases of aphakic glaucoma, in eyes with subluxation of the lens, and in the early stages of traumatic glaucoma with recession of the chamber angle.

To evaluate the condition of Schlemm's canal in eyes with chronic simple glaucoma, we have recently employed the blood-filling test, which is performed as follows.

To decrease the intraocular pressure acetazolamide and glycerol are used in the usual doses and an hour later the eye is compressed with the finger for 3 to 5 minutes. If gonioscopy does not reveal any blood in the Schlemm's canal the cuff of the Rivva-Rochi apparatus is placed around the patient's neck. The pressure in the cuff is gradually raised up to 50 mm. Hg, and if necessary this pressure is maintained for 3 minutes. The result is considered to be positive if Schlemm's canal fills with blood. In such cases simple sinus trabeculectomy may be performed in the segment in which blood is observed. A negative result to this test is difficult to evaluate; it may be due not only to obstruction of Schlemm's canal but also to a narrowing of the canal and to dense pigmentation of the trabecular meshwork.

### Summary

The new techniques of simple and filtering sinus trabeculectomy are described. Both are based on the removal of a piece of deep scleral tissue including Schlemm's canal and the trabecular meshwork, the wound being closed with a scleral flap. If filtering sinus trabeculectomy is performed, a small portion of the external scleral flap is excised. In 96 per cent. of 100 eyes so treated, the intraocular pressure was controlled by surgery alone, and the rate of complications was low. The results were stable in 57 of 59 eyes observed 3 to 12 months after surgery. Indications for these operations are discussed.

### References

- CAIRNS, J. E. (1968) *Amer. J. Ophthalm.*, **66**, 673  
 ——— (1969) *Trans. ophthalm. Soc. U.K.*, **89**, 481  
 DUKE-ELDER, S. (1969) "System of Ophthalmology", vol. 11 "Diseases of the Lens and Vitreous; Glaucoma and Hypotony". Kimpton, London  
 KRASNOV, M. M., and KOLESNIKOVA, L. N. (1969) *Vestn. Oftal.*, No. 6, p. 54  
 LINNÉR, E. (1969) *Trans. ophthalm. Soc. U.K.*, **89**, 475  
 NAKAJIMA, A., KANKI, K., and TAKAYAMA, M. (1961) *Amer. J. Ophthalm.*, **52**, 503  
 NESTEROV, A. P. (1971) *Kazan med. J.*, No. 1, p. 81  
 WATSON, P. (1969) *Trans. ophthalm. Soc. U.K.*, **89**, 523