

# Recent advances in fluorescein fundus angiography

SOHAN SINGH HAYREH

*Department of Ophthalmology, University of Iowa, U.S.A.*

Contributed by request and dedicated to Sir Stewart Duke-Elder

Since MacLean and Maumenee (1960) first examined the fundus of patients with slit-lamp and indirect ophthalmoscopy after the injection of 5 per cent. intravenous sodium fluorescein, and Novotny and Alvis (1961) made the first successful photographs of the passage of dye through the retinal vessels with a modified fundus camera, fluorescein fundus angiography (FFA) has come to occupy a unique position in the diagnosis and understanding of numerous fundus lesions. The technique has made great strides in a comparatively short time because of the enthusiasm with which it has been received by ophthalmologists—both clinical and research. It is impossible to review all the recent advances and literature in such a broad field, and I therefore propose to concentrate mainly on the aspects which I consider most important, and those which interest me.

FFA, like all other investigations, unless properly conducted and interpreted, is bound to produce erratic results. With the sudden explosion of enthusiasm for this technique, it is not uncommon to find that it is being performed with inadequate knowledge of the right equipment and technique and indeed of basic facts; moreover, many abbreviated and inadequate versions have been advocated. Too many ophthalmologists assume that they are able to interpret FFA, not realizing that a correct interpretation of these angiograms, like that of  $x$  rays, requires a good deal of experience and expertise. These factors have often produced disappointing results which have been attributed to the inadequacies of FFA. It is not uncommon to find two extreme views on FFA: one of expecting miracles and an answer to every fundus problem; the other (held even by a few in high places!) that FFA has no significant contribution to make in clinical ophthalmology.

Many factors are involved in obtaining satisfactory rapid-sequence fluorescein angiograms. These include a good fundus camera and accessories, the right combination of filters, correct films and processing, a competent person doing the angiography, good dilatation of the pupils, clear ocular media, good co-operation from the patient, the patient's circulation time, and the concentration, quantity, mode, and site of injection of the fluorescein. A defect in any of these results in imperfect pictures. Over the years a good deal of attention has been devoted to improving the quality of fluorescein angiograms, and some of the recent advances in instrumentation and technique are mentioned below.

## **Instrumentation and technique**

### **FUNDUS CAMERA**

Improvements have been continually made in the camera, to provide a rapid sequence of pictures (usually at an interval of 0.3–0.6 sec.), better illumination and resolution, the

incorporation of a time indicator, vertical mounting, and other modifications; various automatic devices have been improvised to produce filter changing, data recording synchronization with dye injection and stereo-system (Parel, Crock, O'Day, and Wigley, 1968); automatic programme units have been incorporated (*e.g.* with the Retinophot camera—Jütte and Lemke, 1969). Haining (1969) described a semi-automatic system involving automatic fluorescein injection and the taking of pictures at preset intervals after the injection. Many efforts have been made to produce fluorescein cinéangiography in patients (Flocks, Miller, and Chao, 1959; Hyvärinen, 1967; Hart, Heyman, Linhart, McIntosh, and David, 1963; Linhart, McIntosh, Heyman, and Hart, 1964; Oberhoff, Evans, and Delaney, 1965; Dollery, Henkind, Kohner, and Paterson, 1968; Evans, 1969; Leverett, Bailey, Holden, and Cheek, 1970; Evans, Shimizu, Limaye, Deglin, and Wruck, 1973) but no satisfactory commercially available equipment has been produced so far. Attempts have been made to televise FFA and a new apparatus for video-tape recording of FFA has recently been reported (Yuhasz, Akashi, Urban, and Mueller, 1973) although the quality of the angiograms is not perfect. Most fundus cameras cover about 25°–30° of the fundus field and it has been always felt that a camera should be developed capable of covering a much wider field, for both ordinary colour and fluorescein photography. Such a camera\* covering 100°, was announced a few months ago.

#### STEREOSCOPIC ANGIOGRAPHY

Stereoscopic fundus photography and stereoscopic FFA are providing a wealth of new information, which is missing in two-dimensional pictures. This has been made easy by the production of consecutive stereo-photographs, as suggested by Allen (1964a,b), and the same can now be achieved easily in rapid sequence by the automatic Allen Stereo-separator, and by a similar attachment devised by Parel and others (1968). Simultaneous stereo-attachments have also been reported (Donaldson, 1964).

Crock (1970) described in detail the application of stereo-photogrammetry to FFA, providing three-dimensional quantitative measurements of structures and events in the fundus, by constructing contour maps with the help of stereo-plotter or analytical stereoplotter computer.

#### FILTERS

These are essential in obtaining satisfactory FFA. Work on them is discussed by Hodge and Clemett (1966), Haining and Lancaster (1968), Wessing (1969), Allen and Frazier (1969), Frazier and Allen (1972), and others. For sodium fluorescein the peak wave for fluorescein absorption normally lies between 4700 Å and 4900 Å and its major fluorescence emission peak is at 5250 Å with a second smaller peak at approximately 6150 Å (Hodge and Clemett, 1966). In the choice of filters, it is essential to allow the highest possible transmission in the desired wave length range (*i.e.* for excitor filter transmitting freely in 4000 Å–4900 Å). To eliminate pseudo-fluorescence (p. 398), it is extremely important that the barrier filter must block all scattered light passed by the excitation filter (*i.e.* below 5000 Å) but allow all wavelengths up to 7000 Å; the excitor filter must cut off sharply so that no wavelength beyond 5000 Å is transmitted, and there should be little or no overlap between the wavelengths of excitor and barrier filters. The Baird Atomic Inc. B5 interference filter as excitor filter was recommended by Hodge and Clemett (1966) and Haining and Lancaster (1968); Frazier and Allen (1972) recommended the broad-band filter system shown in Fig. 1 (opposite). I have used both the former (Hayreh, 1968a) and the latter systems and have found both of them satisfactory.

\* CA2 100; Field Fundus Camera by Clinitek, Danvers, Mass. 01923, U.S.A.

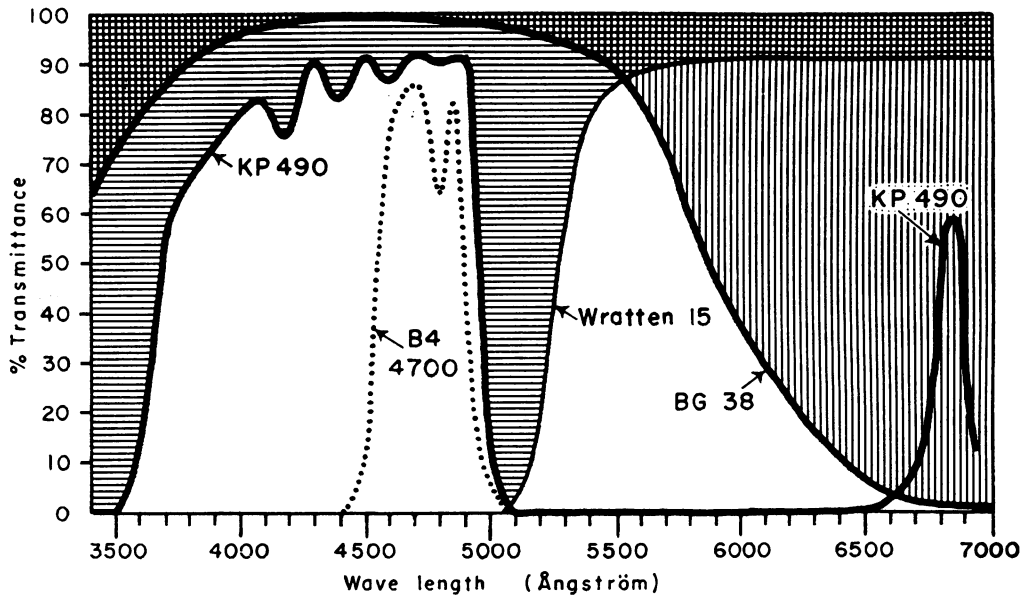


FIG. 1 *Transmission curves of various filters. The combination of filters commonly used for black and white FFA in the Department of Ophthalmology, Iowa City. Leitz KP490 broad-band excitation filter with Schott BG38 filter added in the excitation light to subtract red light transmitted by KP490, in combination with barrier filter Kodak Wratten No. 15. For colour FFA BG38 is not added. The transmission curve of Baird Atomic B<sub>4</sub> (4700Å) interference filter (an excitation filter) is shown for the purposes of comparison. (Reproduced by courtesy of Mr. O. Frazier and Mr. L. Allen of our department)*

#### FILMS

Almost everyone uses black and white films (I use Kodak Tri-X film). However, a good deal of interest has been shown in producing colour fluorescein fundus angiograms (Shikano and Shimizu, 1968; Matsui, Oka, and Matsui, 1969; Hendrickson, Oniki, and Elliott, 1970; Schatz, George, Liu, Maumenee, and Patz, 1973). The main object is to superimpose the FFA on ordinary ophthalmoscopic appearances, like a detailed road map, enabling a better localization and correlation of the fluorescein pattern with the ordinary fundus appearance. I have some reservations about the superiority of the colour angiogram over black and white.

The use of Polaroid films has been advocated by Allen (1964b), Allen, Kirkendall, Snyder, and Frazier (1966), and Snyder, Allen, and Frazier (1967) to obtain instant positive prints of fluorescein angiograms, which are a great advantage; however, a very rapid sequence photography is not possible and the quality of angiograms is not as good as can be obtained by conventional films.

Use of the Kodak 2498 Rapid Access Retrieval film in FFA has been advocated to obtain direct positive films instead of the usual negative films (McGean, Van Dyk, Riekhof, and Reinardy, 1972).

#### MODES OF INJECTION OF FLUORESCEIN

To get the best resolution of vessels in the fundus, it is essential to cause a very small bolus consisting of as high a concentration of fluorescein as possible to reach the eye, giving a sharp and bright dye-front in the ocular vessels. This can be achieved by delivering a

concentrated bolus of dye in as fast a blood stream as possible, *e.g.* intracarotid (Hill, Dollery, Mailer, Oakley, and Ramalho, 1965), by catheter into big veins near the thoracic inlet (Dollery, Hodge, and Engel, 1962; Hayreh, 1968a), or, as a compromise, by injecting by a large calibre butterfly needle (about size 19) in a big antecubital vein in the shortest possible time (less than a second). Since the circulation in the antecubital veins is sluggish and the dye injected here undergoes a dilution of 600 times before reaching the ocular vessels (Flower, 1973), some workers have advocated forcibly flushing the dye by injection of 5 to 15 ml. normal saline immediately after it (Evans, 1969; Flower, 1973). Direct injection of fluorescein solution by a needle on a syringe should be avoided as far as possible because of the higher risk of complications.

I have used the intracarotid injection of fluorescein extensively in my experimental studies in rhesus monkeys and have found that the quality of angiograms is definitely superior to those obtained by intravenous injections, but there are some limitations. The transit of the dye is so fast that the ordinary fundus cameras do not record all its phases and the immediate recirculation of the dye produces complicated angiograms (see legends of Fig. 3). In the human patient carotid injection involves extra risks, although ocular observations can sometimes be performed at the time of carotid angiography for other purposes.

#### CONCENTRATION OF FLUORESCEIN

Most investigators now use 5 ml. of 10 per cent. sodium fluorescein solutions. I and many others have used 2.5 ml. of 20 per cent. solution for many years with no ill-effects, although the manufacturers warn of the possibility of some precipitation with 20 per cent solutions.

#### TOXIC REACTIONS TO INTRAVENOUS FLUORESCEIN

Nausea and occasional vomiting may occur in about 5 to 10 per cent. of cases, but are of no serious consequence because of their transient nature. I have found that this almost invariably occurs with the first injection (sometimes even with the dilute test dose). On repeated injections of fluorescein (Hayreh, 1968a), to photograph different areas of the same or fellow fundus, no nausea or vomiting occurs; the occurrence of nausea or vomiting with the first injection is thus no contraindication for subsequent injection. I have frequently recorded such a response in anaesthetized rhesus monkeys, indicating that nausea and vomiting following intravenous fluorescein is due to central nervous action and is not purely psychological.

Stein and Parker (1971) reviewed and summarized the more serious side-effects of intravenous fluorescein reported in the literature, and added nine patients of their own, making a total of 55, as follows:

<i>Side-effects</i>	<i>No. of cases</i>
Urticaria and skin allergic reactions	36
Respiratory allergic reactions, <i>e.g.</i> wheezing, laryngeal oedema, etc.	5
Hypotension/shock	10
Cardiac Fatal myocardial infarction	1
Cardiac arrest	2
Basilar artery ischaemia	1
Pyrexia (probably due to infection or pyrogen reaction)	6

Some of these patients had more than one side-effect. In my experience of over two thousand patients, I noticed only a slight urticarial reaction in two or three patients and no other side-effects. One has to bear in mind that vasovagal reaction is not uncommon, particularly in young adults (much more in males than females!), and may be totally unrelated to fluorescein; many cases of fainting and hypotension, etc., after the simple introduction of needle or cannula are not due to the fluorescein at all. Cardiac dysrhythmias in hypersensitive persons after painful stimuli, *e.g.* the prick of a needle, are not unknown.

To cope with an emergency situation, Stein and Parker (1971) have suggested keeping ready an emergency tray consisting of adrenaline solution 1:1000, a parenteral anti-histamine, aminophylline, hydrocortisone sodium succinate, a sympathomimetic agent to counteract hypotension (*e.g.* Metaraminol bitartrate), parenteral fluids, airways, and oxygen. An indwelling venous catheter (p. 394) proves extremely useful in such a situation.

Pinkerton (1969) warned against producing an artefact in patients undergoing biochemical assays involving fluorescent spectroscopy because intravenous fluorescein shortly before such an assay will give erroneous high values, *e.g.* in catecholamine estimation for suspected pheochromocytoma in malignant hypertension.

#### OTHER DYES

Sodium fluorescein, although practically a harmless dye, has certain important limitations, *e.g.* its inability to visualize properly individual choroidal vessels because of its poor transmission qualities through the Fuscine pigment in the retinal pigment epithelium (RPE) and xanthophyll pigment in the macula (Fig. 2, p. 401), the free diffusion of the dye through ocular vessels other than those of the retina and optic nerve, its unsuitability for critical blood flow studies, etc. To overcome these limitations and improve the technique other dyes have been tried. The most common has been indocyanine green (a tricarbocyanine dye), which is rapidly excreted in bile with no recirculation in the fundus, and has a peak emission at or near 8450 Å (Flower and Hochheimer, 1973) which is not masked by the RPE. Absorption of the RPE does not decrease until 6600 Å (Behrendt and Wilson, 1965) and xanthophyll pigment in the macular region obscures the blue spectral range shorter than 5000 Å (Wald, 1949), so that the infrared wavelength of indocyanine green can penetrate the RPE and the choroidal vasculature can be seen. To photograph the dye in the fundus, Kodak high-speed Infrared film has been used, after intracarotid injection in monkeys (Kogure, David, Yamanouchi, and Choromokos, 1970) and man (Kulvin, Stauffer, Kogure, and David, 1970), and intravenous injection in cats (Hochheimer, 1971), monkeys (Flower, 1972), and man (Flower and Hochheimer, 1973). Studies have also been conducted by administering a single injection consisting of a mixture of sodium fluorescein and indocyanine green and making simultaneous angiograms of fluorescein and indocyanine green on two separate films by a modified Zeiss fundus camera (Flower and Hochheimer, 1973). The authors claim that this provides an unobstructed view of the choroidal circulation; but none of their angiograms show the quality and details of those seen in Fig. 3 (pp. 402, 403). I took the latter in rhesus monkeys after carotid injection of fluorescein and they show perfect details of the choriocapillaris, but Flower and Hochheimer (1973) admit that clear visualization of the choriocapillaris filling is not to be expected with indocyanine green. To obtain good choroidal details on FFA, the most essential pre-requisites are:

(1) The dye should reach the ocular vessels in a high concentration and as a very small bolus so that it forms a sharp and bright dye-front in the choroidal vessels, similar to that after intracarotid injection;

(2) This has to be photographed at a very rapid sequence, virtually at cine speed, because of a fast choroidal circulation.

I obtained good details of the choriocapillaris in rhesus monkey eyes by intravenous injection of fluorescein after slowing down the choroidal circulation by vortex vein occlusion (Hayreh and Baines, 1973) or posterior ciliary artery (PCA) occlusion (Hayreh and Baines, 1972a).

To test ocular vascular permeability, lissamine rhodamine B albumin (RB 200)—a protein-bound fluorescent dye, has been investigated in monkeys (Machemer, 1970). Its fluorescence was found to be less intense than that of sodium fluorescein. The diffusion pattern of the eye into the ocular tissue was similar to that of sodium fluorescein although the rate of diffusion was slow because of its large molecules. However, this was found to be useful for histological demonstration of the distribution of fluorescein in various ocular tissues.

#### MEASUREMENTS OF CALIBRE CHANGES OF RETINAL VESSELS

Hodge, Parr, and Spears (1969) evaluated the various methods described in the literature for measuring the calibre of retinal vessels in colour and fluorescein angiograms. They found that direct visual measurement of vessels by Olympus screw-micrometer eye-piece in a low-power microscope was the most consistent, with 95 per cent. confidence for less than  $\pm 3 \mu$ .

#### METHODS OF INTERPRETING ANGIOGRAMS

For correct interpretation of fluorescein angiograms it is essential to examine them at a high magnification and good resolution; this is *not* like viewing an *x*-ray film with the naked eye against any light! I usually use small portable projectors. The other important step is to examine the ordinary colour fundus photograph and the fluorescein angiogram of the same area simultaneously to enable a constant orientation and correlation between the two. Colour FFA has been suggested as a compromise for the second step (p. 394). If these two necessary conditions are not observed, the fluorescein angiograms may not only not give the full information but may actually mislead, yet many workers are unaware of these basic steps. Many people produce positive films or prints from the negative films of the FFA for interpretation, but I have never felt any need for this. There is no problem in reading the negative films, and the printing process involves loss of detail.

#### **Normal physiological barriers to diffusion of fluorescein in the fundus**

The presence of the blood-retinal barrier is now well established (Palm, 1947; Shakib and Cunha-Vaz, 1966; Rodriguez-Peralta, 1966, 1968; Cunha-Vaz and Maurice, 1967; Maurice, 1967; Machemer, 1970; Grayson and Laties, 1971). This helps us to differentiate a normal from an abnormal retinal vessel, including retinal neovascularization. I have found that retinal vessels which show a compensatory enlargement due to retinal vascular occlusion, *e.g.* retinociliary veins on the optic disc, maintain their normal retinal-blood barrier. A similar optic nerve-blood barrier has been reported (Anderson, 1969; Grayson and Laties, 1971; Machemer, 1970). The dye diffuses freely through the choriocapillaries and through the Bruch's membrane, but the RPE cells prevent its diffusion into the retina by exercising a "chorio-retinal barrier" (Lasansky and de Fisch, 1965; Rodriguez-Peralta, 1966, 1968; Grayson and Laties, 1971; Shakib, Rutikowski, and Wise, 1972). The retinal-blood, optic nerve-blood, and chorio-retinal barriers to diffusion of fluorescein into the

retina and optic nerve are due to tight cell junctions between the endothelial cells of the retinal (Missotten, 1962; Cunha-Vaz, Shakib, and Ashton, 1966) and optic nerve (Anderson, 1969) capillaries, and the RPE cells (Shakib and others, 1972) respectively. The choriocapillaries have a large number of pores in them (Missotten, 1962; Cunha-Vaz and others, 1966), which make the choriocapillaris 100 times more permeable than the retinal capillaries (Missotten, 1962).

### Normal fluorescein fundus angiograms

#### CHOROIDAL CIRCULATION

It is well established that the choroid, PCA contribution to the optic nerve head, and cilio-retinal artery (when present—Fig. 2) usually start to fill about a second or so before the retinal arterioles in normal eyes. This has been attributed to the faster blood flow in the PCAs than in the central retinal artery (Parr, Hodge, Clemett, and Knight, 1968), presumably because of the wide lumen of the choriocapillaries and the low peripheral resistance in the choroidal vascular bed (Archer, Krill, and Newell, 1970). It must, however, be strongly stressed that this is not invariable. This misconception is responsible for some erroneous interpretations, particularly since the role of the PCA circulation in glaucoma and low tension glaucoma is assuming importance. The initial filling of one part of the choroid before another, patchy filling, and irregular sequence of filling, as reported by many authors (Dollery and others, 1968; Hayreh, 1969b–d,f, 1970b; Hyvärinen, Maumenee, George, and Weinstein, 1969; Hayreh, Revie, and Edwards, 1970; Archer and others, 1970; Evans and others, 1973), are very common findings in perfectly normal eyes. Filling defects have sharp and reproducible margins (Fig. 2, 3c). Usually complete filling of the choroid occurs by the early retinal arterio-venous phase. This irregular filling pattern of the choroid was stressed by us to avoid the misinterpretation of normal spatial and sometimes temporal variations as pathological (Hayreh, 1969c; Hayreh and others, 1970). Evans and others (1973) reiterated our conclusions.

#### TERMINOLOGY OF THE PHASES OF TRANSIT OF FLUORESCEIN THROUGH THE FUNDUS

Dollery and others (1962), and subsequently many other workers, have used the following terminology to denote the different phases in the transit of fluorescein in the fundus:

(1) Choroidal flush → (2) Early arteriolar phase → (3) Late arteriolar phase → (4) Capillary phase → (5) Early venous phase → (6) Late venous phase.

I feel that this is a confusing terminology because phases 3, 4, and 5 merge into one another and cannot be clearly differentiated. I have always used the following terminology:

(A) Pre-retinal arterial phase (corresponding to 1) → (B) Retinal arterial phase (corresponding to 2) → (C) Retinal arterio-venous phase (corresponding to 3, 4, 5) → (D) Retinal venous phase (corresponding to 6), and (E) Late phase about 10–15 minutes after the injection of dye or even longer.

A uniform and simple terminology is essential for communication.

#### RETINAL CIRCULATION

The presence of regional variations in the filling of the retinal vascular bed on FFA has often been mentioned (Hart and others, 1963; Linhart and others, 1964; Ferrer, 1969).

Spatial variations in the filling of the retinal vascular bed (Hayreh and Perkins, 1968; Hayreh, 1969c) are extremely common after intracarotid injection of dye, less so after intravenous injection. Spatial variation may lead to erroneous interpretations, as in the pathogenesis of visual field defects in glaucoma (Hayreh and Perkins, 1969a; Hayreh, 1969c,d,f; 1972a). Attempts have been made to measure the normal retinal circulation time by FFA (Hart and others, 1963; Hickam and Frayser, 1965; Oberhoff and others, 1965; Ferrer, 1969) but the results have shown a wide variation, because circulation time depends upon the site and rate of injection, method of recording, critical resolution of the apparatus, and definition of end-point; moreover, it depends at what point in the fundus it is measured, because circulation is fastest at the macula and shows regional variations.

On FFA all retinal vessels have wider images than in standard retinal photographs (Allen and others, 1966—up to  $\frac{1}{4}$  increase; Shikano and Shimizu, 1968—10 to 15 per cent.; Jütte and Lemke, 1968; Hodge and others, 1969—11 to 22 per cent.; Bulpitt, Dollery, and Kohner, 1969—10 per cent. in arteries and 5 to 12 per cent. in veins) because fluorescein stains the normally transparent plasma between the vessel wall and the central core of cells.

#### FLUORESCEIN STAINING DURING THE LATE PHASES

The normal optic disc shows a well-defined fluorescence—more marked near the margins of the optic disc than at the centre. This is considered to be due to staining of collagen tissues of the lamina cribrosa by diffusion of the leaked fluorescein from the adjacent choroid (Machemer, 1970; Grayson and Laties, 1971), a phenomenon similar to that of scleral staining described by Sollom and Brown (1967). Retinal vessels show a faint fluorescence because of the circulating fluorescent blood. In young blondes and albinos, the choroid shows diffuse fluorescence with big non-fluorescent vessels (mostly choroidal veins) because of diffuse leakage of fluorescein from the choriocapillaris into the intervascular tissue of the choroid.

#### Pseudo-fluorescence

The presence of pseudo-fluorescence in black and white pictures can be a source of mis-interpretation. It has been recorded from light-coloured structures in the fundus, *e.g.* optic disc, medullated nerve fibres, white chorio-retinal scars, defects in the RPE, etc. (Lemke and Jütte, 1966; Lemke, Tilgner, and Jütte, 1967; Gass, 1968a; Norton, 1969a; Machemer, Norton, Gass, and Choromokos, 1970), and was wrongly attributed by some authors to auto-fluorescence of some of the ocular tissue (Lemke and Jütte, 1966; Lemke and others, 1967). The subject was investigated by Machemer and others (1970) who found that, with the right types and combination of filters (p. 3), pseudo-fluorescence can be virtually eliminated (Norton, 1969a). The test for the correct types of filters is to take a control picture of the fundus with the filters in position before injecting the fluorescein. This should show a completely blank picture without any fundus details.

It has frequently been advocated that examination of the fundus with the use of a blue filter in an ordinary ophthalmoscope is an adequate substitute for detailed FFA (Bynke and Aberg, 1970). Such abbreviated techniques must be condemned, however, because the absence of a barrier filter and the use of unsuitable filters produce all sorts of artefacts. An example of such erroneous conclusions is that of Bynke and Aberg (1970) who concluded, from blue light ophthalmoscopy, that a negative FFA result does not rule out optic disc oedema; this is evidently incorrect.



## Optic disc

FFA has proved invaluable not only in the study of the blood supply of the optic disc in health and disease but also as a method of clinical investigation in the diagnosis of many important optic disc lesions (*e.g.* optic disc oedema, retrobulbar neuritis, pseudo-optic-disc-oedema, drusen of the optic disc, optic atrophy, glial membranes covering the disc, optic disc pit, abnormal vessels on the disc, anterior ischaemic optic neuropathy, optic disc vasculitis, glaucoma, low tension glaucoma, and optic disc tumours) and in the better understanding of their pathogenesis. It is beyond the scope of this paper to mention even briefly the FFA contributions to all the above topics; I have discussed them in detail elsewhere and have summarized the relevant literature (Hayreh, 1968b, 1969d,f, 1970b, 1971a, 1972a,c, 1974a,b,d; Hayreh and Baines, 1972c; Hayreh and Cullen, 1972; Hayreh and Perkins, 1969a,b; Hayreh and others, 1970; Hayreh and Walker, 1967).

One of the most important diagnostic contributions of FFA is the differentiation of genuine optic disc oedema from pseudo-oedema; this has been described by Miller, Sanders, and ffytche (1965) and confirmed by many other workers. In early optic disc oedema, the disc is hyperfluorescent and has blurred margins during the late phases, but may show no abnormality during the transit of the dye. In moderate and marked oedema, the angiographic appearances are classical, with dilated capillaries and microaneurysms during the transit of the dye, and marked leakage of dye producing late fluorescence seen usually on the optic disc and the adjacent retina, with extensions usually along the retinal vessels above and below the disc. The FFA pattern is usually independent of the aetiology of non-inflammatory optic disc oedema. In retrobulbar neuritis, fluorescein angiographic changes tend to be sectoral and fluorescein staining of the optic disc precedes the onset of ophthalmoscopically visible optic disc oedema (Hayreh, 1969d,f, 1974d). In pseudo-oedema of the optic disc, the disc shows no abnormal vascular changes or hyperfluorescence. This simple test, therefore, can save the patient hazardous neurological and neurosurgical intervention.

Another very important recent contribution by FFA has been in the study of the normal blood supply and vascular disorders of the optic disc. It has been shown that the main source of blood supply to the optic nerve head is by the PCAs and that the PCA supply to the optic disc and choroid is sectoral (Hayreh and Perkins, 1969a; Hayreh, 1969d,f, 1970b, 1974a). This fact has greatly assisted our understanding of the pathogenesis of many disc lesions, particularly the ischaemic disorders. When the PCA supply to the optic disc is suddenly blocked, as in temporal arteritis, arteriosclerosis, and a host of other systemic and local vascular conditions, it produces anterior ischaemic optic neuropathy—a well known clinical entity with poor prognosis and, until recently, unknown pathogenesis (Foulds 1969a,b; Hayreh, 1969d,f, 1971a, 1974b,d; Hayreh and Baines, 1972c). FFA in these cases shows filling defects in the optic disc, the peripapillary choroid, and sometimes even in the rest of the choroid. The involvement of the optic disc may be total or sectoral, depending upon the extent of vascular occlusion.

When the ischaemia of the optic disc is gradual and of a chronic nature, it produces the changes described in glaucoma and low tension glaucoma. The amount of filling of the blood vessels of PCA origin in the optic disc and peripapillary choroid (this can be demonstrated by FFA) depends upon the difference between the perfusion pressure (PP) in the PCAs (particularly diastolic pressure) and the intraocular pressure—the greater the difference between the PP and intraocular pressure the better the filling and *vice versa*. A rise in intraocular pressure (as in glaucoma) or a fall in PP (as in low tension glaucoma)

produces an imbalance, resulting in vascular insufficiency and ischaemia of the optic disc, peripapillary choroid, and retrolaminar optic nerve (the latter derives its blood supply *via* the peripapillary choroid). This leads to cupping of the optic disc, cavernous degeneration of the retrolaminar optic nerve, and visual field defects. A fall in PP can result from arteriosclerotic narrowing of the PCAs, ophthalmic artery, or carotid arteries (p. 408). In patients with glaucoma and low tension glaucoma associated with significant changes at the optic disc and visual field defects, FFA reveals reduced fluorescence of the optic disc in spite of normal intraocular pressure. Thus, FFA has given us very important information on the pathogenesis of optic disc changes and visual field defects in glaucoma and low tension glaucoma, shifting the emphasis to the PCA circulatory disturbance in these conditions. The subject is discussed in detail elsewhere (Hayreh and Perkins, 1968a,b; Hayreh, 1969c,d,f, 1970b, 1972a, 1974a,b,d; Hayreh and others, 1970).

Spaeth (1971) and Spaeth and Vacharat (1972) advocated a "fluorescein angiographic provocative test" in glaucoma, but this is fraught with limitations as a routine diagnostic test although it may give useful information in some cases (Hayreh, 1972b).

FFA has revealed that, in a normal optic disc, redness and pallor seen ophthalmoscopically are not true guides to its vascularity because the temporal part of the disc, in spite of its paler appearance, is usually more vascular than the nasal part (Hayreh, 1969d,f, 1972d).

## Choroid

FFA can truthfully be said to have made the major contribution so far in the study of the choroidal circulation in health and disease. On ordinary ophthalmoscopy, the RPE completely masks the choroidal vascular bed, whereas FFA reveals significantly more of its nature.

### NORMAL CHOROIDAL VASCULAR PATTERN

FFA has virtually revolutionized our concept of the choroidal vasculature by demonstrating its circulatory pattern *in vivo*. I have studied this extensively by FFA after experimental occlusion of the various choroidal vessels (Hayreh, 1970b, 1971a, 1973a,b; Hayreh and Baines, 1972a,b,c, 1973).

#### (1) *Arterial supply*

FFA has clearly demonstrated the segmental nature of the arterial supply not only of the main PCAs but also all along their subdivisions including the choriocapillaris, with no direct communication between the adjacent sectors at any level.

(a) *Main PCAs* The medial and lateral PCAs usually each supply about half of the choroid, which may be the nasal or temporal half, or less often the superior or inferior.

(b) *Short PCAs* These are small subdivisions of the main PCAs and supply smaller sectors which vary greatly in size, shape, and location. Smaller subdivisions of short PCAs supply still smaller segments of irregular shape and size with well-defined edges. An odd island of choriocapillaris supplied by one of these small subdivisions (Fig. 2, 3c), or even a larger subdivision, may not fill synchronously with its neighbouring subdivisions. The existence of these has also been noticed by other workers (p. 397). These islands show no sign of filling from the adjacent choroid.

(c) *Temporal long PCA* Contrary to the classical description that these arteries supply the choroid only in front of the equator of the eye, my FFA studies have revealed that these supply a narrow segment of the choroid extending forwards from its point of entering into the globe (Hayreh, 1973a).

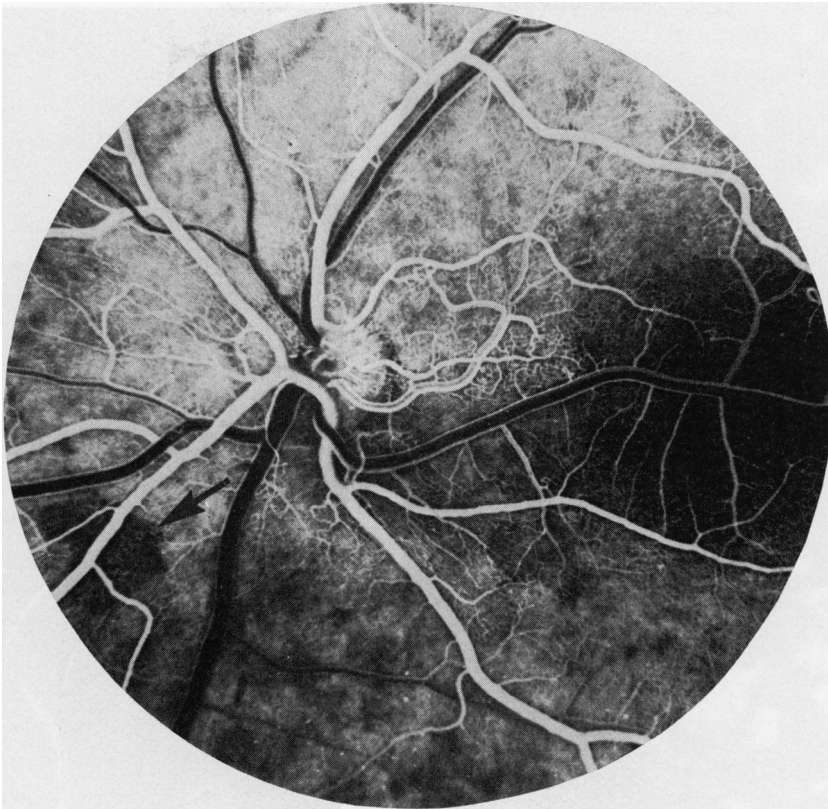


FIG. 2 Fluorescein fundus angiogram of a normal human fundus after intravenous 10% fluorescein, just at the beginning of the retinal arterio-venous phase. Note (i) An unfilled area of the choroid (indicated by an arrow) which filled later on; (ii) A small cilio-retinal artery between optic disc and macula; (iii) complete masking of fluorescein in the macular region, with a big retinal vein crossing over this area.

## (2) Choriocapillaris

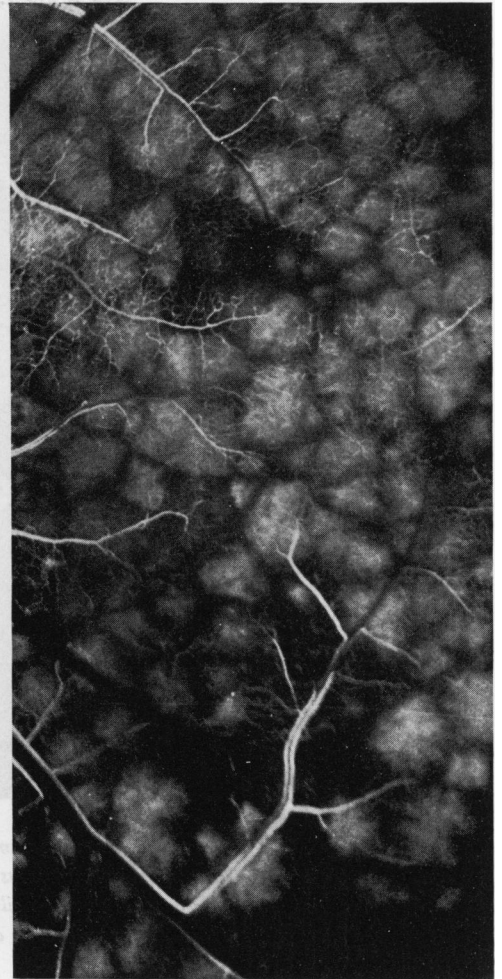
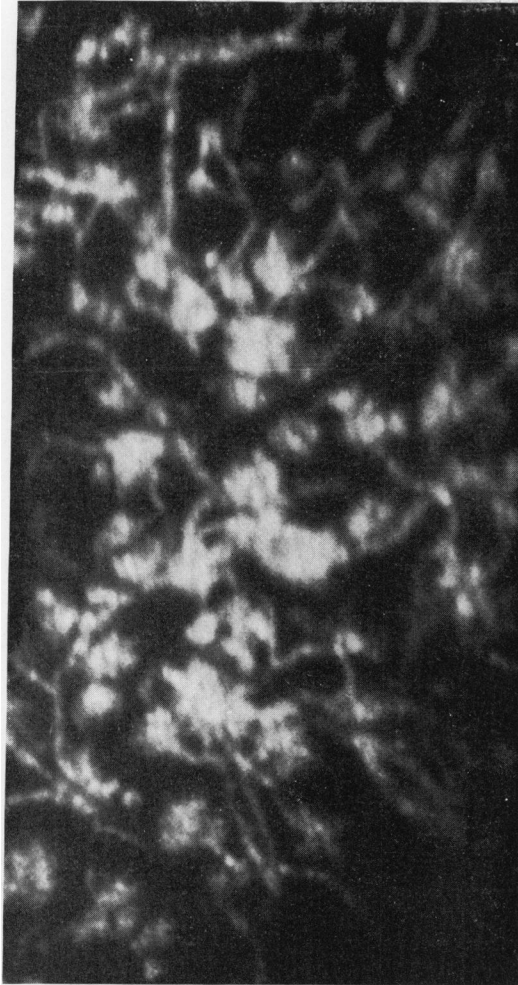
Contrary again to the accepted view that the choriocapillaris forms a freely communicating network, FFA has shown the following pattern:

(a) *Early filling phase* As soon as the dye reaches the choroid, a spotty filling of the choriocapillaris takes place (Fig. 3a, b). Each spot is composed of a large number of very tiny fluorescent spots, like a bunch of microaneurysms, at the end of a small choroidal arterioles (Fig. 3a). The dye starts to leak out immediately from the choriocapillaris and blurs their outlines. Each big spot (about a quarter or less of the size of the optic disc) is surrounded by a polygonal unfilled zone (Fig. 3b), and ultimately gives the appearance of a mosaic (Fig. 3c).

(b) *Complete filling phase* The entire choriocapillaris bed is uniformly fluorescent.

(c) *Early emptying phase* The fluorescence pattern at this stage is the reverse of (a), *i.e.* a central non-fluorescent zone (corresponding to the big spots seen in (a)) surrounded by a polygonal fluorescent mantle (Fig. 3d) composed of very tiny fluorescent spots of the size of microaneurysms (of the same size as seen in (a)). This produces a well-defined honeycomb pattern, which is reproducible on repeated FFA, indicating that these are not artefacts.

These studies indicate that each unit of the honeycomb or mosaic is independent, with



(a) Early filling phase of the choriocapillaris, with filling of the small choroidal arterioles. Choriocapillaries are seen as bunches of very tiny fluorescent spots (like microneurysms) at the ends of very small choroidal terminal arterioles.

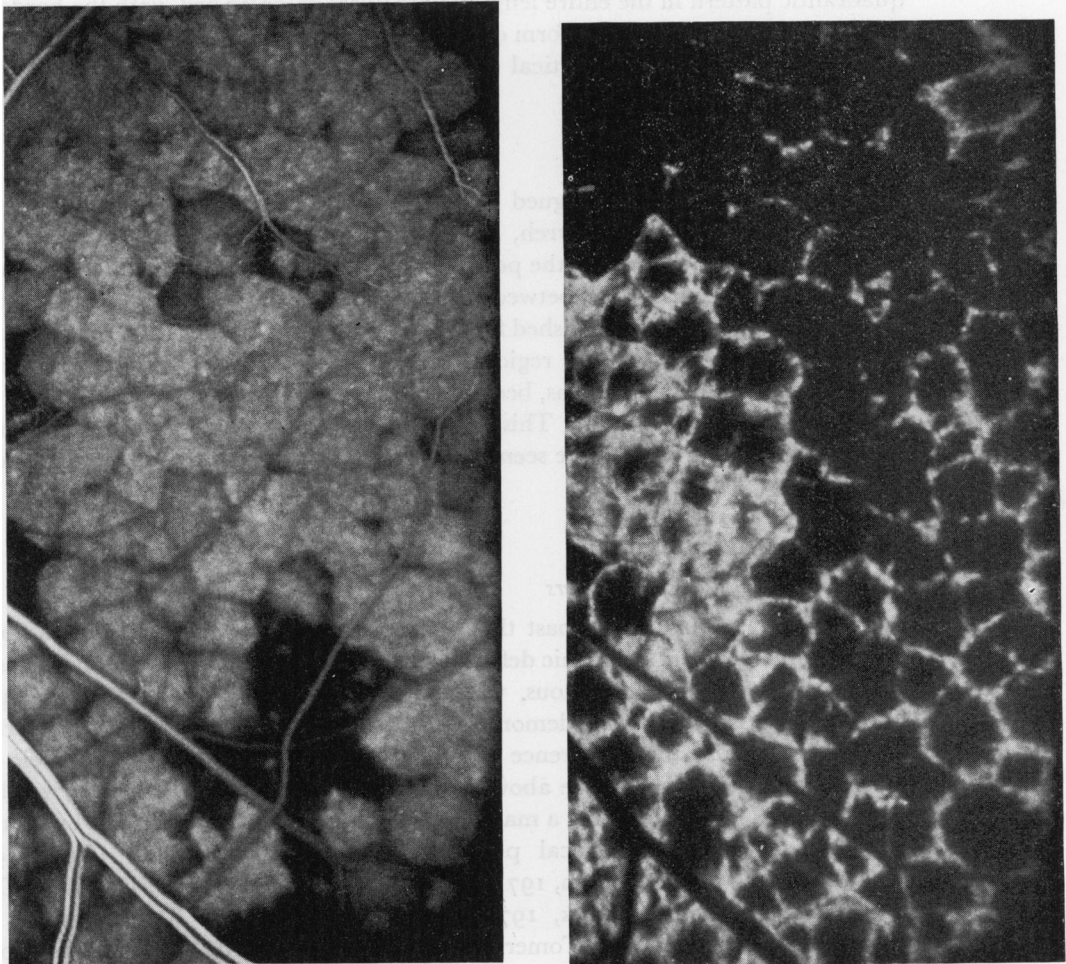
(b) Early filling phase of the choriocapillaris but later than seen in (a). Each bunch of choriocapillaries (supplied by very small choroidal terminal arterioles) now forms a big spot. Each spot is surrounded by a polygonal unfilled zone, producing a mosaic pattern in the choriocapillaris.

FIG. 3 Fluorescein fundus angiograms of normal eyes of rhesus monkeys ('b', 'c', and 'd' are pictures of the same area in one eye; 'a' is the same area of another eye) after intracarotid injection of fluorescein.

After intracarotid injection, the conventional phases of the circulation of dye in the retinal vascular bed (p. 398) are not seen; instead a very complicated picture emerges because the dye enters the retina in a fraction of a second, and then re-circulates very soon after its first transit. Thus Fig. 3(d) represents the pre-retinal arterial phase of the first transit; Fig. 3(b) shows a pre-retinal arterial phase of the re-circulation and at the same time the early retinal venous phase of the first transit (with retinal arteries already empty); Fig. 3(c) shows the early retinal arterial

no direct communication with the adjacent or any other unit, and that each big fluorescent spot or unit represents a bunch of choriocapillaries supplied by the terminal choroidal arteriole.

The vascular patterns of the choroid would help to explain the commonly observed localized nature of various choroidal lesions.



(c) Further stage in filling of the choriocapillaris. Note the well-defined mosaic pattern, with each unit of the mosaic an independent entity, and the isolated non-filling or slow filling of some of the units clearly visible. It is obvious that there is no communication between units.

(d) Early emptying phase of the choriocapillaris. The fluorescent big spots of the mosaic in (b) are now non-fluorescent and the previously unfilled watersheds are now fluorescent. The pattern is like that of a honeycomb, but the fluorescent lines are composed of tiny fluorescent spots (like microaneurysms).

phase of re-circulation with the venous phase of first transit. In re-circulation the transit of the dye is comparatively much slower than in the first transit. Once the sequence is understood, it will be readily apparent that Fig. 3(d) represents the early emptying phase of the first transit while Fig. 3(b, c) are due to re-circulation of the dye, starting with (b) and soon followed by (c). The picture shown in Fig. 3(a) is not commonly caught by the conventional fundus camera (taking pictures every 0.6 sec. or so) because it is best seen only in the first transit and it is impossible to synchronize deliberately the taking of a picture with this phase of the very fast first transit (indeed I have photographed it only occasionally). Cinéangiography of a high resolution may catch this phase more constantly. The time interval between 'd' and 'b' is 1.6 sec. and between 'b' and 'c' 0.8 sec.

### (3) Venous supply

Each of the four vortex veins has a segmental distribution, with poor communications between the adjacent veins (Hayreh and Baines, 1973). There is usually a well-defined

quadrantic pattern in the entire length of the uveal vascular bed, with the borders between the four quadrants taking the form of a cross—the horizontal line passing through the optic disc and macula, and the vertical passing through the zone between the optic disc and macula.

(4) *Macular region*

This subject has always intrigued ophthalmologists because of frequently seen macular lesions. My FFA studies (Hayreh, 1973a) indicate that the watershed zone between the various short PCAs supplying the posterior pole always passes through the macular region. Similarly the watershed zone between the four vortex veins also passes through the macular region. Since it is a well-established fact that the watershed zone is an area of comparatively poor vascularity, the macular region, being located on the watershed zones of both the short PCAs and the vortex veins, becomes more vulnerable to vascular disorders than other parts of the posterior choroid. This would be particularly so in eyes with arteriosclerotic changes in the choroid. I have seen no special macular artery supplying the submacular choroid.

#### CHOROIDAL PATHOLOGY

*Choroidal arterial occlusive disorders*

It had been assumed in the past that occlusion of one or more PCAs was not likely to produce any localized ischaemic defect in the choroid because the choroidal vascular bed was considered to be continuous, with no segmental distribution. In our experimental studies on PCA occlusion, we demonstrated by FFA not only the segmental distribution by the PCAs but also the occurrence of various chorio-retinal lesions and their evolution, thus showing the fallacy of the above assumption (Hayreh and Baines, 1972a, b, c; Hayreh, 1973d). These lesions had a marked resemblance to those described by many workers as “Acute posterior multifocal placoid pigment epitheliopathy” (Gass, 1968; Van Buskirk, Lessell, and Friedman, 1971; Ryan and Maumenee, 1972; Deutman, Oosterhuis, Boen-Tan, and Aan de Kerk, 1972; Kirkham, ffytche, and Sanders, 1972; Bird and Hamilton, 1972; Annesley, Tomer, and Shields, 1973). My experimental observations suggest that this entity represents a form of multifocal choroidal ischaemia with secondary pigment epitheliopathy (Hayreh and Baines, 1972b)—similar RPE changes have been described by us ophthalmoscopically, angiographically, and histopathologically in acute choroidal ischaemia (Hayreh and Baines, 1972b; Hayreh, 1973b). Amalric, in his various publications, has shown many cases of sectoral chorio-retinal lesions secondary to choroidal ischaemia, and calls them “triangular syndromes” (Amalric, 1969, 1973).

In acute choroiditis, the lesion may be non-fluorescent during the early stages of the transit of the dye but stains diffusely during the late phases; the area of late staining may be bigger than the ophthalmoscopically visible lesion (Hayreh, 1971b).

*Role of choroidal circulation in macular lesions*

FFA has once again opened an entirely new chapter in the role of choroidal circulation and neovascularization from the choroid responsible for a variety of exudative and haemorrhagic macular lesions, and their management by photocoagulation, particularly in disciform macular degenerations (Gass, 1967, 1973; Teeters and Bird, 1973a,b) and presumed ocular histoplasmosis syndrome (Hyvärinen, Lerer, and Knox, 1971; Krill and Archer, 1970; Gass, 1973). In these cases the presence of a sub-pigment epithelial or

sub-retinal neovascular membrane of choroidal origin which predisposes the eye to serous or haemorrhagic macular detachment can be demonstrated by FFA long before ophthalmoscopic macular involvement; these membranes are visualized ophthalmoscopically only occasionally, even in well-established cases. Rapid sequence stereo-FFA is valuable in detecting and outlining their precise location. These membranes come either *via* breaks in Bruch's membrane or around the peripapillary end of Bruch's membrane and on FFA are identical to pre-retinal neovascular membranes and freely leak fluorescein. The capillary plexus in the membrane is responsible for exudation and bleeding. These membranes are also seen in colloid bodies (drusen) of the fundus, angioid streaks, myopic degeneration, and choroidal tumours, and may occur without any other ocular abnormalities. FFA is essential to outline these membranes if photocoagulation therapy is to be undertaken, and then to follow their progress. Early recognition of neovascular membranes before, or soon after, the development of macular detachment is important to prevent permanent loss of central vision.

The role of FFA in the diagnosis and understanding of Harada's disease is very well discussed by Shimizu (1973). There are numerous discrete fluorescent spots at first which gradually enlarge and form mounds of dye behind the detached RPE and there is associated optic disc fluorescein staining. He feels that Harada's disease represents an acute posterior uveitis with pigment epitheliopathy so that the RPE becomes permeable to choroidal fluids and dye, and produces secondary retinal detachment. According to Shimizu, Harada's disease and sympathetic ophthalmitis cannot be differentiated on FFA and the Vogt-Koyanagi syndrome is a chronic stage of Harada's disease. On the other hand, Behçet's syndrome involves the retinal vasculature first, associated with diffuse dilatation and hyperpermeability of the retinal vascular system and optic disc capillaries.

#### *Choroidal tumours*

This is another very important field in which FFA has made a very valuable contribution as an additional diagnostic weapon in the ophthalmic armoury to avoid mistaken and late diagnosis. It is surprising to note that the national average of mistaken diagnosis and enucleation of eyes for choroidal malignant melanomas in the United States of America is about 20 per cent., a frightening figure (Ferry, 1964; Shields and Zimmerman, 1973). The latter authors, in their series of eyes removed from October, 1962, to December, 1969, found that FFA was used in only one of the 41 eyes enucleated with a mistaken diagnosis. The role of FFA in the diagnosis of choroidal tumours has been discussed in detail elsewhere (Hayreh, 1974c). In flat infiltrating pigmented choroidal malignant melanoma, which is one of the very dangerous varieties because it infiltrates the choroid without showing the typical elevated mass, extends into the orbit, and is usually confused with a choroidal naevus, FFA can differentiate it from the various benign neoplastic and non-neoplastic pigmented lesion (Hayreh, 1969a, 1970a). Similarly, FFA helps in diagnosis of other pigmented malignant melanomas. Although FFA is helpful in diagnosis of amelanotic choroidal malignant melanoma, secondary choroidal metastatic deposits, and choroidal haemangiomas, it may not always be able to differentiate one of these from the others. In my experience I have frequently come across ophthalmologists who expect a final and immediate answer from FFA in the diagnosis of choroidal malignant tumours; I should like to stress that FFA is an extremely useful and essential test in these cases, but like any other test has its limitations. Therefore its findings must be taken into consideration along with the other available information, *e.g.* from a thorough clinical examination, indirect ophthalmoscopy, biomicroscopy, retroillumination, P<sub>32</sub> uptake, and ultrasonography, etc., to avoid

making a mistaken diagnosis. In the interests of brevity, and to avoid giving inadequate information, I omit here the FFA patterns of the various choroidal tumours.

#### *Vortex vein occlusion*

FFA has revealed not only the segmental distribution of the vortex veins (p. 403) but also that blockage of the vortex veins can play an important role in the production of some major complications following retinal detachment surgery, *e.g.* glaucoma, anterior uveitis, necrosis of the anterior segment of the eye, and choroidal and intraocular haemorrhage; also in the production of some idiopathic hyphaemas and some cases of non-granulomatous iritis (Hayreh and Baines, 1973).

#### *Choroidal folds*

FFA can differentiate choroidal folds from ophthalmoscopically identical retinal folds. The choroidal folds show hyperfluorescence of their peaks while retinal folds show no fluorescein abnormality (Norton, 1969b; Newell, 1973). Since the aetiologies of the two types of folds are very different, FFA is a useful diagnostic aid.

### **Retinal pigment epithelium (RPE)**

FFA once again has given us important information about the various RPE disorders, both in diagnosis and pathogenesis, as well as in other disorders where RPE plays an important role. Recent studies have shown that RPE exercises a chorio-retinal barrier (p. 396), and any lesion which upsets this barrier could produce serous retinal detachment in the area, *e.g.* in central serous retinopathy, Harada's disease (p. 405), and detachment of RPE.

FFA has fundamentally altered our concept of the nature of central serous retinopathy and of other exudative macular diseases. The presence of fluorescein leak on FFA is a well-established phenomenon in central serous retinopathy and is diagnostic of this condition. Wessing (1973) has dealt admirably with the clinical description and management of the condition. FFA, by showing that the leak not only establishes the diagnosis but also helps in localizing the area to be photocoagulated, if the latter is indicated. Gass (1967) and Wessing (1973) consider the causative process probably to be small focal areas of increased capillary permeability in the choriocapillaris but it is still not definite. It seems that the factor responsible for the subretinal serous fluid is the breakdown of the chorio-retinal barrier by the RPE at the site of fluorescein leak either because of a primary lesion of the RPE at that site or because of underlying choriocapillaris involvement.

Detachment of the RPE can be confused with a choroidal hypopigmented malignant melanoma or metastatic carcinoma, but on FFA the entire area of detachment slowly starts to fluoresce soon after the dye reaches the fundus, reaching its maximum fluorescence during the late phase, usually resulting in a circumscribed uniformly fluorescent area. A break in the RPE may result in associated serous detachment of the overlying retina (Gass, 1967).

Gass (1968a) considered the so-called acute posterior multifocal placoid pigment epitheliopathy discussed on p. 404 to be primarily a disease of the RPE.

Degenerative lesions of the RPE unmask the choroidal fluorescence and thus make it easy to recognize them early, *e.g.* in various types of congenital and acquired macular degeneration without overlying retinal detachment, chloroquine retinopathy, retinitis pigmentosa, colloid bodies, fundus flavimaculatus, and other degenerative conditions.



## Macula

I have already mentioned the role of FFA in central serous retinopathy (p. 406), disciform macular degenerations (p. 404), chloroquine retinopathy (p. 406), congenital and acquired macular degenerations (p. 406), colloid bodies (p. 406), and detachment of the RPE (p. 406). Gass (1968b), in a series of papers on macular dysfunctions secondary to retinal vascular disease, *e.g.* retinal vascular occlusion, hypertensive retinopathy, diabetic retinopathy, retinal telangiectasis, radiation retinopathy, carotid occlusion, and collagen vascular diseases, and in his classical work on disciform macular degeneration (Gass, 1967), has fully established the important role of FFA in the diagnosis, management, and understanding of these lesions.

A characteristic diagnostic FFA pattern revealed by macular oedema, seen in a variety of conditions, has proved very useful in the early detection of this macular lesion before the retina undergoes irreversible cystoid macular degeneration (Gass and Norton, 1966; Ffytche and Blach, 1970). In this condition there is fluorescein leakage from the intra-retinal circle of capillaries in the macular region which during the late phase forms typical flower-like multi-radiating fluorescent streaks in the macula. In my experience macular oedema usually responds favourably to high doses of systemic corticosteroids and in the early stages function can be restored. In one rare instance, FFA revealed macular oedema associated with peripheral choroidal malignant melanoma (Newsom, Hood, Horwitz, Fine, and Sewell, 1972).

Pre-retinal macular fibrosis produces characteristic increased tortuosity of the small retinal vessels which may be completely masked on ophthalmoscopy by the membrane, but are clearly outlined by FFA; usually there is no fluorescein leak (Wise, 1972).

## Retina

Ophthalmoscopy, although invaluable and essential in examining the fundus, is a very crude method of evaluating the retinal vasculature and its disorders. FFA has once again opened a new chapter in retinal vascular diseases. Its role in diabetic retinopathy and hypertensive retinopathy is a saga in itself, helping us in their early detection, follow-up, and management, and in understanding their pathogenesis, upon which I shall not dwell. Although retinal digest preparations gave us very valuable information on the various changes in the retinal microcirculation, FFA has helped us to visualize and study it *in vivo*. An enormous literature, once again, exists on the FFA studies in retinal vascular occlusion; FFA has helped to demonstrate the circulation time, haemodynamics, obliterated capillaries, collaterals established, neovascularization, microaneurysms, patency of vessels, and recanalization, in addition to giving information about the pathophysiology of retinal vasculature. In branch retinal vascular occlusion, FFA may help us to localize the site and extent of occlusion, *e.g.* at arterio-venous crossing in branch vein occlusion and at the site of an embolus in an arterial branch. FFA has also given us important information about the rapidity with which circulation is restored even after complete occlusion so that in central retinal artery occlusion, a few hours or days after the onset of the occlusion, retinal circulation is almost always seen on FFA; therefore, unless FFA is performed within a few hours after the occurrence of occlusion, no block may be demonstrated. Thus, inability to demonstrate an arterial block on FFA does not mean that the artery was not previously blocked (Hayreh, 1971b) and the same has been found to be true of PCA occlusion (Hayreh, 1974b). This information is extremely important in determining the presence or

absence of a previous block in an artery in any study on vascular occlusion. In superior or inferior temporal branch vein occlusion, FFA can demonstrate the degree of macular involvement by the actual occlusive process and oedema, and determine the prognosis for vision. Clemett, Kohner, and Hamilton (1973) have shown that, if the capillary arcade in the macula is intact, the prognosis for vision is good. This information is only available by FFA. In patients with neovascularization of the retina following retinal vascular occlusion, diabetic retinopathy, sickle-cell retinopathy, Eales's disease, and other causes, which produce vitreous haemorrhages, FFA is essential to locate the neovascularization for photo-coagulation and follow-up.

White-sheathed and sclerosed retinal vessels, which on ophthalmoscopy look completely occluded, have been found to be patent on FFA. Conversely, ophthalmoscopically normal-looking red terminal arterioles in sickle-cell retinopathy may show complete occlusion on FFA (Goldberg, 1971).

FFA has revealed that in Eales's disease the retinal vasculature shows changes identical to those seen in retinal venous occlusion and diabetes, *i.e.* areas of capillary obliteration, microaneurysms, development of arterio-venous shunts, and neovascularization. This indicates that Eales's disease is a disease of the retinal microcirculation and is a retinal capillary disorder (Wessing and Meyer-Schwickerath, 1969; Hayreh, 1969e). In posterior retinal vasculitis, sheathed and involved big retinal vessels show late fluorescence due to staining.

Sickle-cell retinopathy on FFA shows peripheral arteriolar occlusion, non-perfusion of the involved areas, arterio-venous shunts, and neovascularization (Goldberg, 1971). Post-radiation retinopathy again shows similar changes (Hayreh, 1970c).

Thus, on FFA, the fundus shows identical changes in diabetic retinopathy, retinal venous occlusion, Eales's disease, sickle-cell retinopathy, and post-radiation retinopathy, suggesting a common aetiological factor, *i.e.* an occlusive process involving the retinal microcirculation. FFA not only demonstrates the presence of these retinal vascular changes but also enables us to study their evolution *in vivo*.

In Coats's disease, FFA not only confirms the presence of telangiectases and differentiates them from haemorrhages, but also helps to delineate the degree of vascular involvement, documenting the progression of the disease, the placement of photocoagulation burns, and evaluation of the effectiveness of the treatment (Tasman, 1969).

Thus, in the retina, FFA helps us to differentiate (*i*) white deposits (so-called hard exudates) from other white lesions in the fundus, because on FFA the white deposits show no abnormality; (*ii*) retinal arterial channels from venous ones; (*iii*) abnormal retinal neovascularization from compensatory collateral vessels, because the former leak fluorescein profusely while the latter do not; and (*iv*) haemorrhages from microaneurysms, telangiectases or clusters of vessels, because the former are non-fluorescent while all the latter show fluorescein filling.

In carotid artery occlusion or stenosis, FFA can be helpful by demonstrating delayed ocular circulation on the affected side and also delay in the interval between the retinal arterial and venous phases (David, Norton, Gass, and Sexton, 1966). In addition, this also lowers the perfusion pressure in the ocular vessels, and impaired perfusion in the PCA would produce the clinical picture of low tension glaucoma (p. 400), in which FFA can be of diagnostic help.

## References

- ALLEN, L. (1964a) *Amer. J. Ophthalm.* 57, 13

- (1964b) *Ibid.*, **57**, 539
- and FRAZIER, O. (1969) "Proc. Int. Symp. Fluor. Angio., Albi, 1969, ed. P. Amalric", pp. 2-5. Karger, Basel (Publ. 1971)
- , KIRKENDALL, W. M., SNYDER, W. B., and FRAZIER, O. (1966) *Arch. Ophthalm. (Chicago)*, **75**, 192
- AMALRIC, P. (1969) In "Proc. Int. Symp. Fluor. Angio., Albi, 1969", ed. P. Amalric, pp. 193-203. Karger, Basel (Publ. 1971)
- (1973) *Trans. Amer. Acad. Ophthalm. Otolaryng.*, **77**, 291
- ANDERSON, D. R. (1969) *Arch. Ophthalm. (Chicago)*, **82**, 659
- ANNESLEY, W. H., TOMER, T. L., and SHIELDS, J. A. (1973) *Amer. J. Ophthalm.*, **76**, 511
- ARCHER, D., KRILL, A. E., and NEWELL, F. W. (1970) *Ibid.*, **69**, 543
- BEHRENDT, T., and WILSON, L. A. (1965) *Ibid.*, **59**, 1079
- BIRD, A. C., and HAMILTON, A. M. (1972) *Brit. J. Ophthalm.*, **56**, 881
- BULPITT, C. J., DOLLERY, C. T., and KOHNER, E. M. (1969) "Proc. Int. Symp. Fluor. Angio., Albi, 1969", ed. P. Amalric, pp. 476-9. Karger, Basel (Publ. 1971)
- BYNKE, H. B., and ABERG, L. (1970) *Acta ophthalm. (Kbh.)*, **48**, 752
- CLEMETT, R. S., KOHNER, E. M., and HAMILTON, A. M. (1973) *Trans. ophthalm. Soc. U.K.*, **93**, 523
- CROCK, G. (1970) *Ibid.*, **90**, 577
- CUNHA-VAZ, J. G., and MAURICE, D. M. (1967) *J. Physiol. (Lond.)*, **191**, 467
- , SHAKIB, M., and ASHTON, N. (1966) *Brit. J. Ophthalm.*, **50**, 441
- DAVID, N. J., NORTON, E. W. C., GASS, J. D., and SEXTON, R., (1966) *Arch. Neurol.*, **14**, 281
- DEUTMAN, A. F., OOSTERHUIS, J. A., BOEN-TAN, T. N., and AAN DE KERK, A. L. (1972) *Brit. J. Ophthalm.*, **56**, 863
- DOLLERY, C. T., HENKIND, P., KOHNER, E. M., and PATERSON, J. W. (1968) *Invest. Ophthalm.*, **7**, 191
- , HODGE, J. V., and ENGEL, M. (1962) *Brit. med. J.*, **2**, 1210
- DONALDSON, D. D. (1964) *Trans. Amer. ophthalm. Soc.*, **62**, 429
- EVANS, P. Y. (1969) "Proc. Int. Symp. Fluor. Angio., Albi, 1969", ed. P. Amalric, pp. 463-469, Karger, Basel (Publ. 1971)
- , SHIMIZU, K., LIMAYE, S., DEGLIN, E., and WRUCK, J. (1973) *Trans. Amer. Acad. Ophthalm. Otolaryng.*, **77**, 260
- FERRER, O. (1969) *Ophthalmologica (Basel)*, **157**, 89
- FERRY, A. P. (1964) *Arch. Ophthalm. (Chicago)*, **72**, 463
- FFYTCH, T. J., and BLACH, R. K. (1970) *Trans. ophthalm. Soc. U.K.*, **90**, 637
- FLOCKS, M., MILLER, J., and CHAO, P. (1959) *Amer. J. Ophthalm.*, **48**, 3
- FLOWER, R. W. (1972) *Ibid.*, **74**, 600
- (1973) *Invest. Ophthalm.*, **12**, 881
- and HOCHHEIMER, B. F. (1973) *Ibid.*, **12**, 248
- FOULDS, W. S. (1969a) In "The William Mackenzie Centenary Symp. on Ocular Circulation in Health and Disease, Glasgow, 1968", ed. J. S. Cant, pp. 136-141. Kimpton, London
- (1969b) *Trans. ophthalm. Soc. U.K.*, **89**, 125
- FRAZIER, O., and ALLEN, L. (1972) In "Current Concepts in Ophthalmology", vol. 3, ed. F. C. Blodi, pp. 41-47. Mosby, St. Louis
- GASS, J. D. M. (1967) *Amer. J. Ophthalm.*, **63**, 573, 587, 617, 645, 661, 689
- (1968a) *Arch. Ophthalm. (Chicago)*, **80**, 177
- (1968b) *Ibid.*, **80**, 535, 550, 569, 583, 592, 606
- (1973) *Trans. Amer. Acad. Ophthalm. Otolaryng.*, **77**, 310
- and NORTON, E. W. D. (1966) *Arch. Ophthalm. (Chicago)*, **76**, 646
- GOLDBERG, M. F. (1971) *Amer. J. Ophthalm.*, **71**, 649
- GRAYSON, M. C., and LATIES, A. M. (1971) *Arch. Ophthalm. (Chicago)*, **85**, 600
- HAINING, W. M. (1969) "Proc. Int. Symp. Fluor. Angio., Albi, 1969", ed. P. Amalric, pp. 46-48. Karger, Basel (Publ. 1971)
- and LANCASTER, R. C. (1968) *Arch. Ophthalm. (Chicago)*, **79**, 10

- HART, L. M., HEYMAN, A., LINHART, J. W., MCINTOSH, H., and DAVID, N. J. (1963) *J. Lab. clin. Med.*, **62**, 703
- HAYREH, S. S. (1968a) *Brit. J. Ophthalm.*, **52**, 566
- (1968b) *Docum. Ophthalm.*, **24**, 289
- (1969a) "Proc. Int. Symp. Fluor. Angio., Albi, 1969", ed. P. Amalric, pp. 115-130. Karger, Basel (Publ. 1971)
- (1969b) *Idem*, p. 213
- (1969c) *Idem*, pp. 318-322
- (1969d) *Idem*, pp. 510-530
- (1969e) *Idem*, p. 680
- (1969f) *Brit. J. Ophthalm.*, **53**, 721
- (1970a) *Ibid.*, **54**, 145
- (1970b) *Ibid.*, **54**, 289
- (1970c) *Ibid.*, **54**, 705
- (1971a) *Trans. ophthalm. Soc. U.K.*, **91**, 291
- (1971b) *Amer. J. Ophthalm.*, **72**, 998
- (1972a) *Brit. J. Ophthalm.*, **56**, 175
- (1972b) *Ibid.*, **56**, 216 (Commentary)
- (1972c) *Ibid.*, **56**, 652
- (1972d) *Ophthalmologica (Basel)*, **165**, 100
- (1973a) *Exp. Eye Res.*, **17**, 387
- (1973b) *Trans. Amer. Acad. Ophthalm. Otolaryng.*, **77**, 300
- (1974a) *Ibid.*, **78**, OP 240
- (1974b) "Anterior Ischemic Optic Neuropathy". Springer, New York.
- (1974c) In "Current Concepts in Ophthalmology", vol. 4, ed. F. C. Blodi. Mosby, St. Louis (In press)
- (1974d) In "Aspects in Neuro-ophthalmology", ed. S. I. Davidson, pp. 45-85. Butterworth, London
- and BAINES, J. A. B. (1972a) *Brit. J. Ophthalm.*, **56**, 719
- and ———— (1972b) *Ibid.*, **56**, 736
- and ———— (1972c) *Ibid.*, **56**, 754
- and ———— (1973) *Ibid.*, **57**, 217
- and CULLEN, J. F. (1972) *Ibid.*, **56**, 86
- and PERKINS, E. S. (1969a) In "William Mackenzie Centenary Symp. on Ocular Circulation in Health and Disease, Glasgow, 1968", pp. 71-86. Kimpton, London
- and ———— (1969b) "Proc. Int. Symp. Fluor. Angio., Albi, 1969", ed. P. Amalric, pp. 323-328, Karger, Basel (Publ. 1971)
- , REVIE, I. H. S., and EDWARDS, J. (1970) *Brit. J. Ophthalm.*, **54**, 461
- and WALKER, W. M. (1967) *Amer. J. Ophthalm.*, **63**, 982
- HENDRICKSON, P. H., ONIKI, S., and ELLIOTT, J. H. (1970) *Arch. Ophthalm. (Chicago)*, **83**, 580
- HICKAM, J. B., and FRAYSER, R. (1965) *Invest. Ophthalm.*, **4**, 876
- HILL, D. W., DOLLERY, C. T., MAILER, C. M., OAKLEY, N. W., and RAMALHO, P. S. (1965) *Proc. roy. Soc. Med.*, **58**, 535
- HOCHHEIMER, B. F. (1971) *Arch. Ophthalm. (Chicago)*, **86**, 564
- HODGE, J. V., and CLEMETT, R. S. (1966) *Amer. J. Ophthalm.*, **61**, 1400
- , PARR, J. C., and SPEARS, G. F. S. (1969) *Ibid.*, **68**, 1060
- HYVÄRINEN, L. (1967) *Acta ophthalm. (Kbh.)*, **45**, 862
- , LERER, R. J., and KNOX, D. L. (1971) *Amer. J. Ophthalm.*, **71**, 449
- , MAUMENEE, A. E., GEORGE, T., and WEINSTEIN, G. W. (1969) *Ibid.*, **67**, 653
- JÜTTE, A., and LEMKE, L. (1968) "Bücherei des Augenarztes", No. 49, p. 5. Enke, Stuttgart
- and ———— (1969) "Proc. Int. Symp. Fluor. Angio., Albi, 1969", ed. P. Amalric, pp. 49-51. Karger, Basel (Publ. 1971)

- KIRKHAM, T. H., FFYTCH, T. J., and SANDERS, M. D. (1972) *Brit. J. Ophthalm.*, **56**, 875
- KOGURE, K., DAVID, N. J., YAMANOUCHI, U., and CHOROMOKOS, E. (1970) *Arch. Ophthalm. (Chicago)*, **83**, 209
- KRILL, A. E., and ARCHER, D. (1970) *Ibid.*, **84**, 595
- KULVIN, S., STAUFFER, L., KOGURE, K., and DAVID, N. J. (1970) *Sth. med. J.*, **63**, 998
- LASANSKY, A., and DE FISCH, F. W. (1965) In "Die Struktur des Auges, II, Symposium, Wiesbaden, 1965", ed. J. W. Rohen, p. 139. Schattauer, Stuttgart
- LEMKE, L., and JÜTTE, A. (1966) *Klin. Mbl. Augenheilk.*, **149**, 19
- , TILGNER, S., and JÜTTE, A. (1967) *Ophthalmologica (Basel)*, **153**, 349
- LEVERETT, S. D., BAILEY, P. F., HOLDEN, G. R., and CHEEK, R. J. (1970) *Arch. Ophthalm. (Chicago)*, **83**, 223
- LINHART, J. W., MCINTOSH, H. D., HEYMAN, A., and HART, L. M. (1964) *Circulation*, **29**, 577
- MACHEMER, R. (1970) *Amer. J. Ophthalm.*, **69**, 27
- , NORTON, E. W. D., GASS, J. D. M., and CHOROMOKOS, E. (1970) *Ibid.*, **70**, 1
- MACLEAN, A. L., and MAUMENEE, A. E. (1960) *Ibid.*, **50**, 3
- MATSUI, K., OKA, Y., and MATSUI, T. (1969) *Acta Soc. ophthalm. jap.*, **73**, 653
- MAURICE, D. M. (1967) *Invest. Ophthalm.*, **6**, 464
- MCGEAN, P. H., VAN DYK, H. J. L., RIEKHOF, F. T., and REINARDY, R. (1972) *Amer. J. Ophthalm.* **74**, 1210
- MILLER, S. J. H., SANDERS, M. D., and FFYTCH, T. J. (1965) *Lancet*, **2**, 651
- MISSOTTEN, L. (1962) *Ophthalmologica (Basel)*, **144**, 1
- NEWELL, F. W. (1973) *Amer. J. Ophthalm.*, **75**, 930
- NEWSOM, W. A., HOOD, C. I., HORWITZ, J. A., FINE, S. L., and SEWELL, J. H. (1972) *Trans. Amer. Acad. Ophthalm. Otolaryng.*, **76**, 1005
- NORTON, E. W. D. (1969a) "Proc. Int. Symp. Fluor. Angio., Albi, 1969", ed. P. Amalric, p. 93. Karger, Basel (Publ. 1971)
- (1969b) *Proc. roy. Soc. Med.*, **62**, 119
- NOVOTNY, H. R., and ALVIS, D. L. (1961) *Circulation*, **24**, 82
- OBERHOFF, P., EVANS, P. Y., and DELANEY, J. F. (1965) *Arch. Ophthalm. (Chicago)*, **74**, 77
- PALM, E. (1947) *Acta ophthalm. (Kbh.)*, **25**, 29
- PAREL, J. M., CROCK, G. W., O'DAY, D., and WIGLEY, A. (1968) *Med. J. Aust.*, **1**, 291
- PARR, J. C., HODGE, J. V., CLEMETT, R. S., and KNIGHT, F. H. (1968) *Trans. ophthalm. Soc. N.Z.*, **20**, 88
- PINKERTON, R. M. H. (1969) "Proc. Int. Symp. Fluor. Angio., Albi, 1969", ed. P. Amalric, pp. 652-654. Karger, Basel (Publ. 1971)
- RODRIGUEZ-PERALTA, L. A. (1966) *J. comp. Neurol.*, **126**, 109
- (1968) *Ibid.*, **132**, 109
- RYAN, S. J., and MAUMENEE, A. E. (1972) *Amer. J. Ophthalm.*, **74**, 1066
- SCHATZ, H., GEORGE, T., LIU, J., MAUMENEE, A. E., and PATZ, A. (1973) *Trans. Amer. Acad. Ophthalm. Otolaryng.*, **77**, 254
- SHAKIB, M., and CUNHA-VAZ, J. G. (1966) *Exp. Eye Res.*, **5**, 229
- , RUTKOWSKI, P., and WISE, G. N. (1972) *Amer. J. Ophthalm.*, **74**, 206
- SHIELDS, J. A., and ZIMMERMAN, L. E. (1973) *Arch. Ophthalm. (Chicago)*, **89**, 466
- SHIKANO, S., and SHIMIZU, K. (1968) "Atlas of Fluorescence Fundus Angiography", pp. 8-10, 78. Saunders, Philadelphia
- SHIMIZU, K. (1973) *Trans. Amer. Acad. Ophthalm. Otolaryng.*, **77**, 281
- SNYDER, W. B., ALLEN, L., and FRAZIER, O. (1967) *Arch. Ophthalm. (Chicago)*, **77**, 168
- SOLLOM, A. W., and BROWN, I. A. R. (1967) *Brit. J. Ophthalm.*, **51**, 815, 821
- SPAETH, G. L. (1971) *Trans. Amer. Acad. Ophthalm. Otolaryng.*, **75**, 296
- and VACHARAT, N. (1972) *Brit. J. Ophthalm.*, **56**, 205
- STEIN, M. R., and PARKER, C. W. (1971) *Amer. J. Ophthalm.*, **72**, 861
- TASMAN, W. (1969) "Proc. Int. Symp. Fluor. Angio., Albi, 1969", ed. P. Amalric, pp. 617-619, Karger, Basel. (Publ. 1971)
- TEETERS, V. W., and BIRD, A. C. (1973a) *Amer. J. Ophthalm.*, **75**, 53

- and ————— (1973b) *Ibid.*, **76**, 1
- VAN BUSKIRK, E. M., LESSELL, S., and FRIEDMAN, E. (1971) *Arch. Ophthalm. (Chicago)*, **85**, 369
- WALD, G. (1949) *Docum. Ophthalm.*, **3**, 94
- WESSING, A. (1969) "Fluorescein Angiography of the Retina", trans. G. K. von Noorden, p. 23. Mosby, St. Louis
- (1973) *Trans. Amer. Acad. Ophthalm. Otolaryng.*, **77**, 275
- and MEYER-SCHWICKERATH, G. (1969) "Proc. Int. Symp. Fluor. Angio., Albi", pp. 608–612. Karger, Basel. (Publ. 1971)
- WISE, G. N. (1972) *Trans. ophthalm. Soc. U.K.*, **92**, 131
- YUHASZ, Z., AKASHI, R. H., URBAN, J. C., and MUELLER, M. M. H. (1973) *Arch. Ophthalm. (Chicago)*, **90**, 481