

Ovalness* of the optic cup and disc in the normal eye

ALAN TOMLINSON

Department of Ophthalmic Optics, University of Manchester Institute of Science and Technology

AND

CALBERT I. PHILLIPS

Department of Ophthalmology, University of Edinburgh

Observations have been made of the horizontal extent of cupping of the optic nerve head in both normal and glaucomatous eyes in an attempt to determine the factors which influence cup size in the normal eye (Armaly, 1967; Armaly and Sayegh, 1969; Armaly, 1969a, b; Tomlinson and Phillips, 1969; Jönsas, 1972) and to establish differential diagnostic criteria for glaucomatous excavation (Armaly, 1969c; Armaly, 1970; Becker, 1970; Kirsch and Anderson, 1973a). In our series (1969) cup-disc *area* ratio was chosen to take account of oval or other shapes.

Recently the vertical elongation of the optic cup has been considered as a possible diagnostic feature of glaucomatous cupping by Kirsch and Anderson (1973a, b) and Weisman, Asseff, Phelps, Podos, and Becker (1973). It is important, however, to consider factors which influence physiological variations of any feature before it may be utilized as a diagnostic criterion of any condition, *e.g.* it has been found (Tomlinson and Phillips, 1969) that the area of cup of the optic disc in *normal* eyes is related to axial length of the eyeball and that this in turn is related to intraocular pressure (Tomlinson and Phillips, 1970); similarly the degree of angulation and position of emergence of vessels at the optic disc are dependent on the area of physiological cupping present (Tomlinson and Phillips, 1971).

Our present observations were made to define clearly whether a vertically oval cup tends to occur in a vertically oval disc (this may have been implicit in the investigation by Weisman and other (1973) but is not considered by Kirsch and Anderson (1973a)).

Subjects

The individuals in this investigation had been studied previously (Tomlinson and Phillips, 1969, 1970, 1971). Of the original 75 subjects in these earlier studies, eleven were excluded on the grounds that their astigmatism (greater than 0.75 D) might have affected the ovalness of the cup and disc because of differential magnification by the optical system of the eye in various meridians. Of the remaining 64 subjects, 43 were male and 21 female; their ages ranged from 18 to 27 years. The results from only one eye, selected at random by the toss of a coin (31 right, 33 left), were used for statistical purposes. All subjects had intraocular pressures of less than 20 mm.Hg, and no family history of glaucoma.

Address for reprints: Dr. Alan Tomlinson, Department of Ophthalmic Optics, UMIST, Sackville Street, Manchester 1.

* "Ellipticity" might be more accurate but we prefer "ovalness" although the latter may contain the implication "egg-shaped"

Method

Stereoscopic pairs were constructed from fundus photographs taken successively by a fixed displacement technique (Tomlinson and Phillips, 1969). The photographs were mounted on cards and viewed through a variable prism stereoscope; in this method of viewing the edge of the cup was assessed quite accurately by the change in apparent depth. Measurements were taken of the horizontal and vertical diameters of cup and disc by a finely-graduated steel rule. Ovalness of cup and disc was expressed as the ratio:

$$\text{Vertical diameter of disc (or cup) : Horizontal diameter of disc (or cup).}$$

Observer bias in assessments of these ratios was thought to be unlikely, as the vertical dimensions of the cup and disc were measured at a considerable interval from and without conscious knowledge of the other dimensions considered.

Other dimensions of interest in this investigation, *i.e.* cup-to-disc area and diameter ratio and axial length of eyeball had been determined in a previous study (Tomlinson and Phillips, 1969).

Results

The relationships between cup and disc ovalness ratios, axial length, and cup-to-disc area ratio were statistically analysed by the Spearman rank correlation test (Siegel, 1956); see Table.

A significant relationship was found between the ovalness of cup and disc ($R_s = +0.405$; $P < 0.001$) *i.e.* a (vertically) oval cup tends to occur in a (vertically) oval disc. The ovalness of cup or disc was not found to be significantly related to cup-to-disc area ratio or axial length ($P < 0.25$).

Of the 64 subjects, twelve had a difference between the vertical and horizontal cup-to-disc diameter ratios of greater than 0.1 (*i.e.* C/D vertical : C/D horizontal diameter ratios of > 0.1). In none of these normal subjects did the difference exceed 0.2.

Discussion

Cup-to-disc *area* ratio was considered in relation to cup and disc ovalness (Table) as it was felt that this was a better index than diameter ratio of the extent of disc excavation, particularly in cases of cups and discs with non-circular margins. (In clinical work, however, we would admit that this is impractical because of the need for photographs of each case. Accordingly some consideration was also given to horizontal and vertical cup-to-disc diameter ratios.)

Our results confirm those of Weisman and others (1973) that the majority of subjects have vertical and horizontal cup-to-disc (diameter) ratios which differ by less than 0.1 and that for normal subjects this difference is rarely greater than 0.2.

We consider that an adequate means of indicating "vertical elongation" of the cup and of describing the shape of the cup in isolation from the disc is by the ovalness ratio employed in this study. It is likely that, in visual assessments of cup shape in ophthalmoscopic examination of the fundus, it is the ovalness or shape of the cup alone which is considered. Accordingly it is of some interest to consider the ovalness of the cups in isolation (although of course the burthen of this communication is to counsel against this for clinical purposes) in order to compare our observations with those of Kirsch and Anderson (1973a). In our nomenclature a round cup would have a ratio of horizontal:vertical dimension of near to 1, a "horizontally" oval cup would have a ratio of < 1 and a "vertically" oval cup a ratio

of > 1 . In our 64 eyes (64 subjects) the following observations were made:

- 6 (9.4 per cent.) had horizontally oval cups (ratio < 0.90)
- 24 (37.5 per cent.) had round cups (ratio 0.9 to 1.10)
- 25 (39 per cent.) had moderately vertically oval cups (ratio > 1.10 to 1.30)
- 9 (14.1 per cent.) had markedly vertically oval cups (ratio > 1.30)

These results indicate that the shape of the cup considered in isolation in normal eyes is round in only about one-third of cases but vertically oval in more than half. Since almost 50 per cent. of the eyes examined in this study were myopic, it could be objected that our results may not be an accurate indication of the distribution of cup-shape in the parent population; however, neither the ovalness of the cup nor the ovalness of the disc have been found to be significantly related to axial length of the eyeball (see Table) so that the objection is probably not a valid one.

Table Relationship between ovalness of cup and disc, axial length of eyeball, and cup-to-disc area ratio found by the Spearman rank correlation test

<i>Dimensions compared</i>	<i>Correlation coefficient</i>	<i>Level of significance</i>
Ovalness of disc and cup-disc area ratio	$R_s = -0.163$	$P < 0.25\ddagger$
Ovalness of disc and axial length	$R_s = -0.143$	$P < 0.25\ddagger$
Ovalness of cup and cup-disc area ratio	$R_s = -0.091$	$P < 0.50\ddagger$
Ovalness of cup and axial length	$R_s = 0.071$	$P < 0.60\ddagger$
Ovalness of disc and ovalness of cup	$R_s = +0.403$	$P < 0.001^*$

* Highly significant.

† Not significant.

This finding of a preponderance of vertically oval cups is somewhat at odds with that of Kirsch and Anderson (1973a) who assert that "round" cups are usually found in normal eyes. However, as they give no quantitative description of "roundness", it is possible that a slightly vertically oval cup would be classified as round by these authors. Indeed the visual impression on which their assessments are based appear to be largely influenced by the amount of tissue visible between the margin of the cup and disc.

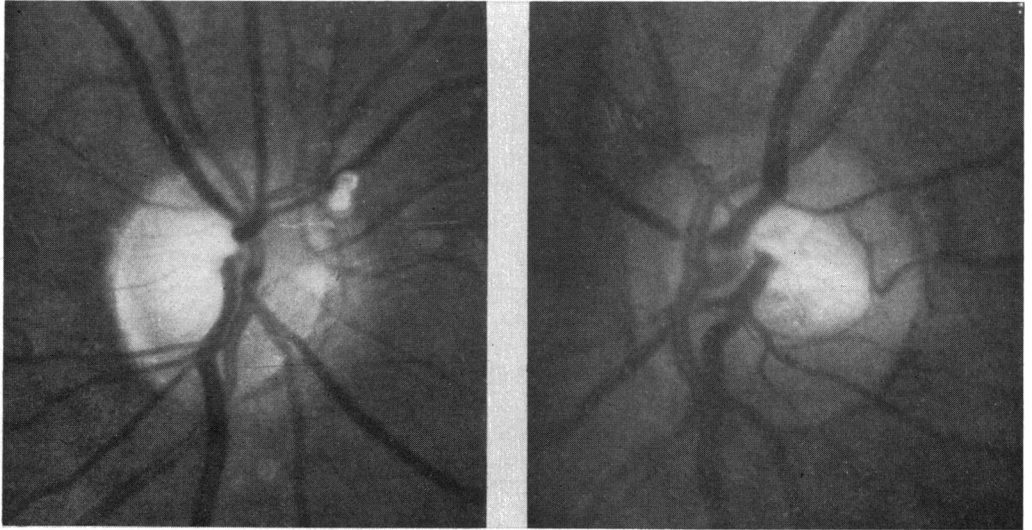
Kirsch and Anderson (1973a) stressed the need for careful examination of the amount of disc tissue present at the edge of cup in the assessment of disc excavation. For this reason and because all measures of ovalness fail to take account of any eccentricity of cup position within the disc area, we determined the correlation between the ovalness ratio of the cup and the (horizontal) eccentricity of the cup within the disc area. This latter dimension had been calculated previously (Tomlinson and Phillips, 1971) for our group of subjects as the ratio:

Horizontal distance from the nasal edge of the cup to the nasal edge of the disc : Horizontal distance from the temporal edge of the cup to the temporal edge of the disc.

No significant relationship was found between these ratios ($R_s = -0.089$; $P < 0.50$).

Both Kirsch and Anderson (1973a, b) and Weisman and others (1973) cite vertical elongation of the cup as a feature of glaucoma. If this elongation is described in quantitative terms by the difference in horizontal and vertical cup-to-disc ratios [see Weisman and others (1973)], we feel that this criterion is acceptable. However, if a purely qualitative

visual impression of the cup alone is taken as the measure, it is possible that errors may occur. The results of our present study show that *a relationship exists between the shape of the cup and disc in normal eyes, in that a vertically oval cup is likely to occur in a vertically oval disc* (Figure); this is probably the explanation for the presence of markedly vertical oval cups in some non-glaucomatous eyes observed by Kirsch and Anderson (1973a). *Although a vertical cup alone would not be suspicious in our view, a vertically oval cup within a round disc would be.* In other words, a large difference between the ovalness ratios of cup and disc should be viewed with suspicion. In the present study of normal subjects, the mean difference between ovalness of cup and disc was 0.08 ± 0.15 .



(a) A (vertically) oval cup is seen within a (vertically) oval disc (ovalness ratio of cup = 1.38; ovalness ratio of disc = 1.12)

(b) A "round" cup is seen within a round disc (ovalness ratio of cup = 0.91; ovalness ratio of disc = 1.00).

FIGURE *Optic discs of two normal eyes photographed with the Zeiss fundus camera*

Summary

In a series of 64 normal eyes from 64 normal subjects (*i.e.* one eye only from each) aged 18 to 27 years, almost 50 per cent. of whom were myopic with astigmatism not greater than 0.75 D, the ratio of vertical:horizontal extent of (a) cup and (b) disc was measured from pairs of fundus photographs viewed in a stereoscope. A vertically oval cup tended significantly to occur in a vertically oval disc. Twelve of the 64 eyes showed a difference of greater than 0.1 (*i.e.* vertical minus horizontal cup-to-disc diameter ratios), but none showed a difference of more than 0.2. A vertically elongated cup should not therefore be accepted as a criterion of glaucoma unless the shape of the disc is also taken into account.

References

- ARMALY, M. F. (1967) *Arch. Ophthalm. (Chicago)*, **78**, 35
 ——— (1969a) *Amer. J. Ophthalm.*, **68**, 401
 ——— (1969b) *Trans. Amer. Acad. Ophthalm. Otolaryng.*, **73**, 898
 ——— (1969c) *Docum. ophthalm. (Den Haag)*, **26**, 526
 ——— (1970) *Invest. Ophthalm.*, **9**, 425

- and SAYEGH, R. E. (1969) *Arch. Ophthalm. (Chicago)*, **82**, 191
- BECKER, B. (1970) *Amer. J. Ophthalm.*, **70**, 681
- JÖNSAS, C-H. (1972) *Acta ophthalm. (Kbh.)*, Suppl. 117
- KIRSCH, R. E., and ANDERSON, D. R. (1973a) *Amer. J. Ophthalm.*, **75**, 442
- (1973b) *Trans. Amer. Acad. Ophthalm. Otolaryng.*, **77**, 143
- SIEGEL, S. (1956) "Non-parametric Statistics for Behavioural Scientists", p. 202. McGraw-Hill, New York
- TOMLINSON, A., and PHILLIPS, C. I. (1969) *Brit. J. Ophthalm.*, **53**, 765
- (1970) *Ibid.*, **54**, 548
- (1971) *Ibid.*, **55**, 165
- WEISMAN, R. L., ASSEFF, C. F., PHELPS, C. D., PODOS, S. M., and BECKER, B. (1973) *Trans. Amer. Acad. Ophthalm. Otolaryng.*, **77**, 157