

Senile choroidal sclerosis

S. H. SARCS

Lidcombe Hospital, Sydney, Australia

Choroidal sclerosis is a descriptive term applied to the ophthalmoscopic appearance of prominent white choroidal vessels in which the blood columns are not seen or are sheathed by white lines. The two pathological reports of central areolar choroidal atrophy (Ashton, 1953; Babel, 1958) and one report of central choroidal sclerosis (Howard and Wolf, 1964) have not shown a greater degree of angiosclerosis than would be expected for the age of the patients. This discrepancy between the clinical interpretation and the histological findings has caused some observers to favour the term choroidal atrophy as originally applied by Nettleship (1884) and Morton (1885). Recently Krill and Archer (1971) have supported this concept on the basis of fluorescein studies demonstrating atrophy of one or more layers of the choroidal vessels.

Affected areas of the fundus are often limited to well-defined zones in which the choroidal circulation is exposed by atrophy of the overlying tissues, and Sorsby (1939) distinguished central, generalized, and peripapillary varieties. Sorsby further drew attention to hereditary features of the condition and subsequently described the early stages, thereby establishing it as an heredo-degeneration with onset earlier in life. However, the fully-developed picture is more commonly encountered in senile eyes. In these cases a similar clinical picture may apparently result from senile arteriosclerosis (Cohen, 1938). Because of the lack of pathological material, the nature of the changes in the vessel walls which account for their clinical appearance remains uncertain.

This report correlates the clinical and pathological changes in two cases of choroidal sclerosis.

Material and methods

Two elderly patients admitted to Lidcombe Hospital for long-term care were referred for assessment of failing vision. Examination of the fundi revealed the presence of choroidal sclerosis. No relatives were available for examination but there was no known family history of eye disease in either case.

The eyes subsequently obtained *post mortem* were fixed in buffered formalin and double embedded. Serial sections were cut horizontally through the affected areas and stained for fibrous tissue, elastic tissue, calcium, reticulin, and mucopolysaccharide. Selected pieces of unembedded tissue were stained for fat.

Case 1, a man aged 91 years, was admitted in January, 1969, with a diagnosis of cerebral arteriosclerosis. Ocular examination and fundus photography were performed on admission. He gave a history of gradual deterioration of vision in the left eye for 8 years but he still continued to read with the right eye. Vision was 6/6 in the right eye and 6/60 in the left. Refraction was emmetropic and, apart from early cortical lens opacities, the only significant abnormality on ophthalmological examination was the presence of bilateral choroidal sclerosis.

Clinical appearance of left eye (Fig. 1, opposite)

The greater part of the left fundus was affected by choroidal sclerosis which was confined to clearly demarcated zones centrally but became diffuse in the periphery. A ring of peripapillary choroidal sclerosis was separated by a narrow strip of more normal fundus from an affected central area approximately 1 disc diameter in size. This central area showed a clear-cut circular edge except on the

temporal side where it merged with a larger diffuse zone of choroidal sclerosis. Other similarly affected areas were evident in the remainder of the fundus. In the affected areas many of the choroidal vessels appeared completely white while others showed irregular sheathing. The background between these vessels was of a greyish-yellow colour although a large patent vessel in the temporal area was flanked on either side by choroidal pigmentation. In the remainder of the fundus some choroidal vessels appeared red and prominent while others were yellowish and indistinct, but much of the choroidal pattern was obscured by numerous ill-defined yellow colloid deposits. The disc was pale and the retinal arterioles were moderately attenuated.

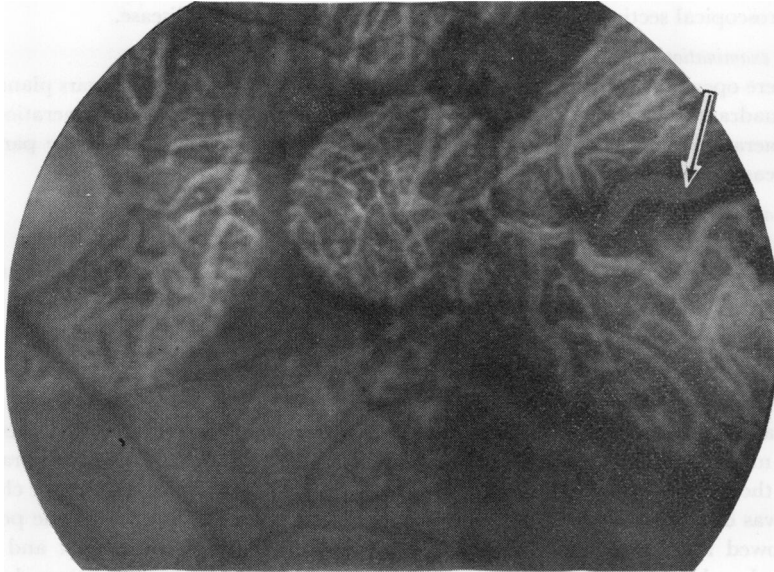


FIG. 1 *Case I. Left fundus. Arrow points to choroidal vessel which remains flanked by choroidal pigment and does not show the white fibrotic appearance*

Clinical appearance of right eye (Fig. 2)

The right eye showed a similar zone of peripapillary choroidal sclerosis and a diffusely involved temporal area in which lay scattered masses of retinal pigment. The intervening more normal portion of the fundus was of larger size than in the left eye and contained widespread colloid deposits.

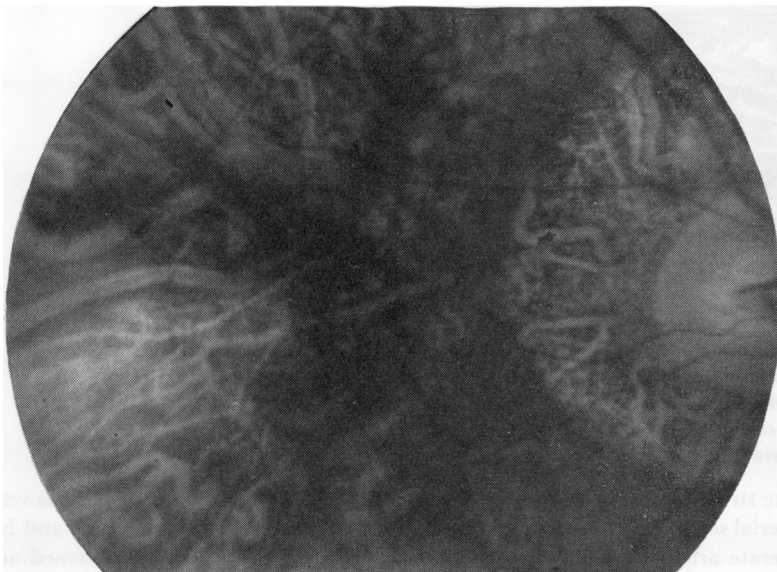


FIG. 2 *Case I. Right fundus*

General health

Apart from senile debility the patient was in fairly good health. Blood pressure was 170/80 and there were no notable previous illnesses. Extensive laboratory studies revealed no significant abnormality.

The patient became progressively demented and death occurred 10 months after admission. Autopsy was performed 2 hours after death. The immediate cause of death was bronchopneumonia. The brain weighed only 980 g. and appeared to have undergone atrophy, dilatation of the lateral ventricles being more noticeable than surface changes. There was extensive atheroma involving the circle of Willis and its branches and the aorta. The brain was not submitted to histological examination. Microscopical sections of the heart showed primary amyloid disease.

Macroscopic examination

The eyes were opened in the horizontal plane. There were clear cysts of the pars plana in the upper temporal quadrants of both eyes. Both eyes also showed peripheral cystoid degeneration and paving-stone degeneration with pigment migration into the retina. The retinae were particularly thin over the areas of choroidal sclerosis.

Microscopic appearances of the left eye

ANTERIOR SEGMENT

The anterior segment showed the usual ageing changes and intraepithelial cyst formation of the corona ciliaris. The cysts of the pars plana were removed with the superior calotte.

POSTERIOR CILIARY ARTERIES AND CHOROID

The posterior ciliary arteries appeared normal for the age of the patient. All the vessels were found patent when traced through their intrascleral course.

There was remarkable atrophy of the choroid in general. The number of larger and smaller vessels was markedly reduced and in the more severely affected areas Bruch's membrane lay almost directly on the sclera. The large vessels remaining occupied the full thickness of the choroid (Fig. 3) and none was of normal appearance. Even the earliest choroidal branches of the posterior ciliary arteries showed atrophy of their muscular coats without fibrous replacement and their lumina appeared reduced. Muscle fibres were observed only occasionally but the internal elastic lamina could be seen in most arteries as a crenelated structure lying in a pale and oedematous acellular material. Occasional vessels consisted only of simple endothelial tubes, while rounded structures with collapsed fibrous walls were also observed, suggesting the remnants of blood vessels.

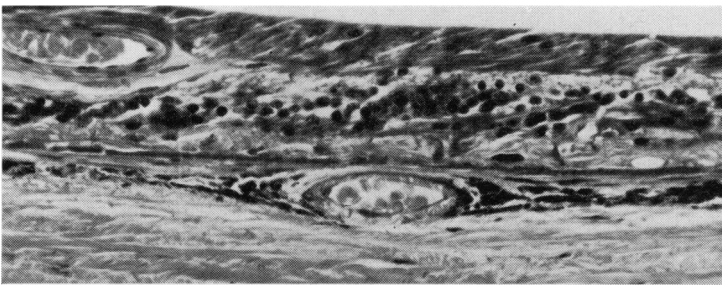


FIG. 3 Case 1. Left eye. Section above the disc in the areas of peripapillary choroidal sclerosis. The choroid is markedly thinned and Bruch's membrane lies almost apposed to the sclera. There is absence of outer retinal layers, retinal pigment epithelium, choriocapillaris, and medium-sized choroidal vessels. A choroidal artery is identified by its internal elastic lamina and shows degeneration of its muscular coat. Picro-Mallory stain. $\times 225$

The white streaks seen in the fundus photograph were identified histologically as vessels and were traced by serial sections. The vessel illustrated in Fig. 4 was sheathed clinically and is recognizable as a degenerate artery by its altered internal elastic lamina. It appears flattened and the lateral

walls are disproportionately thickened. The thickened portion of the wall contains an atrophic media in which muscle cells are no longer visible, and an adventitia which may be derived in part from the choroidal stroma as it contains pigment-laden macrophages. Exposure of the vessel results from loss of the overlying retinal pigment epithelium, choriocapillaris, small choroidal vessels, and pigmented stroma, the vessel occupying the full thickness of the choroid.

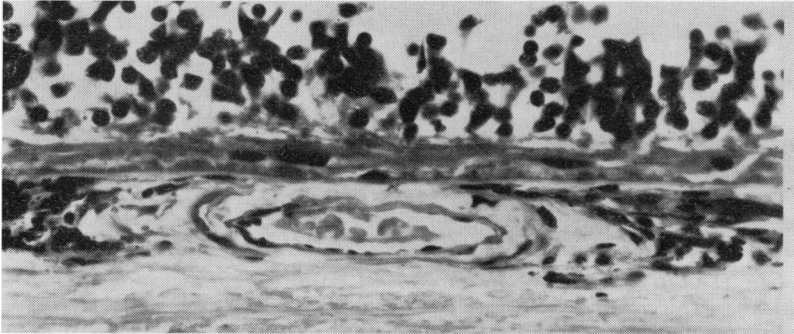


FIG. 4a Case 1. Left eye. Section through choroidal artery which clinically appeared sheathed. The vessel is flattened but occupies the full thickness of the atrophic choroid, and the lateral walls are disproportionately thickened. The media is atrophic and the adventitia contains some pigment-laden macrophages. Note absence of structures normally concealing the larger choroidal vessels, viz. retinal pigment epithelium, choriocapillaris, small choroidal vessels, and pigmented choroidal stroma. Picro-Mallory stain. $\times 400$

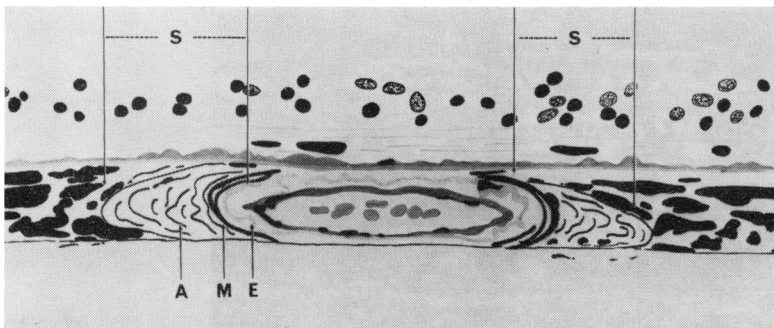


FIG. 4b Diagram illustrating apparent basis of sheathing (S) represented by thickness of lateral walls. A = adventitia, M = media, E = internal elastic lamina

The vessel which did not appear sheathed clinically (Fig. 1) showed only a thin wall separating the blood column from the pigmented choroidal stroma (Fig. 5, overleaf).

The choroid was also thinned beneath areas of relatively normal retina but here the choriocapillaris was intact. At the edges of these persisting islands of choriocapillaris there were larger vessels which were probably telangiectatic capillaries. The residual choroidal stroma was heavily pigmented and fibrosis was marked anterior to the equator. There was no infiltration with inflammatory cells.

BRUCH'S MEMBRANE

This was hyalinized but only slightly thickened and was not calcified. Its outer surface was clearly defined as there was no intercapillary hyalinization of the choriocapillaris. The inner surface presented a serrated appearance because of a continuous row of small colloid bodies (Fig. 6, overleaf).

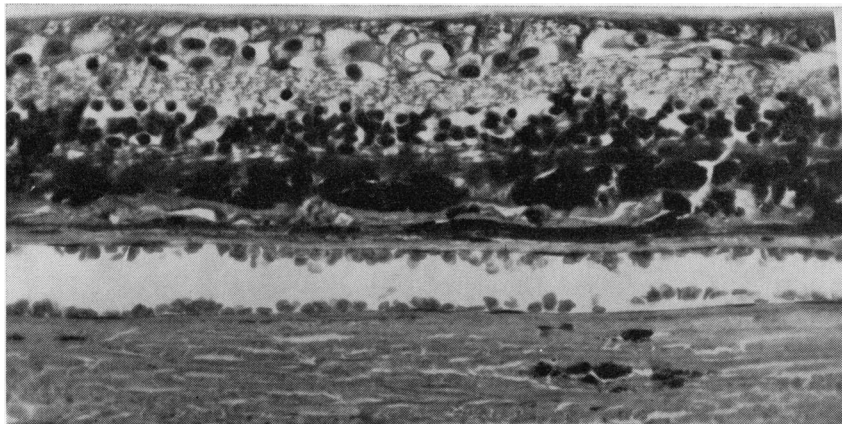


FIG. 5 Case 1. Left eye. Section through choroidal vessels of more normal appearance (Fig. 1, arrow). This section passes through the vessel where it is overlaid by retinal pigment just beyond the limit of the fundus photograph. The vessel occupies the full thickness of the choroid but its lumen is wide and its walls thin. Picro-Mallory stain. $\times 300$

Frozen sections demonstrated that the hyalinized portion of Bruch's membrane and the colloid bodies contained many fat globules. Overlying intact choriocapillaris there were also larger, pale-staining, granular deposits beneath the pigment epithelium, and these corresponded to the ill-defined colloid bodies noted clinically.




FIG. 6 Case 1. Left eye. Section adjacent to the affected temporal zone, showing an island of persistent receptors, choriocapillaris, and a few degenerating retinal pigment cells. The outer surface of Bruch's membrane shows no scalloping or intercapillary hyalinization but the inner surface is covered by an almost continuous row of colloid bodies of varying size (arrow). Picro-Mallory stain. $\times 225$

In the more atrophic regions the hyalinized colloid bodies became larger and more irregular, many containing avascular fibrous tissue without apparent connection with the choroid. Other colloid masses in the periphery were becoming organized by fibrous tissue and capillaries passing through gaps in Bruch's membrane. Above and temporal to the central zone of choroidal sclerosis, a layer of thin-walled capillaries and fibrous tissue arising from the intact choriocapillaris broke through Bruch's membrane and spread along the surface of the membrane over an area of one disc diameter.

RETINA

The peripheral retina showed microcystoid degeneration and here the retinal vessels were grossly sclerosed and their lumina obliterated. The retinal pigment epithelium was intact in an area corresponding to the intervening strip of normal tissue noted clinically. The transition from normal to absent pigment epithelium was abrupt. There was a corresponding disappearance of the choriocapillaris and an increase in size of the colloid material, together with a loss of the outer retinal layers. The outer plexiform layer and scattered groups of nuclei belonging to the outer nuclear layer then lay directly on the colloid material (Fig. 7). Similar changes were noted in other transition zones. Dense clumps of retinal pigment overlaid some of the larger colloid masses.



FIG. 7 Case 1. Left eye. Sections through the nasal edge of the temporal area of choroidal sclerosis showing transitional zone. Note disappearance of choriocapillaris, some increase in size of colloid material, degeneration of retinal pigment epithelium, and loss of outer retinal layers. The choroid is thin even beneath intact retina. Picro-Mallory stain. $\times 150$

OPTIC NERVE

Optic atrophy was apparent with widening of the subarachnoid space. The nerve fibre bundles showed replacement by oligodendrocytes and the pial septa were thickened.

EXTRAOCULAR MUSCLES

Atrophy of muscle cells was apparent with replacement fibrosis. Many of the small vessels were completely fibrosed.

Microscopic appearances of right eye

Marked atrophic changes in the choroid and the attendant disturbances of the overlying tissue were generally similar to those found in the left eye. There was a larger relatively normal area in which the nasal half of the macula was found intact. In the temporal half of the macula the processes of the receptors were distorted and disintegrated, the transition occurring abruptly beneath the fovea and showing the same features as described in the transition zones in the left eye. The right eye also showed large peripheral colloid masses undergoing organization from the choroid but, unlike the left eye, fibrovascular invasion was not in evidence behind the equator.

Case 2, a man aged 83 years, suffering from malnutrition and chronic bronchitis was admitted in June, 1968. He was able to see to get about but had been unable to read for 4 years. A left cataract extraction had been performed in 1958.

The corrected visual acuity in the left eye was 3/60. In the right eye a mature cataract reduced the visual acuity to light perception. Light projection was doubtful.

Clinical appearance of left eye (Fig. 8, overleaf)

The fundus showed a circumscribed area of central choroidal sclerosis measuring 2 disc diameters. The choroidal vessels appeared as tortuous white cords and were prominent in the lower third of the

affected area in which the background between the vessels was also paler than in the upper portion. Between the affected area and the disc the fundus showed scattered colloid bodies and slight pigmentary mottling. A choroidal naevus was noted at the lower temporal margin of the central area. The disc was slightly pale but the retinal vessels appeared normal.

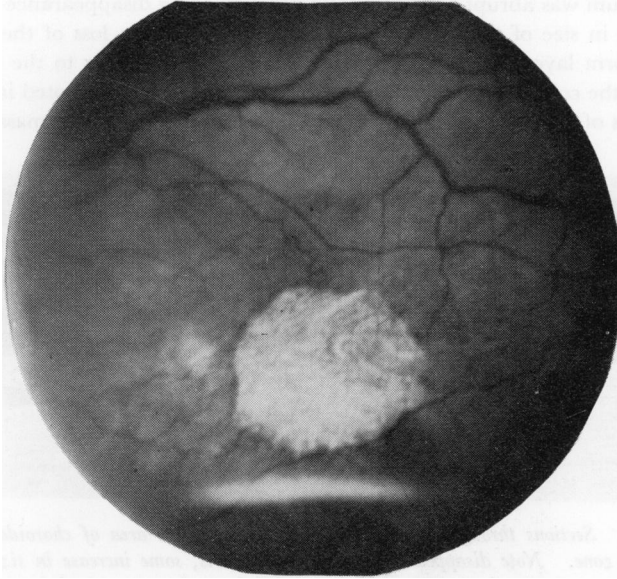


FIG. 8 Case 2. *Left fundus*

The patient was reviewed in December, 1969, when the fundus photograph was taken. The clinical appearance had not altered.

General health

The blood pressure was 140/80 and there were no significant previous illnesses. The patient remained reasonably well except for exacerbations of bronchitis. In March, 1970, he fractured his femur and died 6 weeks later from congestive cardiac failure and lobar pneumonia.

Macroscopic examination

The left eye was aphakic with a complete iridectomy. Over the area of choroidal sclerosis the retina was thinned with a central hole. The patch of choroidal pigmentation was noted adjacent to the lower temporal part of the central area. The other macroscopic changes were consistent with the age of the patient.

The right eye showed a dense brown cataract which was removed before embedding. The peripheral retina showed the usual degenerative changes, microcystoid degeneration extending posteriorly to the equator in relation to thickened inferior temporal vessels. In the posterior fundus there was a circumscribed central area of retinal thinning measuring 2 disc diameters, the surrounding retina showing extensive cystoid degeneration. The choroidal vessels in the central area were prominent and tortuous, and a retinal hole was evident at the macula.

Microscopic appearances of left eye

ANTERIOR SEGMENT

The usual senile changes were evident. An intraepithelial cyst of the corona ciliaris was present and peripheral anterior synechiae were evident in the region of the iridectomy.

POSTERIOR CILIARY ARTERIES AND CHOROID

The posterior ciliary arteries appeared normal for the age of the patient. Anteriorly the choroid showed no remarkable changes. Thinning of the choroid was apparent on the temporal side of the

disc, becoming more pronounced in the central area where the number of large and medium-sized vessels appeared reduced. The remaining choroidal arteries were of wide calibre without intimal proliferation. The media of the arteries showed atrophy of most of the muscle fibres and concentric replacement by fibrous tissue (Fig. 9). The internal elastic lamina was readily identified and adventitial fibrosis was not pronounced.

The choroidal naevus was identified at the edge of the central area and beyond it the choroid appeared normal. As the choriocapillaris was traced posteriorly the degree of intercapillary hyalinization gradually increased, and within the affected area there was patchy obliteration of this layer.




FIG. 9 *Case 2. Left eye. Section through macular region. There is patchy obliteration of the choriocapillaris and reduction in the number of medium-sized vessels, the larger vessels occupying the full thickness of the choroid. The arteries show the customary ageing changes of fibrous replacement of the media and widening of the lumina. A layer of fibrous tissue lies on Bruch's membrane. Picro-Mallory stain. $\times 90$*

BRUCH'S MEMBRANE

Towards the posterior pole the membrane showed progressive thickening, hyalinization, and scalloping. Scattered globular colloid bodies lay on the membrane. In the upper temporal part of the affected area fibrovascular tissue from the choroid passed through a gap in the membrane. This extended as a thin sheet along the surface of Bruch's membrane over the upper two-thirds of the central area, becoming thicker on the temporal side where it passed beneath the pigment epithelium for a short distance. Foci of calcification were noted in the fibrous tissue. Overlying the fibrous tissue was a thick layer of finely granular, periodic acid-Schiff positive material, becoming thinner as it was traced outwards beneath the pigment epithelium.

RETINA

Peripheral microcystoid degeneration was present. The remainder of the retina was generally normal but where the finely granular material was present beneath the pigment epithelium the overlying receptors showed degenerative changes. In the central area itself the retina was thinned and at the macula it almost disappeared entirely. The retinal pigment epithelium was similarly absent over the central area and showed proliferative changes around the margin, some attenuation of this layer extending as far as the disc.

Microscopic appearances of right eye

POSTERIOR CILIARY ARTERIES AND CHOROID

The posterior ciliary vessels and the choroid were generally similar to the left eye. In the central area where a retinal hole was present the choroid was thinned. The larger choroidal vessels were not noticeably different in this area and showed changes consistent with the age of the patient. There was patchy obliteration of the choriocapillaris beneath the retinal hole (Fig. 10, overleaf).

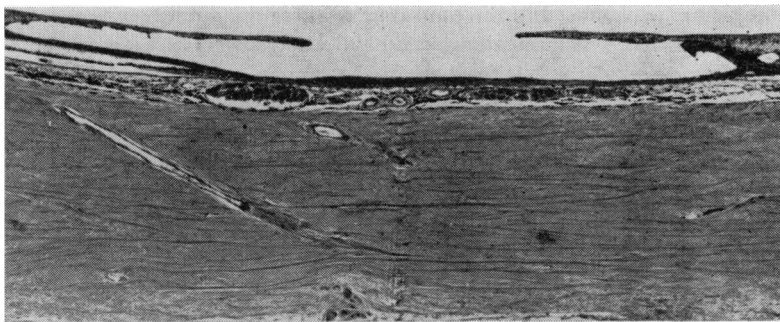


FIG. 10 *Case 2. Right eye. Section through macular hole. Picro-Mallory stain. $\times 45$*

BRUCH'S MEMBRANE

This showed thickening, scalloping, and patchy basophilia. Globular colloid bodies and a few pale-staining granular deposits containing calcium were scattered on the surface of the membrane. Fibrovascular tissue passed through the membrane under the nasal part of the retinal hole and extended for a short distance beneath the pigment epithelium towards the disc.

A thin, discontinuous layer of finely granular, periodic acid Schiff positive material overlaid the fibrous tissue.

RETINA

The retinal vessels differed from the left eye in being grossly sclerosed and in the periphery many were obliterated and surrounded by pigment. New vessel formation consistent with an old retinal vein occlusion was noted at the disc. Microcystoid degeneration of the retina was widespread. These cysts lay in the outer plexiform layer, becoming larger towards the posterior pole and coalescing at the macula to form an extensive split over which the inner lamella had disappeared. The rods and cones were intact where the microcystoid degeneration was minimal but disappeared over the fibrovascular tissue. The retinal pigment epithelium was absent in the central area but showed proliferative changes at the edges of the hole. A thin layer of the finely granular periodic acid Schiff positive material extended a short distance beneath the pigment epithelium beyond the margins of the hole.

Discussion

The visibility of the choroidal circulation varies among normal individuals mainly with the intensity of fundus pigmentation (Rutnin, 1967), while regional differences occur in the same eye according to the density of retinal pigment and the thickness of the choroid. The choroidal vessels are normally obscured at the macula where the retinal pigment cells are taller, and are most readily seen in the periphery where the choroid is thinner. It has therefore been suggested that the clinical picture of choroidal sclerosis results from loss of the pigment epithelial screen and atrophy of the choroid, but it has not been clear to what extent changes in the vessel walls themselves contribute to the picture. The patients with heredodegenerative choroidal sclerosis described by Ashton (1953) and Howard and Wolf (1964) were both women aged 56 suffering from hypertension and cardiovascular disease. They showed only the degree of choroidal angiosclerosis expected for their ages while Babel (1958) reported that his 70-year-old male patient had moderately sclerosed choroidal vessels.

The two cases under discussion are thus of interest in that they showed histological differences in choroidal vessels which presented a similar clinical picture of angiosclerosis.

Case 1 showed generalized choroidal sclerosis while in Case 2 the disease was localized to the central area. In both cases the posterior ciliary arteries appeared normal for the age of the patients. In Case 1 none of the choroidal vessels were of normal appearance, even the earliest choroidal branches of the posterior ciliary arteries showing atrophy of their muscular coats without fibrous replacement. In some arteries the atrophic media was surrounded by fibrous tissue of oedematous appearance, but often arteries could be distinguished from veins only by finding the remains of a degenerate internal elastic lamina. The vessels were flattened in the atrophic choroid and their calibre diminished, the lateral walls appearing disproportionately thickened whereas the anterior and posterior walls were correspondingly thinned. In Case 2 the calibre of the vessels was wide and by comparison with the lumen the walls were not thickened. Concentric fibrous replacement of the media was evident, but some muscle fibres remained recognizable, and adventitial fibrosis was not pronounced. In neither case was subintimal fibrosis observed. In both cases the white streaks seen clinically represented the remaining large vessels which occupied the full thickness of the choroid and lay directly upon the sclera. All such vessels seen clinically have been demonstrated to fill with fluorescein (Archer, Krill, and Newell, 1971).

The appearance of sheathing of the vessels has previously been ascribed to localized exsanguinity, perivascular exudates or fibrosis, as described by Ashton (1953), or white deposits derived from the pigment epithelium (Archer and others, 1971). Fig. 4a represents a blood vessel from Case 1 which appeared to be sheathed clinically. From the diagram it is apparent that sheathing of the blood column is represented by the vessel wall itself which extends up to the pigmented choroidal stroma and is rendered visible ophthalmoscopically by the absence of overlying structures. By comparison, a vessel (Fig. 1) in which the blood column did not appear sheathed showed only a thin wall (Fig. 5).

The two patients showed corresponding differences in the manner in which the choriocapillaris was involved. In Case 1 there was total disappearance of the capillaries in the affected areas, and no thickening or scalloping of the outer surface of Bruch's membrane. In Case 2 the customary ageing change of intercapillary hyalinization was pronounced, resulting in patchy obliteration of the capillary bed in the central area. Vessels resembling telangiectatic capillaries were noted at the margin of many of the affected areas where leakage of fluorescein has also been reported (Archer and others, 1971).

Bruch's membrane

In the previously reported cases only Babel's older patient showed significant abnormality of Bruch's membrane. In the two cases under discussion there was marked disturbance at the level of this membrane, Case 1 in particular showing an almost continuous formation of colloid bodies. There were also pale-staining granular deposits overlying areas of intact choriocapillaris, and these corresponded to the ill-defined yellow colloid bodies noted clinically. Case 2 also showed a continuous layer of finely granular periodic acid-Schiff positive material overlying the central area and extending beyond it beneath the pigment epithelium. Both eyes of Case 2 showed an extensive fibrovascular sheet arising from the choroid and breaking through the membrane in the central region.

Case 1 also showed such a sheet at the edge of the central zone of choroidal sclerosis in the left eye.

Distribution of choroidal sclerosis

The absence of retinal pigment epithelium most closely accounted for the distribution of the sclerotic areas. Where it was noted ophthalmoscopically that the affected areas were outlined by a dark border, the pigment epithelium was found to terminate with proliferation, and where the edges were ill-defined there was more evidence of cellular degeneration overlying an extension of the finely granular material. It was apparent that the colloid bodies, the fine granular layer, and the fibrovascular tissue did not correspond closely with the distribution of the sclerotic zones.

It has been suggested that the circumscribed distribution results from occlusion of one or more of the short posterior ciliary arteries. However, Ashton (1953) carefully dissected these vessels in the orbit without demonstrating any occlusion, and the present cases also failed to reveal any such occlusion within the sclera or immediately behind the eye. Archer and others (1971) have also demonstrated that the circulation time for fluorescein to appear in the retinal and choroidal arteries was in the normal range.

Comments

Sorsby (1939) first observed that choroidal sclerosis may be genetically determined and may commence in early adult life, although the typical clinical appearance is often not fully developed until the sixth decade or later. Hereditary patterns are not always evident, however, and in later years such a choroidal dystrophy becomes increasingly difficult to distinguish from choroidal atrophy secondary to arteriosclerosis. Krill and Archer (1971) preferred to avoid the term dystrophy and to call all these conditions the choroidal atrophies, grouping them according to the extent of fundus involvement and the degree of choroidal atrophy: *i.e.* choriocapillaris only or total choroidal atrophy.

In Case 1 there was atrophy of all elements of the choroid with the possible exception of the chromatophores. Yet, despite the advanced age of the patient, this generalized form of the condition showed no predilection for the macula and vision in the right eye remained 6/6. The choroid was also atrophic in areas of patent choriocapillaris and normal retina, suggesting that atrophy of the choroid commences before the choriocapillaris disappears. Atrophy of the choroid may therefore be partial or total as described by Krill and Archer (1971), but it was not possible to confirm atrophy of the choriocapillaris alone.

Case 2 presented a localized area of choroidal atrophy in which were exposed vessels of large calibre. The vessels showed the customary changes of old age. Narrowing of the lumen was observed only in the retinal vessels of the right eye in which new vessel formation suggested a retinal vein occlusion. The retinoschisis and lamellar macular hole were probably secondary to this interference with the retinal circulation.

Conclusion

The two cases described confirm that the clinical picture of senile choroidal sclerosis does not reflect the degree of arteriosclerosis of the vessels. The white streaks corresponded in Case 1 to vessels showing predominantly atrophy without fibrous replacement of the media. The vessels had taken part in the universal atrophy of the choroid and their ability to function appeared correspondingly reduced. In Case 2 the white streaks corresponded to vessels showing the customary ageing changes of replacement fibrosis and relatively wide lumina. There was patchy loss of the choriocapillaris and the histological findings suggested a secondary senile macular degeneration (Klien, 1951). Exposure of the larger vessels resulted from loss of the overlying retinal pigment epithelium,

choriocapillaris, medium-sized choroidal vessels, and pigmented choroidal stroma. The vessels occupied the full thickness of the atrophic choroid and the thinning of the choroid appeared to be the most important single factor contributing to the increased prominence of the vessels.

Summary

The eyes of two elderly patients suffering from choroidal sclerosis were examined clinically and pathologically. The distribution of the process was generalized in the first case and confined to the central area in the second.

The histological findings are described and the basis for the greater prominence of the vessels and for the appearance of sheathing is discussed. In the first, atrophy of the choroid affected all elements including the blood vessels, while in the second case the atrophy of the choroid was associated with normal ageing changes in the blood vessels. The two cases confirm that the clinical picture of senile choroidal sclerosis is dependent on choroidal atrophy and does not reflect the degree of arteriosclerosis.

I am indebted to Associate Professor A. Tait Smith, Department of Pathology, Prince Henry Hospital, Sydney, for his advice and encouragement. I also wish to thank Mr. L. Vorbach and Mrs. E. King for their technical assistance and the Department of Medical Illustration, Prince of Wales Hospital, Sydney, for the photomicrographs.

This work was supported in part by the Unit of Clinical Investigation, Lidcombe Hospital, Sydney, and a Grant from the Ophthalmic Research Institute of Australia. The views expressed in this paper are those of the author and not necessarily those of the Institute. Permission to publish this paper was given by the Superintendent of Lidcombe Hospital.

References

- ARCHER, D., KRILL, A. E., and NEWELL, F. W. (1971) *Amer. J. Ophthalm.*, **71**, 266
 ASHTON, N. (1953) *Brit. J. Ophthalm.*, **37**, 140
 BABEL, J. (1958) *Bull. Soc. franç. Ophtal.*, **71**, 389
 COHEN, M. (1938) *Arch. Ophthalm. (Chicago)*, **19**, 487
 FERRY, A. P., LLOVERA, I., and SHAFER, D. M., (1972) *Ibid.*, **88**, 39
 HOWARD, G. M., and WOLF, E. (1964) *Trans. Amer. Acad. Ophthalm. Otolaryng.*, **68**, 647
 KLIEN, B. A. (1951) *Amer. J. Ophthalm.*, **34**, 1279
 KRILL, A. E., and ARCHER, D. (1971) *Ibid.*, **72**, 562
 MORTON, A. A. (1885) *Trans. ophthalm. Soc. U.K.*, **5**, 142
 NETTLESHIP, E. (1884) *Ibid.*, **4**, 165
 RUTNIN, U. (1967) *Amer. J. Ophthalm.*, **64**, 821
 SORSBY, A. (1939) *Brit. J. Ophthalm.*, **23**, 433

ADDENDUM

Since this Paper was accepted for publication a further pathological examination has been reported in an eye removed for thrombotic glaucoma in which the fundus could not be seen (Ferry, Llovera, and Shafer, 1972). The patient was a 76-year-old man whose other eye showed a central area of choroidal sclerosis. His 84-year-old sister was stated to have similar macular lesions in both eyes.

The pathological findings were similar to those in the three cases hitherto reported.