

Scleromalacia perforans associated with Crohn's disease

Treated with sodium versenate (EDTA)

THE LATE P. JAMESON EVANS AND P. EUSTACE

Birmingham and Midland Eye Hospital

Scleromalacia perforans is most frequently associated with rheumatoid arthritis. A necrotizing nodular scleritis proceeding to scleromalacia perforans is sometimes seen in the collagen disorders systemic lupus erythematosus, periarteritis nodosa, and Wegener's granulomatosis. Rarely scleromalacia has been described in porphyria and herpes zoster (Duke-Elder and Leigh 1965; François, 1951).

The following case is presented as the first report of scleromalacia perforans associated with Crohn's disease. An additional feature which prompted this report was the beneficial result obtained from the topical application, as an anticollagenase, of sodium versenate (EDTA).

Case report

The patient, a frail woman aged 63 years, was in poor physical condition and weighed only 5 stone (31.75 kg.).

For more than 10 years she had been treated for arthritis which affected her knees most severely. In 1968 she had a period of diarrhoea and at that time a barium enema was given: the colon was reported to be normal.

In September, 1971, her health had deteriorated and she was emaciated from chronic diarrhoea; for 2 weeks she had been unable to walk.

She was referred to the ophthalmic department of the United Birmingham Hospitals on account of conjunctivitis, and was admitted for investigation on October 8, 1971, her ocular complaint being of watering of the eyes. On account of her poor general condition the advice was sought of a consultant physician (Dr. Clifford Hawkins).

Examination

She was emaciated and anaemic, bedridden, with severe arthropathy affecting her knees (Fig. 1) and hips, and with an anal fistula. An extensive series of investigations was initiated by Dr. Clifford Hawkins, the relevant ones being shown below:

Blood profile

	Hb per cent.	Packed cell volume	Mean corpuscular haemoglobin concentration	Red cell count	Mean corpuscular volume	E.S.R. mm./ 1st hr	Platelets
October 1, 1971	8.5	28	30	3.3	0.84	70	429
November 29, 1971	14.3	45	32	5.3	0.85	8	219

Rheumatoid arthritis tests

Sheep cell agglutination	Negative
Latex slide	Negative
Fluorescent antinuclear	Negative

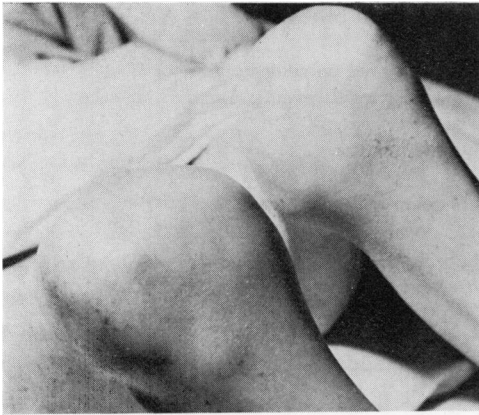


FIG. 1 *Arthropathy affecting knees*

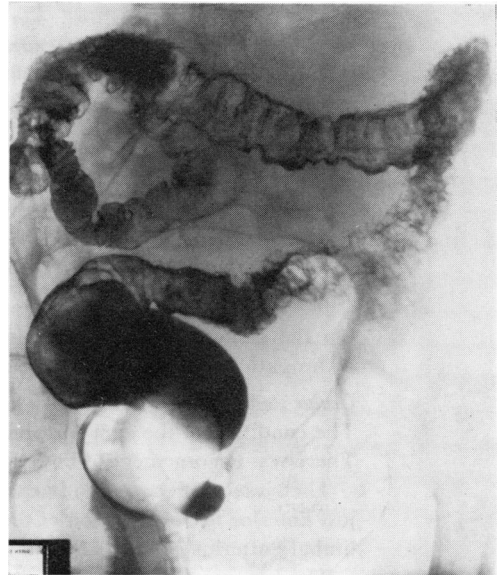


FIG. 2 *Barium enema, showing features of Crohn's disease*

Radiology

ABDOMEN (8.II.71)

There is a scoliosis, probably secondary to the right hip pathology.
The barium sulphate remains in the anal fissure.
No other lesion seen

HANDS (8.II.71)

There is slight soft tissue swelling around the proximal phalangeal and metacarpophalangeal joints.
No lesions specific of rheumatoid arthritis seen

HIPS (18.I0.71)

The left femoral head has been almost completely destroyed and the acetabulum is extensively eroded.
The right hip joint space is reduced and the acetabular roof is eroded.
The sacroiliac joints appear normal

KNEES (18.I0.71)

Both knee joints are symmetrically involved with loss of joint space, articular erosions, particularly in the lateral compartment, and periarticular osteoporosis

BARIUM ENEMA (13.I0.71)

The large bowel is shortened and its haustral pattern absent.
There is a 'thumb print' irregularity of its wall extending from the sigmoid region to the caecum. There is a very deep fissure demonstrated in the sigmoid area which must penetrate a very thick wall.
The appearances are those of Crohn's disease of the large bowel.
The terminal ileum appears normal (Fig. 2).

In the later films, barium passes through what must be the known anal fissure, and spreads thinly between layers of the rectal wall. This suggests that very little granuloma is present in this lesion. The rectum otherwise appeared normal.

A barium follow-through is advised

BARIUM MEAL AND FOLLOW-THROUGH (27.I0.71)

No evidence found of a granulomatous enteritis of the small intestine.
The oesophagus, stomach, and duodenum are also normal, apart from the scar of an old duodenal ulcer now healed

Biopsies

RECTAL BIOPSIES at 15 × 10 cm. were not significantly abnormal

COLONIC BIOPSIES (31.II.71) showed non-specific features of chronic inflammation

COLONOSCOPY TO 100 CM. (29.11.71) (Dr. Clifford Hawkins)

- (1) Sigmoid: somewhat red and friable
- (2) Lower descending: relatively normal with scattered polypi granulomata
- (3) Upper descending: many discrete ulcers with generalised inflammation between
- (4) Transverse: patchy inflammation with scattered polypi
- (5) Ascending: near hepatic flexure patchy inflammation
- (6) Caecum: normal

Assorted biopsies were taken from all levels of colon and several polypi

SIGMOIDOSCOPY

Appearance of normal rectum becoming abnormal higher up is suggestive of Crohn's disease

Diagnosis

On the strength of these investigations, a diagnosis of Crohn's disease complicated by anaemia, arthropathy, and scleromalacia perforans was made.

Ocular state (8.10.71)

The condition of the eyes was that of bilateral scleromalacia perforans, with watering but no pain. There was engorgement of both conjunctival and episcleral vessels.

The visual acuity was 6/9 in each eye. The right eye had a deep oval ulcer of the sclera, situated just anterior to the insertion of the external rectus. The cornea was clear but there was an area of limbal guttering to the temporal side (Fig. 3).

The left eye showed two smaller punched-out scleral holes, one above the other, in front of the insertion of the external rectus, and there were two areas of limbal guttering, but no invasion of the cornea by new vessels (Fig. 4).

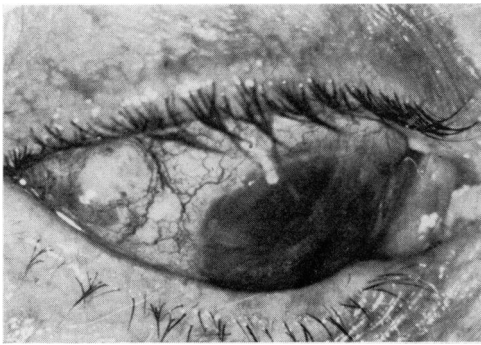


FIG. 3 Right eye, showing scleromalacia perforans preoperatively

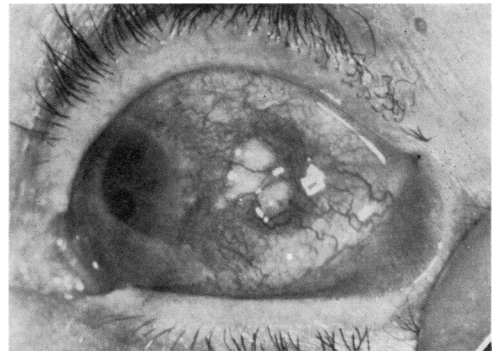


FIG. 4 Left eye before treatment with EDTA drops

Treatment

(16.10.71) A subconjunctival injection of 300 ml. heparin was given to each eye.

(20.10.71) As there was no improvement and the scleral ulcers increased in size and depth, it was decided to do a scleral graft on the right eye, in which there was a threat of perforation, and to cover the graft with a conjunctival flap, and to apply drops of EDTA solution (0.5 per cent.) 4-hourly to both eyes.

On 22.10.71 a 7 mm. scleral graft was applied, after trephination of the punched-out scleral ulcer, just anterior to the insertion of the lateral rectus, the area being covered with a conjunctival flap (Fig. 5, overleaf).

Excised ocular tissue: PATHOLOGICAL REPORT (Dr. R. Barry)

Microscopy (19.11.71). The tissue is covered by epithelium of conjunctival type: in the centre this epithelium represents the whole thickness of the specimen. At the edges there is thicker tissue containing scleral lamellae infiltrated with histiocytes and chronic inflammatory cells, along with

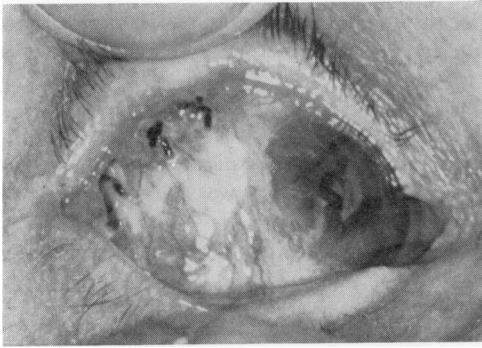

FIG. 5 *Right eye immediately after operation*

plasma cells; lymphocytes, neutrophils, and a few eosinophils can be identified. Areas of necrosis and haemorrhage are also present. The histological pattern is not truly specific of the rheumatoid nodule, but the picture seems consistent with scleromalacia perforans associated with rheumatoid arthritis.

Post-operative course with topical treatment—EDTA 0.5 per cent. solution drops four times a day. The improvement in both eyes was dramatic. In 3 days the conjunctival congestion had disappeared, and in a week the punched-out scleral defects were filling in and the limbal guttering becoming less. Systemic treatment with steroids was commenced 3 weeks after operation (Figs 6 and 7).

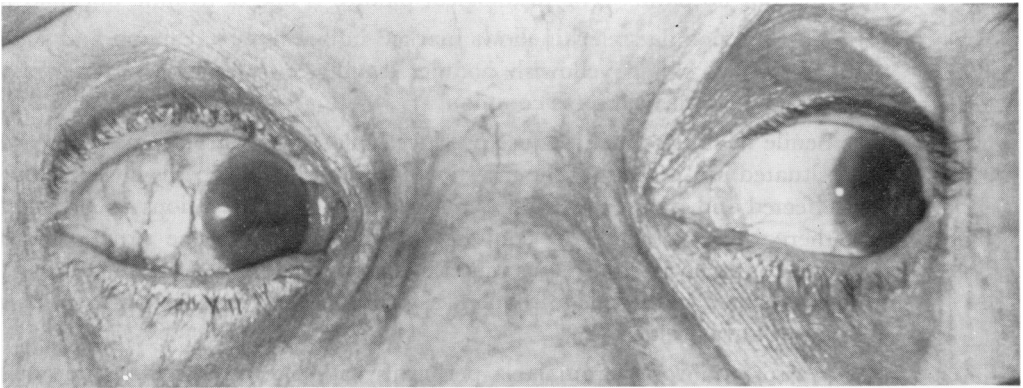


FIG. 6 *Right eye 3 weeks postoperatively, showing graft in good apposition*

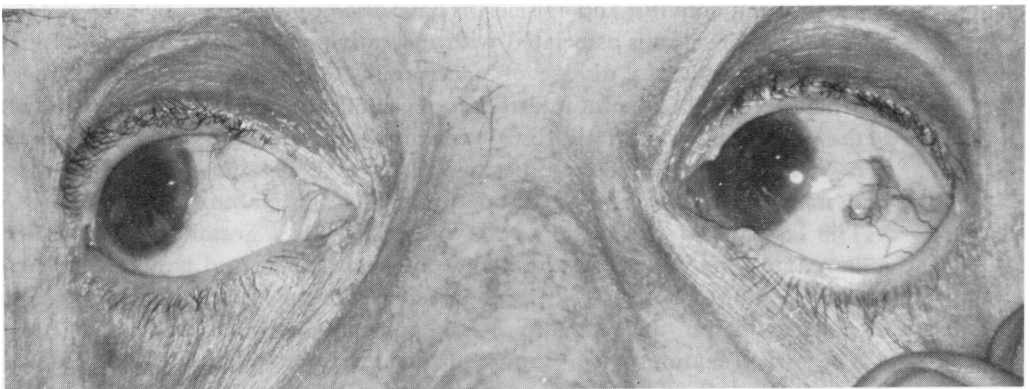


FIG. 7 *Left eye after 3 weeks' treatment with EDTA, showing scleral defects filled in*

A careful watch on the eyes was kept, in case of signs of deterioration. Progress, however, was well maintained and at discharge there was no sign of graft rejection, both eyes being quiet, and in the left eye almost all the scleral defect had filled in.

Progress

The patient's general state improved dramatically with adequate dietary management and on 14.11.71 treatment with prednisolone 10 mg. three times daily was commenced. At discharge her weight was 36 kg.—a gain of 4.25 kg. and the Hb had risen to 14.3 g. per cent.

She was transferred to an orthopaedic hospital for further management of her incapacitating arthritis.

Discussion

Scleromalacia perforans is uncommon in West European countries. It has most frequently been reported in association with rheumatoid arthritis, but also with porphyria and herpes zoster, and a necrotizing nodular scleritis has been described in the collagen disorders, systemic lupus erythematosus, periarteritis nodosa, and Wegener's granulomatosis (Duke-Elder and Leigh 1965).

François (1951) distinguished three groups of spontaneous scleral degeneration.

(1) Associated with diffuse rheumatoid arthritis and perhaps with pemphigoid degeneration of the conjunctiva which is only slightly congested. There is mild discomfort and watering but no pain. The histological picture is one of hyaline fibrinoid necrosis.

(2) Necrotic nodular scleritis shows marked inflammatory reaction and is painful. The plaques start as raised yellowish nodules leaving, on absorption, a series of punched-out holes. Corneal infiltration is common.

(3) Senile hyaline scleral plaques produce hollowed-out greyish patches, possibly coalescing, situated just in front of the insertion of the horizontal rectus muscles: the conjunctiva is unaffected and scleral ectasia does not occur. The excavations do not reach the limbus and there is no episcleral or conjunctival hyperaemia. The situation in front of the insertion of the horizontal rectus muscles is ascribed to muscular traction or, more likely, to local ischaemia: there is a frequent association with rheumatoid arthritis and patients are almost always elderly.

The association of scleromalacia perforans with Crohn's disease is one which does not appear to have been noted previously, although uveitis has been reported in 2 per cent. of patients with Crohn's disease (Korelitz and Coles, 1967). Corneal ulceration, marginal keratitis, conjunctivitis, and episcleritis have also been reported by Ellis and Gentry (1964), and one case of scleritis associated with ulcerative colitis was referred to by Hurst (1935).

Crohn's disease is a disease of uncertain aetiology, primarily affecting the gut and characterized by segmental infiltration of granulomatous and fibrous tissue into all layers of the bowel wall. When the disease is mainly confined to the colon, as in the case reported here, it is difficult to diagnose because of its close resemblance to ulcerative colitis, and both may be complicated by arthropathy and uveitis (Hammer, Ashurst, and Naish, 1968).

The histological picture in Crohn's disease is of a granulomatous rather than of an inflammatory nature, whereas polymorphs, eosinophils, and lymphocytes predominate in ulcerative colitis (Lockhart-Mummery and Morson, 1964). It is interesting that the scleral specimen in this case also showed granulomatous features.

The second feature which prompted this report was the favourable clinical response to the topical application of sodium versenate (EDTA). The rationale behind the use of EDTA is explained in the following paragraphs.

The sclera is one of a number of tissues composed almost entirely of collagen, likewise its extension as the substantia propria of the cornea. Other tissues of a basically collagen composition are the synovial membranes of the joints, the skin, and the walls of the arteries, and the presence of an enzyme collagenase has been demonstrated in synovial tissues by Evanson, Jeffrey, and Krane (1967).

The influence of a collagenolytic enzyme was investigated by Itoi, Gnadinger, Slansky, Freeman, and Dohlman (1969), who demonstrated it in bovine cornea, and in alkali burns of the cornea by Brown, Akiya, and Weller (1969). McCulley, Slansky, Pavan-Langston, and Dohlman (1970) found the same enzyme in increased concentration, compared to controls, in rabbits with experimentally-induced herpes simplex of the cornea, and postulated that this prevented healing.

It was further shown that the collagenase activity could be inhibited by the topical application of sodium versenate (EDTA) and that this was effective in the treatment also of alkali burns of the cornea.

Pseudomonas pyocyanus has also been shown to produce an enzyme with collagenolytic activity which is inhibited by Na₂EDTA. Wilson (1970) has demonstrated a marked therapeutic response to this substance in rabbits after the corneae had been injected with collagenase produced by *Pseudomonas pyocyanus*. It has been postulated that collagenases are calcium dependent, hence the rationale of using a chelating substance to inhibit their action.

It was on the basis of this work that it was decided to treat the present case with EDTA.

Summary

A case of Crohn's disease, complicated by anaemia, arthropathy, and scleromalacia perforans, is described. Solution of sodium versenate (EDTA) was applied topically in 0.5 per cent. drops four times a day as an anticollagenase. Beneficial results from this form of treatment were obtained.

References

- BROWN, S. I., AKIYA, S., and WELLER, C. A. (1969) *Arch. Ophthalm. (Chicago)*, **82**, 95
- DUKE-ELDER, S., and LEIGH, A. G. (1965) "System of Ophthalmology", vol. 8, Pt. II, p. 1098. Kimpton, London
- ELLIS, P. P., and GENTRY, J. H. (1964) *Amer. J. Ophthalm.*, **58**, 779
- EVANSON, J. M., JEFFERY, J. J., and KRANE, S. M. (1967) *Science*, **158**, 499
- FRANÇOIS, J. (1951) *Trans. ophthalm. Soc. U.K.*, **71**, 61
- HAMMER, B., ASHURST, P., and NAISH, J. (1968) *Gut*, **9**, 17
- HURST, A. F. (1935) *Lancet*, **2**, 1194
- ITOI, M., GNÄDINGER, M. C., SLANSKY, H. H., FREEMAN, M. I., and DOHLMAN, C. H. (1969) *Exp. Eye Res.*, **8**, 368
- KORELITZ, B. I., and COLES, R. S. (1967) *Gastroenterology*, **52**, 78
- LOCKHART-MUMMERY, H. E., and MORSON, B. C. (1964) *Gut*, **5**, 493
- MCCULLEY, C. J. P., SLANSKY, H. H., PAVAN-LANGSTON, D., and DOHLMAN, C. H. (1970) *Arch. Ophthalm. (Chicago)*, **84**, 516
- WILSON, L. A. (1970) *Brit. J. Ophthalm.*, **54**, 587