

Communications

Cystic disorders of the corneal epithelium

I. Clinical aspects

A. J. BRON AND R. C. TRIPATHI

From the Departments of Clinical Ophthalmology and Pathology, Institute of Ophthalmology, University of London

Epithelial cysts are commonly encountered in corneal disease, either as an essential component of the disease picture or as an associated finding.

This paper deals with the clinical manifestations of cysts with an emphasis on the methods of examination in various corneal disorders. A classification of cystic disorders of the corneal epithelium is presented in Table 1.

Table 1 *Classification of cystic disorders of the corneal epithelium*

-
- (1) Hydrokeratopathy
 - (2) Meesmann's dystrophy
 - (3) Recurrent erosion
 - (4) Cogan's microcystic dystrophy
 - (5) Other disorders
 - (a) Idiopathic cysts
 - (b) Pannus
 - (c) Virus keratitis
 - (d) Cystic epithelial keratopathy
-

Material and methods

The findings reported in this paper are based on the study of over ten patients with hydrokeratopathy, two with Meesmann's dystrophy, over fifty with recurrent erosion, four with Cogan's epithelial microcystic dystrophy, and a number of patients with miscellaneous ocular disorders.

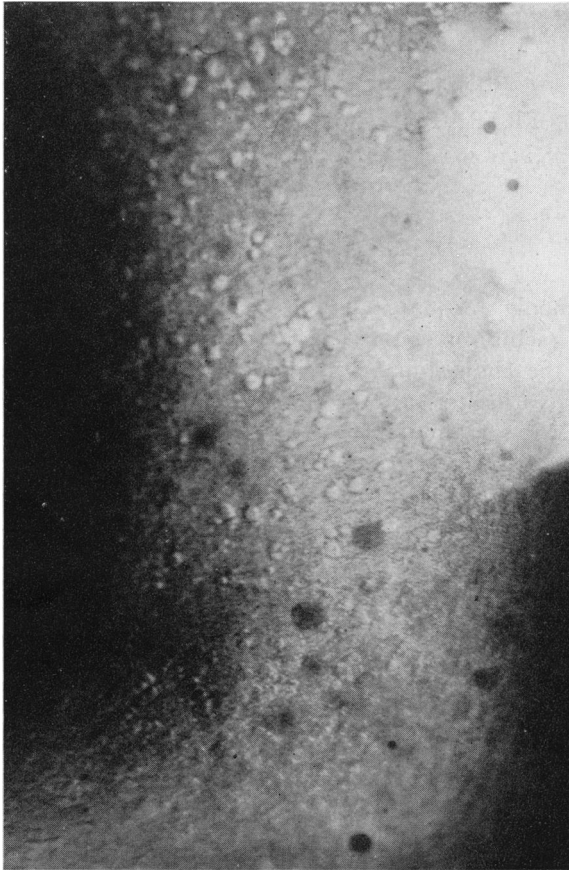
Patients were examined with the Haag-Streit 900 and Zeiss slit lamps. Macrophotographs were taken with the equipment designed by N. Brown (1970). This provides a magnification on film of $\times 10$.

2 per cent. fluorescein sodium and 1 per cent. rose bengal were used as vital stains.

HYDROKERATOPATHY

The term hydrokeratopathy will be used to define a state of corneal oedema due to endothelial dysfunction.

The term is preferable to 'bullous keratopathy' which does not permit a distinction between clinical grades of oedema. Three clinical grades of epithelial oedema may be found in association with hydrokeratopathy. The mildest degree of epithelial oedema gives rise to the appearance of epithelial bedewing, when a fine patina may be observed in the epithelium by retroillumination. An intermediate grade is that of vesicular keratopathy, in which many tiny vesicles or cysts appear distributed throughout the oedematous epithelium (Fig. 1). With further oedema bullous keratopathy



supervenes, characterized by large dome-shaped elevations of the corneal epithelium, which may measure many millimetres across (Duke-Elder and Leigh, 1965a). These bullae are usually due to a detachment of the epithelium from the underlying Bowman's layer of the stroma (Kenyon, 1969), but pathological studies (Tripathi and Bron, 1973) show that they may sometimes arise as intraepithelial collections of fluid.

Depending on the distribution and severity of the endothelial disorder, all degrees of hydrokeratopathy may exist together in the same cornea. It is usual, in fact, for bullae to arise within zones of vesicular oedema. The individual vesicles or cysts are clear and roughly globular in shape. Measurement from photographs indicates a variation in diameter between 20 and 75 μ . Fused cysts also occur, the largest of which are some hundreds of microns long. The clarity of these cysts as seen by retro-illumination suggests an absence of debris within them, and since the epithelium

FIG. 1 *Hydrokeratopathy in a corneal graft. Vesicular epithelial oedema*

between the cysts appears cloudy in focal illumination, or more particularly on scleral scatter illumination, the cysts appear as clear zones in a relatively opaque ground. Other cystic conditions also show this change.

Another feature which may be seen is due to the focal expansion of the epithelium by the cysts. This causes a thinning of the tear-film overlying the cysts which may be observed in the specular reflection or, with fluorescein in the tear-film, as dark zones in the fluorescent film. The use of fluorescein also demonstrates that the dye is taken up into the substance of many cysts. It is this staining within the cysts which accounts for the major part of the punctate staining with fluorescein in vesicular keratopathy and not punctate erosions. Fluorescein uptake by epithelial cysts, whatever their cause, results in a particularly brilliant fluorescence. Some cysts take up stain immediately and others more slowly over a matter of seconds. The full intensity of the fluorescence may take up to a minute to develop. Bullae may take up stain extremely slowly and the luminosity of the fluorescein within them never reaches a high level.

Meesmann's corneal dystrophy

Meesmann's epithelial corneal dystrophy may be recognized in the first few months of life as a bilateral corneal disorder, associated in some families with mild irritative and visual symptoms affecting older members (Burns, 1968). Occasionally, the visual deterioration may be sufficient to warrant keratoplasty. It is inherited as a dominant trait. Epithelial cysts, appearing as tiny punctate opacities in the focal beam of the slit lamp, are profusely distributed in the interpalpebral zone of the cornea (Fig. 2) and with

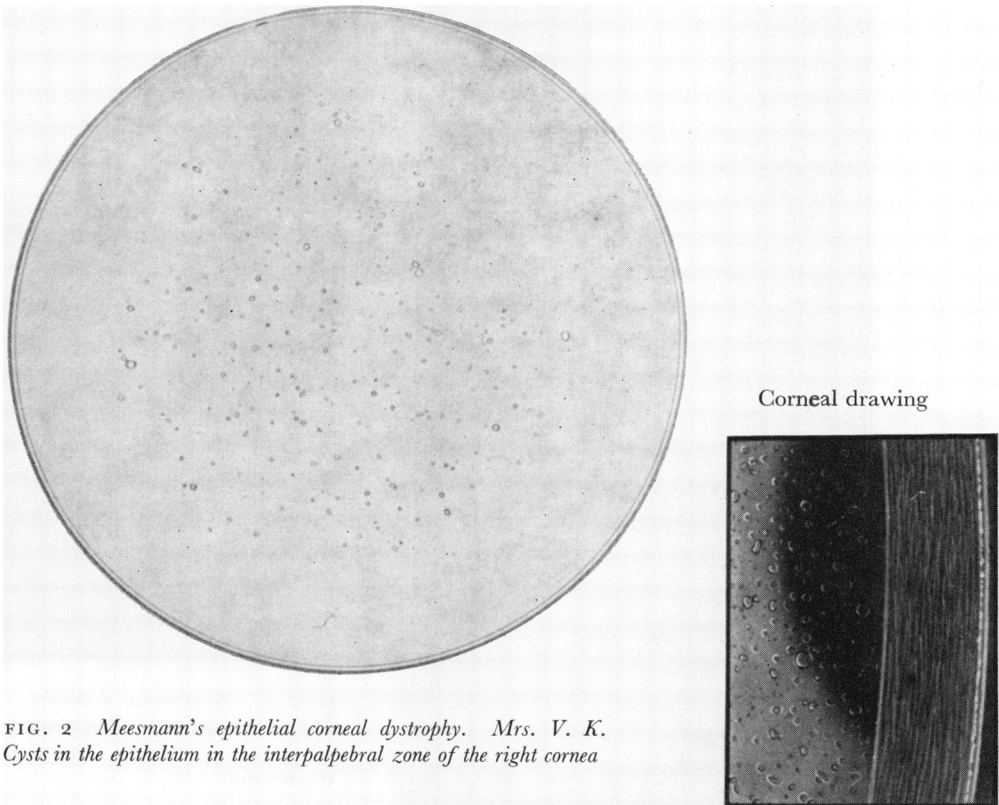


FIG. 2 *Meesmann's epithelial corneal dystrophy. Mrs. V. K. Cysts in the epithelium in the interpalpebral zone of the right cornea*

time the whole epithelium may be diffusely affected. Sometimes a whorl-shaped pattern is seen (Paufigue and Étienne, 1950) and opacities at the level of Bowman's membrane occur. Examination by focal illumination demonstrates mainly the debris within the cysts. This is small in proportion to the volume of the cysts themselves, so that the cysts seem like minute white flecks on focal illumination, but much larger on retroillumination when the full dimensions of the cysts may be appreciated. The cysts of Meesmann's dystrophy are the most regular, both in size and shape, of those under discussion (Fig. 3). They are mainly spherical, occasionally fused, and vary in diameter from 10 to 50 μ . The epithelium as a whole does not appear oedematous, although a slight haze may be seen between cysts. Like the cysts associated with hydrokeratopathy, some but not all of them take up fluorescein dye. Again, there is a variable rate of uptake of dye from cyst to cyst, which may be immediate in some and slower in others (Fig. 4). Thinning of

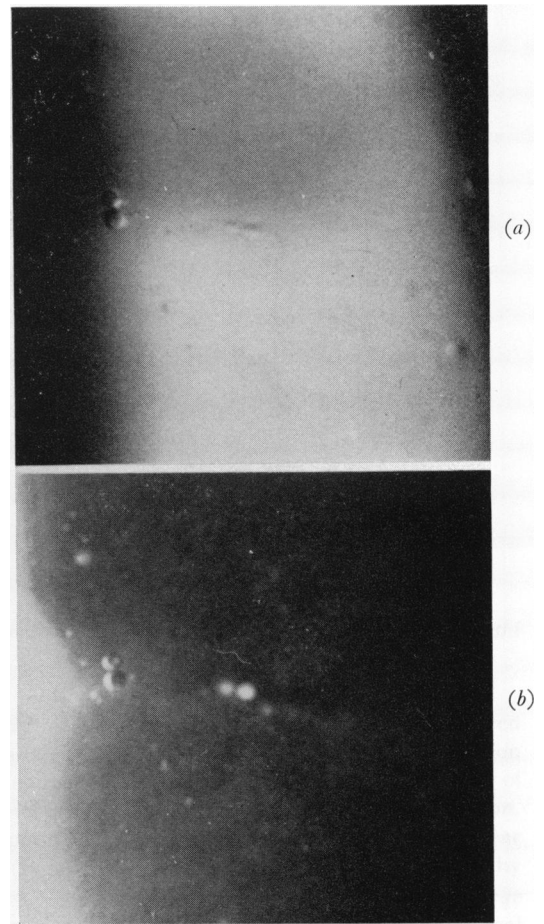
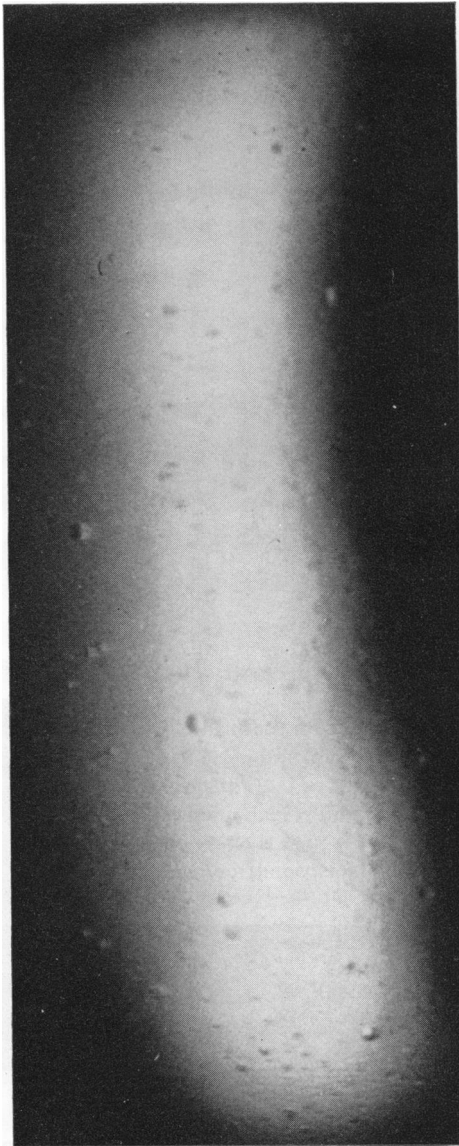


FIG. 4 *Meesmann's dystrophy. Mrs. V. K. Differential uptake of fluorescein dye by the cysts. Right eye: (a) Before fluorescein (b) After fluorescein*

FIG. 3 *Meesmann's epithelial dystrophy. Mrs. V. K. Distribution of epithelial cysts. Right eye*

the tear film over the cysts may be noted in the specular reflection or by staining the tears with fluorescein.

Recurrent erosion

This is characterized by repeated episodes of early morning waking symptoms, with pain, difficulty in opening eyes, watering, and blurring of vision. It generally follows surface trauma to the cornea and is then a unilateral condition (Arlt, 1874). There is also a spontaneous variety in which trauma cannot be incriminated (Spektor, 1931). This may be a unilateral or bilateral condition (Tripathi and Bron, 1972). The spontaneous

cases may be inherited (Franceschetti, 1928), and it may be added that certain corneal dystrophies are associated with recurrent erosion episodes (Stansbury, 1948).

Recently, a superficial corneal disorder has been described (Bron and Brown, 1971) in which a very delicate change in the region of the subepithelium of the cornea is associated with a high incidence of recurrent erosion, particularly of the cystic variety. The disorder is characterized by bleb-like patterns, net-like patterns, fingerprint lines, or by combinations of these changes. In this report, based on the study of forty patients with the disorder, fifteen patients presented with recurrent erosion (38 per cent.). Of these cases, nine were nontraumatic in origin (60 per cent. of the recurrent erosion cases) and eleven (73 per cent.) showed microcysts in the affected cornea. In three patients in the whole series, cysts were present bilaterally. The condition is thought to be similar to that described by DeVoe (1962) and Kaufman and Clower (1966). It affects both men and women and the age range is from 39 to 81 years.

It is thought that the association between the superficial corneal disorder and the recurrent erosions is not a chance one and must reflect some instability of corneal epithelial adhesion in these cases. The cysts encountered are no different from those seen in recurrent erosion of differing aetiology and the condition is mentioned merely to emphasize that, when recurrent erosion occurs in patients in the fifth decade and older, a very thorough search should be made for signs of the net, bleb, fingerprint, and combined patterns of superficial corneal disorder. These changes are poorly seen in diffuse or focal illumination and are demonstrated best by retroillumination against the fundus reflex.

Chandler (1945) introduced a clinical distinction between 'macro' and 'micro' forms of recurrent erosion. In the 'macro' form, trauma could usually be incriminated as an initiating factor. The episodes were relatively infrequent, but were severe and often associated with actual epithelial loss, that is, a large erosion. In the 'micro' form, trauma was less common, and episodes were frequent but less severe. Epithelial cysts were more common in this variety.

The cysts seen in recurrent erosion may present in different ways. They may be seen in oedematous epithelium at the edge of a large erosion, or within the detached epithelium of a bulla. A shower of cysts may usher in a recurrent erosion attack. In other cases, the cysts may be present in small numbers in an eye giving rise to occasional symptoms or in an eye which is no longer symptomatic. Such cysts may not be the cause of the specific symptoms of recurrent erosion in these cases, but they represent a marker of defective epithelium. For this reason the recognition of these cysts and an understanding

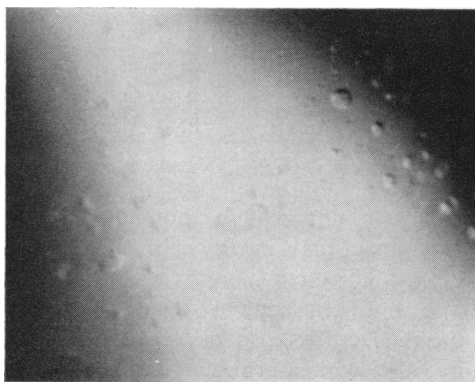


FIG. 5 *Recurrent erosion. Left eye. Cysts of varying shape and size. The eye is still symptomatic*

of their significance is essential to the diagnosis and management of many recurrent erosion cases.

The individual cysts of recurrent erosion range in size from 15 to 100 μ across. Characteristic of this condition is the chaotic variation in shape and content which occurs. Cysts may be spherical, ovoid, pyriform, linear, or pyramidal (Fig. 5). The amount of debris which they contain is variable, but it is usually more than that seen in Meesmann's dystrophy, and it is more copious during an attack than in a quiescent phase of the condition. Fusion of cysts is not uncommon, and neighbouring cysts may be linked by narrow strands of opaque material or by clefts in the epithelium. At times giant conglomerate cysts may be formed which may appear to explode from a central focus.

Some but not all recurrent erosion cysts stain with fluorescein and show the peculiar brilliance of staining cysts (Tripathi and Bron, 1972) (Fig. 6).

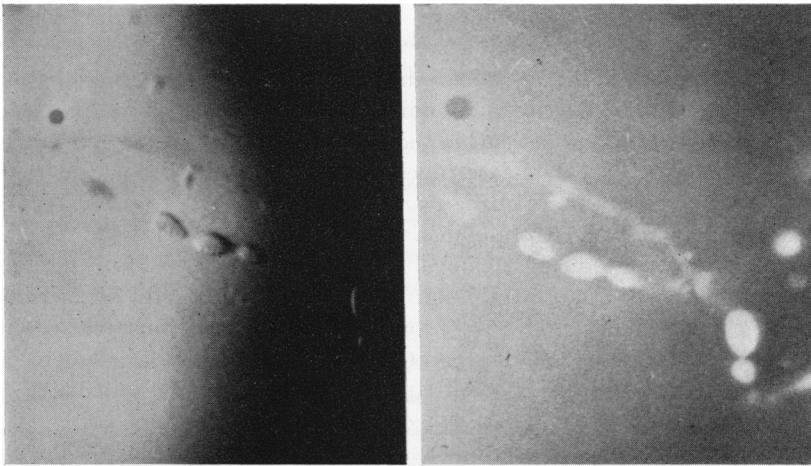


FIG. 6 *Recurrent erosion. Left eye*
 (a) Unstained cysts showing a sediment of debris
 (b) Uptake of fluorescein by cysts

The cysts of recurrent erosion change in shape and size over a period of time, while continuing to occupy the same general position in the corneal epithelium (Fig. 7, opposite).

Cogan's epithelial microcystic corneal dystrophy

This condition was originally described by Cogan, Donaldson, Kuwabara, and Marshall (1964) and was regarded as dystrophic in origin because of its commonly bilateral occurrence and the lack of corneal vascularization. Further reports have appeared from Guerry (1965), Wolter and Fralick (1966), and Levitt (1971). Affected family members have not been described.

The condition occurs in adults of both sexes and is characterized by the occurrence of multiple opaque putty-grey cysts in the epithelium of the pupillary zone of the cornea (Fig. 8). Patients may be asymptomatic or may experience some blurring of vision. Rarely, there is a foreign body sensation. These cysts may reach up to 1,000 μ in length (Cogan and others, 1964). In a case examined by one of us (A.J.B.), a variation in size from 20 to 900 μ was recorded at one time. The cysts of Cogan's dystrophy are rarely clear cysts. The majority are evenly filled with a granular debris. They do not stain

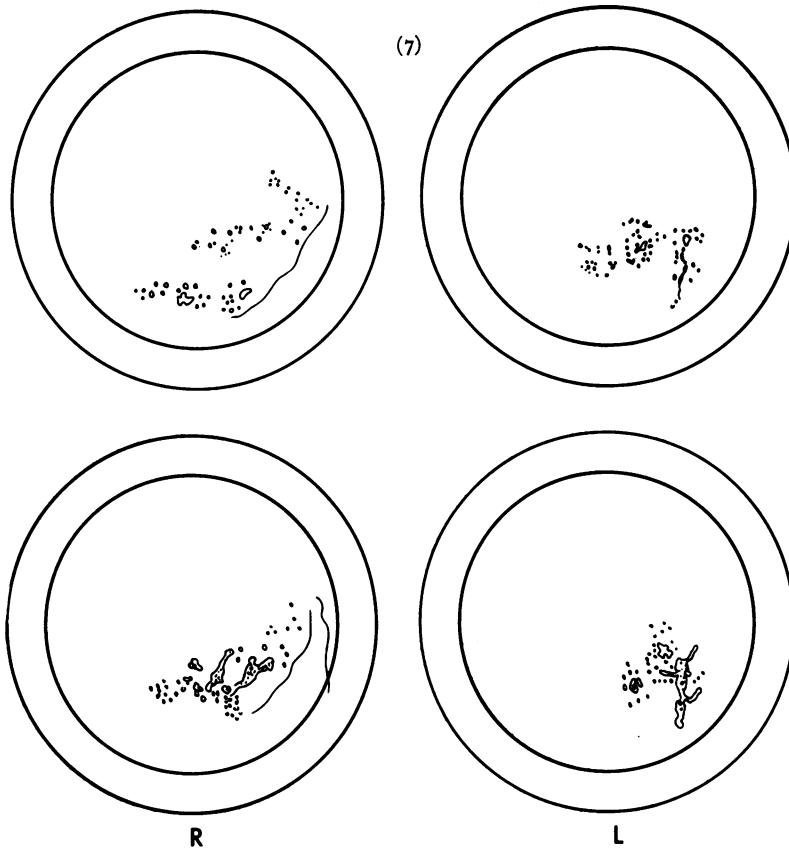


FIG. 7 Drawing of cysts seen in the right and left cornea of a patient with bilateral spontaneous recurrent erosion

(a) Above—October 10, 1971
(b) Below—October 14, 1971
(See Tripathi and Bron, 1972)

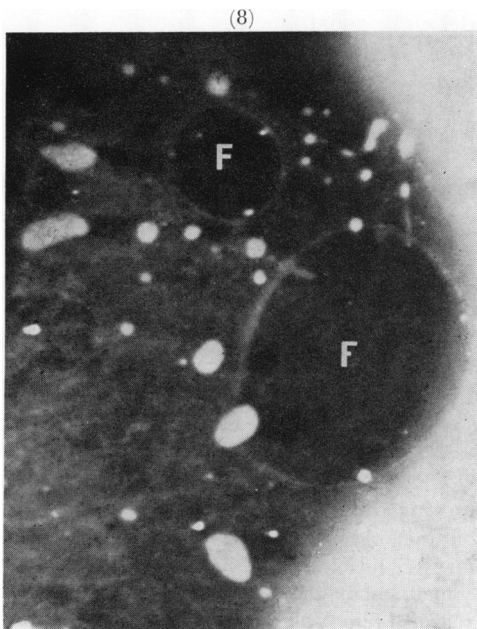


FIG. 8 Cogan's epithelial microcystic corneal dystrophy. Right eye. Opaque cysts are seen in the epithelium over a zone of amorphous sub-epithelial clouding (map-like pattern). There are clear fenestrations within the cloudy zone (F)

with rose bengal and only the uncommon clear cysts stain with fluorescein, although punctate staining over them has been recorded, and has been interpreted as due to rupture of cysts (Cogan, 1964). Guerry (1965) pointed out the existence of an amorphous geographical pattern in affected corneae, even in the absence of cysts (Fig. 8), and it has been emphasized in the literature that both the cysts and the geographical patterns change their morphology with time. The epithelium appears thickened or raised in the affected zone and the tear film is thinned over it. The condition is benign and only occasionally demands surgical therapy. Debridement may effect a cure without recurrence of the cysts. The map-like change may persist, however, and vision is not always improved.

Cysts associated with other ocular conditions

Epithelial cysts are observed in association with ocular disorders of diverse aetiology. A list of causes is given in Table 1 (above). Occasionally, however, isolated cysts may be found in the corneal epithelium with no history of trauma and in the absence of other ocular disease. Recurrent erosion may, of course, leave just such an appearance. Usually the typical history is present, but it is of note that asymptomatic cysts may be noted in the fellow eye in cases of unilateral recurrent erosion.

PANNUS

Cysts may occur in pannus of any aetiology, whether it is part of a hydrokeratopathy, infection, dry eye, or degeneration. These cysts are empty. It is possible that they occur in epithelium of conjunctival origin. A proportion of the cysts take up fluorescein.

VIRUS KERATITIS

Cysts have been observed with viral keratitis, such as herpes zoster keratitis, herpes simplex, and epidemic haemorrhagic conjunctivitis. The question may be raised whether the cysts are due solely to an associated epithelial oedema or to direct viral insult of the epithelial cells (Duke-Elder and Leigh, 1965b).

CYSTIC EPITHELIAL KERATOPATHY

More diffuse cystic epithelial changes have been observed in a series of possibly related disorders. The general descriptive name of 'cystic epithelial keratopathy' is proposed for a group of disorders in which diffuse epithelial cystic changes are present with or without a fine punctate epithelial keratitis (Jones, 1962), predominantly in the interpalpebral zone of the cornea. The cysts are relatively clear and of variable shape and size. They may occur in zones of relatively opaque epithelium and a proportion of them take up stain.

Diffuse cystic changes have been observed in corneal grafts in two patients:

A 45-year-old man showed profuse cystic changes over the graft in the postoperative period, despite a normal stroma and normal endothelial function. Tear production was found to be reduced by Schirmer's test. The cysts were greatly reduced in number after removal of a loose 10/0 Perlon continuous suture (Fig. 9, opposite).

A 53-year-old man developed diffuse cystic changes over a lamellar graft of 9 years' standing. After a left trigeminal nerve section for intractable neuralgic pain in June, 1971, an incomplete left facial nerve paresis was noted, with imperfect lid closure. Bilaterally reduced tearing was noted 1 month later (Schirmer's test). The meibomian gland orifices showed moderate abnormality on the left, but oil was visible in the precorneal film. The cysts were first noted 3 months after the

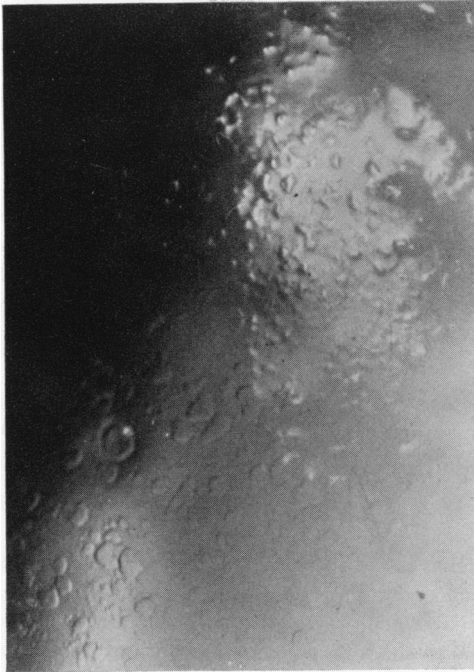


FIG. 9 Cystic changes in the epithelium of a graft in the absence of stromal oedema. Cystic epithelial keratopathy. In the upper right zone the cysts are raised above the surface where they disturb the specular reflex from the tear-film. Below and to the left discrete and confluent cysts are seen by retroillumination

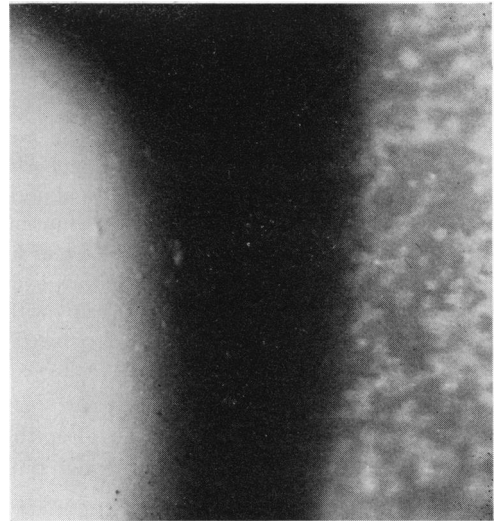


FIG. 10 Cystic epithelial keratopathy (see text for history). On the right, the punctate epithelial keratopathy is demonstrated in focal illumination while on the left a few cysts are seen by retroillumination

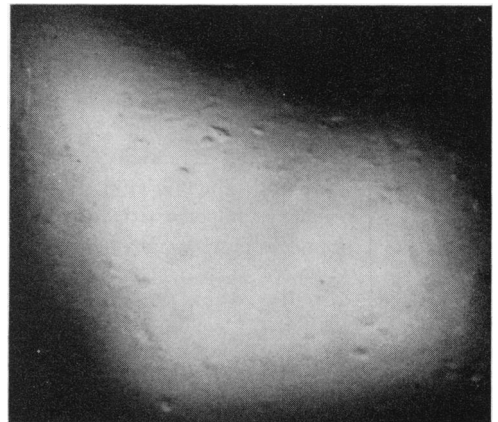

FIG. 11 Cystic epithelial keratopathy in a boy with diminished corneal sensation and reduced meibomian secretion. Right eye

neurectomy, although punctate staining had been recorded in the postoperative period. The cysts occupied the interpalpebral zone of the cornea including both graft and host. After occlusion of the left upper and lower puncta, a marked reduction in cysts occurred despite a persistence of the punctate epithelial keratitis.

In another patient with a highly allergic history, a fine punctate epithelial keratitis was present with cysts in the interpalpebral corneal epithelium of both eyes.

A 28-year-old West Indian presented with a complaint of irritation and itching in both eyes with some reduction in vision. Both eyes showed a punctate epithelial keratitis in which tiny flake-like

opacities were combined with a smaller number of cysts. The flakes were visible only in focal illumination and the cysts, which were clear, only on retroillumination (Fig. 10). In each eye the cysts occupied a large oval zone of the interpalpebral lower cornea and also, less severely, an oval patch under the upper lid. This latter site is a common one for the punctate keratitis of vernal catarrh (Jones, 1961). The tarsal conjunctival changes of tissue-paper scarring and papillary hypertrophy were in keeping with a diagnosis of tarsal vernal catarrh, but in addition there was lid thickening and gross abnormality of all meibomian gland openings. Pressure on the lids expressed an inspissated white material and not the normal oily secretion. No tear oil could be observed in the precorneal tear film on biomicroscopy of either eye. *Bacillus proteus* was repeatedly grown from the lid margins over many months, the culture becoming negative only during and shortly after systemic therapy with either ampicillin or trimethoprim. Tear production was variable and at times appeared reduced (Schirmer's test). The visual acuity fluctuated between 20/60 and 20/30 corrected in each eye.

Bilateral, interpalpebral epithelial cysts associated with a fine punctate epithelial keratitis have been observed in two patients, both male, with reduced corneal sensation of unknown cause (Fig. 11).

A 10-year-old boy presented with a foreign body sensation in the left eye and a curious dendritiform lesion in the left cornea. Stromal oedema and infiltration were present and there were some satellite stromal and epithelial opacities. The visual acuity was 20/20 and 20/60 without correction in the right and left eyes respectively. Corneal sensitivity was reduced in each eye. Tear production was normal, but many of the meibomian orifices were obstructed in the lids on both sides. Tear oil was difficult to demonstrate. The right cornea showed cysts and a punctate epithelial keratitis in the interpalpebral zone.

A 41-year-old man had marked reduction of corneal sensitivity bilaterally. The left cornea showed a plaque-like interpalpebral epithelial opacity with cysts in places and a large erosion temporally. The right eye showed diffuse punctate changes on the interpalpebral globe with mixed cysts and punctate epithelial keratitis over the cornea. The visual acuity was as good as 20/20 in each eye uncorrected despite extensive epithelial changes in the left eye. Tear production was found to be reduced (Schirmer's test).





Finally, a severe cystic epithelial keratopathy has been observed bilaterally in the interpalpebral corneae of a young boy with distichiasis. The changes were similar to those depicted in Fig. 11 in another patient. Although repeated trauma to the epithelium by the aberrant lashes appeared to be an obvious basis for the keratitis, it persisted despite the removal of the aberrant lashes completely on one side, and almost completely on the other. Although subtle changes in the tarsal conjunctiva secondary to electrolysis might be blamed for the persistent epithelial keratopathy, none was visible clinically. Therefore, it must be considered whether the absence of tarsal glands which occurs in this condition and the consequent absence of their contribution to the structure of the tear film could be a significant factor in the development and persistence of the keratitis.

Discussion

An attempt has been made to discuss the clinical methods which may be used to identify and characterize epithelial cysts of the cornea in a number of disorders.

Certain features of the cysts found in the various conditions mentioned are summarized in Table II (opposite).

Table II Characteristics of corneal cysts

Clinical features	Epithelial cysts of the cornea				
	Bullous keratopathy	Meesmann's dystrophy	Recurrent erosion	Cogan's dystrophy	
Size (μ)	20-75	10-50	15-100	20-900	
Shape	Globular; ovoid fused 	Globular 	Globular; ovoid conglomerate 	Globular; elongated 	
Contour	Smooth or irregular	Smooth	Smooth or irregular	Smooth	
Content	Empty	Debris +	Debris +	Debris + +	
Intervening epithelium	Cloudy	Faint haze	Clear or cloudy	Geographical opacity	
Slit lamp	Clear in cloudy ground	Opaque flecks	Opaque flecks or masses	Large opaque masses	
					Focal
Staining	Rose Bengal	++	+	+	-
	Fluorescein	++	+	+	-
Tear-film thinning	+	+	+	+	
Evolution	?	?	+	+	
Symptoms	+	+	+	+	

(1) *Size and shape*

Comparing the morphology of cysts found in hydrokeratopathy, Meesmann's dystrophy, recurrent erosion, and Cogan's dystrophy, it may be seen that the cysts in Meesmann's dystrophy are both the smallest and the most regular in form. Those of bullous keratopathy tend to have a bossed contour, because of the fusion with adjacent cysts. The cysts of recurrent erosion are extremely variable in shape while those of Cogan's dystrophy, although far larger than those seen in other conditions, still contrive to show a generally smooth contour. The latter appear to remain discrete and do not seem to coalesce with neighbouring cysts. The lower limit of cyst diameter, measured from photographs, is from 10 to 20 μ in these four main groups. Although this may not be a completely accurate measure, the order of size is so close to the diameter of the basal epithelial cells that the question arises whether some apparent cysts are, in fact, swollen epithelial cells.

It is possible to measure the lateral dimensions of cysts only from photographs, although binocular observation with the slit lamp suggests that the smaller cysts are

isodiametric in shape while the larger intraepithelial cysts, in the region of 100 μ or more across, are relatively flattened from before backwards.

In many instances, an increase in the thickness of the epithelium by the cysts is inevitable, although the degree of surface change must depend partly on the size of the cyst and partly on its level in the epithelium.

(2) *Content*

Different methods of examination with the slit lamp are able to demonstrate different features of the cysts. Debris contained within a cyst appears opaque on direct illumination and is therefore best demonstrated in the focal beam of the slit lamp. The full contour of a cyst is best appreciated by indirect illumination and may be gauged by retroillumination against the iris or the fundus reflex. With the latter methods of illumination the debris may be less readily distinguished unless it is very densely packed, as in Cogan's dystrophy or some cases of recurrent erosion. The fullest impression of the cyst structure may be obtained therefore by switching from focal to retroillumination by off-setting the slit-beam. The vesicles of epithelial oedema appear to be clear on biomicroscopy. Histological studies suggest that many contain cellular debris (Tripathi and Bron, 1972, 1973). It is possible that debris is not observed clinically because the vesicles are contained within relatively opaque epithelium. Opaque debris may sometimes be seen within bullae.

Tiny amounts of debris may be seen in the cysts of Meesmann's dystrophy, sometimes apparently suspended within the centre of a cyst, at other times lying below or against one wall of the cyst. In recurrent erosion, debris may occupy the cyst or it may appear to float free within the cyst. In Cogan's dystrophy, the debris forms a granular opacity which diffusely fills the cyst; clear cysts are uncommon.

(3) *Staining*

Only the opaque cysts of Cogan's dystrophy repeatedly fail to take up fluorescein stain into their substance, although occasional clear cysts do so. Punctate staining over the cysts has been interpreted as due to their rupture at the surface, but it is noteworthy that large staining areas are not seen despite the large size of the cysts themselves. It is questionable, then, whether these large cysts become *de-roofed* and then take up stain. In all the other disorders mentioned, some of the cysts which stain show a brilliance of fluorescence which distinguishes them from other forms of punctate staining and allows easy identification by the slit lamp under low power. This differentiation is aided by the rounded contour which many cysts display and which is not apparent in various forms of punctate keratitis. It seems likely that this brilliance of staining of the cysts is related to their thickness, since the luminance of fluorescein, within a certain range of concentration, is directly proportional to the thickness of the fluorescein layer exposed to the exciting light. It follows that, up to a point, the larger the cyst, the brighter it will appear. Epithelial bullae do not show this brilliant fluorescence, probably because they take up stain slowly so that with their large size only a low concentration of dye is achieved within them. Also, because of the delay in staining, the surrounding epithelium takes up fluorescein diffusely and intensely before peak concentration in the bulla is reached. Thus, any contrast effect which would enhance apparent brightness is lost.

The phenomenon of fluorescein staining of apparently intact cysts raises the question of the route of entry of the fluorescein from the tear-film into the cyst. Rarely, a cleft in the epithelium appears to connect the surface of the epithelium with the cyst cavities, and

this is associated with immediate staining with fluorescein. More often this is not the case and yet it is evident that fluorescein has ready access to the cystic spaces. Obviously, some permeability factor must be invoked to explain fluorescein entry. Normally, the surface cells of the epithelium are impervious to the diffusion of fluorescein, but it can be demonstrated with rose bengal that, in many situations where cysts are present which take up fluorescein, the surface epithelium takes up rose bengal in punctate fashion. Rose bengal stains degenerate and dead cells; this staining may or may not overly individual cysts, but in a few instances careful observation has suggested that entry of fluorescein into a particular cyst began at the site of a punctate staining with rose bengal. It is therefore suggested that fluorescein enters the disordered epithelium at sites of increased permeability, and that these may be related to defective surface cells (Tripathi and Bron, 1973). Green and Tonjum (1971) showed that increased permeability may be associated with widening of the epithelial intercellular spaces. This is likely to be an important route for the inward diffusion of fluorescein in the presence of epithelial oedema.

(4) *Overlying tear-film*

McDonald (1969) pointed out that any structure lying in the tear-film will induce a meniscus in relation to it and that thinning of the adjacent tear-film will result. The focal expansion of the epithelium produced by intraepithelial cysts produces multiple projections into the tear-film and thinning of the film over the cyst occurs (Fig. 9). This is expressed biomicroscopically as 'goose-pimpling' of the specular reflex or as dark spots of thinning in the fluorescein-stained tear-film. The dark spots will not be observed if the underlying cyst itself stains.

(5) *Evolution of cysts*

Epithelial cells are continuously lost from the surface of the cornea and are replaced by the division of cells in the basal layer. If it is accepted that the epithelial turnover rate in man is once a week (Hanna, Bicknell, and O'Brien, 1961), then it is not unexpected that cysts originating in the epithelium should exhibit a change in morphology over a relatively short space of time. This has been observed in the case of recurrent erosion cysts and in Cogan's dystrophy. The fact that it has not been observed in hydrokeratopathy and Meesmann's dystrophy probably reflects only the difficulty of making observations in a more complex situation.

Symptoms caused by cysts

The presence of multiple cysts lying in the visual axis of the cornea may produce an irregular astigmatism at the surface. Differences between the refractive index of the cysts and that of the surrounding tissue are responsible for light scatter (Dohlman, 1971). Both these factors may reduce vision significantly in vesicular keratopathy and to a variable degree in the other conditions mentioned. Possibly minor irritative symptoms are caused by punctate epithelial erosions formed by the rupture of cysts at the surface of the epithelium and major symptoms of pain by more extensive epithelial loss. The exposure of nerve endings could be a factor here. Alternatively, the production of dry spots in the tear-film could produce symptoms (S. I. Brown, 1970). However, typical cysts may be present in cases of recurrent erosion, Meesmann's dystrophy, and Cogan's dystrophy without producing discomfort. The specific symptomatology of attacks of recurrent erosion is most likely to be related to the defect in epithelial adherence in this condition (Tripathi

and Bron, 1972, 1973; Khodadoust, Silverstein, Kenyon, and Dowling, 1968; Goldman, Dohlman, and Kravitt, 1969).

Differential diagnosis

Recurrent erosion may sometimes be confused with Cogan's dystrophy. The spontaneous form of recurrent erosion may be bilateral, and the cysts relatively opaque. However, the cysts of Cogan's disorder are usually discrete and opaque and rarely take stain, whereas those of recurrent erosion are often fused, the proportion of debris within them is variable, and they often take stain. Even the most opaque recurrent erosion cysts may take up stain, which is in marked contrast to the situation in Cogan's dystrophy. Only the irregular conglomerate cysts of recurrent erosion could match the size of the largest cysts of Cogan's dystrophy. Though Cogan's dystrophy is not commonly associated with discomfort, one histologically proven case has been observed (Bron and Brown, 1971) in which early morning waking pain was present. Trobe and Laibson (1972) noted an association between recurrent erosion and Cogan's dystrophy.

Though it is recognized that the patients with cystic epithelial keratopathy represent a heterogeneous group, they appear to have certain features in common. Each of the patients mentioned showed abnormalities which affected the integrity of the tear-film. Both graft patients showed dry eyes, and while one showed an abnormality of the meibomian glands, the other exhibited a loose continuous suture. Removal of the suture ameliorated the keratopathy. Insensitivity of the graft may decrease blinking and renewal of the precorneal tear-film; in one case the host cornea was also insensitive as a result of a fifth nerve section. Two patients with insensitive corneae showed cystic epithelial keratopathy and these comments apply equally to them. One showed an abnormality of the oil glands. The patient with allergic eye disease showed gross meibomian gland disorder and there was also a possible defect in tear production. The patient with distichiasis had no visible meibomian glands.

If disturbances of the integrity of the tear-film are important in stimulating cyst formation, then it seems unlikely that a single factor is sufficient to induce them. The punctate keratitis associated with reduced tear formation alone does not take on a cystic form (McDonald, 1969). Corneal grafts may remain insensitive for many years without showing epithelial disease, and indeed patients who have had injection or section of the fifth cranial nerve need not show an epithelial keratopathy.

Cases of cystic epithelial keratopathy have been observed which resemble Meesmann's dystrophy because of the presence of diffuse, bilateral cystic epithelial changes. The diagnosis may be differentiated by a lack of family history and by the presence of the other ocular problems referred to earlier. One patient, however, has been observed with phenotypical Meesmann's dystrophy in the absence of affected family members and with no other ocular disease present. The appearances of an epithelial biopsy were not those of previously described cases of Meesmann's dystrophy (Tripathi and Bron, unpublished observations).

Summary

Cystic changes in the corneal epithelium are a common occurrence. They are found in hydrokeratopathy, recurrent erosion, Meesmann's corneal dystrophy, and Cogan's epithelial microcystic corneal dystrophy. They may be idiopathic, but are also found in association with pannus, virus keratitis, and certain disorders interfering with the integrity

of the tear-film. The term 'cystic epithelial keratopathy' has been employed for the last group. Full clinical characterization of epithelial cysts is achieved by biomicroscopy, with focal and retroillumination, scleral scatter illumination, and examination of the specular zone of the tear-film. It is aided by the use of fluorescein, which demonstrates thinning of the tear-film overlying the cysts and an uptake of the dye into a proportion of the cysts to produce a characteristically brilliant fluorescence.

Thanks are due to Prof. N. Ashton and Prof. B. R. Jones for helpful discussions during the preparation of this paper, to the Audio-Visual Department of the Institute of Ophthalmology, London, for preparation of the illustrative material, and to Miss J. Hancock for secretarial assistance.

References

- ARLT (1874) *Wien. med. Wschr.*, **24**, 447
- BRON, A. J., and BROWN, N. (1971) *Trans. ophthalm. Soc. U.K.*, **91**, 13
- BROWN, N. (1970) *Brit. J. Ophthalm.*, **54**, 697
- BROWN, S. I. (1970) *Arch. Ophthalm. (Chicago)*, **83**, 542
- BURNS, R. P. (1968) *Trans. Amer. ophthalm. Soc.*, **66**, 530
- CHANDLER, P. A. (1945) *Amer. J. Ophthalm.*, **28**, 355
- COGAN, D. G., DONALDSON, D. D., KUWABARA, T., and MARSHALL, D. (1964) *Trans. Amer. ophthalm. Soc.*, **62**, 213
- DOHLMAN, C. H. (1971) *Invest. Ophthalm.*, **10**, 383
- DUKE-ELDER, S., and LEIGH, A. G. (1965a) "System of Ophthalmology", vol. 8, part 2, p. 661. Kimpton, London
- (1965b) *Idem*, p. 735
- DEVOE, A. G. (1962) *Trans. Amer. ophthalm. Soc.*, **60**, 195
- FRANCESCHETTI, A. (1928) *Z. Augenheilk.*, **66**, 309
- GOLDMAN, J. N., DOHLMAN, C. H., and KRAVITT, B. A. (1969) *Trans. Amer. Acad. Ophthalm. Otolaryng.*, **73**, 471
- GREEN, K., and TONJUM, A. (1971) *Amer. J. Ophthalm.*, **72**, 897
- GUERRY, D. (1965) *Trans. Amer. ophthalm. Soc.*, **63**, 320
- HANNA, C., BICKNELL, D. S., and O'BRIEN, J. E. (1961) *Arch. Ophthalm. (Chicago)*, **65**, 695
- JONES, B. R. (1961) *Trans. ophthalm. Soc. U.K.*, **81**, 367
- (1962) *Int. Ophthalm. Clin.*, **2**, 591
- KAUFMAN, H. E., and CLOWER, J. W. (1966) *Amer. J. Ophthalm.*, **61**, 227
- KENYON, K. R. (1969) *Invest. Ophthalm.*, **8**, 156
- KHODADOUST, A. A., SILVERSTEIN, A. M., KENYON, K. R., and DOWLING, J. E. (1968) *Amer. J. Ophthalm.*, **65**, 339
- LEVITT, J. M. (1971) *Ibid.*, **72**, 381
- MCDONALD, J. E. (1969) *Ibid.*, **67**, 56
- PAUFIQUE, L., and ÉTIENNE, R. (1950) *Bull. Soc. Ophthalm. Fr.*, p. 690
- SPEKTOR, S. (1931) *Klin. Mbl. Augenheilk.*, **87**, 661
- STANSBURY, F. C. (1948) *Arch. Ophthalm. (Chicago)*, **40**, 189
- TRIPATHI, R. C., and BRON, A. J. (1972) *Brit. J. Ophthalm.*, **56**, 73
- (1973) *Ibid.*, **57**, 376
- , Unpublished observations
- TROBE, J. D., and LAIBSON, P. R. (1972) *Arch. Ophthalm. (Chicago)*, **87**, 378
- WOLTER, J. R., and FRALICK, F. B. (1966) *Ibid.*, **75**, 380