

# Ocular disorders in a series of 332 patients with Crohn's disease

D. J. HOPKINS, E. HORAN, I. L. BURTON, S. E. CLAMP,  
F. T. DE DOMBAL, AND J. C. GOLIGHER

*From the Department of Surgery, The General Infirmary, Leeds*

Ocular disorders arising in association with Crohn's disease are apparently something of a rarity, since there is very little reference in the literature to such a combination of complaints. This is something of a paradox, since it was Crohn (1925) who described the simultaneous occurrence of corneal inflammatory disorders, conjunctivitis, and uveitis in two patients suffering from ulcerative colitis. Since that time, a few reports have noted that such a combination of eye and bowel disorders may exist in respect of Crohn's disease (Korelitz and Coles, 1967; Lennard-Jones, 1968; Macoul, 1970; Truelove, 1971; Sherman, Swanson, Fleisher, Woolley, and Weitzman, 1972; Evans and Eustace, 1973), but these have chiefly consisted of reports of isolated cases, and there has been little in the way of systematic investigation of the two conditions.

The present paper describes in detail a series of eye lesions which were found amongst a group of 332 patients suffering from Crohn's disease. An analysis is presented of the types of eye lesion found and an attempt is made to assess the development of ocular complaints in relation to the clinical course of the inflammatory bowel disease.

## **Clinical material and methods**

The ocular complications described in this paper were noted during a survey of 332 patients suffering from Crohn's disease including all those who presented and were admitted to the General Infirmary, Leeds, during the period 1938 to 1969. The diagnosis of Crohn's disease was made in all instances during life on the basis of the criteria set out by Morson (1968). The extent of Crohn's disease was assessed by repeated endoscopy and radiological examination as well as histopathological examination of the excised specimen. Use is also made of the concept of a "patient year" (that is one year of observed medical follow-up of an individual patient) to relate the development of ocular conditions to the clinical course of Crohn's disease.

Every patient known to have ocular symptoms or who complained of such symptoms (past or present) or who had been found on previous examination to have an ocular disorder was seen and examined in detail by one of two ophthalmic surgeons (DJH or EH). The detailed history of the ophthalmic complaint was obtained and the patient underwent a thorough examination which included refraction, slit-lamp microscopy with fluorescein and rose Bengal staining, tonometry, and ophthalmoscopy.

## **Findings**

### **OVERALL INCIDENCE**

Of the total group of 332 patients with Crohn's disease, 21 (6.3 per cent) were found to have one or more ocular complaints; these were found in 8 per cent. of the 161 males in

the survey and 4.7 per cent. of the 171 females, a trend which though interesting does not reach statistical significance. The mean age at which eye lesions developed was 37 years; Table I shows the age-specific incidence in more detail, including the somewhat unusual

**Table I** *Effect of age at onset on incidence of eye conditions in patients with Crohn's disease*

Age at onset of Crohn's disease	No. of patients	Patients with eye lesions		Patients with uveitis	
		No.	Per cent.	No.	Per cent.
0-19	67	4	6.0	0	—
20-39	159	10	6.3	6	3.8
40-59	78	6	7.7	1	1.3
60+	28	1	3.6	1	3.6

finding that eye lesions were rather less commonly found in patients over 60 years of age.

#### DETAILS OF EYE LESIONS

The nature of the eye lesions found in this survey is shown in Table II. *Anterior uveitis* was

**Table II** *Nature of eye lesions in patients with Crohn's disease*

Eye lesions	No. of patients	Percentage of 332 cases
Uveitis	8	2.4
Corneal ulcers	4	1.2
Blepharitis	2	0.6
Bilateral episcleritis	2	0.6
Cataracts Steroid-induced	1	0.6
Congenital	1	0.6
Keratitis	1	0.3
Conjunctivitis	1	0.3
Macular haemorrhage	1	0.3
Other	3	0.9

diagnosed when a patient presented with typical symptoms and four of the following characteristics were revealed by examination:

- |                                    |                                     |
|------------------------------------|-------------------------------------|
| (1) Flare in the anterior chamber; | (4) Keratic precipitates;           |
| (2) Cells in the anterior chamber; | (5) Atrophy of the iris;            |
| (3) Posterior synechiae;           | (6) Deposits of pigment on the lens |

Eight patients, 2.4 per cent. of the total group, were found to have anterior uveitis when so defined.

*Ulceration of the cornea* was found in four patients (1.2 per cent.).

*Blepharitis* (inflammation of the lid margin) was found in two patients.

Other less common findings were *keratitis*, *conjunctivitis*, *macular haemorrhage*, and *cataract*. Two patients suffered from cataracts, one congenital and the other induced by steroids.

## RELATIONSHIP TO COURSE OF CROHN'S DISEASE

As in our earlier survey pertaining to ulcerative colitis, we attempted to relate the development of eye lesions to a number of aspects of the clinical course of Crohn's disease in each patient. Some of the more interesting findings of this further analysis will now be discussed.

*Activity of Crohn's disease*

As shown in Fig. 1, the chance of development of an ocular complaint seemed to be related to the activity of the patient's gastrointestinal disease. During the years in which a patient experienced a clinical remission of gastrointestinal symptoms, the chance of development of an eye complaint was remote (0.2 per cent.). However, during the years in which the patient had intermittently active disease, the chance of development of an eye complaint rose by a factor of 10 (2.1 per cent.), and moreover in those years when the patient's intestinal disease was continuous the risk of an eye complaint was twice as high again (4.4 per cent.). Despite the small numbers of patients, this trend reaches statistical significance at the 1 per cent. level when absolute probability tests are applied.

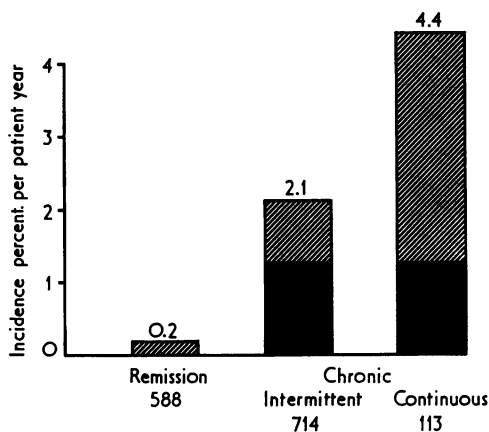


FIG. 1 *Relationship of activity of Crohn's disease to development of ocular complaints. Figures at bottom show number of "patient-years" in each analysis. Hatched columns overall values for all eye lesions. Black columns identical analyses for patients with uveitis.*

*Site of disease*

Interestingly, the site of Crohn's disease appeared to be less closely related to the risk of development of eye lesions (Fig. 2). During the years of follow-up, when the patients' intestinal disease was confined to the large bowel, the risk of development of an eye lesion was 3.0 per cent. The corresponding risk during the years of follow-up of patients when the disease was confined to the *small* bowel was strictly comparable (2.4 per cent.), and the risk during years of follow-up when the disease involved both small and large bowel was only marginally higher (3.8 per cent.). These differences are not statistically significant.

*Duration*

Fig. 3 shows that the greatest risk of developing an eye lesion in patients with Crohn's disease seems to be in the early course of their gastrointestinal disease, and specifically in the first year of symptoms. Nevertheless, as Fig. 3 also shows, after this first year the risk is not greatly altered by the passage of time and the mean duration of symptoms of Crohn's disease when ocular complications developed was at 5.6 years. The trend towards the development of eye lesions in the early years of Crohn's disease is not statistically significant.

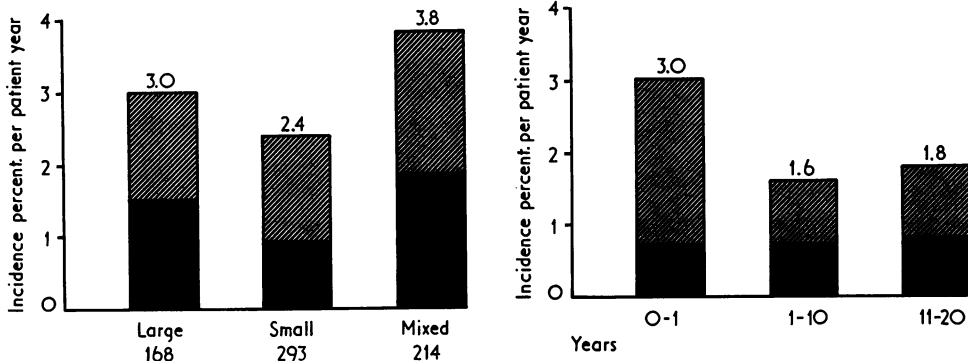


FIG. 2 Relationship of site of Crohn's disease to development of ocular complaints.

Number of "patient-years" shown as in Fig. 1. Discrepancy between overall numbers of patient-years in Figs 1 and 2 is due to several hundred patient-years in which the activity of Crohn's disease was known but the precise extent was not

FIG. 3 Relationship of duration of Crohn's disease to development of ocular complaints

ASSOCIATION WITH OTHER COMPLICATIONS

One of the findings which most intrigued us in respect of our survey of patients with ulcerative colitis was the association between various "systemic" complications, and again we have found a similar picture in respect of Crohn's disease. Thus, no less than thirteen of the 21 patients also had one or more other systemic complications of Crohn's disease (Table III). Most striking of all was the association between eye lesions and joint lesions, for nine

**Table III** Systemic complications in patients with eye lesions in Crohn's disease

Nature of complication	No. of patients	Percentage of cases
Joint disease	9	42.9
Blood disease*	7	33.3
Skin disease	3	14.3
Mouth disease	1	4.8

\* Predominantly iron deficiency anaemia

patients were so afflicted. This implies that nearly half the patients with eye disease also had some form of arthritis, and since only thirty patients in our whole series suffered from joint lesions, it implies that one-third of those with joint lesions also suffered from an ocular complaint. A less spectacular but equally interesting coincidence is the finding that three patients suffered from both ocular lesions and skin complaints; and in view of the data in Table III it is difficult to avoid the conclusion that there exists some degree of association between the "systemic" complications of Crohn's disease.

TREATMENT AND OUTCOME

Of the 21 patients with ocular lesions, nineteen came to surgery for Crohn's disease. After the operation some five patients reported further problems with their eyes—two of these patients suffered from anterior uveitis and also had other multiple "systemic" complica-

tions, two had impaired vision as a result of cataract formation, and one lost the vision of the left eye after a macular haemorrhage.

In the two patients who did not come to surgery, the eye lesions rapidly resolved with the cessation of the activity of their intestinal complaint, and in both cases the patients remained symptom-free as regards eye and gastric inflammatory problems up until the time of review. We thus adduce some evidence in support of the assertion of Macoull (1971) that intestinal resection produces an improvement in the ocular symptoms, but such improvement is by no means universal.

## Discussion

It is perhaps surprising that the association of ocular complaints and Crohn's disease has not been documented more fully in the years since the latter complaint was first described by Crohn, Ginzburg, and Oppenheimer (1932). For the association between specific dysenteries and eye lesions was well documented as long ago as 1916 (Crouzon, 1916; Maxwell and Kiep, 1918; Graham, 1919); and Crohn himself, describing ocular lesions in two patients suffering from ulcerative colitis, ascribed this combination of complaints to a vitamin deficiency resulting from impaired diet and decreased intestinal absorption (Crohn, 1925). In respect of ulcerative colitis, several reports have described the association between the disease and eye lesions in some detail (Edwards and Truelove, 1964; Ellis and Gentry, 1964; Wright, Lumsden, Luntz, Sevel, and Truelove, 1965; Billson, de Dombal, Watkinson, and Goligher, 1967). In respect of Crohn's disease, however, whilst several authors have commented that eye lesions may be found (Lennard-Jones, 1968; Truelove, 1971), most reports allude to single cases, such as that of Macoull (1970) or merely mention the combination of complaints *en passant*. Moreover, in those reports in which the lesions *are* discussed in any detail, there seems to be some doubt as to the precise diagnosis of the inflammatory bowel lesion. For example, the report of Korelitz and Coles (1967) notes that "in 4 cases" (out of 13) the clinical features "were more in favour of granulomatous colitis", but the diagnosis was not made with any more certainty, even in this sub-group of patients.

This might have been due to the fact that eye lesions are infrequently encountered in patients with Crohn's disease, but we found no less than 21 patients (6.3 per cent. of the 332 surveyed) who had one or more ocular complaints. This is not an inconsiderable proportion of the survey group and it heightens our sense of surprise that it has not been more fully reported on previous occasions.

As regards the nature of the eye lesions themselves, some were undoubtedly incidental to the disease (such as the single patient with a congenital cataract). Other eye lesions were perhaps related not to the disease but to its treatment—such as the patient with a cataract thought to have been induced by steroid therapy. Nevertheless, in many of the remaining cases, we believe that the eye disease was a genuine complication of the bowel abnormality. Thus, no less than eight patients were found to have anterior uveitis, and this proportion (2.4 per cent. of the total) is far above the 0.05 per cent. reported in the population at large by Darrell, Wagener, and Kurland (1962).

We have moreover been impressed—like Korelitz and Coles (1967)—by the association between the development of eye lesions and attacks of active bowel disease. As is clearly shown in Fig. 1, the majority of eye lesions were first noticed by the patient during an active episode of Crohn's disease. Our data show an association between Crohn's disease—particularly when chronic and continuous—and the development of eye lesions. Especially remarkable is the fact that the development of uveitis—alleged by several authors to be a

complication of Crohn's disease—is not related to the clinical course of the bowel disorder (Figs 1, 2, and 3). Conversely, other ophthalmic lesions—dismissed by these same authors as irrelevant or coincidental—are found almost exclusively in association with severe, continuous, active bowel disease. Whether uveitis is truly a complication remains to be seen, but it seems highly likely that previous authors have considerably underestimated the importance of ocular disorders in association with Crohn's disease.

In addition there seems to be a clear-cut association between eye lesions and joint changes in our patients, a feature noted in respect of ulcerative colitis both by Wright and others (1965) and Korelitz and Coles (1967). Half of our patients with eye lesions were also found to be suffering from one or more joint complaints and, as already noted, this is far higher than the overall incidence of joint disease (about 10 per cent.) in our 332 patients. We are unable to offer a ready explanation of combination of systemic complications, which again parallels our observations with ulcerative colitis (Billson and others, 1967). It is perhaps worth mentioning in this context that we have no firm evidence to support any hypothesis that these patients have some diarrhoeal form of Reiter's disease—in particular, the majority of our patients came to operation and the diagnosis of Crohn's disease was made on histopathological grounds.

### Summary

During a survey of 332 patients with Crohn's disease, some 21 patients were found to have ocular lesions. There were eight patients with anterior uveitis and four with corneal ulceration. Males were more often affected than females. Eye lesions developed in relation to active Crohn's disease and particularly in association with chronic continuous symptoms. The presence of an eye lesion was usually associated with at least one further systemic manifestation of Crohn's disease, and no less than half the patients with eye disease also had joint symptoms. After surgical treatment of the bowel lesion, the patient's prognosis in respect of the eye lesion was variable.

### References

- BILLSON, F. A., DE DOMBAL, F. T., WATKINSON, G., and GOLIGHER, J. C. (1967) *Gut*, **8**, 102  
 CROHN, B. B. (1925) *Amer. J. med. Sci.*, **169**, 260  
 ———, GINZBURG, L., and OPPENHEIMER, G. D. (1932) *J. Amer. med. Ass.*, **99**, 1323  
 CROUZON, O. (1916) *Bull. Soc. méd. Hôp. Paris*, **40**, 1926  
 DARRELL, R. W., WAGENER, H. P., and KURLAND, L. T. (1962) *Arch. Ophthalm. (Chicago)*, **68**, 502  
 EDWARDS, F. C., and TRUELOVE, S. C. (1964) *Gut*, **5**, 1  
 ELLIS, P. P., and GENTRY, J. H. (1964) *Amer. J. Ophthalm.*, **58**, 779  
 EVANS, P. JAMESON, and EUSTACE, P. (1973) *Brit. J. Ophthalm.*, **57**, 330  
 GRAHAM, G. (1919) *Proc. roy. Soc. Med.*, **13**, (Sect. Med.), 23  
 KORELITZ, B. I., and COLES, R. S. (1967) *Gastroenterology*, **52**, 78  
 LENNARD-JONES, J. E. (1968) *Proc. roy. Soc. Med.*, **61**, 81  
 MACOUL, K. L. (1970) *Arch. Ophthalm. (Chicago)*, **84**, 95  
 MAXWELL, E. M., and KIEP, W. H. (1918) *Brit. J. Ophthalm.*, **2**, 71  
 MORSON, B. C. (1968) In "Ulcerative Colitis", by J. C. GOLIGHER, F. T. DE DOMBAL, J. MCK. WATTS, and G. WATKINSON, p. 5. Baillière, London  
 SHERMAN, N. J., SWANSON, V., FLEISHER, D., WOOLLEY, M. M., and WEITZMAN, J. J. (1972) *J. pediat. Surg.*, **7**, 585  
 TRUELOVE, S. C. (1971) In "Regional Enteritis (Crohn's Disease)", ed. A. ENGEL and T. LARSON, p. 114. Skandia International Symposia, 1970. Nordiska Bokhandeln, Stockholm  
 WRIGHT, R., LUMSDEN, K., LUNTZ, M. H., SEVEL, D., and TRUELOVE, S. C. (1965) *Quart. J. Med.*, **34**, 229