

Hereditary sex-linked retinoschisis

J. D. BRODRICK* AND H. T. WYATT†

St. Pauls Eye Hospital, Liverpool

The management of retinoschisis still presents a complex clinical problem, and a survey of the current literature suggests that opinion remains divided regarding the most suitable form of treatment. It has been suggested that the results of surgery are poor and that operative treatment should be undertaken only with reluctance (Balian and Falls, 1960; Shea, Schepens, and von Pirquet, 1960; Duke-Elder, 1964). Pischel (1963), however, claimed good results from surgical treatment and in selected cases photocoagulation has been advocated (Okun and Cibis, 1964; Harris, 1968).

Hereditary sex-linked retinoschisis is a rare familial form of the condition, first described in detail by Mann and Macrae (1938). Subsequent authors have contributed a variety of additional information (Sheehan, 1952; Jager, 1953; Goodside, 1960; Gieser and Falls, 1961; Duke-Elder, 1964; Cibis, 1965; Falls, 1966; Keith, 1966).

The clinical appearance is variable. Mild cases present as a localized, cystic macular degeneration associated with haemorrhages and radial streaks caused by 'creasing' of the superficial retinal layers. More severe forms show advanced macular changes, vascular sheathing, optic atrophy, chorio-retinal degeneration, and semi-translucent veils which may become detached to float free in the vitreous (Jager, 1953; Balian and Falls, 1960; Duke-Elder, 1964; Sabates, 1966; Bengtsson and Linder, 1967; Vainio-Mattila, Eriksson, and Forsius, 1969).

A high incidence of retinal detachment has been a consistent observation (Jager, 1953; Ricci, 1961; Sabates, 1966; Bengtsson and Linder, 1967; Harris, 1968; Ewing and Ives, 1969; Vainio-Mattila and others, 1969) and some authors have reported degenerative changes in the vitreous (Ewing and Ives, 1969; Vainio-Mattila and others, 1969).

The electroretinogram has consistently been reduced or absent (Ricci, 1961; Forsius, Eriksson, and Vainio-Mattila, 1963; Vainio-Mattila and others, 1969), and dark adaptation has been reported to be either within normal limits (Ricci, 1961) or impaired (Vainio-Mattila and others, 1969). Colour discrimination has been recorded as reduced (Forsius and others, 1963; Vainio-Mattila and others, 1969) or unaffected (Lévy, 1952; Ricci, 1961).

No haematological or chromosomal abnormalities have been recorded (Bengtsson and Linder, 1967).

Pathological examination reveals that cleavage occurs in the nerve fibre layer, unlike senile retinoschisis in which splitting is observed in the outer plexiform layer (Yanoff, Rahn, and Zimmerman, 1968; Vainio-Mattila and others, 1969). The retinal vessels may lift off with the separated inner leaf which may undergo progressive hole formation.

The pathogenesis of the intraretinal fluid is uncertain, but is variously ascribed to vitreous traction, microscopic holes in the inner lamina, ischaemic autolysis, or osmosis with the inner leaf acting as a semi-permeable membrane. Alternative theories suggest

transudation from the chorio-capillaris or active secretion from the retinal cells of the outer lamina (Zimmerman and Spencer, 1960; Cibis, 1964; Harris, 1968).

The inheritance is well established as X-chromosomal recessive, being transmitted from an affected male *via* his apparently normal daughter to her sons (Lévy, 1952; Jager, 1953; Sabates, 1966; Bengtsson and Linder, 1967; Eriksson, Fellman, Vainio-Mattila, Sanger, Race, Krause, and Forsius, 1969; Ewing and Ives, 1969; Vainio-Mattila and others, 1969).

According to the Lyon hypothesis of random inactivation of one of the two X-chromosomes in females, one might expect some evidence of retinoschisis in carriers (Vainio-Mattila and others, 1969) but most reports suggest that heterozygotes are normal. Some recent studies have demonstrated peripheral retinoschisis with macular changes in elderly females (Sabates, 1966; Vainio-Mattila and others, 1969), ill-defined mottling with peripheral gliosis (Ewing and Ives, 1969) and cystic macular degeneration (Gieser and Falls, 1961; Lisch, 1968).

The locus for retinoschisis on the X-chromosome has recently been considered a measurable linkage with the Xg blood group, but the evidence to date is somewhat equivocal (Eriksson and others, 1969; Race and Sanger, 1968; Ewing and Ives, 1969; Vainio-Mattila and others, 1969).

The course of the disease is variable, but in general tends to be progressive (Jager, 1953; Balian and Falls, 1960; Duke-Elder, 1964). Visual acuity may fall because of macular involvement, the development of a true detachment, or haemorrhage into the vitreous from unsupported retinal vessels (Falls, 1966).

In this paper a family with hereditary sex-linked retinoschisis is reported. The varying course of the disease in different members of the family is described and the management of these cases is discussed.

Case reports (Fig. 1)

The pedigree shown in Fig. 1 contains 48 members in four generations. Of the thirteen members not examined, six in Generation I had died, two in Generation II had died, and two were not traced. Three in Generation III were too young to be adequately examined without a general anaesthetic which was not felt to have been justified.

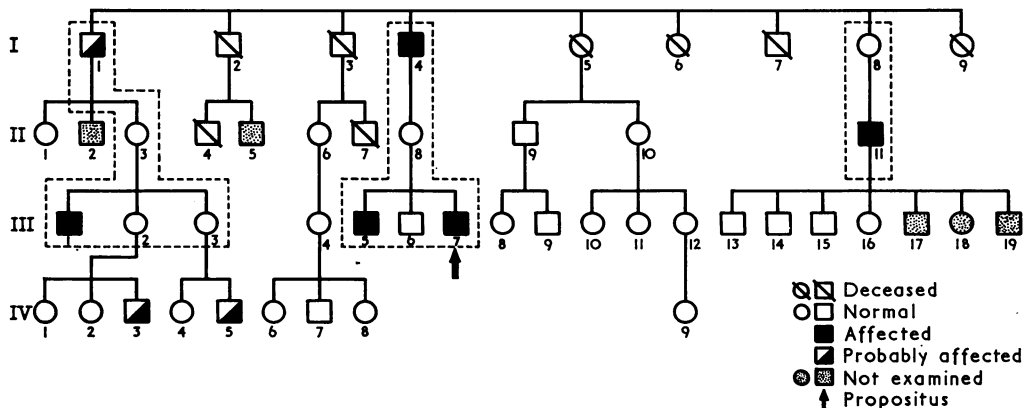


FIG. 1 Pedigree of family with hereditary retinoschisis, showing sex-linked recessive inheritance. The interrupted lines indicate those from whom linkage information might be obtainable

Of the fifteen males examined, five showed clear evidence of the disease; in one case the diagnosis was uncertain because he had dense cataracts which obscured the fundus view. These six cases are reported below.

SUBJECT I. 1 AGED 85

He first wore spectacles at the age of 30 and his vision had deteriorated very slowly since that time. More recently he had found progressive difficulty with reading. The visual acuity in the right eye was 6/60 with -4 D sph. (subjectively), and in the left eye counting fingers at 2 m. with -4 D sph. (subjectively).

In both eyes dense brown nuclear cataracts obscured the fundus. A dark streak-like vitreous opacity and extensive chorio-retinal atrophy with pigment disturbances could be seen in the lower periphery of the left eye by indirect ophthalmoscopy. The peripheral fields showed a generalized loss to a 5-mm. white target at $\frac{1}{3}$ metre. Although the presence of chorio-retinal changes could have fitted a diagnosis of hereditary sex-linked retinoschisis, the difficulties of fundus examination caused us to count this case as uncertain. We felt that his visual acuity and field loss could possibly be adequately explained by his lens opacities.

SUBJECT I. 4 AGED 79

His only complaint was of difficulty with distance vision. The visual acuity in the right eye was 6/24 with -8 D sph., and in the left 6/24 + with -7 D sph., -2.5 D cyl., axis 60° . In both eyes brown nuclear and cuneiform lens opacities made the fundus difficult to see. In the lower part of each fundus vitreous veils were seen, consisting of a few grey bands between which were huge dehiscences. No vessels were lifted off the retina in the areas of schisis. The underlying retina was atrophic with fine pigmentary changes but no heavy pigment clumping. Macular details could not be seen through the dense lens opacities. Peripheral fields to a 3-mm. white target at $\frac{1}{3}$ metre showed defects corresponding to the areas of schisis (Fig. 2). Hereditary retinoschisis was diagnosed in this case.

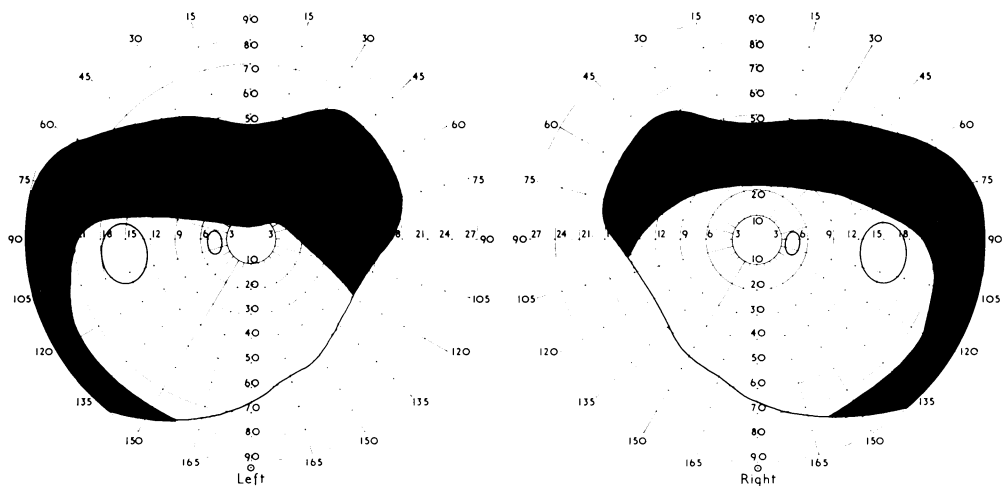


FIG. 2 Subject I, 4. Peripheral fields, showing marked upper and temporal defects (3-mm. white target at $\frac{1}{3}$ metre)

SUBJECT II. 2 AGED 48

At the age of 14 years he noticed that the visual acuity of the right eye suddenly became hazy while making a billiard shot. The history was suggestive of a right vitreous haemorrhage and, although examination of his old case records did not provide us with a detailed clinical description, we did

ascertain that he had been hospitalized for 3 months during which time trans-scleral diathermy was carried out on two occasions.

During the second world war he served in a tank regiment and was three times involved in attacks when he said he was "blown out of his tank". Despite these injuries he had no further eye trouble until he recently began to need reading glasses.

Examination

Visual acuity with the right eye was 6/36 unaided and was not improved with -1 D sph., $+2$ D cyl., axis 110° . The anterior segment was normal and the ocular media were clear. Almost the whole of the lower half of the fundus showed heavy choroidal scarring with dense pigment clumps and the macula was involved in the upper edge of this area. At the lower periphery, an area of vitreous veil was still visible, containing the typical large dehiscences. No vessels were lying on the lifted membrane. The visual field to a 3-mm. white target at $\frac{1}{3}$ metre on perimetry corresponded to the area of choroidal scarrings (Fig. 3).

Visual acuity with the left eye was 6/12 unaided and 6/9 with $+1.25$ D cyl., axis 90° . The anterior segment was normal and the ocular media were clear. There was a typical vitreous veil in the upper temporal quadrant of the fundus containing two enormous dehiscences. The underlying retina looked normal through this very thin membrane. The edge of the area showed a glial reaction and in some areas the vessels adjacent to the edge of the schisis were sclerosed resulting in a lattice-like appearance. There were pigmentary disturbances at the nasal periphery. The macula was normal. The area of retinoschisis did not produce much change in the peripheral field to a 3-mm. white target at $\frac{1}{3}$ metre, probably because of its extreme peripheral situation (Fig. 4).

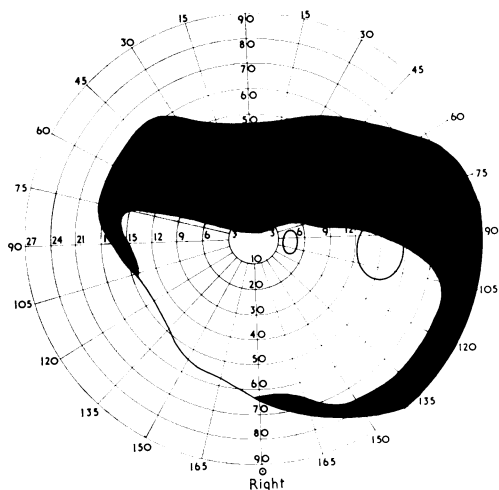


FIG. 3 Subject II, 2. Right peripheral field, showing marked upper and temporal defect

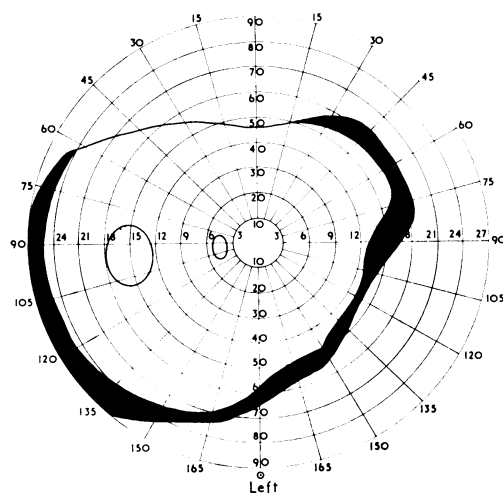


FIG. 4 Subject II, 2. Left peripheral field virtually within normal limits, probably because of the extreme peripheral location of the retinoschisis (3-mm. white target at $\frac{1}{3}$ metre)

SUBJECT III. 1 AGED 25

At the age of 9 years he had sustained a knock on the head, and 2 days later he noticed a shadow in the vision of his right eye. Visual acuity was then at best 6/60. There were many floaters in the inferior nasal quadrant and the overall appearance of the vitreous was hazy. At that time the visual acuity in the left eye was 1/60 at best, and the lower temporal quadrant showed some retinal abnormality which was unfortunately not described in detail in the old records. Eales's disease with a vitreous haemorrhage was diagnosed and he was treated by radiotherapy.

Examination

The visual acuity of the right eye was 6/24+ with +3 D cyl., axis 70°. There was a pendular nystagmus. The lens showed a small posterior polar cataract. In the upper retinal periphery a thick grey vitreous veil was attached to the retina, but no retinal vessels crossed its surface. The macula was abnormal with flat grey flecks and the optic disc was pale. The peripheral field was full to a 3-mm. white target at $\frac{1}{3}$ metre.

The visual acuity with the left eye was finger counting at 3 m. with +1.25 D cyl., axis 90°. There was a pendular nystagmus. The lens was clear. In the upper periphery, in a symmetrical position to the right eye, a vitreous veil was present. In this case it was not attached to the retina but lay close to the retinal surface. No vessels crossed the veil. The macula was abnormal, showing extensive degenerative changes with dense pigment clumping. The peripheral field was full to a 3 mm. white target at $\frac{1}{3}$ metre.

A diagnosis of sex-linked retinoschisis with predominantly macular features was made in this case.

SUBJECT III. 5 AGED 16

This boy was symptom free. The visual acuity in the right eye was 6/9 with -6 D sph. The anterior segment was normal and the ocular media were clear. In the equatorial zone of the lower temporal quadrant of the retina there was a limited area where a thin translucent veil with a free edge curled inwards towards the vitreous. No retinal vessels crossed the veil or were lifted off by it. The macula showed a slightly granular pigment irregularity and the foveal reflex was absent. The peripheral field was full to a 3-mm. white target at $\frac{1}{3}$ metre.

The visual acuity in the left eye was 6/9 with -4.25 D sph., +1 D cyl., axis 80°. The anterior segment was normal and the ocular media were clear. The retina showed a symmetrical though less marked irregularity of the inner retinal layer. No vessels were lifted on the veil. The foveal reflex was absent. The peripheral field was full to a 3 mm.-target at $\frac{1}{3}$ metre.

Hereditary retinoschisis with minimal manifestations was diagnosed.

SUBJECT III. 7 AGED 8. PROPOSITUS

This boy presented with a history of seeing coloured squares in front of the right eye. This had occurred spontaneously once previously but on this occasion was possibly precipitated by minor trauma to the eye.

The visual acuity in the right eye was 3/60 without glasses, improving to 6/18 with +2.5 D sph., +2 D cyl., axis 105°. A vitreous haemorrhage obscured a detailed view of this fundus.

The visual acuity in the left eye was 6/24 without glasses, improving to 6/18 + with +0.5 D sph., +3.5 D cyl., axis 60°. There was a vitreous veil in the lower half of the left equatorial zone and the retinal vessels in this area were lifted off. Some small retinal haemorrhages were seen deep to the veil. Both visual fields showed marked defects, the left corresponding to the visible area of schisis (Fig. 5, overleaf).

As the vitreous haemorrhage cleared it became evident that a similar veil was present in the right eye, again with the retinal vessels lifted off and small retinal haemorrhages lying deep to the separated leaf.

In addition, there was some new vessel formation in the retina just above the margin of the schisis. Many of these new vessels were extremely close to the main vessels and the optic disc and, because of this, photocoagulation, on the one occasion it was carried out, was extremely limited.

The vitreous has since remained clear and there has been no further haemorrhage in either eye. The visual acuity has remained at 6/24 right, 6/18+ left. A diagnosis of sex-linked retinoschisis was made in this case.

Two male children both under ten had minor fundus abnormalities which could have been early manifestations of retinoschisis. Both were descendants of Subject I. 1 (Fig. 1).

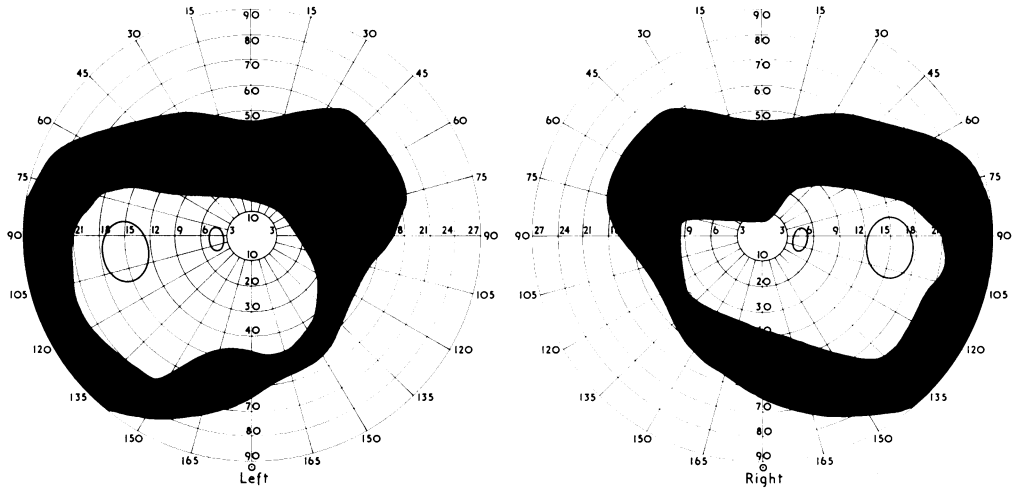


FIG. 5 Subject III, 7. *Propositus*. Visual fields, showing upper defects (3-mm. white target at $\frac{1}{3}$ metre)

SUBJECT IV. 3 AGED 6

Emmetropic. Visual acuity 6/6 right and left. The ocular media were clear and the foveae were normal. In the lower temporal quadrant of each retina there was an oval ill-defined area of relative depigmentation.

SUBJECT IV. 5 AGED 6

Emmetropic. Visual acuity 6/6 right and left. In the lower temporal retina of the left eye there was again an oval area of relative depigmentation where the surface of the retina had a rippled appearance. The overlying vitreous appeared normal.

Of twenty women examined, only three showed any retinal abnormalities.

SUBJECT I. 8 AGED 73

Visual acuity in the right eye 6/6 with -0.5 D sph., $+1$ D cyl., axis 180° , and in the left eye 6/6 with -0.5 D sph., $+0.75$ D cyl., axis 180° . The peripheral retina in each eye showed fine irregular clumps of pigment migration compatible with a diagnosis of peripheral senile degeneration. There was no evidence of vitreous veils or of gliosis.

SUBJECT II. 1 AGED 61

In the right eye the visual acuity was 6/12 with $+1$ D sph., $+3$ D cyl., axis 80° , and in the left 6/9 with $+1.25$ D sph., $+2.75$ D cyl., axis 90° . Peripheral fields and colour discrimination were normal. There was evidence of early degenerative changes at both maculae and both fundi showed peripheral cystoid degeneration.

SUBJECT III. 16 AGED 7

In the right eye the visual acuity was 6/6 unaided, and in the left eye 6/5 unaided. Both eyes were emmetropic. In the lower right quadrant of each retina there was a small area of whitish flecking on the inner surface, interpreted as a small glial irregularity. There was no other evidence of retinal abnormality.

Discussion

The features of hereditary sex-linked juvenile retinoschisis have been listed by Balian and Falls (1960) as follows:

- (1) Translucent veil-like membranes projecting from the inner retinal layer, sometimes carrying vessels, and containing large oval dehiscences.
- (2) Perivascular and intraretinal grey opalescence—"resolution gliosis".
- (3) Macular aberrations—cystic changes leading later to atrophic and pigmentary changes.
- (4) Peripheral retinal neovascularization tending to sclerose later.
- (5) Posterior vitreous detachment.
- (6) Rarely, a true retinal detachment.
- (7) Partial amblyopia due to macular changes.
- (8) High incidence of hypermetropia.
- (9) Sex-linked recessive inheritance.
- (10) Field defects.

They also observed that the disease manifests a marked range in expressivity and varies from family to family and from individual to individual.

The varied clinical picture and the inheritance seen in the family described in this paper seem to us to accord well with the diagnosis. Cases I, 4; II, 2; III, 5; and III, 7 (Fig. 1) show predominantly the features of the peripheral retinal disease, whilst Case III, 1 and possibly Case I, 1 show the predominantly macular features.

In the family presented here, there is evidence to suggest that the disease is one of slow progression throughout life. Cases IV, 3 and IV, 4 already show ill-defined abnormalities in the most commonly affected sectors, and Case III, 7 shows the fully-developed picture, whilst in the old men (*e.g.* Case I, 4) the dehiscences in the vitreous veils were very large, leaving thin strands and sheets of tissue with no unsupported vessels.

This suggests that progression may be due to the formation of a separated inner leaf in which oval dehiscences develop. These may enlarge with the passage of time, thus reducing the area of the lifted leaf to smaller and smaller residual strands. This mechanism differs considerably from the normal extension of the schisis process which occurs in the senile form of the disease.

If this is the case, then it is possible that the successes described by Pischel (1963) in treating this disease represent no more than the normal progression of the retinal changes. Indeed it is difficult to conceive how any form of drainage of fluid from beneath the veil could materially affect the outcome, when there are such large holes in the leaf allowing free communication between the vitreous space and the subleaf zone. This seems to be a more rational concept than that surgical treatment has had any effect for as long as 8 or 9 years as claimed.

Regarding treatment, diverse views have been expressed, as already noted. We believe that the veils *per se* should be left alone unless there is evidence of the development of a true detachment. Case I, 4 has remained symptom-free throughout life, and has not been aware of the loss of the upper visual fields. Case II, 2, who had what we presumed to be a vitreous haemorrhage in the right eye which was treated, also had the disease in an unusual quadrant in the left eye, but despite repeated trauma in later life he had never experienced symptoms from this eye. To have interfered with this eye would, we feel, have been a mistake.

The fundi of the female patients were examined in detail for any evidence suggestive of a carrier state. Seventeen of the twenty female patients examined were clinically normal. This group included four known carriers: II, 2; II, 8; III, 2; and III, 3. In the remaining three patients, I, 8 (known carrier), II, 1 (no children), and III, 16 (infant), macular changes, peripheral gliosis, and peripheral retinal degeneration were found. This would seem to accord with the appearances described by previous authors in the fundi of heterozygous females (Gieser and Falls, 1961; Sabates, 1966; Lisch, 1968; Ewing and Ives, 1969; Vainio-Mattila and others, 1969). From our study no unequivocal consistent stigmata of a carrier state have emerged.

Linkage information was sought from the groups illustrated by the interrupted lines in Fig. 1. At this stage of the study, however, Subjects I, 8 and II, 11 were not available.

All the patients who were studied were Xg (a—); as far as linkage between the locus for retinoschisis and Xg is concerned, this family has no information to contribute.

This family demonstrates again that one of the commonest presenting signs is vitreous haemorrhage, occurring presumably from unsupported vessels. Our Case III, 7 appeared to have bled from vessels lifted well away from the actual bed, and attempted light coagulation produced no obvious change in the fundus picture. It does not seem likely that light coagulation would be effective in these situations because the vessels are too large to be coagulated safely and nets of new vessel formation were not found in the retinal plane where they would be accessible to treatment. The argon laser may provide a solution to this problem.

Visual impairment clearly arises from the complications of vitreous haemorrhage, from the development of a true detachment, or from progression of the characteristic macular lesions. With presently available methods there would seem to be no solution to the latter problem.

Summary

- (1) The clinical features of hereditary sex-linked retinoschisis have been discussed and the current literature regarding treatment has been reviewed.
- (2) A family affected by this condition has been described.
- (3) No information regarding Xg linkage was obtained from this study.
- (4) Visual impairment is due to macular involvement, the development of a true detachment, or haemorrhage into the vitreous from unsupported vessels.
- (5) We suggest that progression of the condition occurs by enlargement of the oval dehiscences in the inner leaf rather than by extension of the schisis in the manner seen in the senile type.
- (6) Enlargement of the dehiscences where retinal vessels are lifted off with the inner leaf can leave these vessels unsupported, thus constituting a source of vitreous haemorrhage.
- (7) The presence of the condition without evidence of progression is no indication for attempting treatment.

We wish to thank Mr. D. M. J. Burns for access to his patient, Dr. R. R. Race and Dr. Ruth Sanger for their co-operation in carrying out studies of the Xg groups, and Miss Vanessa Clark for secretarial assistance.

References

- BALIAN, J. V., and FALLS, H. F. (1960) *A.M.A. Arch. Ophthalm.*, **63**, 92
 BENTGSSON, B., and LINDER, B. (1967) *Acta ophthalm. (Kbh.)*, **45**, 411

- CIBIS, P. A. (1965) "Vitreoretinal Pathology and Surgery in Retinal Detachment". Mosby, St. Louis
- DUKE-ELDER, S. (1964) "System of Ophthalmology", vol. 3, part 2, p. 643. Kimpton, London
- ERIKSSON, A., FELLMAN, J., VAINIO-MATTILA, B., SANGER, R., RACE, R., KRAUSE, U., and FORSIUS, H. (1969) Int. Congr. Ser. Excerpta Med. Found. No. 356
- EWING, C. C., and IVES, E. J. (1969) *Trans. ophthalm. Soc. U.K.*, **89**, 29
- FALLS, H. F. (1966) In "Retinal Diseases", ed. S. J. Kimura and W. M. Caygill, pp. 124-135, 182. Kimpton, London
- FORSIUS, H., ERIKSSON, A., and VAINIO-MATTILA, B. (1963) *Klin. Mbl. Augenheilk.*, **143**, 806
- FRANÇOIS, J., and RABAEY, M. (1953) *Brit. J. Ophthalm.*, **37**, 601
- GIESER, E. P., and FALLS, H. F. (1961) *Amer. J. Ophthalm.*, **51**, 1193
- GOODSIDE, V. (1960) *A.M.A. Arch. Ophthalm.*, **63**, 682
- HARRIS, G. S. (1968) *Canad. J. Ophthalm.*, **3**, 312
- JAGER, G. M. (1953) *Trans. ophthalm. Soc. U.K.*, **73**, 617
- KEITH, C. G. (1966) *Brit. J. Ophthalm.*, **50**, 617
- LÉVY, J. (1952) *Ibid.*, **36**, 626
- LISCH, K. (1968) *Klin. Mbl. Augenheilk.*, **153**, 204
- MANN, I., and MACRAE, A. (1938) *Brit. J. Ophthalm.*, **22**, 1
- OKUN, E., and CIBIS, P. A. (1964) *Arch. Ophthalm. (Chicago)*, **72**, 309
- PISCHEL, D. K. (1963) *Amer. J. Ophthalm.*, **56**, 1
- RACE, R. R., and SANGER, R. (1968) "Blood Groups in Man", 5th ed., p. 349. Blackwell, Oxford
- RICCI, A. (1961) *Bull. Soc. Ophthalm. Fr.*, **61**, 618
- SABATES, F. N. (1966) *Amer. J. Ophthalm.*, **62**, 683
- SHEA, M., SCHEPENS, C. L., and VON PIRQUET, S. R. (1960) *A.M.A. Arch. Ophthalm.*, **63**, 1
- SHEEHAN, B. (1952) *Trans. ophthalm. Soc. U.K.*, **72**, 623
- VAINIO-MATTILA, B., ERIKSSON, A., and FORSIUS, H. (1969) *Acta ophthalm. (Kbh.)*, **47**, 1135
- YANOFF, M., RAHN, E. K., and ZIMMERMAN, L. E. (1968) *Arch. Ophthalm. (Chicago)*, **79**, 49
- ZIMMERMAN, L. E., and SPENCER, W. H. (1960) *Ibid.*, **63**, 10