

Angle recession and secondary glaucoma

D. MOONEY

Kent County Ophthalmic and Aural Hospital, Maidstone

In a previous article (Mooney, 1972), the incidence and extent of angle tears was reported in a series of 53 cases of traumatic hyphaema examined within 3 years of the date of injury, and it was suggested that those cases with angle tears involving 180° or more of the anterior chamber angle should have annual tonometry in order to detect the development of glaucoma in the injured eye at as early a stage as possible.

The purpose of this paper is to report the findings in a series of cases examined between 11 and 14 years after hyphaema due to non-perforating injury.

The late development of glaucoma after traumatic hyphaema has been described by several authors.

D'Ombraïn (1944) drew attention to the association of ocular trauma and chronic glaucoma and described four patients with chronic unilateral glaucoma who had suffered ocular or periorbital injury 18, 16, 20, and 4 years previously. D'Ombraïn substantiated his observations with further cases described in articles published in 1945, 1946, and 1949. He suggested that the glaucoma may be due to a process of fibrosis or cuticular proliferation in the region of the trabecular meshwork as described by Reese (1944).

Wolff and Zimmerman (1962) described the early and late histopathological changes of angle recession in a series of eyes enucleated after ocular contusion and confirmed D'Ombraïn's theory of the underlying cause. In early cases they noted lacerations into the face of the ciliary body with damage to the ciliary muscle. Those lacerations that passed between the circular and longitudinal muscles of the ciliary body resulted in posterior displacement of the former along with the iris root and pars plicata. They also noted disruption of the trabecular meshwork. In late cases they noted atrophy of the circular muscle fibres that had been separated from the longitudinal fibres and advanced degenerative changes of the trabecular meshwork consisting of atrophy, fibrosis, and hyalinization of the trabeculae and obliteration of the intertrabecular spaces and Schlemm's canal. In many cases there was a newly formed hyaline membrane covering the inner surface of the trabeculae continuous with Descemet's membrane and often extending into the recessed angle covering the longitudinal muscle.

D'Ombraïn made no comment about the gonioscopic findings in his cases, but Alper (1963) described the gonioscopic changes in a selected series of 27 non-perforating eye injuries; he noted deepening of the anterior chamber, widening of the ciliary body band and posterior displacement of the iris root. Fourteen of his 27 cases had chronic unioocular glaucoma in the injured eye.

Pettit and Keates (1963) described eight cases of angle recession after blunt ocular trauma, one of which had chronic unioocular glaucoma 8 years after trauma.

Blanton (1964) found 130 cases of angle recession in a series of 182 cases of traumatic hyphaema; four of these patients had chronic unioocular glaucoma diagnosed more than 10 years after the injury and all four had angle recession involving more than 180° of the anterior chamber angle.

Tönjum (1968) reviewed 160 cases of traumatic hyphaema examined between 2 months and 15 years after injury. All 160 cases had some degree of angle recession and in one late chronic unioocular glaucoma was diagnosed six years after injury; this patient had recession involving more than 270° of the angle circumference.

Material and methods

Between July, 1958, and July, 1961, 112 patients were admitted to the Kent County Ophthalmic Hospital with traumatic hyphaema due to non-perforating injury. Of these patients, 42 attended the clinic for examination on request; the other seventy patients failed to attend for various reasons (the majority having moved out of the Maidstone area).

Examination consisted, principally, of tonometry with the Goldmann applanation tonometer and gonioscopy with the Haag-Streit slit lamp and the Goldmann goniolens. Goniophotography was carried out in selected cases with Kowa fundus camera and the Medical Workshop contact lens.

Results

Of the 42 patients examined between 11 and 14 years after traumatic hyphaema, 35 (83 per cent.) were found to have angle recession (Table I). The circumferential extent of the recession is shown in Table II; thirteen patients had angle recession of 180° or more.

Intraocular pressures were normal in 41 of the 42 cases; the remaining case will be described in some detail.

Table I 42 cases examined 11 to 14 years after traumatic hyphaema

Angle recession	No.	Per cent.
Present	35	83
Absent	7	17
Total:	42	100

Table II Circumferential extent of angle recession in 35 cases

Circum. extent	< 90°	< 180°	< 270°	$270^\circ \rightarrow 360^\circ$	Total
No. of cases:	9	13	8	5	35

Case report

A boy aged 10 years was admitted to the Kent County Ophthalmic Hospital with a small traumatic hyphaema following a blow from a stick on the right eye. He was noted to have a small iridodialysis in the lower temporal quadrant and commotio retinae in the temporal periphery. He made an uneventful recovery.

When he was seen 12 years later at the age of 22 years as part of this study, the visual acuity was 6/5 in each eye, and he had traumatic mydriasis and a small iridodialysis as noted 12 years previously. There was also a scattered chorioretinal pigmentation in the temporal periphery of the right fundus. The intraocular pressure was 22 mm. Hg in the right eye and 17 mm. Hg in the left. Gonioscopy revealed recession involving 300° of the right angle (Figs 1 and 2, overleaf).

At subsequent hospital visits the intraocular pressure was:

(1) Right 21; Left 16. (2) Right 19; Left 13 (3) Right 22; Left 15

A provocative water-drinking test after initial readings of Right 18 and Left 14 mm. Hg induced a rise in intraocular pressure to a maximum of Right 23 and Left 17. The fields of vision were normal as were the optic discs.

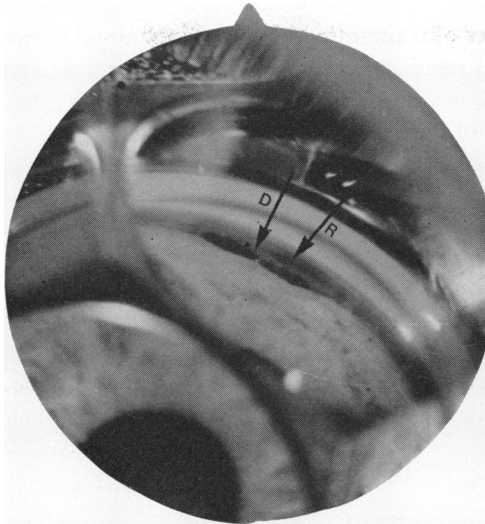


FIG. 1 Case 1. Iridodialysis (*D*) and cleft into face of ciliary muscle (*R*), i.e. angle recession

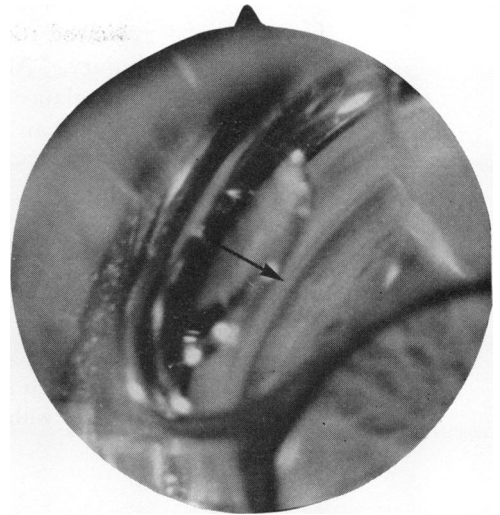


FIG. 2 Case 1. Corresponding area of uninjured eye showing normal angle (arrow)

Figs 3 to 8 show the injured and uninjured eyes in three other patients (Cases 2, 3, and 4), in which the intraocular pressure remained normal.




FIG. 3 Case 2. Angle recession involving entire sector of angle in this view (*R*) and Schlemm's canal (*S*). Note that blood fills the canal to the left of arrow but fails to fill the canal to right of arrow (possibly due to atrophy and fibrosis of canal and trabeculae in this area)




FIG. 4 Case 2. Normal angle of uninjured eye (arrow)

Discussion

Blanton (1964), in his series of 130 cases, noted two peak incidences of glaucoma after angle recession; the early peak occurred within 3 years of injury and the late peak 10 or more years after injury. The five cases of glaucoma occurring within 3 years of injury all eventually reverted to normal intraocular pressures within 1 year. Four cases of glaucoma were diagnosed 10 or more years after injury, whereas none of the 64 cases examined

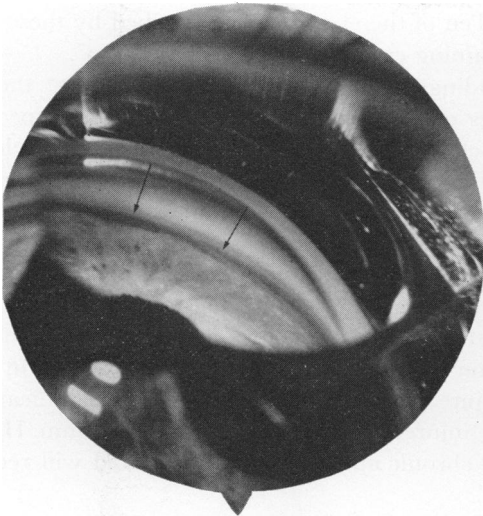

FIG. 5 Case 3. Clefts into face of ciliary muscle (arrows)

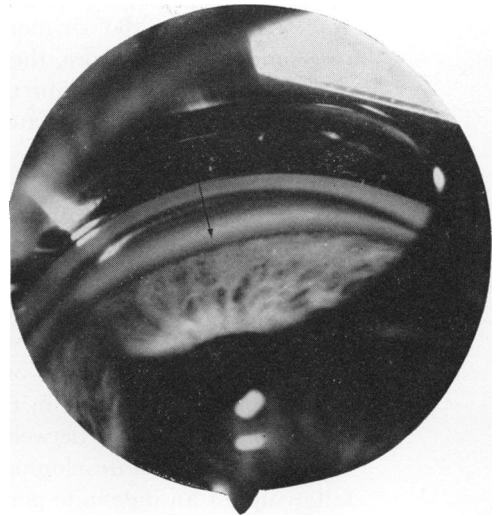

FIG. 6 Case 3. Corresponding area of uninjured eye, showing normal angle (arrow)



FIG. 7 Case 4. Extensive deep angle recession



FIG. 8 Case 4. Corresponding area of uninjured eye

between 3 and 10 years of injury had glaucoma. The four cases of late glaucoma had more than 180° of angle recession.

Alper (1963) noted fourteen cases of glaucoma in his series of 27 cases; eight of these were diagnosed within 4 years of injury and the remaining six cases more than 14 years after trauma. Five of these late cases had 240° or more of angle recession and the remaining case had 150° of recession. His findings tend to support Blanton's observation that there are two peak incidences of glaucoma.

Tönjum (1968) diagnosed one case of glaucoma 6 years after injury (with more than 270° of recession) in his series of 160 cases.

From the observations of Alper (1963), Blanton (1964), and Tönjum (1968), it is clear that the cases most at risk of developing late chronic unioocular glaucoma are those with

angle recession of 180° or more. Ten of the eleven cases described by these authors had recession of 180° or more, the remaining case having recession of 150° .

As would be expected from the findings of Wolff and Zimmerman (1962), the gonioscopic appearances of early and late cases of angle recession differ in some respects. In cases examined soon after injury, the cleft into the face of the ciliary muscle is sharply demarcated, whereas in late cases the cleft is no longer so clearly defined because of the process of healing and fibrosis which occurs in association with the development of a hyaline membrane over the angle structures. In late cases, angle recession may be overlooked unless careful comparison is made with the uninjured eye. Some of the gonioscopic findings found in the present series of cases are shown in Figs 3 to 8.

The patient described above cannot yet be labelled as a case of concussion glaucoma, as the optic disc and field of vision are normal, but it would appear, in view of his marginally raised tension in the injured eye and, in particular, the significant difference in intraocular pressure between the injured and uninjured eye (5 to 7 mm. Hg), that he is in the early stage of development of chronic uniocular glaucoma, and will require careful follow-up for an indefinite period.

Conclusion

The management of cases of angle recession poses several problems. It would appear that those with less than 180° of recession are extremely unlikely to develop late glaucoma and these cases need not be followed; however, up to 8 per cent. of cases with 180° or more of recession may eventually develop late glaucoma. If these cases are not detected at an early stage, the patients concerned are not likely to seek medical advice until considerable visual impairment has resulted from the development of glaucoma. It seems a lot to expect patients to continue to attend the clinic for a check-up for as long as 20 years after sustaining what may appear to have been a trivial injury; nevertheless, an attempt should be made to check the intraocular pressure in all cases of angle recession of 180° or more, annually for an indefinite period.

Summary

Angle recession and intraocular pressures are described in a series of 42 cases examined between 11 and 14 years after traumatic hyphaema. The literature on the subject of concussion glaucoma is discussed and suggestions are made regarding the management of patients with 180° , or more, of angle recession.

I wish to thank Mr. J. N. Ormrod and Mr. C. G. F. Munton for allowing me to examine their patients and Mrs. M. Bird for secretarial assistance.

References

- ALPER, M. G. (1963) *Arch. Ophthalm. (Chicago)*, **69**, 455
 BLANTON, F. M. (1964) *Ibid.*, **72**, 39
 D'OMBRAIN, A. (1944) *Med. J. Aust.*, **2**, 112
 ——— (1945) *Trans. ophthalm. Soc. Aust.*, **5**, 116
 ——— (1946) *Ibid.*, **6**, 129
 ——— (1949) *Brit. J. Ophthalm.*, **33**, 495
 MOONEY, D. (1972) *Ibid.*, **56**, 418
 PETTIT, T. H., and KEATES, E. U. (1963) *Arch. Ophthalm. (Chicago)*, **69**, 438
 REESE, A. B. (1944) *Amer. J. Ophthalm.*, **27**, 1193
 TÖNJUM, A. M. (1968) *Acta ophthalm. (Kbh.)*, **46**, 886
 WOLFF, S. M., and ZIMMERMAN, L. E. (1962) *Amer. J. Ophthalm.*, **54**, 547