

# Experiments on refractive keratoplasty

O. P. AHUJA AND K. C. MALHOTRA

*Institute of Ophthalmology, Jawaharlal Nehru Medical College, Aligarh Muslim University, Aligarh (U.P.), India*

Spectacle correction for eyes with refractive errors is still the most widely used method, but very high-powered spectacle lenses, besides their unpleasing appearance, have the inherent drawbacks of spherical and chromatic aberrations, prismatic effects, and limitation of the visual fields.

Contact lenses present their own problems in the form of intolerance, allergy, irritation, and conjunctival and corneal lesions.

Several workers have attempted to change the refractive state of the eye by corneal surgery.

Barraquer (1949) and Poyales (1950) resected a ring of corneal tissue in the periphery in order to flatten the cornea in high myopes. Barraquer gave the name "refractive keratoplasty" to this procedure. Sato (1955) made multiple radial incisions in the anterior and posterior surface of the cornea, and achieved an improvement ranging from 1.5 to 7 dioptres in 72 eyes. Krwawicz (1963) performed partial lamellar resection of the middle layers of the corneal stroma in rabbits without disturbing the anterior or posterior surface. In 1964, he performed this operation on three myopic human patients and reported satisfactory results.

After several years of laboratory research, Barraquer (1965) described specially prepared lenses of known dioptric power made from homogeneous corneal donor material. These lenses were introduced into an interlamellar pocket of aphakic eyes in order to correct hypermetropia. He termed this procedure "keratophakia".

Martinez and Katzin (1965) described other methods and special instruments which could be used to obtain corneal lenses with a positive or negative dioptric power, as desired.

Barraquer (1965) described the procedure of "keratomileusis" for the correction of myopia. A lamellar disc is removed from the cornea and after it has been turned on a lathe to change it into a negative lens, it is stitched back onto its bed. The results were satisfactory in twelve human eyes.

## **Present study**

The present study was undertaken on fifty healthy adult albino and pigmented rabbits of both sexes with an average weight of 1.5 kg. All had clear healthy corneae. Retinoscopy was performed under 5 per cent. homatropine cycloplegia to ascertain the refractive state of the eyes, and an average was taken of the readings in two principal axes. The radius of curvature of the anterior corneal surface was determined with a keratometer. The animals were then studied in various groups, according to the experimental procedure adopted. Conjunctival swabs were cultured and suitable local antibiotics were applied until the culture was negative. Surgery was performed under an operating microscope in sterile conditions.

## GROUP I KERATECTOMY (6 eyes)

A corneal disc 6.5 mm. in diameter and 0.2 mm. deep was removed from the middle portion of the cornea.

## GROUP II LAMELLAR INCLUSION (7 eyes)

A de-epithelialized graft, 6.5 mm. in diameter and 0.2 mm. thick, was taken from the left cornea of seven rabbits. This disc was then inserted into an interlamellar pocket in the right cornea of the same animal (autografts).

## GROUP III STROMECTOMY (6 eyes)

A disc 6.5 mm. in diameter and 0.1 mm. thick was removed from the mid-stromal layers.

## GROUP IV KERATOPHAKIA (25 eyes)

This group consisted of those animals in which specially prepared corneal tissue lenses (autogenous) of known and unknown power were inserted into an interlamellar pocket of the cornea:

- (A) A plano-convex lens of unknown power was prepared from the enucleated left eye of five animals. This lens was then inserted into an interlamellar pocket of the right eye of the same animals.
- (B) A corneal tissue lens with a power of +2 D sph. was prepared from the left eye of five animals and inserted into the interlamellar pocket of the right eye.
- (C) A corneal tissue lens with a power of +4 D sph. was used in five eyes.
- (D) A corneal tissue lens of -4 D sph. was used in five eyes.
- (E) A corneal tissue lens of -8 D sph. was used in five eyes.

## GROUP V CONTROL (6 eyes)

A disc (6.5 × 0.2 mm.) was dissected from the middle of the cornea and stitched back immediately to its bed to observe the changes in refraction, if any, produced by this operative procedure alone.

The eyes were treated postoperatively with local tetracycline drops three times a day and tetracycline ointment at night.

*Preparation of corneal tissue lenses*

The plano-convex lens of unknown power was prepared from the enucleated eyeball, which was immediately fixed in paraffin wax in a specially designed metallic cup (Fig. 1), being so placed that the cornea remained projecting above the level of the margin of the cup (Fig. 2). The cup with the eyeball was then kept at -30°C. for 24 hrs. After removal from the deep freeze, it was immediately mounted on a sliding microtome. The blade of the microtome was so adjusted as to slice the cornea at its apex at a depth of 0.2 mm. The cornea being rigid and hard after freezing, no applanation was made by the cutting blade. The piece of cornea thus removed was about 4 mm. in diameter; it had a convex surface anteriorly and was flat posteriorly. The procedure is shown diagrammatically in Fig. 3.

Lenses with a known dioptric power were also obtained from the enucleated eyeball. The cornea with a 2 mm. rim of sclera was excised and immersed in 20 per cent. glycerol for 15 min. An acrylic button, as used for the manufacture of contact lenses, was fixed at the end of the chuck of a contact lens lathe. The outer face of this button was turned into a convex surface with a radius of curvature of 7.1 mm., *i.e.* corresponding to the mean radius of curvature of the posterior surface of the rabbit cornea.




FIG. 1 *Metallic cup for designing plano-convex lens. The hole at the bottom is threaded so that it can be screwed over the table of the sliding microtome*



FIG. 2 *Placement of eye-ball in cup*

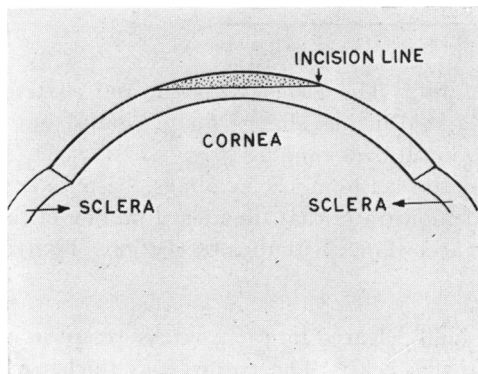


FIG. 3 *Principle of preparation of a plano-convex corneal tissue lens*



FIG. 4 *Corneo-sclera mounted on chuck before turning on a contact lens lathe*

The excised corneo-sclera was then mounted, with its endothelial surface inwards, over the processed acrylic button at the end of the chuck (Fig. 4), and the chuck with the mounted cornea was fitted into the contact lens lathe. The anterior surface of the cornea was chiselled, in a frozen state, to carve a radius of curvature of 7 mm. and a thickness of 0.25 mm. The modification of the anterior curvature of the cornea was made in accordance with the Tables provided for turning contact lenses, so as to give a power of +2 D sph. From the processed cornea a 5 mm. diameter disc was removed with a corneal trephine. This disc was then transplanted interlamellarly. Lenses of various dioptric power were prepared by the same method.

### Observations and comments

The average changes in the various groups are shown in the Table.

**Table** *Average changes in refraction and curvature*

<i>No. of rabbits</i>	<i>Group</i>	<i>Procedure adopted</i>	<i>Change in refraction (dioptres)</i>	<i>Change in radius of curvature of anterior surface (mm.)</i>
6	I	Keratotomy	+1.2	Nil
7	II	Lamellar inclusion	-8.58	-0.24
6	III	Stromectomy	+1.43	-0.10
5	IV	Keratophakia		
	A	Plano-convex lens (unknown power)	-6.5	-0.26
5	B	+2 D sph.	-7.94	-0.21
5	C	+4 D sph.	-5.31	-0.23
5	D	-4 D sph.	+2.62	+0.19
5	E	-8 D sph.	+3.66	+0.16
6	V	Control	-0.37	Insignificant

#### I (KERATECTOMY)

The postoperative period was uneventful. The cornea was clear and relatively thinner in the area of keratectomy. There was no further change for 32 weeks, but after this an increase in hypermetropia was seen in all eyes ranging from 1 to 1.75 D (average 1.2). There was no significant change in the keratometric readings, because of the removal of the disc of corneal tissue. This demonstrates that the mere thinning of the cornea can reduce its dioptric power. This is in accordance with the observations of Barraquer (1965).

#### II (LAMELLAR INCLUSIONS)

The postoperative corneal haze gradually cleared in 3 to 4 weeks except in one animal in which a marked haze persisted for 28 weeks. The cornea was thicker in the area of inclusion (Fig. 5).

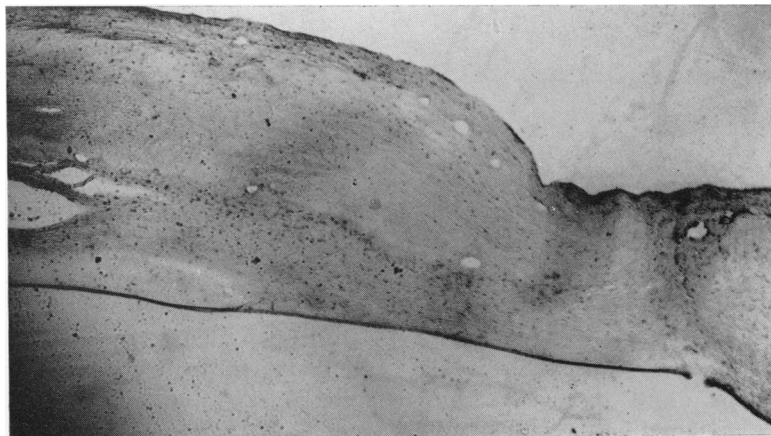


FIG. 5 *Increase in thickness of host cornea 28 weeks after a lamellar inclusion. The transplanted cornea is relatively acellular. Haematoxylin and eosin.  $\times 232$*

The final change in refraction was towards myopia, range 6 to 10 D (average 8.58). There was a decrease in the radius of curvature of the anterior corneal surface of 0.19 to 0.31 mm. (average 0.24). The development of myopia was probably due to the increase in corneal thickness combined with the increase in the anterior corneal curvature.

After the insertion of the lamellar disc, the edges of the incision made to create the interlamellar pocket are brought together by sutures. The addition of the graft to the tissues, which are already closely packed, must lead to certain changes to make room for itself. The graft may be expected to push out the corneal tissue of the host both forwards and backwards, but there is a greater resistance at the back because of the intra-ocular pressure, so that the greatest change is that in the anterior surface.

Thus, while additional corneal tissue increases the refractive power of the cornea, as observed by Barraquer (1965), it also increases the corneal curvature.

### III (STROMECTOMY)

The postoperative corneal haze gradually cleared in all but two eyes. The cornea was thinner in the area of stromectomy, and after 28 weeks the eyes became more hypermetropic (range 0.5 to 2.5 D; average 1.43). There was an insignificant reduction (0 to 0.1 mm.; average 0.06) in the radius of curvature of the anterior corneal surface. The change in refraction was due to the decreased thickness of the cornea.

### IV A (PLANO-CONVEX LENS)

The postoperative corneal haze gradually cleared except in one eye. The cornea was relatively thicker in the central zone. All the eyes became more myopic (range 4.5 to 8.5 D; average 6.5). The radius of curvature decreased (range 0.2 to 0.35 mm.; average 0.26). This change in refraction was due to the increased thickness and curvature of the cornea.

### IV B (+ 2 D SPH. LENS)

The postoperative corneal haze gradually cleared except in one eye. The central zone of the cornea was relatively thicker. After 24 weeks myopia developed (range 7 to 10 D; average 7). The radius of curvature of the anterior corneal surface decreased by 0.18 to 0.26 mm. (average 0.21). The change in refraction was due to the increased thickness (Fig. 6, overleaf) and anterior curvature.

The change in refraction brought about by this lens was much greater than its dioptric value, and this may be due to two factors:

- (1) The tissue lens, not being rigid like plastics, remoulds itself according to the curvature of the host cornea once it is firmly secured into the interlamellar pocket, so that its original dioptric power is modified.
- (2) The tissue lens increases the thickness as well as the curvature of the host cornea, thereby increasing the dioptric power of the host cornea itself.

A large number of experiments with lenses of varying dioptric power and thickness may enable us to determine the relationship between the dioptric power of the lens and the change in refraction it is likely to produce.

### IV C (+ 4 D SPH. LENS)

The postoperative haze gradually cleared in all eyes in 4 to 6 weeks, and myopia developed

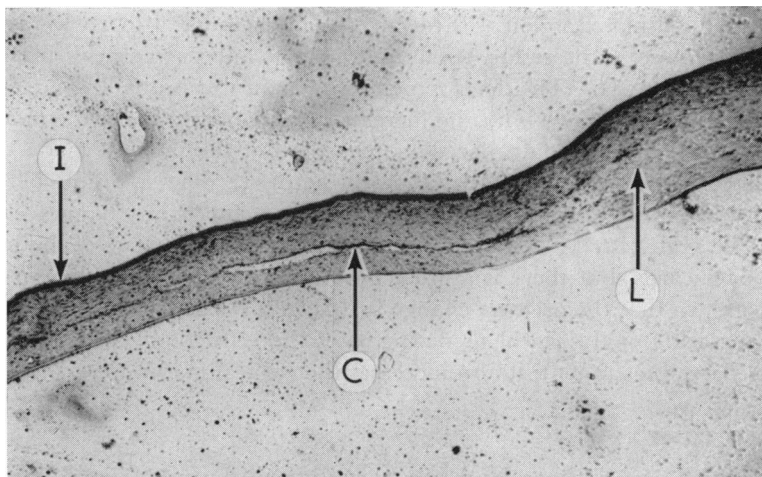


FIG. 6 24 weeks after insertion of a +2 D sph. lens into the interlamellar pocket, showing incision (I), cleavage line of pocket (C), and margin of corneal tissue lens (L). The lens with reduced cellularity is thinner at the margins, becoming gradually thicker towards the centre. Haematoxylin and eosin.  $\times 80$

(range 3.5 to 8 D; average 5.31). The radius of curvature was reduced by 0.16 to 0.23 mm. (average 0.2 mm.). The factors leading to a change greater than the dioptric power of the lens are discussed above.

#### IV D (−4 D SPH. LENS)

The retinoscopic and keratometric readings could not be taken in two eyes because of marked central corneal haze. Hypermetropia developed in the other three eyes (range 2 to 3.25 D; average 2.6). The radius of curvature increased (range 0.16 to 0.25 mm.; average 0.19).

In these experiments the addition of corneal tissue should have increased the refractive power of the cornea, but the actual change was in the opposite direction. This may be explained by the different thickness of the cornea in the central and peripheral zones. These lenses are thinner in the centre, and the increase in thickness of the host cornea was greater in the peripheral region, which would cause a relative flattening in the central zone. This conjecture is supported by the measurements of corneal curvature; there was an increase in the radius of curvature of the anterior corneal surface, the keratometric measurements having been made in the central zone.

#### IV E (−8 D SPH. LENS)

The average change in refraction towards hypermetropia was 3.6 D (range 2 to 4.25). One cornea remained hazy until the end of the observation period of 24 weeks. The radius of curvature increased (range 0.14 to 0.21 mm.; average 0.16). The effect of the increased corneal thickness was more than counter-balanced by the decrease in the corneal curvature.

#### GROUP V (CONTROL)

In this group no significant change was seen in either the refractive state or the corneal curvature. The change in refraction ranged from −0.5 to +0.25 D (average −0.37). The change in radius of curvature ranged from +0.07 to −0.12 mm. (average −0.07).

## Conclusion

To summarize, an addition to corneal tissue usually enhances its refractive power, while the removal of tissue has the opposite effect. This holds good as long as a disc with parallel surfaces is added or removed. The effect can be further enhanced or even reversed if there is a significant difference in the thickness of the peripheral and central zones of the corneal tissue lens. A direct numerical transfer of the dioptric value to the host cornea is not achieved, because lenses lose their specified power when remoulded between the lamellae of the host cornea, and also because they modify the curvature of the host cornea.

Although the techniques and procedures of the present investigation are too crude for use on human eyes, we have shown that the preparation of corneal tissue lenses with a pre-determined dioptric value and their transplantation into an interlamellar pocket of the host cornea are technically and surgically feasible. The graft is well tolerated and the refraction changes in the expected direction. Further research may enable us to devise a method by which an exact change of refraction in a particular eye can be brought about.

## Summary

Experiments were carried out in an effort to change the refraction of rabbit eyes by corneal surgery. Corneal tissue lenses with various dioptric values (both positive and negative) were designed and transplanted interlamellarly. The principles involved in the refractive changes so induced are discussed.

We are grateful to Mr. D. Kumar, Head of the Contact Lens Department, Gandhi Eye Hospital, Aligarh, for advice and for providing facilities in the Department.

## References

- AKIJAMA, K. (1955) *Acta Soc. ophthal. jap.*, **59**, 294  
BARRAQUER, J. I. (1949) *Cited by Barraquer* (1965)  
——— (1965) In "The Cornea". I. World Congress, 1964, ed. J. H. King and J. W. McTigue, p. 586. Butterworth, London  
KRWAWICZ, T. (1963) *Klin. oczna*, **32**, 1  
——— (1964) *Amer. J. Ophthal.*, **57**, 828  
MARTINEZ, M., and KATZIN, H. M. (1965) In "The Cornea". I. World Congress, 1964, ed. J. H. King and J. W. McTigue, p. 605. Butterworth, London  
PAHWA, J. M. (1966) *Proc. All-India ophthal. Soc.*, **23**, 115  
POYALES, A. (1950) *Cited by Pahwa* (1966)  
SATO, T. (1955) *Cited by Akijama* (1955)