

Electroretinal responses in ocular vascular occlusions due to temporal arteritis

DAVID McLEOD*

Department of Ophthalmology, University of Edinburgh

Temporal arteritis is a potentially blinding disease of the elderly; its effects are principally due to inflammatory obliteration of the arterial supply to the retina and the optic nerve head. The ophthalmic artery and the extraocular course of the central retinal and posterior ciliary arteries may be involved singly or in combination. The usual presenting feature in these cases is acute ischaemic optic neuropathy due to diminished posterior ciliary artery perfusion; central retinal artery occlusion is less frequently seen.

The central retinal artery (CRA) and cilio-retinal arteries, when present, supply the inner layers of the retina by capillary plexus (Michaelson, 1954). In experimental CRA occlusion, with generalized ischaemic necrosis of the ganglion cells and most of the inner nuclear layer, the positive b-wave of the electroretinogram (ERG) is diminished, and an augmented negative a-wave results from unmasking of the PIII component of Granit (1933) which is generated in the receptor layer (Brown, 1968). Granit's PII component, responsible for the b-wave of the ERG, is generally considered to originate in the inner nuclear layer, possibly from the Müller cells (Dowling, 1970).

The posterior ciliary arteries (PCAs), usually two or three in number, supply the optic nerve head, the choroid posterior to the equator, and the overlying pigment epithelium and outer retina (visual receptors and outer nuclear layer) by diffusion from the chorio-capillaris (Hayreh, 1971a). Experimental PCA occlusions in monkeys cause ischaemic optic neuropathy, patches of chorioretinal atrophy, and a subnormal ERG, with proportionate reduction in a- and b-waves (Hayreh and Baines, 1972b, c; McLeod and Hayreh, 1972).

There are several reports in the literature of the ERG responses in patients with temporal arteritis (Palm, 1958; Younessian, 1962; Burian, 1963; Edmund and Jensen, 1967). However, the role of PCA insufficiency in ischaemic optic neuropathy has only recently been fully appreciated (Hayreh, 1969, 1971b) and the influence of PCA occlusion on the ERG in temporal arteritis has not previously been taken into account.

Patients with visual loss due to temporal arteritis were studied by electroretinography (ERG), electro-oculography (EOG), and intravenous fluorescein angiography (IVFA); the last technique has not previously been used in ERG studies in this condition. The varying ERG responses recorded in these patients illustrate a number of interesting features of the ERG in ocular vascular occlusive disorders. The EOG was also recorded, as it has been considered to be a sensitive index of the metabolic activity of the pigment epithelium-receptor complex (Arden, Barrada, and Kelsey, 1962); however, no significant EOG abnormality was generally found in ischaemic optic neuropathy.

Material and methods

ERG and EOG were recorded in twelve patients with temporal arteritis. The diagnosis was based on the history, elevated erythrocyte sedimentation rate, and biopsy of the superficial temporal artery. All patients were normotensive for their age and received oral prednisolone (60 to 100 mg. daily) on presentation. The pattern of arterial occlusion was determined by the clinical picture and by IVFA.

Scotopic ERGs were recorded by means of contact lens electrodes (Echte and Papst, 1962) in response to a brief flash stimulus of variable intensity from a flash Tac Stroboscope (Electronic Applications (Commercial) Ltd.); the oscilloscope recording system incorporated a computer of average transients. Examination of ERGs in response to a range of stimulus intensities was necessary in order to categorise the ERG changes. The terminology introduced by Karpe (1945) and Henkes (1953) was used to describe the ERGs, as defined below:

(a) Normal ERG

This was an ERG with a maximal b-wave amplitude of 200-450 μV (as measured from the trough of the a-wave); the a-wave amplitude at high stimulus intensities increased to 80 to 150 μV , but was less than 50 per cent. of the b-wave amplitude (Fig. 1).

(b) Subnormal ERG

This was an ERG with a maximal b-wave amplitude less than 200 μV ; the a-wave amplitude at higher stimulus intensities was proportionately reduced producing an ERG of normal configuration (with the a-wave less than 50 per cent. of the b-wave) but subnormal a- and b-waves (Fig. 1).

(c) Negative (–) ERG

This was an ERG with maximal b-wave amplitude less than 200 μV ; the a-wave amplitude at higher stimulus intensities was normal or increased producing an ERG of abnormal configuration (with the a-wave more than 50 per cent. of the b-wave). The negative (–) ERG could be indistinguishable from the subnormal ERG at low stimulus intensities (Fig. 1).

(d) Negative (+) ERG

This was an ERG with a normal maximal b-wave amplitude (200 to 450 μV as measured from the trough of the a-wave); the a-wave amplitude at higher stimulus intensities was excessive, *i.e.* over 150 μV and/or more than 50 per cent. of the b-wave amplitude. The negative (+) ERG may be indistinguishable from a normal ERG at lower stimulus intensities (Fig. 1); some negative (+) ERGs represent an intermediate stage between the normal and the negative (–) response.

(e) Subnormal-Negative ERG

This was an ERG with no positive deflection above the isoelectric line and a subnormal a-wave (less than 80 μV) at high stimulus intensities. The subnormal-negative ERG could appear “extinguished” except at high stimulus intensities (Fig. 1, opposite).

The EOG was recorded in the standard manner described by Arden and others (1962). In this unit, the mean Arden Ratio for the normal population over 60 years was 210 per cent. and the lower limit of normal was 160 per cent.

Results

The Table (overleaf) summarizes the pertinent clinical features and electro-retinal responses in twelve patients with visual loss attributable to temporal arteritis in one (9 out of 12) or both (3 out of 12) eyes. The ERG and EOG findings in the different types of ocular vascular occlusion will be considered in more detail below:

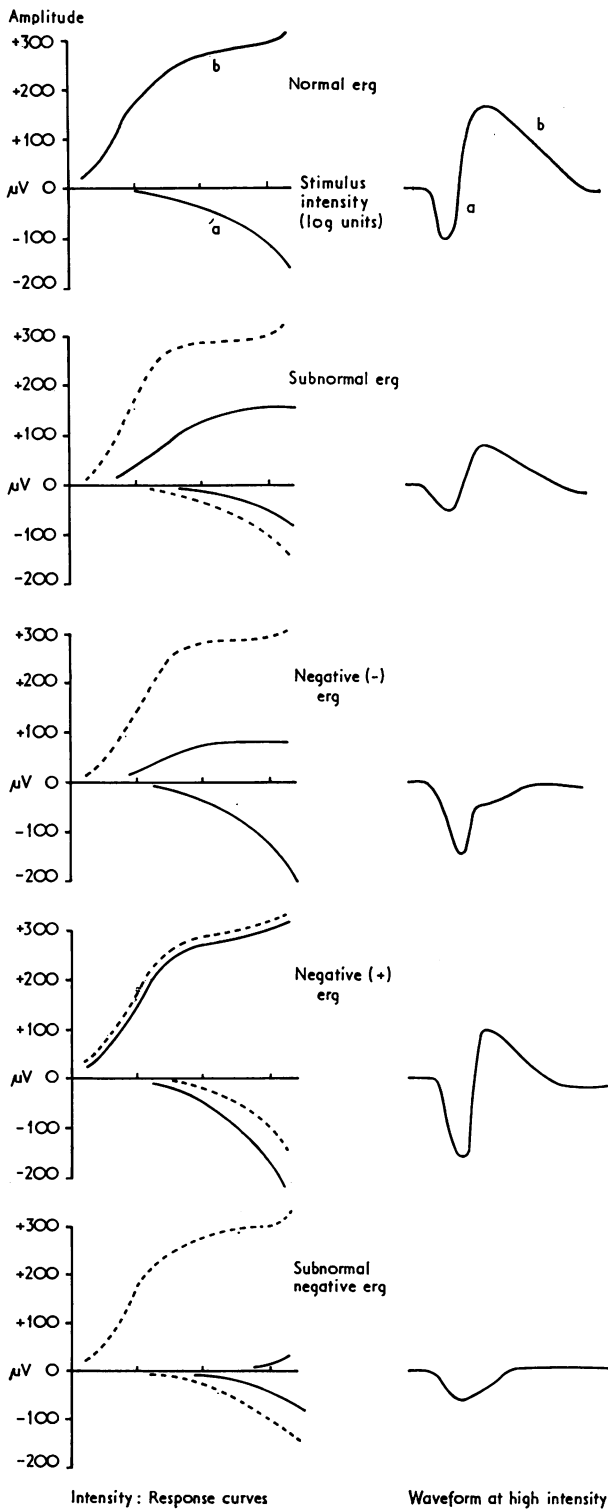


FIG. 1 *Electroretinographic responses*

Table *Particulars of twelve cases*

Case no.	Age (yrs)	Sex	Presentation		Visual field		Electroretinogram (Configuration/amplitude of wave μV)				Electro-oculogram (Arden Ratio)		
			Right	Left	Right	Left	Days of steroid treatment	Right	Left	Right	Left		
1	68	M	CRAO (Fig. 2)	-	No PL	Normal	2	Neg. -	a = 130 b = 120	Normal	a = 100 b = 240	175	220
2	80	F	-	ION	Normal	No PL	1	Normal	a = 80 b = 240	Normal	a = 90 b = 240	190	180
3	72	F	ION (Fig. 3)	-	No PL	Normal	1	Neg. +	a = 170 b = 270	Neg. +	a = 170 b = 270	205	210
					No PL	Normal	26	Normal	a = 110 b = 270	Neg. +	a = 120 b = 240	190	200
4	75	M	ION	-	No PL	Normal	1	Neg. -	a = 130 b = 130	Neg. -	a = 130 b = 140	170	170
					PL	Normal	70	Normal	a = 100 b = 320	Neg. +	a = 130 b = 250	180	170
5	76	F	ION	-	PL	Normal	0	Normal	a = 100 b = 250	Normal	a = 80 b = 260	210	220
6	80	F	-	ION	Normal	No PL	10	Normal	a = 80 b = 250	Normal	a = 80 b = 200	225	180
					Normal	No PL	360	Normal	a = 70 b = 230	Normal	a = 70 b = 200	215	190
7 \oplus	78	M	ION	ION (Fig. 4)	NFBFD	NFBFD	100	Normal	a = 70 b = 210	Normal	a = 90 b = 280	280	350
					NFBFD	NFBFD	500	Normal	a = 70 b = 230	Normal	a = 80 b = 260	225	255
8	80	M	ION**	-	No PL	Normal	200	Subn.	a = 50 b = 140	Normal	a = 80 b = 230	130	175
					No PL	Normal	220	Subn.	a = 50 b = 140	Normal	a = 80 b = 220	125	165
9	87	F	(?CRAO** + ION)	ION*	No PL	No PL	1	Sub/Neg.	a = 30 b = 0	Normal	a = 70 b = 220	---	---
					No PL	No PL	10	Sub/Neg.	a = 40 b = 0	Normal	a = 70 b = 230	---	---
10	71	F	SBRAO + ION	-	No PL	Normal	1	Neg. -	a = 130 b = 130	Normal	a = 130 b = 390	110	175
					No PL	Normal	8	Neg. +	a = 160 b = 340	Normal	a = 130 b = 400	160	190
11	73	M	ION + CRAO (Fig. 5)	-	No PL	Normal	40	Normal	a = 100 b = 320	Normal	a = 120 b = 380	---	---
					PL	Normal	1	Sub/Neg.	a = 40 b = 0	Neg. -	a = 140 b = 150	100	200
12	72	F	ION** + CRAO (Fig. 6)	ION*	No PL	Normal	10	Neg. -	a = 110 b = 110	Neg. -	a = 130 b = 150	220	245
					No PL	Normal	120	Neg. -	a = 130 b = 120	Neg. +	a = 130 b = 230	185	205
12	72	F	ION** + CRAO (Fig. 6)	ION*	No PL	NFBFD	250	Sub/Neg.	a = 60 b = 20	Normal	a = 100 b = 330	110	190

Key to Table

\oplus = No biopsy confirmation of arteritis
 * = Patches of chorioretinal degeneration present
 ** = (* less extensive than **)
 a = a-wave amplitude in microvolts
 b = b-wave amplitude in microvolts
 CRAO = Central retinal artery occlusion
 ION = Ischaemic optic neuropathy

Neg. - = Negative (-) ERG
 Neg. + = Negative (+) ERG
 NFBFD = Nerve fibre bundle defects
 PL = Perception of light
 PSF = Peripheral superior field present
 SBRAO = Superior branch retinal artery occlusion
 Subn = Subnormal ERG
 Sub/ Neg. = Subnormal negative (-) ERG

(A) CRA OCCLUSION

There was only one patient in the series with an occlusion essentially localized to the retinal circulation (Case 1 in the Table). He presented with sudden complete visual loss in the right eye, and the fundus showed retinal arteriolar stasis, posterior polar oedema, and cherry-red spot at the macula. IVFA confirmed that the arterial occlusion was localized to the retinal circulation; the posterior ciliary circulation to the choroid and optic disc was normal (Fig. 2).

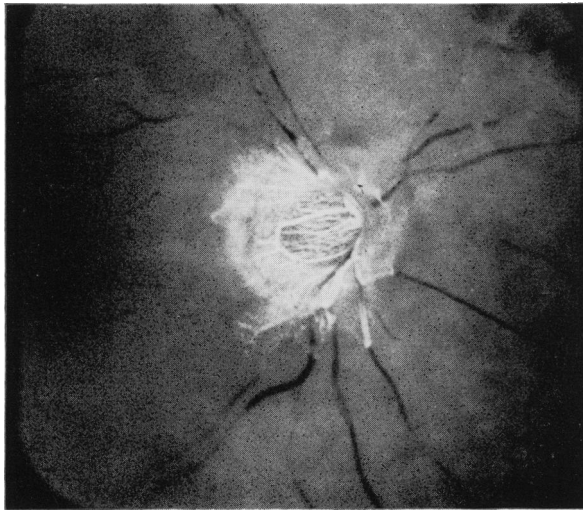


FIG. 2 *Fluorescein fundus angiogram of right eye of Case 1 (Table), 15 sec. after injection of dye. There is no filling of the retinal vessels with fluorescein, while the circulation to the choroid and optic disc has filled normally. The angiogram was performed 2 days after the occurrence of (and presentation with) acute visual loss and the institution of systemic steroid therapy*

Electroretinography showed selective loss of the b-wave (the negative (—) ERG); the EOG light-rise, though reduced, remained within normal limits (Table).

(B) ISCHAEMIC OPTIC NEUROPATHY

Acute ischaemic optic neuropathy was the presenting feature in ten eyes from Cases 2 to 9 and Case 12 (Table).

(i) *Fundus changes*

The principal sign was ischaemic oedema of the optic disc, sometimes accompanied by a few peripapillary haemorrhages; in none of these cases were there signs of CRA occlusion. The optic disc subsequently became atrophic and sometimes cupped, and in Cases 8, 9, and 12, patches of pigment epithelial degeneration and chorio-retinal atrophy were observed in the fundus posterior to the equator.

(ii) *IVFA*

The retinal arterial circulation was within normal limits, but delayed and patchy filling of the choroid and optic disc vessels was evident in all cases in which IVFA was possible immediately on presentation (*i.e.* in all except Cases 8, 9, and 12). The pattern of filling defect in the choroid was variable, *e.g.* in Case 3, there was generalized delay in choroidal filling and no filling of the peripapillary choroid and associated optic disc vessels (Fig. 3), while in Case 7 there was delayed filling of the choroid and disc vessels in the distribution of the lateral PCA (Fig. 4). In these cases, except for the peripapillary choroid, the rest of the choroid was observed to fill with fluorescein by the venous phase of the retinal circulation (normally the entire choroid fills completely during the arterial phase).

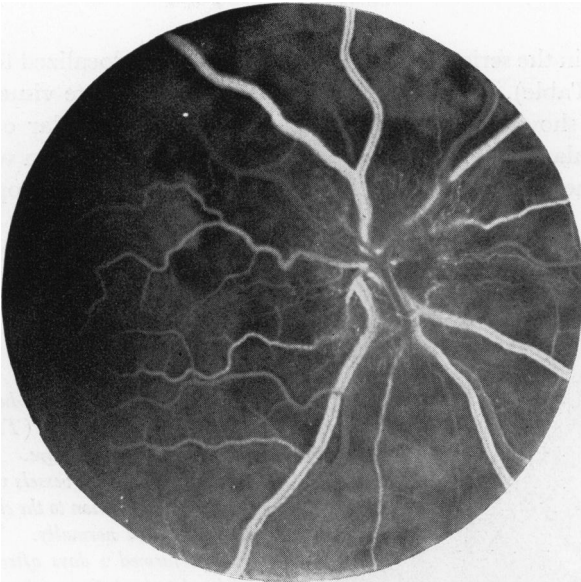


FIG. 3 Fluorescein fundus angiogram of right eye of Case 3 (Table), during retinal venous phase of dye transit. The peripapillary choroid and optic disc vessels failed to fill at any stage of the dye-transit, and the non-filling zone, within a disc diameter of the optic disc, is clearly demarcated from the surrounding choroid which filled in the venous phase of the retinal circulation. The intraocular pressure was 14 mm. Hg. The angiogram was performed one day after the occurrence of (and presentation with) acute visual loss and the institution of systemic steroid therapy

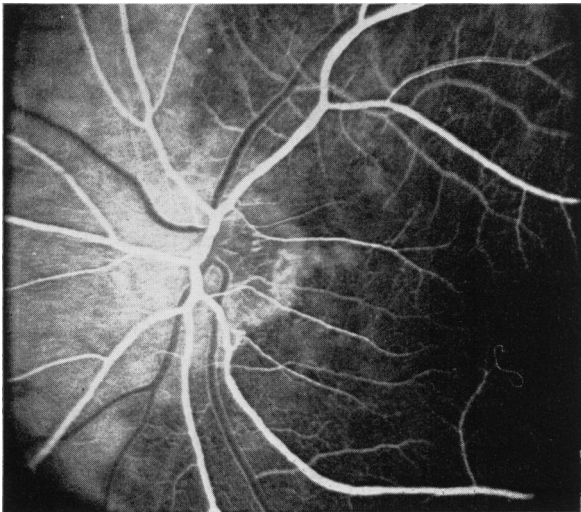


FIG. 4 Fluorescein fundus angiogram of left eye of Case 7 (Table), during early arteriovenous phase of retinal circulation. There is delayed filling of the choroid and associated optic disc vessels in the distribution of the lateral posterior ciliary artery. The angiogram was performed 6 weeks after the onset of visual symptoms and 4 days after presentation and the institution of systemic steroid therapy

(iii) ERG and EOG

In the acute stage, three types of ERG response were seen: normal (3 eyes), negative (+) (1 eye), and negative (—) (1 eye). After some days or weeks of steroid therapy, the usual response was one of normal configuration and amplitude (8 out of 9 eyes); in Cases 3 and 4, “normalization” of the ERG occurred. In Case 8, the late ERG was subnormal (Table).

The EOG was within normal limits in all cases except Case 8, though in Case 7, the EOG might be interpreted as “supernormal” (Foulds, Lee, and Taylor, 1971).

(c) COMBINED CRA AND PCA OCCLUSION

In the right eyes of Cases 10, 11, and 12, funduscopy indicated that ischaemic optic neuropathy was combined with retinal artery stasis, and involvement of both retinal and

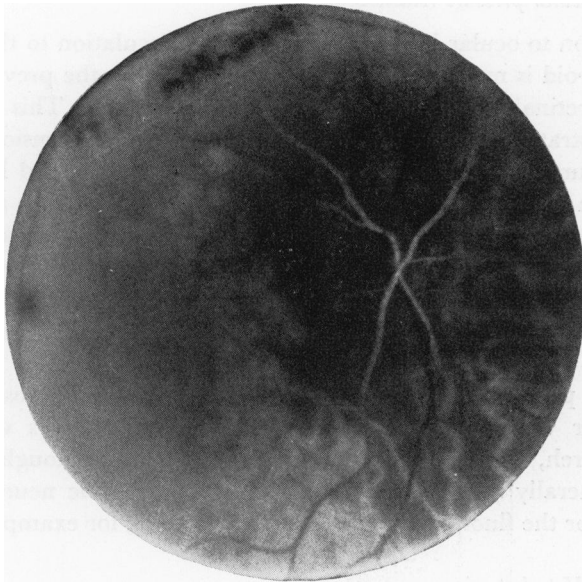


FIG. 5 Fluorescence fundus angiogram of right eye of Case 11 (Table), 50 sec. after the injection of dye. There is no filling of the peripapillary choroid and associated optic disc vessels, and poorer filling of the choroid in the distribution of the medial posterior ciliary artery than that in the distribution of the lateral posterior ciliary artery. There is very gradual filling of the retinal arterioles with gross sludging in the blood column. The angiogram was performed 7 days after the occurrence of acute visual loss and one day after presentation and the institution of systemic steroid therapy. The combination of medial PCA and CRA obstruction probably reflects their common origin from the ophthalmic artery

choroidal circulations was confirmed by IVFA, *e.g.* Fig. 5 from Case 11. This could be due either to combined CRA and PCA obstruction, or to ophthalmic artery occlusion, or both. Such a situation is also surmised in the right eye of Case 9, in which nuclear sclerosis obviated a detailed examination of the posterior pole.

The initial ERGs were entirely negative in Cases 9, 10, and 11; in Cases 9 and 11, the receptor component was much reduced, producing a subnormal-negative response. EOGs in Cases 10 and 11 were initially flat and the standing potential was reduced by over 50 per cent. In Cases 10 and 11, striking ERG changes were seen within a few days of treatment with steroids and Diamox, and there was some associated improvement in choroidal filling on IVFA. In Case 11, the a-wave of the ERG increased from 40 to 110 μ V and a small positive b-wave developed (producing a negative (-) ERG identical with that of "isolated" CRA occlusion (Case 1, Table); in Case 10, there was a considerable increase in the b-wave, and the negative (-) ERG changed to negative (+), which is the response commonly seen in arteriosclerotic branch retinal artery occlusion (Henkes, 1954). Similarly, a considerable EOG revival was seen in Cases 10 and 11; the standing potential increased and the Arden Ratio returned to the normal range. Cases 9 and 12 showed persisting subnormal-negative ERGs.

(D) THE "UNAFFECTED" EYE

Despite the normal visual acuity, visual field, and fundus appearance in the unaffected eye of the nine unilateral cases, significant ERG abnormalities were found in three of these eyes (Cases 3, 4, and 11), of either the negative (+) or negative (-) type; in Cases 4 and 11, the diminution in the b-wave of the ERG was associated with an EOG within the normal range.

Discussion

There are three important considerations in the interpretation of electrophysiological changes in ocular vascular occlusive disorders producing retinal ischaemia, and in correlation with the angiographic pattern of blood flow:

(i) *Vascular perfusion: Intraocular pressure relationship*

When there is an obstruction to ocular blood flow, the ciliary circulation to the optic disc from the peripapillary choroid is more susceptible to obliteration by the prevailing intraocular pressure than the retinal and general choroidal circulations. This relationship has been repeatedly demonstrated in experimentally induced ocular hypertension, especially when the intraocular pressure was sustained at a constant level (Ernest and Potts, 1968), and was most evident when the CRA had previously been occluded (Hayreh and Perkins, 1969, 1971; Swietliczko and David, 1970). In clinical ophthalmodynamo-angiographic studies (with intraocular pressure falling steadily from above the ophthalmic artery pressure), this relationship tends to be obscured (Archer, Ernest, and Krill, 1972), but Blumenthal, Best, Galin, and Gitter (1971) observed a zone of particular peripapillary ischaemia in some cases.

This susceptibility of the peripapillary choroid and optic disc vessels to closure was also demonstrated when ocular vascular perfusion was reduced in monkeys with normal intraocular pressure (Hayreh, Revie, and Edwards, 1970), and, although a reduced intraocular pressure is generally seen in patients with ischaemic optic neuropathy, this relationship may account for the fluorescein perfusion pattern seen, for example, in Fig. 3.

(ii) *Sensitivity of PII and PIII to hypoxia*

In conditions producing generalized ocular ischaemia, the receptor component of the ERG (PIII or a-wave) is far more resistant to hypoxia than the PII component or b-wave (Granit, 1933). Thus, a selective loss of the b-wave results in a negative ERG, *e.g.* in electroretinodynamographic studies in carotid artery disease (Wulfing, 1963) and in partial arteritic ophthalmic artery obstruction causing maximal ischaemia in the optic nerve head. Hence, ischaemic optic neuropathy may be associated with a negative (—) ERG (the response usually associated with CRA occlusion).

Indeed, a subnormal b-wave and negative (—) ERG may be seen in the presence of a normal visual acuity, visual fields, and fundus, *e.g.* in two of the “unaffected” eyes in this series (Cases 4 and 11 in the Table), though diminished perfusion pressure in the CRA was evident on ophthalmodynamometry in these cases. This ERG abnormality most probably reflects the sensitivity of the positive wave to diminished perfusion, and has previously been reported in the unaffected eye of patients with arteriosclerotic CRA occlusion (Henkes, 1954). This may indicate that the b-wave is not directly related to bipolar cell discharge.

(iii) *Revival capacity*

Revival of the EOG and of individual elements of the ERG was seen in this study. Thus revival can occur even after prolonged ischaemia, provided irreversible structural changes (infarction of the inner retina or chorio-retinal atrophy) do not occur. This phenomenon appears to be a particular feature of temporal arteritis, presumably related to the capacity for early restoration of an adequate circulation after steroid therapy. The time interval between the institution of steroid therapy and ERG recordings is thus of great importance, as has also been stressed by Burian (1963); the role of steroid therapy *per se* has not been evaluated.

There are, however, important limitations in the interpretation of EOG and ERG data in patients with temporal arteritis:

(1) *Lack of premorbid data*

In most cases, since no preocclusion clinical or electrophysiological data are available, it is difficult to assess the findings at the first examination after the visual loss. Patients with temporal arteritis are elderly, so that pre-existing senile changes may affect the ERG, *e.g.* by subnormal or negative responses. The influence of such factors, however, is likely to be less important in temporal arteritis than in cases in which occlusions complicate hypertension or arteriosclerosis.

(2) *Normal amplitude range*

Within each age-group, there is a very wide range of ERG amplitude (Peterson, 1968). A substantial reduction in amplitude (*e.g.* over 50 per cent.) may therefore occur and the ERG may still remain within the normal range. A difference of up to 25 per cent. between the two eyes can also be regarded as normal variation, so that, even in unilateral occlusions, changes must be interpreted with caution.

(3) *Temporal variations*

Considerable physiological variations in the ERG occur with time (Spivey and Pearlman, 1963), and similar temporal variations in the EOG have been reported by Kelsey (1967) and van Lith and Balik (1970); these changes are often parallel between the two eyes. This is of importance when postulating revival.

(4) *Summation of factors*

While severe hypoxia and anoxia diminish the ERG, milder degrees of hypoxia may augment the ERG—the “hyperexcitability response” (Henkes, 1954); such factors may underlie some negative (+) responses. A supernormal response has also been reported after optic nerve damage, *e.g.* after optic nerve section (Gills, 1966) and in traumatic ischaemic optic neuropathy (Wyllie, McLeod, and Cullen, 1972); no increase in the ERG was found after experimental optic nerve section however (Brindley and Hamasaki, 1962; Winkler, 1972). The ERG in temporal arteritis thus represents the resultant of the potential operation of all these factors.

Interpretation of the electrophysiological responses has been made in the light of the various considerations and limitations mentioned above. These are as follows:

(A) CRA OCCLUSION

Patients suffering from temporal arteritis present only infrequently with an isolated CRA occlusion. The rarity of an isolated involvement of the CRA may be due to the generalized distribution of the arteritic process in the orbital arteries and the relative resistance of the retinal circulation to the effects of intraocular pressure. Histological studies reveal that the involvement of the CRA in temporal arteritis is often before its entry into the optic nerve (Henkind, Charles, and Pearson, 1970; Macmichael and Cullen, 1971); intact pial collaterals of the CRA (Hayreh, 1971c) might, therefore, maintain a certain amount of circulation in the artery distal to the block in its intraorbital course.

The ERG in arteritic CRA occlusion (Case 1, Table) differs in no way from that seen in arteriosclerotic CRA occlusion (Karpe, 1945; Henkes, 1954; Nilsson, 1971); the persistence of a small b-wave may be related to the incomplete infarction of the inner nuclear layer.

(B) COMBINED CRA AND PCA OCCLUSION

These produced the most marked ERG and EOG changes and also provided the most striking examples of revival. Complete loss of the EOG light rise was found in Cases 10 and 11, and the small negative ERG in Case 11 and the right eye of Case 9 represented an isolated but curtailed PIII component; a summation of the effects of retinal ischaemia (with loss of the b-wave) and severe choroidal ischaemia (with diminution in the a-wave) was thus evident.

Nevertheless, considerable ERG and EOG revival was subsequently observed in Cases 10 and 11, despite significant persistent choroidal underperfusion on IVFA. There was also some visual revival in Case 11; the peripheral superior visual field survived the occlusion. No significant ERG revival was observed in the right eye of Case 9 after treatment with steroids for 10 days; it is of interest that chorio-retinal atrophy was subsequently observed in the fundus posterior to the equator, accounting for the persistent subnormal-negative response, as in Case 12.

The superior branch retinal artery occlusion in Case 10 does not necessarily represent an intraocular extension of the arteritic process. In this eye, the first bifurcation of the CRA occurred behind the optic disc, so a retrolaminar arteritic obstruction could account for the branch retinal artery occlusion picture.

(C) ISCHAEMIC OPTIC NEUROPATHY

Acute infarction of the optic nerve head results from a rapidly developing imbalance between PCA perfusion and intraocular pressure, whether due to acutely raised tension (Kalvin, Hamasaki, and Gass, 1966), or to diminished perfusion in the carotid, ophthalmic or posterior ciliary arteries from arteriosclerosis or arteritis (Hayreh, 1970, 1971a).

If the arteritic process mainly involves the PCAs, complete visual loss may be associated with a normal ERG in the acute phase, *e.g.* in Cases 2 and 5, the left eye in Case 9, and in the third case described by Edmund and Jensen (1967). The degree of choroidal ischaemia in such cases is sufficient to cause complete infarction of the optic nerve head, but is insufficient to affect the ERG (and EOG). Because of the widespread distribution of the arteritic process, involvement of the ophthalmic artery (as indicated by ophthalmodynamometry) often contributes significantly to impaired posterior ciliary perfusion, and a negative ERG may ensue in the absence of fundoscopic signs of involvement of the retinal circulation. Even in these circumstances, the EOG light-rise may remain within normal limits, and appears not to be as sensitive to hypoxia as previously considered by Arden and others (1962). With systemic steroid therapy and time, the ocular circulation improves and normal ERGs and EOGs are generally seen; this indicates that the originally negative ERGs did not result from arteriosclerosis or from undetected CRA occlusion with infarction of the inner retina. In the left eyes of Cases 9 and 12, the ERG amplitude remained within the normal range despite the presence of chorioretinal atrophy.

Burian (1963) described a large negative (+) ERG in temporal arteritis before the institution of steroid therapy; surprisingly, this response was obtained irrespective of the pattern or degree of involvement of the ocular circulation (Burian, 1972) and was considered to be pathognomonic for arteritis. However, a range of acute ERG responses occurs in arteritic, and also in arteriosclerotic, ischaemic optic neuropathy, and *the ERG is of no value in differentiating these conditions.*

Previous reports have indicated that ERGs of normal configuration and amplitude are the most common late response in arteritic ischaemic optic neuropathy (Younessian, 1962; Burian, 1963; Edmund and Jensen, 1967), and the above results confirm this. This

contrasts with the consistently subnormal ERG found experimentally after PCA occlusions (McLeod and Hayreh, 1972). However, in addition to the obvious difficulties of comparing a clinical condition in elderly humans and an experimental lesion produced in young monkeys, a number of factors contribute to this discrepancy:

- (i) The gradual and incomplete arteritic occlusion of vessels contrasting with the sudden complete experimental occlusion of the PCAs.
- (ii) The difficulties in identifying subnormal ERGs clinically in view of normal variations (*vide supra*).
- (iii) The resistance of the ERG receptor-response to hypoxia and the capacity for revival (*vide supra*).

In arteritis, the establishment of collaterals and recanalization may be occurring simultaneously with occlusion; this "subtotal" posterior ciliary ischaemia is illustrated by the following:

- (i) In these patients, the choroid filled in the venous phase of the retinal circulation on IVFA. In contrast, in monkeys with experimental occlusion of the PCAs, no choroidal filling was seen during the transit of the dye on IVFA 1 hour after the occlusion, and some areas did not fill even in the late phases 10 to 15 minutes after the injection of dye (Hayreh and Baines, 1972a).
- (ii) The monkeys developed chorio-retinal lesions in the above-mentioned unfilled areas (Hayreh and Baines, 1972b). However, such atrophic patches occurred only infrequently (in five eyes) in the last twenty eyes of patients with ischaemic optic neuropathy seen in this department (Fig. 6, overleaf); some of the factors responsible for the rarity of chorio-retinal atrophic patches in these patients have been discussed elsewhere (Hayreh and Baines, 1972c).
- (iii) No report has so far appeared in the literature of a histological examination showing significant abnormality of the pigment epithelium or receptors after temporal arteritis (Henkind and others, 1970), even where gross PCA obstruction was evident (Macmichael and Cullen, 1971).

The presence of a normal ERG in arteritic ischaemic optic neuropathy is, therefore, not inconsistent with the concept that this condition results from diminished posterior ciliary perfusion. However, Case 8 provides an interesting clinical correlate of the experimental model; in this patient, the arteritic occlusion of the PCAs was presumably more sudden and complete than is generally the case, because unilateral optic atrophy and patches of chorio-retinal atrophy were the sequelae of arteritic ischaemic optic neuropathy. The late ERG on the affected side was subnormal (with a 40 per cent. reduction in amplitude compared with the normal eye), and the EOG light-rise was severely curtailed (Table). Histological examination of both eyes was performed when the patient died 18 months after presentation (Macmichael, in preparation). This revealed complete atrophy of the optic nerve on the affected side, with absence of the ganglion cells in the retina. No generalized abnormality of the outer retinal layers was seen, and there was no suggestion of previous CRA occlusion from the histological appearances of the inner nuclear layer. There were, however, localized areas of degeneration of the outer retina in keeping with the fundus appearances; as in experimental occlusion of the PCAs (McLeod and Hayreh, 1972), the extent of the retinal degeneration was less than might have been anticipated from the degree of subnormality of the ERG.

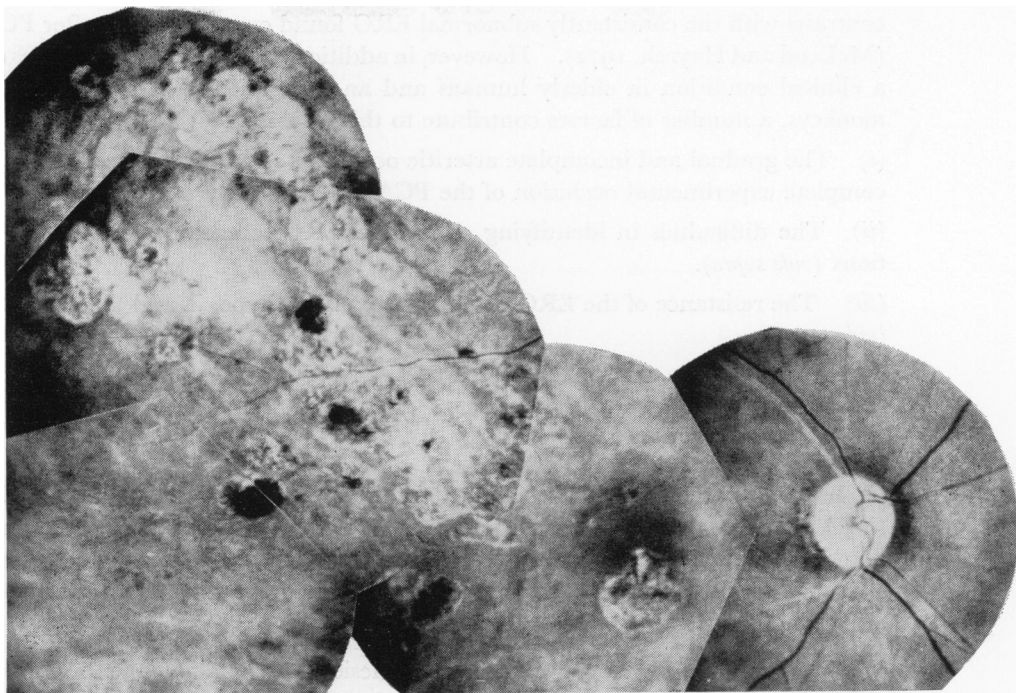


FIG. 6 Fundus photograph of right eye of Case 12 (Table), showing optic atrophy (with cupping), sectoral chorio-retinal degenerative lesions, and sheathing of the retinal arterioles 8 months after presentation. (See Hayreh and Baines, 1972, Fig. 9, p. 763)

Edmund and Jensen (1967), erroneously ascribing ischaemic optic neuropathy to arteritic occlusion of the so-called "central artery of the optic nerve", considered that the ERG should always be normal and that abnormal ERGs are the result of pre-existing retinal vascular pathology; similarly, the subnormal ERGs reported by Younessian (1962) were attributed to pre-existing arteriosclerosis. However, subnormal ERGs are more likely to be related to the effects of PCA insufficiency, even without obvious chorio-retinal degeneration, because of subclinical retinal changes not evident on ophthalmoscopy or IVFA (McLeod and Hayreh, 1972).

(D) THE "UNAFFECTED" EYE

Burian (1963) found bilateral ERG abnormalities consistently in patients with unilateral loss of vision from temporal arteritis. However, in this series, negative ERGs were found in only three of the seven "unaffected" eyes in which early ERGs could be recorded.

Where a negative ERG was present in the unaffected eye, there was a history of transient visual disturbance, evidence of diminished CRA perfusion pressure on ophthalmodynamometry, and slight choroidal delay on IVFA. However, the presence of a normal ERG in the "unaffected" eye is no indication that the eye is out of immediate danger of visual loss from arteritis; visual loss can occur without ERG change when the arteritis is mainly localized to the PCAs (*vide supra*). Indeed, in Case 1, the "unaffected" eye showed significant choroidal delay in the distribution of the lateral PCA though the ERG, EOG, and vision were normal. IVFA is thus the most useful investigation for assessment of the apparently unaffected eye in unilateral arteritic visual loss.

As indicated above, ischaemic optic neuropathy results from an imbalance between

the intraocular pressure and posterior ciliary perfusion pressure; *assessment of the intraocular pressure is thus of great importance in these cases.* The patients were given Diamox in the early stages (particularly if IVFA indicated some embarrassment of posterior ciliary perfusion in the unaffected eye), since such a therapeutic lowering of the intraocular pressure should have a beneficial "protective" effect in maintaining perfusion in the optic nerve head.

Summary

Electroretinography and electrooculography were performed in twelve patients with ocular ischaemia due to temporal arteritis in whom the degree and pattern of vascular obstruction was determined by intravenous fluorescein angiography. In some cases, both retinal and choroidal circulations were involved. The responses were found to correlate with those described in experimental occlusion of the central retinal or posterior ciliary arteries.

In eyes with significantly diminished perfusion in the retinal circulation, selective loss of the b-wave of the ERG resulted in a negative waveform with a large a-wave. The EOG light-rise was found to be less sensitive to diminished retinal perfusion.

In eyes with diminished perfusion in the posterior ciliary arteries, there was often no detectable ERG or EOG abnormality which could be ascribed to choroidal ischaemia even in eyes with complete loss of vision due to infarction of the optic nerve head. A diminution in both a- and b-waves of the ERG was found when the circulation through the posterior ciliary arteries was severely curtailed.

The various considerations and limitations in the interpretation of electrophysiological changes in ocular vascular occlusive disorders are discussed.

I am grateful to Miss K. Fowler for technical assistance, to Mrs. A. Roger for secretarial help, to Mr. A. McDonald for the illustrations, and to Drs. A. M. Wyllie, J. F. Cullen, and S. S. Hayreh for encouragement and criticism.

References

- ARDEN, G. B., BARRADA, A., and KELSEY, J. H. (1962) *Brit. J. Ophthalm.*, **46**, 449
 ARCHER, D. B., ERNEST, J. T., and KRILL, A. E. (1972) *Amer. J. Ophthalm.*, **73**, 834
 BLUMENTHAL, M., BEST, M., GALIN, M. A., and GITTER, K. A. (1971) *Ibid.*, **71**, 819
 BRINDLEY, G. S., and HAMASAKI, D. I. (1962) *J. Physiol. (Lond.)*, **163**, 558
 BROWN, K. T. (1968) *Vision Res.*, **8**, 633
 BURIAN, H. M. (1963) *Amer. J. Ophthalm.*, **56**, 796
 ——— (1972) Personal communication
 DOWLING, J. E. (1970) *Invest. Ophthalm.*, **9**, 655
 ECHTE, K., and PAPST, W. (1962) *Acta ophthalm. (Kbh.)*, Suppl. 70, p. 176
 EDMUND, J., and JENSEN, S. F. (1967) *Ibid.*, **45**, 601
 ERNEST, J. T., and POTTS, A. M. (1968) *Amer. J. Ophthalm.*, **66**, 380
 FOULDS, W. S., LEE, W. R., and TAYLOR, W. O. G. (1971) *Trans. ophthalm. Soc. U.K.*, **91**, 323
 GILLS, J. P. (1966) *Amer. J. Ophthalm.*, **62**, 287
 GRANIT, R. (1933) *J. Physiol. (Lond.)*, **77**, 207
 HAYREH, S. S. (1969) *Brit. J. Ophthalm.*, **53**, 721
 ——— (1970) *Ibid.*, **54**, 289
 ——— (1971a) *Trans. ophthalm. Soc. U.K.*, **91**, 291
 ——— (1971b) In "Proc. Int. Symp. Fluorescein Angiography, Albi, 1969", ed. P. Amalric, pp. 510-530. Karger, Basel
 ——— (1971c) *Amer. J. Ophthalm.*, **72**, 998
 ——— and BAINES, J. A. B. (1972a) *Brit. J. Ophthalm.*, **56**, 719
 ——— and ——— (1972b) *Ibid.*, **56**, 736
 ——— and ——— (1972c) *Ibid.*, **56**, 754

- and PERKINS, E. S. (1969) In "Proceedings of the William Mackenzie Centenary Symposium on the Ocular Circulation in Health and Disease", ed. J. S. Cant, pp. 71-86. Kimpton, London
- and ————— (1971) "Proc. Int. Symp. Fluorescein Angiography, Albi, 1969", ed. P. Amalric, pp. 323-328. Karger, Basel
- , REVIE, I. H. S., and EDWARDS, J. (1970) *Brit. J. Ophthalm.*, **54**, 461
- HENKES, H. E. (1953) *A.M.A. Arch. Ophthalm.*, **49**, 190
- (1954) *Ibid.*, **51**, 42
- HENKIND, P., CHARLES, N. C., and PEARSON, J. (1970) *Amer. J. Ophthalm.*, **69**, 78
- KALVIN, N. H., HAMASAKI, D. I., and GASS, J. D. M. (1966) *Arch. Ophthalm. (Chicago)*, **76**, 82
- KARPE, G. (1945) *Acta ophthalm. (Kbh.)*, Suppl. **24**
- KELSEY, J. H. (1967) *Brit. J. Ophthalm.*, **51**, 44
- MCLEOD, D., and HAYREH, S. S. (1972) *Ibid.*, **56**, 765
- MACMICHAEL, I. M., and CULLEN, J. F. (1972) In "Proc. Second William Mackenzie Memorial Symposium, Glasgow 1971", ed. J. S. Cant, p. 108. Kimpton, London
- MICHAELSON, I. C. (1954) "Retinal Circulation in Man and Animals". Thomas, Springfield, Ill
- NILSSON, E. G. (1971) *Acta ophthalm. (Kbh.)*, **49**, 111
- PALM, E. (1958) *Ibid.*, **36**, 208
- PETERSON, H. (1968) *Ibid.*, **46**, Suppl. 99
- SPIVEY, B. E., and PEARLMAN, J. T. (1963) *Amer. J. Ophthalm.*, **55**, 1013
- SWIETLICZKO, I., and DAVID, N. J. (1970) *Ibid.*, **70**, 351
- VAN LITH, G. H. M., and BALIK, J. (1970) *Acta ophthalm. (Kbh.)*, **48**, 1091
- WINKLER, B. S. (1972) *Exp. Eye Res.*, **13**, 227
- WULFING, B. (1963) *Acta ophthalm. (Kbh.)*, Suppl. 73
- WYLLIE, A. M., MCLEOD, D., and CULLEN, J. F. (1972) *Brit. J. Ophthalm.*, **56**, 851
- YOUNESSIAN, S. (1962) *Ophthalmologica (Basel)*, **143**, 288