

# Macular lesions during systemic therapy with depot tetracosactrin

\*J. WILLIAMSON AND †G. NUKI

*\*Department of Ophthalmology, Southern General Hospital, Glasgow.*

*†Centre for Rheumatic Diseases and University Department of Medicine, Royal Infirmary, Glasgow.*

Ocular complications associated with long-term systemic corticosteroid therapy include the development of posterior subcapsular cataracts (Black, Oglesby, von Sallmann, and Bunim; 1960; Giles, Mason, Duff, and McLean, 1962; Crews, 1963; Spencer and Andelman, 1965; Fürst, Smiley, and Ansell, 1966; Williamson, Paterson, McGavin, Jasani, Boyle, and Doig, 1969), glaucoma (Alfano, 1963; Becker and Shaffer, 1965; Diotallevi and Bocci, 1965; Williamson and others, 1969), and scleral softening (Crews, 1965). In addition adrenocorticotrophic hormone has been implicated in the causation of posterior subcapsular cataracts (Crews, 1963), glaucoma (Alfano and Platt, 1966), and the simultaneous appearance of macular lesions and posterior subcapsular cataracts (Williamson and Dalakos, 1967).

This paper is concerned with the sudden development of bilateral macular exudates in a middle-aged man suffering from rheumatoid arthritis who was receiving large doses of depot tetracosactrin (Depot Synacthen, CIBA).

## Case Report

**A 45-year-old joiner** was admitted to hospital with an 18-month history of sero-positive rheumatoid arthritis. He was incapacitated by active disease in many joints, despite treatment with salicylates, phenylbutazone, and indomethacin; latterly hospitalization and prednisolone (2.5 mg. three times a day) had failed to induce a remission of the disease or to control the symptoms.

There were no ocular symptoms and an ophthalmological examination gave normal results immediately before treatment with depot tetracosactrin was begun. This form of therapy had been started as intramuscular injections 0.5 mg. every 48 hours after the withdrawal of steroids in September, 1968. An immediate improvement in symptoms was accompanied by a gradual fall in the erythrocyte sedimentation rate and a rise in haemoglobin, and he was discharged from hospital 2 weeks after starting treatment with depot tetracosactrin. Owing to a misunderstanding, however, out-patient treatment was continued with alternate day injections of 1 mg., a much larger dose than that recommended for long-term therapy.

In December, 1968, he began to notice defective vision, particularly affecting the left eye. At this time he was noticeably Cushingoid and pigmented and had gained 8 kg. in weight. There was, however, no peripheral oedema; he remained normotensive and the rheumatoid arthritis remained in remission. The dose of depot tetracosactrin was then gradually reduced until in May, 1969, he was receiving 0.25 mg. every 72 hours and his visual acuity improved concurrently.

## Laboratory investigations

Tests before starting treatment with depot tetracosactrin gave the following results: Hb 9.9 g./100 ml.; mean corpuscular haemoglobin concentration 34 per cent.; erythrocyte sedimentation rate

(Westergren) 103 mm./hr; serum proteins 7.4 g./100 ml. (albumin 3.4; globulin 4.0); serum electrolytes, calcium, inorganic phosphorus, alkaline phosphatase, urea, and uric acid, all normal.

A joint x-ray survey showed erosive changes in many joints, whilst x-rays of the chest and sinuses were clear.

The Hyland RA latex-fixation test was strongly positive and the sheep cell agglutination test was positive in a titre of 1/64. An immunofluorescent test for antinuclear antibody was weakly positive (titre 1/16) and showed homogeneous staining (Beck, Anderson, McElhinney, and Rowell, 1962), but the L.E. latex test was negative, as were precipitin tests for thyroglobulin and immunofluorescent tests for antibodies to thyroid microsomes and gastric parietal cells.

Tests of hypothalamo-pituitary-adrenal function (plasma 11-hydroxycorticosteroid responses to tetracosactrin and insulin-induced hypoglycaemia (normal before treatment was begun).

A transient fall in serum potassium to 2.9 mEq/l. occurred and this was corrected by administration of potassium chloride (Slow-K-CIBA, 1.2 g. three times a day). When the ocular symptoms were evident, the serum electrolytes were normal, the haemoglobin had risen to 12.9 g./100 ml. and the erythrocyte sedimentation rate had fallen to 9 mm./hr. Intermittent glycosuria, with a blood sugar of 136 mg./100 ml. 2 hours after lunch, was noted at this time.

#### *Ocular examinations*

10 SEPTEMBER, 1968

Routine full ophthalmological examination revealed no abnormalities and no family history of ocular disease was obtained. The visual acuity was 6/6 and N<sub>5</sub> in both eyes.

1 JANUARY, 1969

The patient gave a 4-weeks' history of defective vision, particularly affecting the left eye. There was no history of inflammation, pain, or haloes. Pupil reactions were normal. The visual acuity was 6/9 and N<sub>5</sub> in the right eye and 1/60 and N<sub>24</sub> in the left. Ophthalmoscopic examination of the right eye revealed small non-confluent exudates and a few superficial haemorrhages in the perifoveal region. The left eye, however, had developed a large raised plaque of oedema, of three disc diameters, covering the entire macular area. There were no large haemorrhages and the retinal vessels appeared normal (Fig. 1).

The right visual field charted on a Bjerrum screen showed a small relative central scotoma to 5/1000 red targets. The left visual field demonstrated a dense complete central scotoma to all targets extending to the 15° isopter and a partial scotoma to the 20° isopter to white targets (2/1000 and 5/1000) and to red targets (5/1000) and 10/1000). There was no evidence of glaucoma.

1 JUNE, 1969

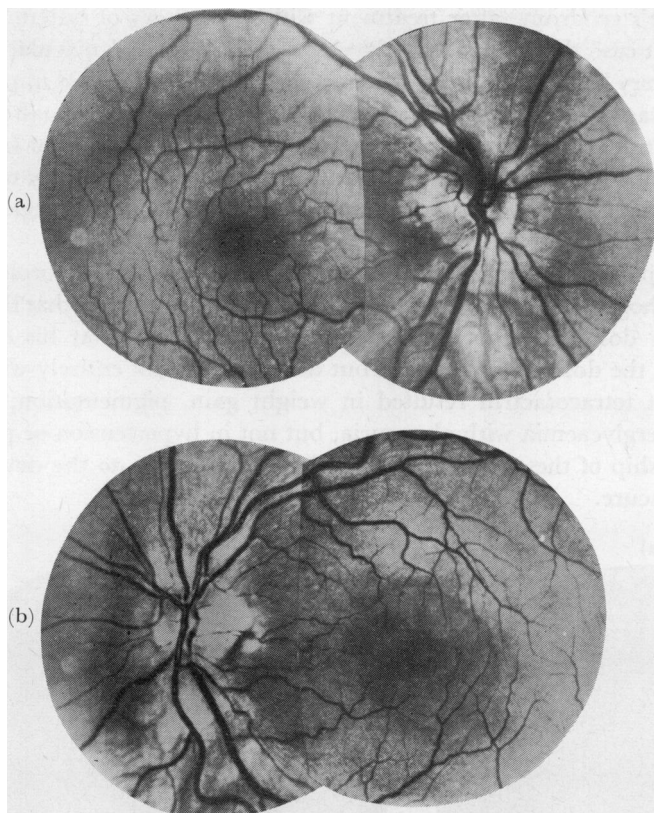
The patient's ocular symptoms, which had begun to improve immediately the dose of depot tetracosactrin was reduced, had disappeared and a full ophthalmological examination gave normal results apart from some residual pigment in the left macular area (Fig. 2). The visual acuity was 6/6 and N<sub>5</sub> in the right eye and 6/9 and N<sub>5</sub> in the left.

JANUARY 1970

No further deterioration had occurred.

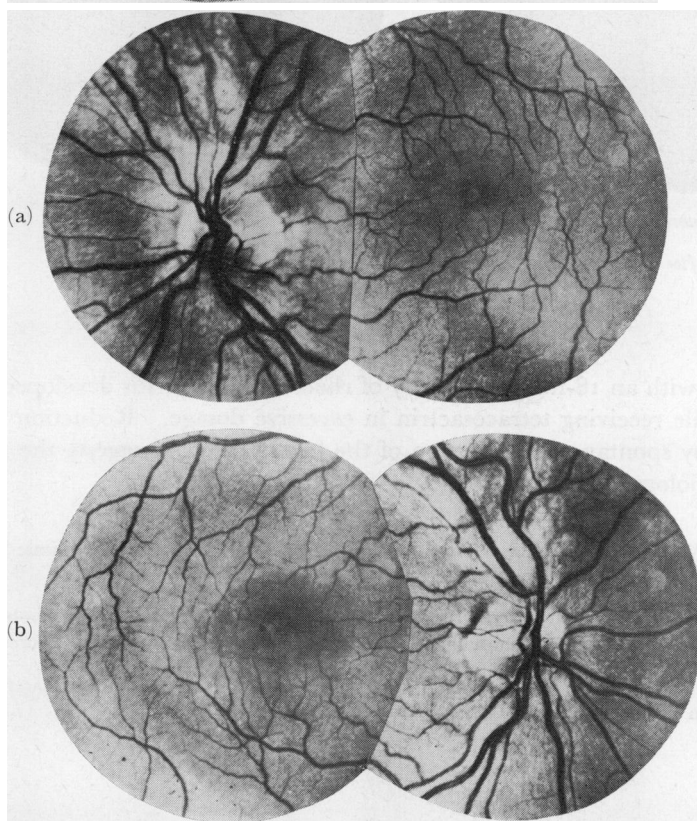
#### **Discussion**

Macular degeneration in association with posterior subcapsular cataracts has been reported during the course of therapy with natural corticotrophin (ACTH gel) (Williamson and Dalakos, 1967) and a central serous retinopathy was observed by Jain and Singh (1966)



**FIG. 1** (a) *Right eye, showing a few small perifoveal exudates.*

(b) *Left eye, showing large raised plaque of oedema over the entire macular area.*



**FIG. 2** (a) *Right eye 6 months after cessation of treatment.*

(b) *Left eye, showing fine macular pigmentation.*

in a patient with Reiter's syndrome after treatment with large doses of systemic corticosteroids. In the present case the coincidental development of bilateral macular exudates during treatment with very large doses of depot tetracosactrin and their rapid improvement after a reduction in dosage also suggests the possibility of iatrogenic disease, although the spontaneous development of an unrelated presenile macular dystrophy cannot be entirely ruled out. There was no family history of macular degeneration and the only other drug being taken by the patient when visual symptoms developed was dextropropoxyphene, which is not known to have ocular side-effects.

Fluorescein photography (Fig. 3) demonstrated a perifoveal leak in the choroidal circulation, but the exact pathogenesis of these lesions is uncertain. It is of interest that the patient was receiving excessive doses of depot tetracosactrin in error and that his symptoms improved rapidly when the dosage was reduced but the drug was not entirely withdrawn. The high dosage depot tetracosactrin resulted in weight gain, pigmentation, transient hypokalaemia and hyperglycaemia with glycosuria, but not in hypertension or peripheral oedema. The relationship of these corticosteroid side-effects, if any, to the development of a maculopathy is obscure.

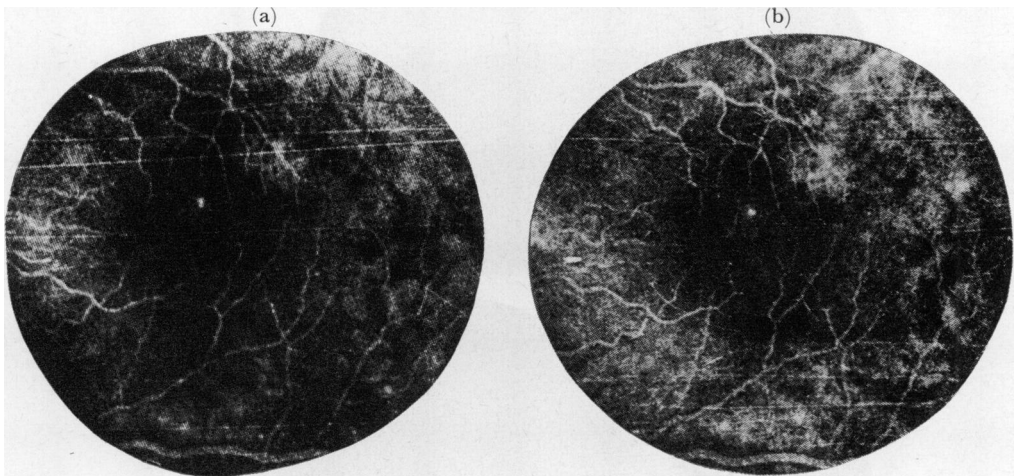


FIG. 3 *Left eye (a) fluorescein after 3 minutes.*

*(b) after 5 minutes, showing perifoveal leak in choroidal circulation.*

### Summary

A 45-year-old man with an 18-months' history of rheumatoid arthritis developed bilateral macular lesions while receiving tetracosactrin in excessive dosage. Reduction in dosage was accompanied by spontaneous regression of the lesions, which suggests the possibility of an iatrogenic aetiology.

We wish to thank Dr. W. Watson Buchanan, Consultant Physician at the Centre for Rheumatic Diseases, for allowing details of this patient's case to be published.

We are indebted to Mr. Ibbott, Senior Optician, Southern General Hospital, for fundus photographs and to Mr. J. Watt, Tennent Institute of Ophthalmology, Western Infirmary, Glasgow, for the fluorescein photographs.

One of us (G.N.) is in receipt of a CIBA Clinical Research Fellowship.

**References**

- ALFANO, J. E. (1963) *Amer. J. Ophthalm.*, **56**, 245  
——— and PLATT, D. (1966) *Ibid.*, **61**, 911
- BECK, J. S., ANDERSON, J. R., McELHINNEY, A. J., and ROWELL, N. R. (1962) *Lancet*, **2**, 575
- BECKER, B., and SHAFFER, R. N. (1955) "Diagnosis and Therapy of the Glaucomas", 2nd. ed., p. 144, 190, 191. Mosby, St. Louis
- BLACK, R. L., OGLESBY, R. B., SALLMANN, L. VON, and BUNIM, J. J. (1960) *J. Amer. med. Ass.*, **174**, 166
- CREWS, S. J. (1963) *Brit. med. J.*, **1**, 1644  
——— (1965) *Proc. roy. Soc. Med.*, **58**, 533
- DIOTALLEVI, M., and BOCCI, N. (1965) *Acta ophthalm. (Kbh.)*, **43**, 524
- FÜRST, C., SMILEY, W. K., and ANSELL, B. M. (1966) *Ann. rheum. Dis.*, **25**, 364
- GILES, C. L., MASON, G. L., DUFF, I. F., and McLEAN, J. A. (1962) *J. Amer. med. Ass.*, **182**, 719
- JAIN, I. S., and SINGH, K. (1966) *J. All-India ophthalm. Soc.*, **14**, 250
- SPENCER, R. W., and ANDELMAN, Y. S. (1965) *Arch. Ophthalm. (Chicago)*, **74**, 38
- WILLIAMSON, J., and DALAKOS, T. G. (1967) *Brit. J. Ophthalm.*, **51**, 839  
———, PATERSON, R. W. W., MCGAVIN, D. D. M., JASANI, M. K., BOYLE, J. A., and DOIG, W. M. (1969) *Ibid.*, **53**, 301