

Recurrent erosion of the cornea

RONALD F. LOWE

Melbourne, Australia

Recurrent erosion of the cornea has been known for a hundred years and many excellent reviews have been published about it. A comprehensive discussion was presented by Duke-Elder (1965). Most of this material does not need re-iteration. My purpose is to emphasize certain features of diagnosis, to discuss some theories of pathology, and present details of management.

Symptoms

The characteristic symptom is a severe pain in one eye, on waking from sleep, usually occurring some weeks after abrasion by a finger nail, piece of paper, or branch of a shrub, but relatively seldom after removal of an industrial foreign body. The pain tends to improve during the day, and may last several days and then disappear to return after another interval. At other times the pain may be continuous but of varying severity, or the patient may feel as though he has something in the eye.

A symptom infrequently described, but of considerable significance, is pain or tenderness on rubbing the eye—this is likely to be noted while drying the face after washing.

Signs

Although the condition is known as "corneal erosion" a denuded area of corneal epithelium is seldom seen and occurs in only the most severe cases. Occasionally, by slit-lamp examination, a collection of tiny white dots can be seen in the corneal epithelium (Vogt, 1930), but in most cases these examinations are completely negative.

In 1964 I described a method of examination to provide conclusive diagnosis, but this small paper (Lowe, 1964) appears to have been largely overlooked. In the meantime I have become increasingly convinced of the value of this test and that without its use most cases of recurrent erosion of the cornea will not be properly diagnosed. Without accurate diagnosis, treatment is apt to be vague and ineffective.

Diagnosis

In cases in which the history is suggestive but slit-lamp examination is negative, diagnosis is accomplished by placing a loose-fitting contact lens with fluid under it (such as a Goldmann fundus examination contact lens) upon the anaesthetized cornea, waiting a minute or two, then turning the lens around as one might do when using a gonioscopes with a slit lamp.

Two features may be observed and the presence of either makes the diagnosis certain:

(1) If the corneal epithelium is loose it is likely to wrinkle beneath the lens and if it is very loose it will break as the lens is turned. This is similar to the effect that occurs when the epithelium is wiped with a swab but, whereas the application of an examination contact lens to an eye will cause no undue discomfort, one would hesitate to rub the cornea of an apparently normal eye to see if the epithelium were loose.

(2) More frequently, the epithelium does not appear loose but develops small, irregular, faintly grey patches that may surround the site of the previous injury or be scattered widely from it (Figure). With repeat examinations, they do not always appear to be of the same size or in the same position. Sometimes a grey patch appears like an exact template, in shape and location, of the previous corneal abrasion.

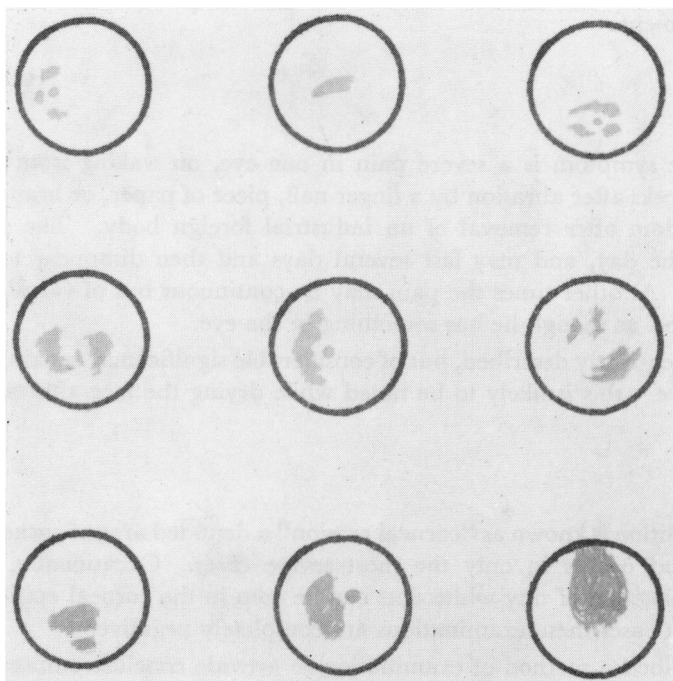


FIGURE *Recurrent erosion of the cornea showing as irregular grey patches that develop in corneal epithelium under a loose-fitting contact lens*

The grey patches will develop in appropriate corneal epithelium that has previously appeared to be perfectly normal, and with the slit lamp they can be readily seen beneath the fluid under the contact lens. The greyness persists for some time after removal of the lens and does not stain with fluorescein or Bengal rose; but, on contact with air, the epithelium gradually clears, indicating recovery by the cells involved.

Unless the grey patches are widespread they give no clue to the total area of corneal epithelium that would wipe off with a swab. Usually the epithelium is loose over a much larger area than that indicated by the grey patches.

After treatment, some grey areas may still develop under the contact lens even though the patient is symptom free. In such cases they indicate that the corneal epithelium is not normal even though it may have recovered sufficiently to cause no symptoms.

Mechanism of the test

The grey patches that develop in the corneal epithelium seem to be caused by oedema due to interference with corneal respiration similar to the veiling that occurred under the early scleral or haptic contact lenses, except that the process is much more rapid and is confined to limited areas. Not all the corneal epithelium shows this reaction, but only certain areas that on the day of examination are most vulnerable.

During sleep, a similar relative oxygen deficiency occurs beneath the closed eyelids (Ruben, 1967) and presumably on some nights is sufficient to cause a patch of corneal oedema. Ruben (1967) has described how a steep-fitting contact lens causes a negative hydrostatic pressure which can pull oedematous corneal epithelium away from Bowman's membrane. The loose-fitting examination contact lens can act in this manner upon the oedematous grey areas, and opening the eyelids after sleep may have a similar effect.

Pathology

Defects in corneal epithelium are repaired by two processes—the sliding and proliferation of surrounding epithelial cells to cover the defect, and the re-establishment of a tight adhesion between the new epithelium and the underlying tissue (Khodadoust, Silverstein, Kenyon, and Dowling, 1968).

Not only the cells immediately adjacent to the defect are involved but the epithelium may become loose over a surrounding area of considerable extent. This loosening seems to vary markedly with the various unknown circumstances which may be present after injury. I have treated patients for embedded corneal foreign bodies and found loose epithelium quite out of proportion to the size of the foreign body. These eyes have sometimes healed with considerable difficulty. Some of these patients have later returned apprehensively with another foreign body, but the second time the surrounding epithelium was firm and healing was quick. Certain types of scratch injury (finger nail, paper edge, pieces of twig) are well recognized as apt to result in poor epithelial healing.

The corneal epithelium is attached to basement membrane which is a complex structure of four layers (Teng, 1962). The outermost layer has a considerable content of phospholipid and although sparse fine fibrils cross this layer from the epithelial cells to the reticular layers beneath, the adhesion of corneal epithelium to basement membrane appears to depend largely on the lipid layer (La Tessa, Teng, and Katzin, 1954). The epithelium can be loosened by many different agents—proteolytic and lipid-splitting enzymes, lipid solvents, as well as toxic substances.

After localized damage to corneal epithelium, the surrounding cells apparently liberate an enzyme that loosens their attachment to the basement membrane, presumably to permit more ready sliding to cover the defect. The extent of this release must vary in different circumstances.

When the cornea has been mechanically scraped, the original basement membrane may survive intact and be re-used by the new epithelial cells which, at the same time, remove cellular debris. A tight epithelial adhesion requires several days. When both epithelium and basement membrane are removed, the regenerating epithelium can form a new basement membrane but its adhesion to the underlying stroma may take several weeks to develop (Khodadoust and others, 1968).

Many complex repair functions are required from the epithelium and its biochemical activities are now being elucidated. The importance of collagenase release has been determined (Slansky and Dohlman, 1970) but other actions await discovery.

Goldmann, Dohlman, and Kravitt (1969) examined by electron microscopy a specimen of cornea involved in recurrent erosion. The most noteworthy findings were the absence of basement membrane and associated hemidesmosomes in some portions of the specimen, and an abnormal discontinuity of basement membrane in other portions. Bowman's membrane and the anterior stroma were normal. Their description of the lesions recurring at the same site each time suggests that this was the site of injury and that the basement membrane had not regenerated from the epithelial cells that had spread into and proliferated in this area.

However, the epithelial pathology of recurrent erosion of the cornea is frequently much more widespread than the area of trauma, and this suggests a biochemical disturbance. After healing, the biochemical loosening of the epithelium must be reversed and a firm adhesion between epithelium and basement membrane reconstituted. The continuing looseness of the epithelium over a wide area suggests a persistence of the loosening factor and a failure in its reversal. This biochemical concept has a deliberate effect upon treatment.

Treatment

This is based upon three main principles:

- (1) To overcome the biochemical abnormality.
- (2) To prevent eyelid suction,
- (3) To prevent trauma from the patient's own fingers.

The biochemical abnormality is unknown and, until it is elucidated, treatment must be empirical, though it can be effective.

The most suitable treatment to date is the use of corticosteroid eyedrops (Thygeson, 1959) combined with patience and encouragement. As this is an epithelial abnormality there is no need to use soluble or powerful corticosteroids that penetrate the eye freely and may risk raising the intraocular pressure. To date, 0.5 to 1.0 per cent. hydrocortisone eyedrops have been adequate, although medrysone drops may replace them if they prove to be equally effective. For a start, one drop should be ordered four times daily, and the patient should be seen after approximately 3 weeks. By that time there is usually some improvement and treatment can be re-assessed.

The aim is to reduce treatment to the minimum—but not hurriedly—and to continue treatment until symptoms disappear. Important guides are continued or episodic eye discomfort, especially on waking, and tenderness on eye pressure through the upper eyelid. With improvement, the symptoms become milder and then usually occur only at irregular intervals; but while they persist continued treatment is necessary.

Ocular tensions may be checked after 6 weeks or as considered advisable. The drops should be slowly tapered off and the patient should be given advice at intervals until the treatment is complete. Relapses are managed by repetition of treatment. Reassuring supervision is most important.

Prevention of eyelid suction may be achieved by the use of a non-drying lubricant between the eyelids at bedtime. Thick liquid paraffin or castor oil have been used for many years but these are often difficult to obtain sterile and in drop bottles. A soft oculentum is most convenient. Various ointments should be checked to eliminate those that are thick or tacky. Oculentum hydrocortisonae, with or without antibiotic, may be used initially; but a bland relatively inert ointment should be prescribed for prolonged use.* The lubricants permit more ready opening of the eyelids and prevent sudden pain at these times.

* I commence with Oc. Chlorocort (Parke Davis and Co.) and change to Oc. Bepanthen (Roche Products Pty. Ltd.) as symptoms abate.

Patients must be warned to avoid trauma from eye rubbing; they should be especially advised not to rub the eye while drying the face, but to dab gently with a towel. The desire to rub the eye in response to discomfort must be controlled.

Some cases become symptom-free within a month, have treatment tapered off, and are discharged within 2 or 3 months; others require 12 months or longer. Sometimes progress seems very slow, but complete failure to improve is very rare and indicates a doubtful diagnosis. Failure is more likely in cases in which there has been no trauma and in these the condition probably depends upon a constitutional abnormality or a more widespread disturbance.

I have discontinued chemical cautery such as iodine paints, and I agree with Kaufman (1964) that this treatment has been superseded, although in the past I have found it helpful in some of my patients and I should be prepared to use it again in suitable cases. Two very refractory cases were treated by superficial x rays—possibly with benefit.

In 15 years, I have treated 32 cases with generally satisfactory results.

Summary

Recurrent erosion of the cornea can be best diagnosed by the use of a fundus examination (or similar) contact lens having fluid beneath it. Diagnosis is definite if the corneal epithelium appears to be wrinkled or if small grey patches are seen in the corneal epithelium.

Recurrent erosion of the cornea appears to be due to a persistent biochemical abnormality preventing adhesion of the corneal epithelium to the basement membrane.

Treatment needs patience and perseverance. Surface-acting corticosteroid eyedrops by day and a lubricant at night should be continued as long as symptoms persist.

References

- DUKE-ELDER, S. (1965) "System of Ophthalmology", vol. 8, pt. 2, p. 694. Kimpton, London
- GOLDMAN, J. N., DOHLMAN, C. H., and KRAVITT, B. A. (1969) *Trans. Amer. Acad. Ophthal. Otolaryng.*, **73**, 471
- KAUFMAN, H. E. (1964) *Amer. J. Ophthal.*, **57**, 983
- KHODADOUST, A. A., SILVERSTEIN, A. M., KENYON, K. R., and DOWLING, J. E. (1968) *Ibid.*, **65**, 339
- LA TESSA, A. J., TENG, C. C., and KATZIN, H. M. (1954) *Ibid.*, **38**, 171
- LOWE, R. F. (1964) *Ibid.*, **57**, 397
- RUBEN, M. (1967) *Trans. ophthal. Soc. U.K.*, **87**, 27
- SLANSKY, H. H., and DOHLMAN, C. H. (1970) *Surv. Ophthal.*, **14**, 402
- TENG, C. C. (1962) *Amer. J. Ophthal.*, **54**, 969
- THYGESON, P. (1959) *Ibid.*, **47**, no. 5, pt. II, p. 48
- VOGT, A. (1930) "Lehrbuch und Atlas der Spaltlampenmikroskopie des lebenden Auges", 2nd ed., vol. 1, p. 246. Springer, Berlin