

# Ocular psoriasis

PETER EUSTACE AND DERMOT PIERSE

*Croydon Eye Unit*

Although psoriasis is said to occur in 2 per cent. of the general population (Ingram, 1964), ocular involvement is a comparative rarity. The lids, conjunctiva, and cornea may be involved and anterior uveitis has been described in association with the arthropathic form of psoriasis (Wright, 1959). This paper presents two patients with ocular psoriasis.

## Case reports

**Case 1.** A 15-year-old girl presented at the Croydon Eye Unit on March 15, 1966, with a left inferior marginal keratitis which healed after topical applications of chloramphenicol ointment to leave a vascularized scar, and 2 years later she attended again with a recurrence of corneal ulceration at the same site. This time the ulcer took longer to heal. She came back 4 months later with a mild follicular conjunctivitis, and this recurred in April, 1969.

A further episode of discomfort brought her back to the Unit on February 16, 1970, and at this time it was noted that there were unusual and distinctive features in the corneal lesion: namely a fairly superficial tongue of opacity extending inwards about 3 mm. infero-temporally in the left eye with slight guttering and several discrete whitish slightly irregular dots (Fig. 1). It was thought possible that the mild psoriasis, from which she had suffered since childhood, was connected with these lesions. Direct questioning revealed the fact that on two occasions the episodes of ocular inflammation coincided with cutaneous relapses. The diagnosis of psoriasis was confirmed by a dermatologist.

**Case 2.** A 42-year old-man attended the Casualty Department of the Croydon Eye Unit on February 13, 1970, with a severe right marginal keratoconjunctivitis which settled over a period of 4 weeks after intensive topical administration of corticosteroids. Marginal infiltration of the left cornea of an unusual nature was noted (Fig. 2). The patient admitted to recurrent inflammatory ocular episodes occurring about twice yearly in either eye for the previous 10 years. Scalp lesions suggestive of psoriasis were noted and this diagnosis was confirmed by a dermatologist.

## Discussion

Psoriasis is one of the common dry scaly dermatoses. Rare in childhood and with about an equal sex incidence, it is subdivided into various clinical groupings dependent on anatomical site, and the extent and persistence of lesions. Typically, the primary lesion consists of a small flat round or oval sharply-demarcated papule covered with a delicate silvery scale, distribution being roughly symmetrical with a predilection for the extensor surfaces of the extremities.

Psoriasis may involve the lids, conjunctiva, cornea, and anterior uveal tract. Plaques may appear on the lid and lid margins, though often the appearance is simply that of a red swollen lid. A nonspecific conjunctivitis usually with considerable secretion occurs, and healing may produce trichiasis, symblepharon, and a "dry eye" (Kaldeck, 1953). Demarcated yellowish red plaques have been seen on the palpebral conjunctiva (Rossler,

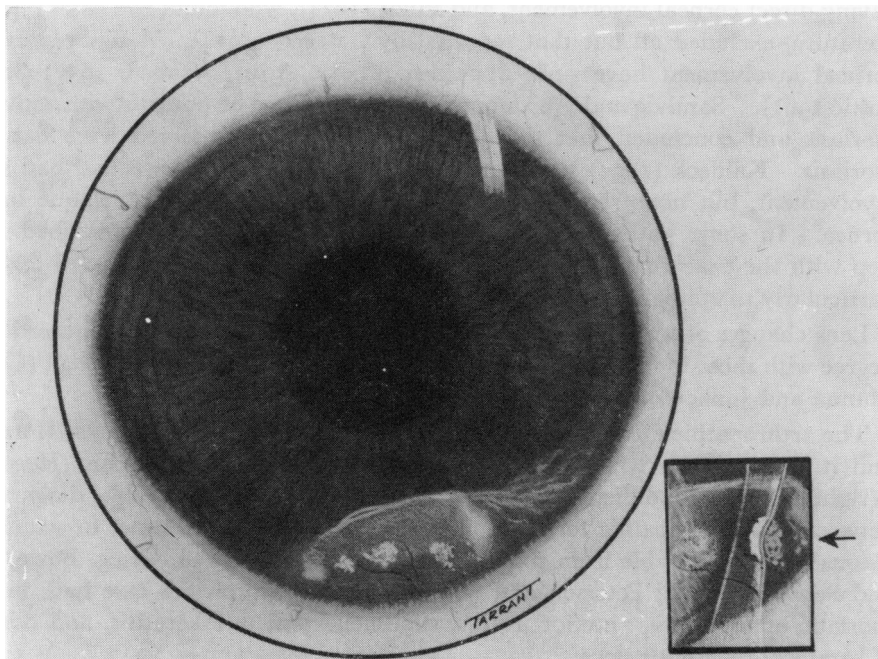


FIG 1. Drawing of left cornea with slit-lamp optical section inset

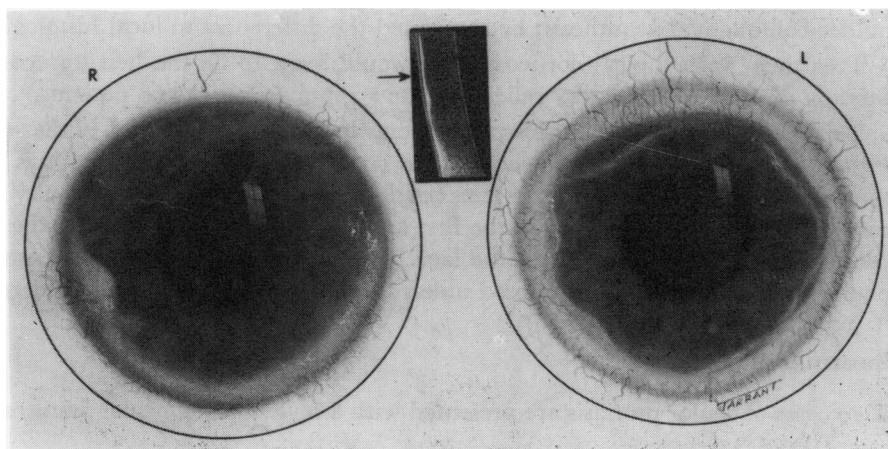


FIG 2. Drawings of both corneae with slit-lamp optical section inset.

1947), and nodular excrescences of piled-up epithelium at the limbus with surrounding stromal opacity were described by Stuart (1963). These lesions resembled those sometimes seen in rosacea (Starr and MacDonald, 1969). The cornea may be involved in a non-specific fashion, the commonest presentation being superficial punctate keratitis; a marginal keratitis occurs less frequently (Fontana, 1953). The distinctive picture specific to psoriatic involvement of the cornea was considered by Pillat (1934) to show three elements: a thickening of the epithelium with multiple erosions; an infiltrated zone beneath Bowman's membrane with superficial vascularization; and homogenous deep opacities. This description excludes several reported cases of ocular psoriasis from being considered as

having direct corneal involvement, and Pillat (1934), who found five cases reported in the literature, excluded all but that reported by Lasareff (1914). A few reports of specific corneal involvement have since appeared (Oxilia, 1949; Vrabec, 1952; Stuart, 1963; Poštić 1961). Sandvig and Westerberg (1955) examined 92 patients with active cutaneous psoriasis and concluded that the corneal changes they observed were not specific for psoriasis. Kaldeck (1953) reviewed ninety cases, eleven of which had had some ocular involvement, but none showed the features specific to a psoriatic plaque involving the cornea. In some patients the episodes of ocular inflammation described fluctuate in step with the exacerbations and remissions of the cutaneous lesions, and this may apply particularly to epithelial lesions (Stuart, 1963).

Lens changes observed are considered to be incidental findings and accord in type and degree with those to be expected for the particular age group of the patient (Collier, 1962; Manna and Jankowski, 1966).

The arthropathic form of psoriasis occurs in about 5 per cent. of cases (Horowitz, 1949) and it is this group which has been associated with anterior uveitis (Horowitz, 1949; Wright, 1959). A difficulty arises in that there is a considerable diagnostic overlap between the arthropathic form of psoriasis and Reiter's syndrome, in which cutaneous lesions indistinguishable from psoriasis may develop (Maxwell, Grieg, Boyle, Pascieczny, and Schofield, 1966; Peterson and Silbiger, 1967). Horowitz's case had, in addition to psoriatic arthropathy, anterior uveitis, superficial punctate keratitis, and other evidence of keratoconjunctivitis sicca.

The histopathology of ocular psoriasis was found by Vrabec (1952) to be very similar to the cutaneous changes, but with less severe parakeratosis, no corneal acanthosis, and milder conjunctival acanthosis; he attributed the differences to local histological features.

Treatment with topical corticosteroids would seem to be the best approach, and this therapy produced satisfactory relief of acute symptoms in our two patients.

The first case described in this paper seems to be almost identical to that described by Pillat (1934); the second case showed less specific features although this is perhaps the more usual presentation. What seems particularly significant is the difficulty and delay in reaching the correct diagnosis in the first case, which was mainly due to the fact that no psoriatic lesions were present on the face. It seems probable that other similar cases of ocular psoriasis will go undiagnosed unless this possibility is actively considered.

### Summary

Two cases of ocular psoriasis are presented with a review of the ocular features of psoriasis.

We should like to thank Mr. T. Tarrant of the Institute of Ophthalmology for the drawings.

### References

- COLLIER, M. (1962) *Bull. Soc. Oftal. Fr.*, **62**, 59  
 FONTANA, G. (1953) *G. ital. Oftal.*, **6**, 316  
 HOROWITZ, S. (1949) *Glasg. med. J.*, **30**, 251  
 INGRAM, J. T. (1964) *Brit. J. Derm.*, **76**, 238  
 KALDECK, R. (1953) *Arch. Derm. Syph. (Chicago)*, **68**, 44  
 LASAREFF, J. G. (1914) *Vestn. Ophthal.*, **31**, 249  
 MANNA, F., and JANKOWSKI, W. (1966) *Klin. oczna*, **36**, 371

- MAXWELL, J. D., GREIG, W. R., BOYLE, J. A., PASIECZNY, T., and SCHOFIELD, C. B. S. (1966) *Scot. med. J.*, **11**, 14
- OXILLA, E. (1949) *G. ital. Oftal.*, **2**, 122
- PETERSON, C. C., and SILBIGER, M. L. (1967) *Amer. J. Roentgenol.*, **101**, 860
- PILLAT, A. (1934) *Klin. Mbl. Augenheilk.*; **93**, 751
- POŠTIĆ, D. (1961) *Med. Pregl.*, **14**, 25
- RÖSSLER, F. (1947) *Wien. klin. Wschr.*, **59**, 819
- SANDVIG, K., and WESTERBERG, P. (1955) *Acta ophthal. (Kbh.)*, **33**, 465
- STARR, P. A. J., and MACDONALD, A. (1969) *Proc. roy. Soc. Med.*, **62**, 9
- STUART, J. A. (1963) *Amer. J. Ophthal.*, **55**, 615
- VRABEC, F. (1952) *Ophthalmologica (Basel)*, **124**, 105
- WRIGHT, V. (1959) *Amer. J. Med.*, **27**, 454