

Corneal blood staining after hyphaema

J. D. BRODRICK

Sheffield

Corneal blood staining has been described as a rare complication of contusion injury in which a hyphaema of relatively long duration and a raised intraocular pressure co-exist. It is infrequent after penetrating injuries, in which the tension is usually low, and is occasionally found in association with haemorrhagic glaucoma, occlusion of the central retinal vein, and intraocular tumours (Berliner, 1949; Duke-Elder and Leigh, 1965; Rychener, 1944; Thygeson and Beard, 1952).

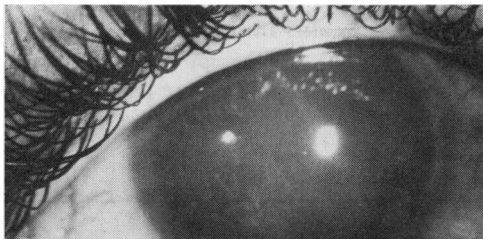


FIG. 1 *Dense corneal blood staining obscuring all details of anterior chamber*

The clinical appearance is that of a rust-coloured opacity which may occupy the entire cornea or may merely involve an axial disciform area (Fig. 1). The colour of the opacity changes with time through shades of greenish-black to grey, and a greyish discoid opacity deep in the stroma can simulate an anterior dislocation of the lens (Berliner, 1949; Duke-Elder and Leigh, 1965; Hogan and Zimmerman, 1962).

The opacity usually clears from the periphery by phagocytosis and the total clearing process can take up to 2 or 3 years, but clearing may be incomplete, resulting in a permanent corneal opacity (Duke-Elder and Leigh, 1965; Hogan and Zimmerman, 1962).

The purpose of this paper is to review the aetiology of corneal blood staining, to comment on the prognosis if the complication should occur, and to estimate the incidence after blunt trauma.

Selection of cases

We have recently studied a series of 289 cases of traumatic hyphaema due to contusion injury. This was a retrospective survey of consecutive cases admitted to St. Paul's Eye Hospital, Liverpool, between January, 1966, and June, 1967 (Brodrick and Hall, 1971a).

Report of cases

Of the 289 patients admitted with primary traumatic hyphaema, 27 developed a secondary hyphaema, nine of which were partial and eighteen total. All the patients with a total secondary haemorrhage had a raised intraocular pressure at some stage and six of these developed corneal blood staining (Brodrick and Hall, 1971b).

The Table shows that corneal blood staining occurred in those patients in whom surgery was delayed (Cases 2, 4, 5, 6), or in whom clearing of the hyphaema was inadequate (Cases 1, 4, 6). There was a combination of both these features in two patients (Cases 4, 6). Case 3 is interesting

in that urokinase washout was performed within 24 hours of the total secondary hyphaema developing and, although a residual one-third hyphaema remained, the intraocular pressure was immediately lowered to normal. This patient subsequently developed blood staining in the lower third of the cornea exactly conforming to the residual hyphaema (Fig. 2).

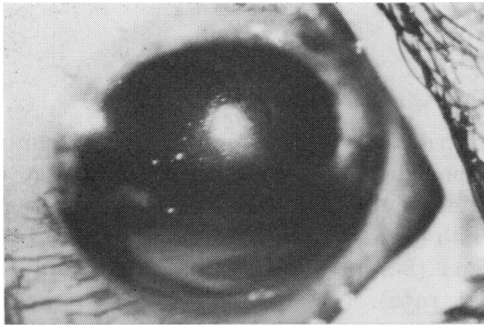


FIG. 2 Blood staining of lower third of cornea in Case 3, in which the intraocular pressure was rapidly restored to normal but a residual one-third hyphaema remained

These patients were reviewed between 3 and 4 years after their original admission, when complete corneal clearing had occurred in four (Cases 1, 2, 3, 5). Although only one patient (Case 5) had recovered a good visual acuity (6/9), the poor result in the other three patients was entirely due to associated traumatic pathology and in no way to residual corneal changes (Table).

Table Clinical course of six cases of corneal blood staining

Case No.	Interval before operation* (days)	Operation	Postoperative result	Result after 3 yrs
1	2	Paracentesis	Pressure remained high Hyphaema cleared slowly Corneal blood staining	Clear cornea Cataracta glaucomatosa Peripheral anterior synechiae Retinal detachment (replaced) Visual acuity 6/36
2	5	Urokinase washout	Adequate clearing Corneal blood staining	Clear cornea Post-cortical cataract Visual acuity 6/18
3	1	Urokinase washout	Normal tension Residual $\frac{1}{3}$ hyphaema Corneal blood staining lower $\frac{1}{3}$	Clear cornea Cataracta glaucomatosa Visual acuity perception of light
4	1	Urokinase washout	Inadequate clearing Pressure remained high	Dense corneal blood staining
	14	Urokinase washout	Inadequate clearing Corneal blood staining	Organized anterior chamber Visual acuity perception of light
5	3	Urokinase washout	Adequate clearing Corneal blood staining	Clear cornea Visual acuity 6/9
6	5	Paracentesis	Pressure remained high Hyphaema failed to absorb	Band keratopathy
	11	Urokinase washout	Inadequate clearing Corneal blood staining	Visual acuity no perception of light due to associated ocular pathology

*From total secondary hyphaema

One patient (Case 4) still had dense corneal blood staining with organized tissue in the anterior chamber and the clinical impression was that the visual acuity in this patient was unlikely to improve.

Case 6, in which operation was complicated by loss of vitreous, was found to have a soft eye, an absent anterior chamber, and a band-shaped corneal opacity (Fig. 3).

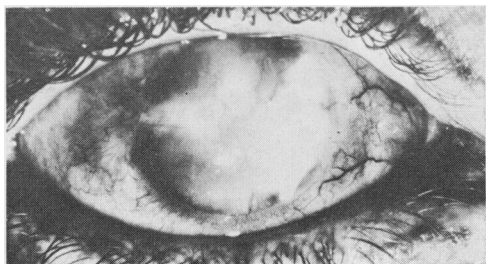


FIG. 3 Case 6. *Permanent corneal opacification following corneal blood staining with associated ocular pathology*

Discussion

PATHOLOGY

Although the diagnosis of corneal blood staining after contusion injury usually presents no difficulty, it must be differentiated from corneal haemorrhage. In this condition the stroma is involved by frank bleeding, usually arising from one of the following three sources:

- (1) A large subconjunctival haemorrhage at the limbus may give rise to extravasation of blood into the stroma, usually at the periphery, at the level of Bowman's membrane.
- (2) New vessels in the cornea, due to interstitial keratitis or mustard gas keratitis, may rupture to produce an intracorneal haemorrhage.
- (3) Subepithelial haematomata may be found postoperatively adjacent to a cataract section (Duke-Elder and Leigh, 1965).

In corneal blood staining the stroma is infiltrated with the breakdown products of red blood cells and pathological examination reveals three types of infiltrate:

- (1) Interlamellar masses of amorphous pigmented granules.
- (2) Intralamellar, minute, round, oval or rod-shaped, highly refractile particles.

These two groups probably represent crystalline precipitates of the protein fraction of haemoglobin.

- (3) Pigmented granules within the corneal corpuscles which are probably haemosiderin and lipofuscin (Duke-Elder and Leigh, 1965; Greer, 1963; Hogan and Zimmerman, 1962) (Figs 4 and 5, overleaf).

AETIOLOGY

Infiltration of the stroma from the anterior chamber can occur either directly across the endothelium or round the periphery, and passage across the endothelium can take place in three ways:

- (1) In the absence of direct endothelial damage, the combination of a long-standing hyphaema and raised intraocular pressure is sufficient to produce transient decompensation of the endothelium as no doubt occurred in Cases 1, 2, and 5. These patients subsequently recovered complete corneal clarity with no evidence of permanent endothelial dysfunction.

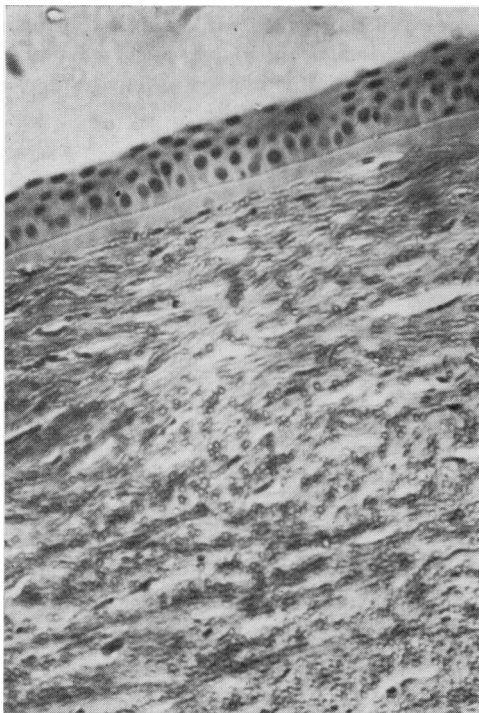

FIG. 4 Corneal blood staining, showing superficial stromal involvement. Normal epithelium and Bowman's layer. $\times 140$

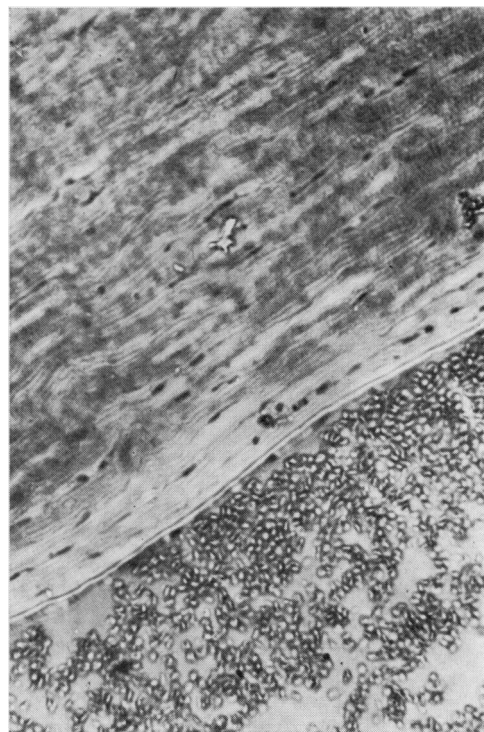


FIG. 5 Section from same eye as Fig. 4, showing hyphaema in anterior chamber, normal endothelium and Descemet's membrane, and a zone adjacent to the endothelium completely clear of infiltration. $\times 140$

(2) Reversible endothelial decompensation may occur, either as a direct result of trauma alone or aggravated by the irritant action of fragmenting red blood cells and the local inflammatory response. This was probably the mechanism of the localized area of blood staining in Case 3.

(3) Severe permanent endothelial damage may result from concussion necrosis (Duke-Elder, 1938), and it is probable for this to cause permanent opacification as in Cases 4 and 6.

INCIDENCE

The overall incidence of corneal blood staining in the whole series was 2.1 per cent. (6 cases). The condition occurred only in those who developed secondary hyphaema (27 cases) and exclusively in those patients in whom the secondary hyphaema was total (18 cases). The incidence in these two groups was 22 and 33.3 per cent. respectively.

PROGNOSIS

In the absence of severe associated pathology, corneal blood staining seems to clear without permanent residual corneal changes even though the process may take 2 to 3 years. Four of our six patients (Cases 1, 2, 3, and 5) had completely clear corneae when reviewed for this study.

The two patients with permanent corneal opacification (Cases 4 and 6) both had severe associated ocular pathology, especially involving the anterior segment, and this no doubt contributed to the corneal changes.

Summary

- (1) The clinical and pathological features of corneal blood staining are reviewed and the differentiation from corneal haemorrhage is discussed.
- (2) Six examples of corneal blood staining which occurred in a series of cases of traumatic hyphaema are described. The condition was only observed after the occurrence of a total secondary hyphaema.
- (3) Some further suggestions regarding the aetiology of corneal blood staining have been made based on clinical features observed in these cases. Although a sustained rise in intraocular pressure is a contributory factor, it does not appear to be mandatory.
- (4) The prognosis is good in the absence of associated ocular damage; clearing was complete in four out of six cases within 3 years.
- (5) The incidence rises sharply from 2.1 per cent. in the whole series to 33 per cent. if the complication of total secondary hyphaema occurs.

I wish to thank Dr. J. L. S. Smith for supplying the histology slides.

References

- BERLINER, M. L. (1949) "Biomicroscopy of the Eye", vol. 1. Hoeber, New York
- BRODRICK, J. D., and HALL, R. D. (1971a) *Proc. roy. Soc. Med.*, **64**, 931
- (1971b) *Trans. ophthal. Soc. U.K.*, **91**, 757
- DUKE-ELDER, S. (1938) "Text-book of Ophthalmology", vol. 2, p. 2037. Kimpton, London
- and LEIGH, A. G. (1965) "System of Ophthalmology", vol. 8, pt. 2, p. 982. Kimpton, London
- GREER, C. H. (1963) "Ocular Pathology", p. 202. Blackwell, Oxford
- HOGAN, M. J., and ZIMMERMAN, L. E. (1962) "Ophthalmic Pathology. An Atlas and Textbook", 2nd ed., p. 337. Saunders, Philadelphia
- RYCHENER, R. O. (1944) *J. Amer. med. Ass.*, **126**, 763
- THYGESON, P., and BEARD, C. (1952) *Amer. J. Ophthal.*, **35**, 977