

Mechanism of the dicrotic pulse

DAMON SMITH, ERNEST CRAIGE

From the Department of Medicine of the University of North Carolina, Chapel Hill, North Carolina, USA

SUMMARY The dicrotic pulse is an abnormal carotid pulse found in conjunction with certain conditions characterised by low cardiac output. It is distinguished by two palpable pulsations, the second of which is diastolic and immediately follows the second heart sound. In the course of open chest canine studies of the second heart sound, micromanometers and an electromagnetic flow meter were used to study proximal aortic haemodynamic function in both strong and weak beats. It was found that the incisural notch of the aortic pressure signal is not strongly dependent on the extent of left ventricular ejection, and is of essentially normal amplitude even in beats having greatly reduced aortic flow. In contrast, the magnitude of the systolic upstroke of the aortic pressure pulse is strongly determined by the magnitude of left ventricular ejection and is considerably reduced in weak beats. With low cardiac output the relative size of the incisural notch becomes exaggerated in comparison with the overall pulsation, thus creating the characteristic M shaped waveform of the dicrotic pulse.

The dicrotic pulse has long been described as a physical sign associated with low cardiac output.¹ As early as 1863, with the development of Marey's sphygmograph, the abnormality was documented graphically. This abnormal pulsation is characterised by the presence of two distinct upstrokes, the second being diastolic and immediately following the second heart sound. This configuration is shown in fig 1. Flemming suggested in 1881 that the necessary conditions for the abnormality included a fast pulse, elastic vessels, feeble tension in the vessels, and a small amount of blood injected with each ventricular systole.² In 1902, MacKenzie pointed out that dicrotism is usually present in conditions of weak ventricular contraction and relaxed vessels.³ Dicrotism has also been found in association with cardiomyopathy.^{4,5} In a more recent paper from this laboratory, Orchard and Craige reported that persistence of the dicrotic pulse is an important prognostic sign after open heart surgery.⁶

The mechanism of the dicrotic pulse has been the subject of debate. The importance of a competent aortic valve was suggested by the study of Orchard and Craige in which two of their patients lost ini-

tially large dicrotic waves when a paravalvar aortic leak developed.⁶ The contractile state of the myocardium is also of fundamental importance. Orchard and Craige reported that in pulsus alternans it is the weaker beats that display the dicrotic pulse more prominently. Some have suggested that dicrotism is a distortion of the waveform resulting from abnormal arterial resistance such that the dicrotic wave becomes exaggerated.⁴

As a part of open chest canine studies designed to study the second heart sound, we have made observations which we feel explain the genesis of this phenomenon.

Methods

Six mongrel dogs weighing from 20 to 35 kg were anaesthetised with intravenous pentobarbitone sodium and ventilated by means of a mechanical respirator. The dogs were placed in the supine position and a median sternotomy was performed. The pericardium was opened and sewn so as to create a pericardial cradle for the heart. The proximal aortic root was exposed by blunt dissection. An electromagnetic flow probe of the cuff type (Carolina Medical Electronics) was placed around the proximal aortic root, just above the coronary sinus. The flow signal was recorded on a direct current input channel of a multichannel physiological recorder (Electronics for Medicine VR12) with a bandwidth of

Requests for reprints to Damon Smith, BME, School of Medicine, University of North Carolina, 338 Burnett Womack Building, 229-H, Chapel Hill, NC 27514, USA.

Accepted for publication 21 August 1986

120 Hz. The aortic and ventricular pressure signals were detected through high fidelity micromanometer tipped catheters (Millar Instruments). The aortic catheter was inserted through the right external carotid artery, with its micromanometer tip positioned within 2 cm of the aortic valve. The ventricular catheter was inserted directly through the left ventricular wall at the apex and positioned in the apical region of the ventricular chamber. The aortic and left ventricular pressure signals were recorded with a frequency bandwidth of 250 Hz. In some cases the aortic pressure signal was also recorded with a bandwidth of 25 Hz, and this low fidelity signal is shown simultaneously with the high fidelity aortic pressure signal in figs 2, 3, and 4. The high and low fidelity aortic pressure tracings were obtained from the same micromanometer tipped

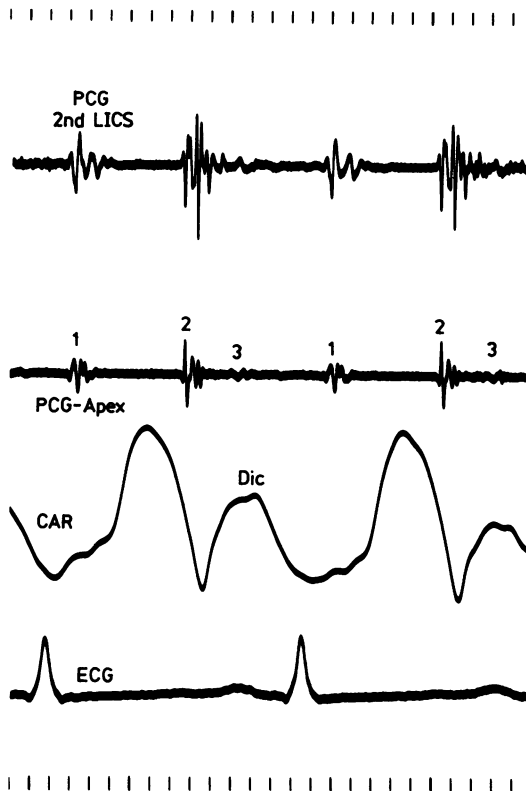


Fig 1 Recording of the carotid pulse and simultaneous phonocardiograms obtained from a patient with dilated cardiomyopathy in the non-invasive cardiac graphics laboratory. The carotid tracing shows a dicrotic pulse with its distinguishing M shaped configuration of which the second component is diastolic. PCG 2nd LICS, phonocardiogram from second left intercostal space; PCG-Apex, phonocardiogram from apex; CAR, carotid tracing; Dic, the dicrotic wave; ECG, the electrocardiogram.

catheter. In the recordings made during studies of haemodynamic failure, the high fidelity aortic and ventricular pressure signals are calibrated, as indicated in figs 3 and 4. In contrast, the low fidelity aortic pressure signal is not calibrated and is adjusted between recordings so as to show a pulsation of approximately constant amplitude. The recordings were made during control conditions and during heart failure subsequent to global hypoxaemia caused by interruption of the mechanical respirator.

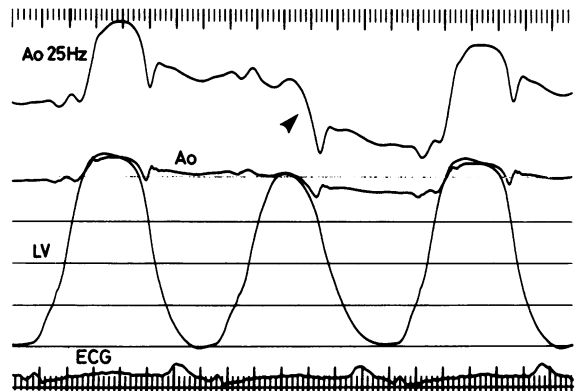


Fig 2 Recording obtained from open chest canine study during pulsus alternans. The weak beat shows no diminution of its incisural downstroke (arrow) and rebound, although its systolic upstroke is markedly diminished. Ao 25 Hz, low fidelity aortic pressure signal; Ao, high fidelity aortic pressure signal; LV, left ventricular pressure; ECG, electrocardiogram.

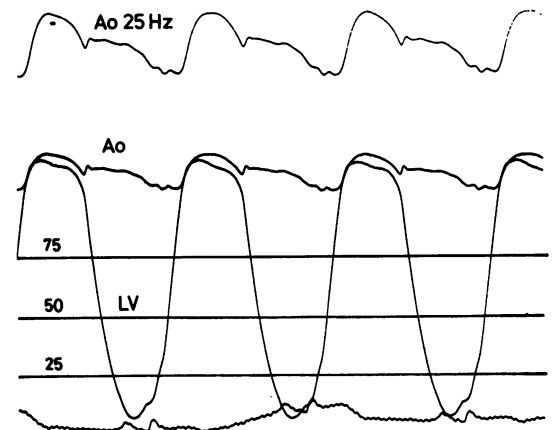


Fig 3 Recording obtained from open chest canine study during control condition. The aortic pressure waveform morphology is normal. Ao 25 Hz, low fidelity uncalibrated aortic pressure signal; Ao, high fidelity calibrated aortic pressure signal; LV, left ventricular pressure.

Results

Three of the dogs showed pulsus alternans, with alternating strong and weak beats. In addition, the weak beats showed slight alteration of strength, with some beats exceeding aortic pressure and others not exceeding aortic pressure. This fortuitous variation afforded an "experiment of nature" in which the incisural notch could be studied. An example is shown in fig 5. This figure shows a sequence of three weak beats numbered 1, 2, and 3. These numbered beats are shown to increase in strength, with beat number 2 being larger than number 1, and number 3

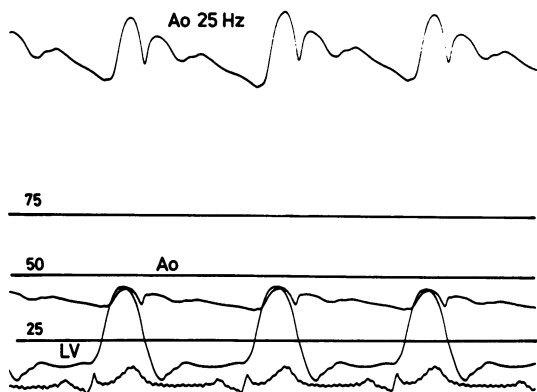


Fig 4 Recording obtained from same dog as in fig 3, now with heart failure. The low fidelity uncalibrated aortic pressure signal (*Ao* 25 Hz) now shows dicrotism. *Ao*, high fidelity calibrated aortic pressure signal; *LV*, left ventricular pressure.

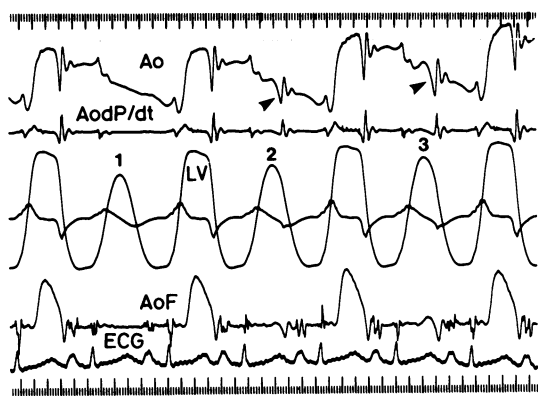


Fig 5 Recording obtained from open chest canine study during pulsus alternans. Weak beats numbered 1, 2, and 3 grow progressively in peak systolic pressure. Weak beats 2 and 3 result in incisural notches of the aortic pressure signal (arrows). *Ao*, high fidelity aortic pressure signal; *Ao dP/dt*, time derivative of aortic pressure; *LV*, left ventricular pressure; *AoF*, proximal aortic blood flow; *ECG*, electrocardiogram.

larger than number 2. In weak beat number 1 no aortic pressure pulse is produced. Therefore, the aortic pressure of beat number 1 shows no incisural downslope or rebound. During this beat there is no forward or retrograde proximal aortic flow seen in the flow signal. In weak beat number 2 an incisural downslope (arrow) and rebound is clearly demonstrated, even though essentially no forward aortic blood flow was detected in the flow signal. In weak beat number 3 the size of the incisural notch (arrow) is almost as large as that of the strong beats of the figure, even though the systolic upstroke of the pulsation is insignificant. Note also that the extent of retrograde aortic blood flow is as large in weak beat number 3 as it is in the strong beats, even though the extent of forward systolic blood flow is a very small percentage of that obtained in the strong beats.

Figure 2 shows simultaneously the high and low fidelity aortic pressure signals in a sequence that includes a weak beat due to pulsus alternans. The weak beat is characterised by a considerable reduction in the size of the overall aortic pressure pulse. The size of the incisural downslope (arrow) and rebound is, however, of the same size as that of the strong beats, again indicating the insensitivity of the magnitude of the incisural notch to the strength of systole.

Figures 3 and 4 were recorded from the same dog and indicate the characteristic alteration in the aortic pressure signal from the proximal aorta which we observed when the dogs experienced haemodynamic failure. Figure 3 shows the control condition, in which the aortic pressure signals display normal configuration. The incisural downslope and rebound are a small percentage of the overall pressure pulsation. Figure 4 shows the results obtained during haemodynamic failure. The overall aortic pressure pulse indicated in the calibrated high fidelity aortic pressure signal has reduced to approximately 60% of its size in fig 3. The size of the incisural notch, however, is essentially unchanged compared with that of fig 3. The amplifier gain of the low fidelity aortic pressure signal in fig 4 has been increased between recordings so that the size of the overall pulsation appears as large as in fig 3. When this is done, the low fidelity aortic pressure signal displays the characteristic dicrotic pulse waveform.

Discussion

In recording the carotid or other peripheral arterial pulsations in the non-invasive cardiac graphics laboratory it is widespread practice to adjust the amplifier gain of the recording equipment so as to obtain a tracing of convenient amplitude. This means that the smaller pulse associated with hae-

modynamic failure is routinely recorded with larger gain than is the normal pulse. This practice is appropriate in that no attempt is usually made to quantify the pulse, and it is the waveform configuration and timing that are of principal concern. We therefore include in our tracings a low fidelity uncalibrated aortic pressure signal for which we adjusted the amplifier gain between recordings as the dog developed haemodynamic failure. There are obvious differences between this low fidelity filtered proximal aortic pressure signal and the non-invasively obtained carotid pulse. One important difference is that this signal obtained from the proximal aorta is not subject to the distortion that occurs as the pulse travels down the arterial tree. Our purpose for including the low fidelity pressure signal is to demonstrate that the characteristic dicrotic wave configuration can be detected in the proximal aorta and is not dependent on modification of the pulse as it travels to the peripheral circulation.

It should be noted that the configuration of the arterial pulse is not dependent on the actual magnitudes of its various components but instead is determined by the relative contributions of these. We hypothesise that the development of dicrotism, which appears to involve an increase in amplitude of the dicrotic wave component, is not actually the result of an exaggeration of the dicrotic wave but rather of a reduction of the systolic upstroke of the pulsation in conjunction with an essentially normal amplitude of the incisural downslope and rebound. This results in the characteristic M shaped configuration.

The ability to palpate the secondary component of the dicrotic pulse appears to be a consequence of the characteristics of the tactile sense. If two pulsations occurring closely in time are applied to the fingers, the ability to detect the second pulsation depends to a large extent on the relative amplitudes of the two pulsations. If the first pulsation is much more prominent than the second, the secondary pulsation will not be perceived. If the amplitude of the first pul-

sation is then reduced so as to more nearly equal the amplitude of the second pulsation, the second pulsation can be palpated even though it has not changed in amplitude. The auscultatory analogue of this phenomenon is well known, in that a loud sound or murmur may interfere with the appreciation of an immediately following softer event.

Conclusion

Whereas in the past cardiologists have interpreted the dicrotic pulse as the result of an exaggeration of the dicrotic wave, the actual basis for the unusual waveform appears to be a reduction of the overall pressure pulse in conjunction with an essentially normal magnitude of the incisural downslope and rebound. This causes the pulse to show a considerable increase in the relative contribution from the incisura, resulting in the characteristic M shaped waveform. Although we cannot exclude an additional involvement of transmission distortion as the pulse travels peripherally, we have demonstrated that the characteristic waveform of dicrotism can be detected in the proximal aorta immediately above the aortic valve.

References

- 1 O'Rourke RA. Physical examination of the arteries and veins (including blood pressure determination). In: Hurst JW, ed. *The heart*. New York: McGraw Hill, 1986:145.
- 2 Flemming WJ. Pulse dicrotism. *Journal of Anatomy and Physiology* 1881;15:278-91.
- 3 MacKenzie J. *The study of the pulse, arterial, venous and hepatic and of the movement of the heart*. London: Young J Pentland, 1902:25.
- 4 Ewy GA, Rios JA, Marcus FI. The dicrotic arterial pulse. *Circulation* 1969;39:655-61.
- 5 Meadows WR, Draur RA, Osadjan CE. Dicrotism in heart disease. *Am Heart J* 1971;82:596-608.
- 6 Orchard RC, Craige E. Dicrotic pulse after open heart surgery. *Circulation* 1980;62:1107-14.