

## **The ultrastructure of mast cells in the uterus throughout the normal menstrual cycle and the postmenopause\***

**LOUISE DRUDY, BRIAN L. SHEPPARD AND JOHN BONNAR**

*TCD Department of Obstetrics and Gynaecology, Sir Patrick Dun Research Centre,  
St. James's Hospital, Dublin 8, Ireland*

*(Accepted 28 August 1990)*

### INTRODUCTION

With increasing evidence of inter- and intra-species mast cell heterogeneity (Enerback 1966 *a, b, c*; Steer, 1976; Strobel, Miller & Ferguson, 1981) human mast cell function can no longer be inferred from studies using purified rat peritoneal mast cells. Cyclical changes and patient variability have been observed by light microscopy for mast cell numbers in the functional endometrium, basal endometrium and the endometrial/myometrial border throughout the menstrual cycle (Drudy, Sheppard & Bonnar, 1990 *a*). Mast cells were identified in all areas of the anterior wall of the corpus uteri, having been stained by the uranyl nitrate metachromatic method following fixation in 10% formalin. Although mast cells were not observed in every patient in the functional endometrium they were present in the basal endometrium in all cases. However, ultrastructural studies throughout the menstrual cycle have not previously been undertaken. Mast cells are readily identified by light microscopy, although electron microscopy is necessary to identify the pregranular and degranulating mast cell. Fewer mast cells are present in the postmenopausal uterus (Drudy, Sheppard & Bonnar, 1990 *b*). The present study was undertaken to examine the mast cells in all layers of the uterine wall throughout the normal menstrual cycle and in the postmenopausal uterus.

### MATERIALS AND METHODS

Biopsies were obtained from uteri at hysterectomy following the clinical diagnosis of utero-vaginal prolapse and/or stress incontinence. Group 1, Table 1, contains details of patients from whom biopsies were taken covering the full range of the menstrual cycle and Group 2, Table 2, gives details of patients in their postmenopausal years.

Immediately following hysterectomy, biopsies were taken from the anterior wall of the upper uterine body incorporating both endometrium and myometrium. One part of each biopsy was fixed in unbuffered 10% formalin for routine processing for light microscopy for histological dating of the menstrual cycle according to the method of Noyes, Hertig & Rock (1950) modified by Fox (1973). The second part was immediately immersed in cold 0.067 M sodium cacodylate-buffered 2.5% glutaraldehyde, pH 7.4, for 1½ hours. Tissue was dissected into 1 mm cubes of known orientation. In Group 1, samples were taken of functional endometrium, basal

\* Reprint requests to Louise Drudy, Department of Obstetrics and Gynaecology, Royal College of Surgeons in Ireland, Rotunda Hospital, Dublin 1, Ireland.

Table 1. *Summary of patients with normal menstrual cycles having hysterectomy for utero-vaginal prolapse and/or stress incontinence. (Group 1, n = 28)*

Stage of menstrual cycle	Number of patients	Mean age (years)	Age range (years)	Mean $\pm$ s.d. Duration of vaginal bleeding (range) (days)	Mean $\pm$ s.d. Duration of menstrual cycle (range) (days)	Mean number of pregnancies (range)
Menstrual	5	46	41-50	5.16 $\pm$ 1.04 (4-6)	28.83 $\pm$ 0.76 (28-29.5)	5.5 (4-7)
Early proliferative	2	39	34-44	5.5	28	3.0 (0-6)
Mid-proliferative	4	38	28-49	6.75 $\pm$ 1.76 (5.5-8)	27.25 $\pm$ 3.18 (25-29.5)	6.0 (4-9)
Late proliferative	4	44	41-49	6.66 $\pm$ 1.52 (5-8)	24.50 $\pm$ 3.27 (21-27.5)	6.0 (1-9)
Early secretory	4	38	31-44	3.33 $\pm$ 1.25 (2-4.5)	30.66 $\pm$ 3.78 (28-35)	3.5 (2-8)
Mid-secretory	5	36	27-43	4.83 $\pm$ 2.02 (2.5-6)	25.50 $\pm$ 5.22 (22-31.5)	4.6 (3-7)
Late secretory	4	40	36-45	5.75 $\pm$ 1.84 (3.5-7.5)	28.62 $\pm$ 0.94 (28-30)	3.5 (1-5)

Table 2. *Summary of patients having hysterectomy for utero-vaginal prolapse and/or stress incontinence in their postmenopausal years. (Group 2, n = 9)*

Years postmenopausal	Number of patients	Mean age (years)	Age range (years)	Mean number of pregnancies (range)
1-5 years	3	54	53-66	3.6 (3-4)
6-10 years	3	61	56-64	6.3 (5-9)
11-20 years	3	63	62-66	6.3 (2-13)

endometrium, endometrial/myometrial junction and the myometrium and from patients in Group 2 samples were taken of endometrium, endometrial/myometrial junction and the myometrium. The myometrial sample was always taken from the area adjacent to the endometrium. The tissue samples were postfixed in 0.067 M sodium cacodylate-buffered 1.33% osmium tetroxide, pH 7.4, for one hour at 4 °C, stained in 0.25% uranyl acetate in 75% ethanol and dehydrated through graded ethanols prior to embedding in epoxy resin. One micrometre sections were stained with a 1:1 solution of 1% methylene blue and 1% azure II and examined for the presence of mast cells. Ultrathin sections, cut with an LKB Ultratome III, were stained with lead citrate (Reynolds, 1963) and examined with an Hitachi HU 12A and a JEOL 100 CX electron microscope.

## RESULTS

Mast cells were rarely seen in the functional endometrium but they were plentiful in the endometrial/myometrial junctional region and in the myometrium. In the loose connective tissue of the functional endometrium mast cells they were round or ovoid, whereas in the fibrous connective tissue of the basal endometrium and myometrium they were elongated; their shape often appeared to be dependent on the density of the surrounding tissue. The presence of surface processes was not obvious when the mast cell was surrounded by compact tissue.

A variety of granule structures was identified which was similar to those reported in mast cells from other human tissues, such as skin (Hibbs, Burch & Philips, 1960; Hibbs, Philips & Burch, 1960; Kobayashi, Midtgard & Asboe-Hansen, 1968),

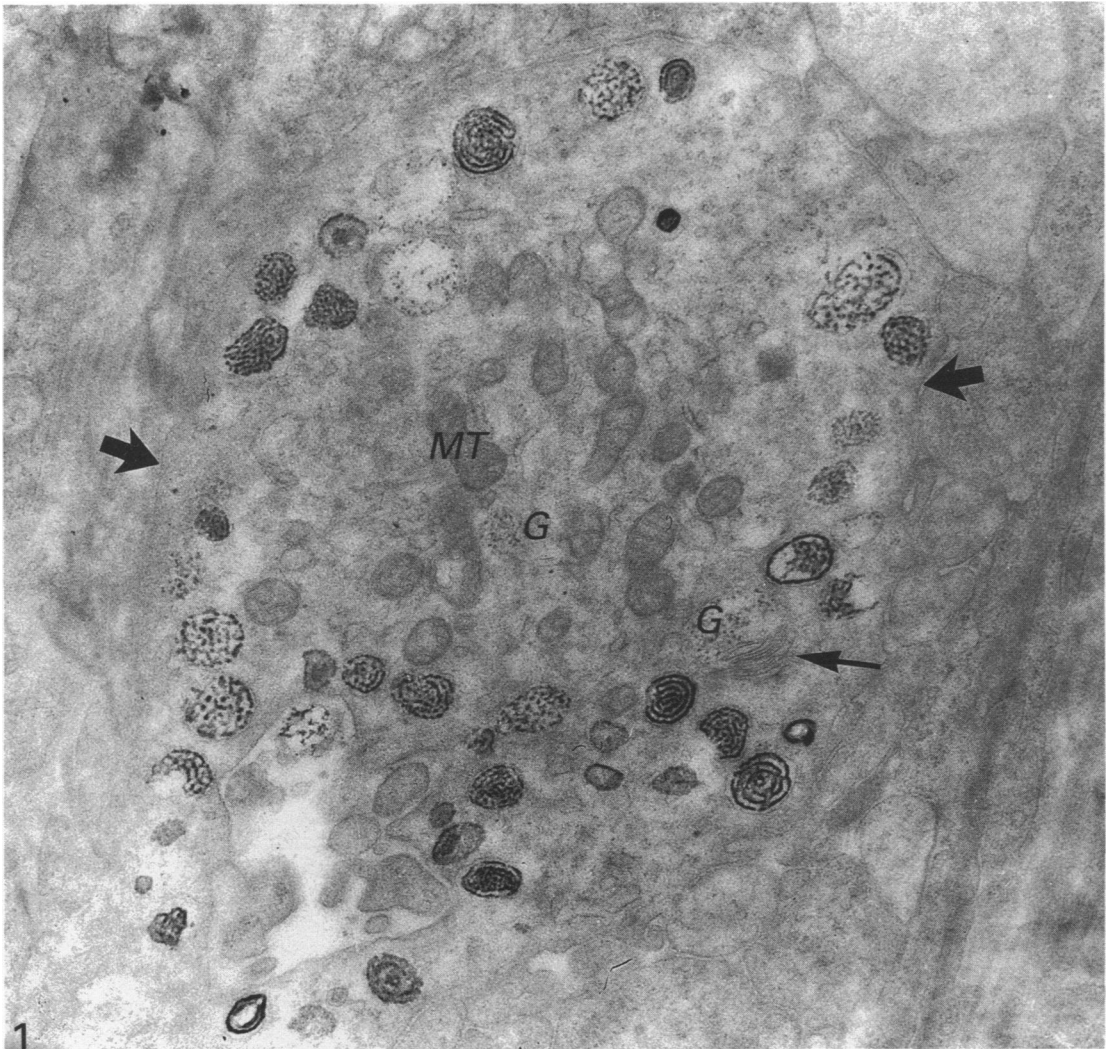


Fig. 1. Menstrual phase of the cycle, Day 2. Mast cell with particulate granules (G) in the remnants of degenerating endometrium. Mitochondrion, MT; parallel lamellar structures, small arrow; mast cell membrane, large arrows.  $\times 28000$ .

bronchial mucosa (Brinkman, 1968), gastrointestinal tract (Steer, 1976; Fox *et al.* 1985), lung (Dvorak *et al.* 1983), rectum (Heatley *et al.* 1979) and nose (Freidman, Metcalfe & Kaliner, 1986).

A gradation in granule substructure from the functional endometrium towards the myometrium was observed in the majority of uteri from patients in Group 1. Although no definite lines of demarcation could be drawn as to where mast cells with one type of granule were located, mast cells with few faint particulate granules were only seen near the endometrial surface (Fig. 1). Mast cells which contained more electron-dense particulate granules were seen in the deepest layers of the endometrium. In the myometrium mast cells were observed that were packed with electron-dense granules (Fig. 2). Granules with a substructure of scrolls were mostly seen in mast cells in the basal endometrium and in the endometrial/myometrial junction (Fig. 3).

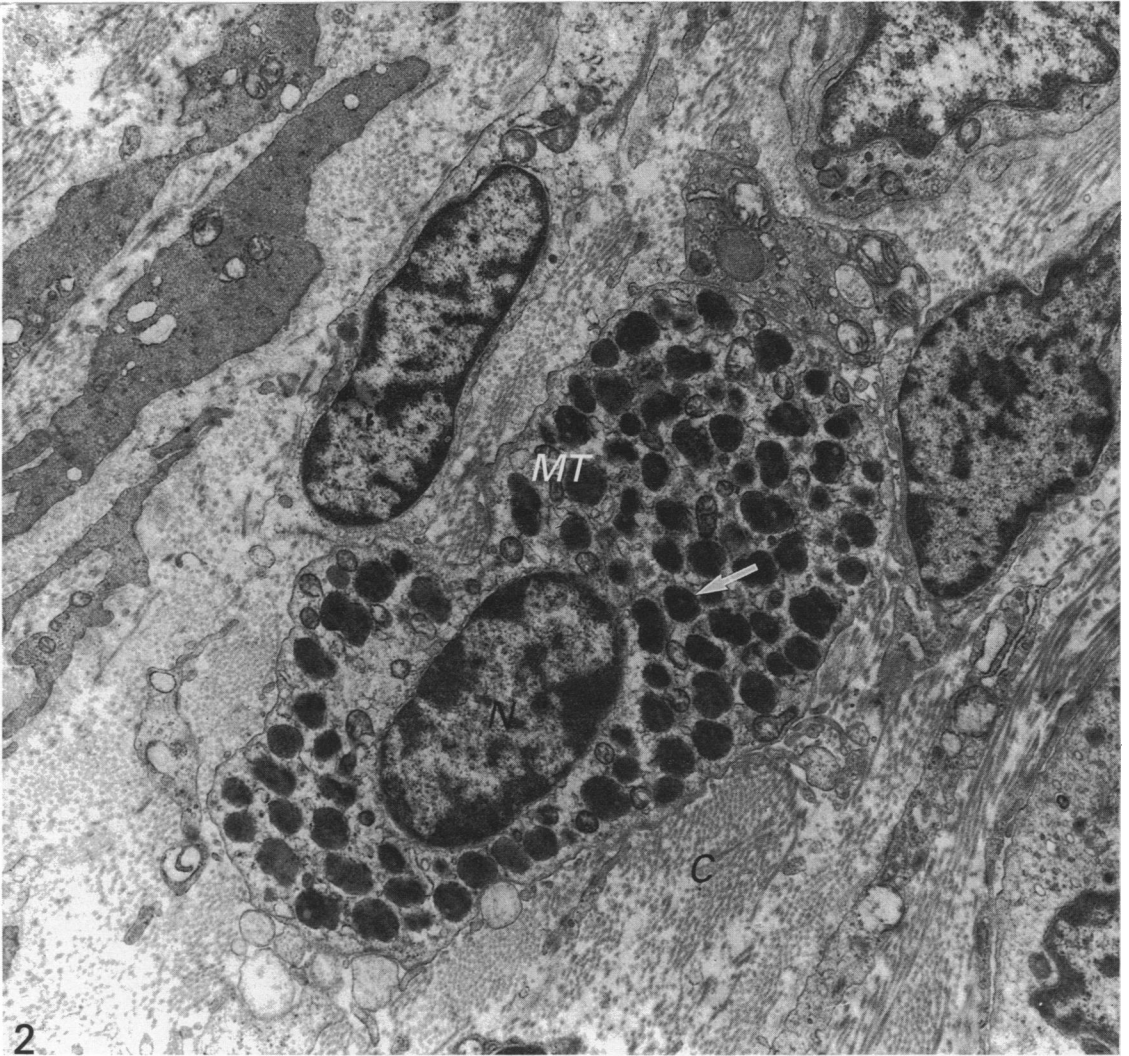


Fig. 2. Menstrual phase of the cycle, Day 3. Mast cell with very electron-dense granules (arrow) in the myometrium. Nucleus, *N*; mitochondrion, *MT*; collagen, *C*.  $\times 14000$ .

#### *Mast cells throughout the normal menstrual cycle*

Considerable variability in mast cell ultrastructure, particularly in the endometrium, was observed in biopsies, not only at the various stages of the menstrual cycle, but also from patient to patient at any particular stage. More uterine mast cells were observed in the menstrual and late secretory stages of the menstrual cycle and the pattern of mast cell ultrastructure did not appear to be associated with a particular tissue component in the uterine wall at any stage of the menstrual cycle.

On Day 2 of the menstrual cycle, mast cells contained granules with appearances varying from a few particles to joined particles held together in a rope-like structure. In the remnants of degenerating endometrium mast cells exhibited condensation of granule contents (Fig. 4). During the final days of menstruation extensive invagination (Fig. 5) of the mast cell membrane and mast cells containing many vacuoles were

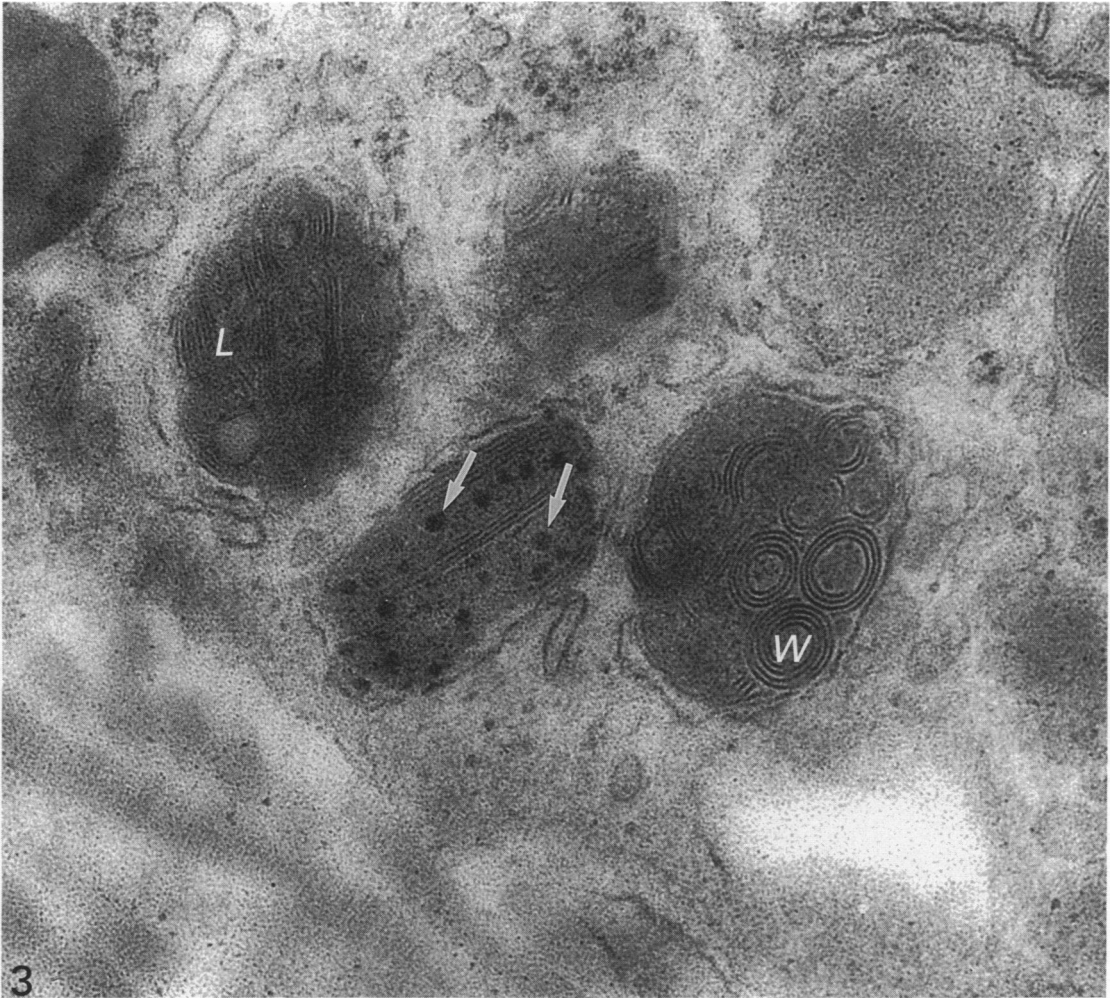


Fig. 3. Late secretory phase of the menstrual cycle. High magnification of mast cell granules containing scrolls in the endometrial/myometrial junction. Dense particles (arrows) are scattered along the central axis. Whorl, *W*; lamellar structures, *L*.  $\times 144\,000$ .

observed (Fig. 6). A characteristic feature of mast cells in the early proliferative stage of the cycle was the presence of many smooth-surfaced cisternae or vesicles in the cytoplasm which appeared to be associated with the Golgi complex. Mast cells near the regenerated endometrial surface contained particulate granules; vacuoles were not in evidence. More mast cells with particulate granules and vacuolation were seen in the mid-proliferative stage of the cycle. In the endometrial/myometrial junction oval mast cells containing particulate granules and an invaginated cell membrane were observed (Fig. 7).

In the late proliferative stage of the menstrual cycle, slight invagination of the mast cell membrane and vacuolation were observed in mast cells containing particulate granules; slight invagination of the mast cell membrane was also observed in the endometrial/myometrial border. However, very electron-dense granules were also observed in the cytoplasm of these mast cells, with few vacuoles.

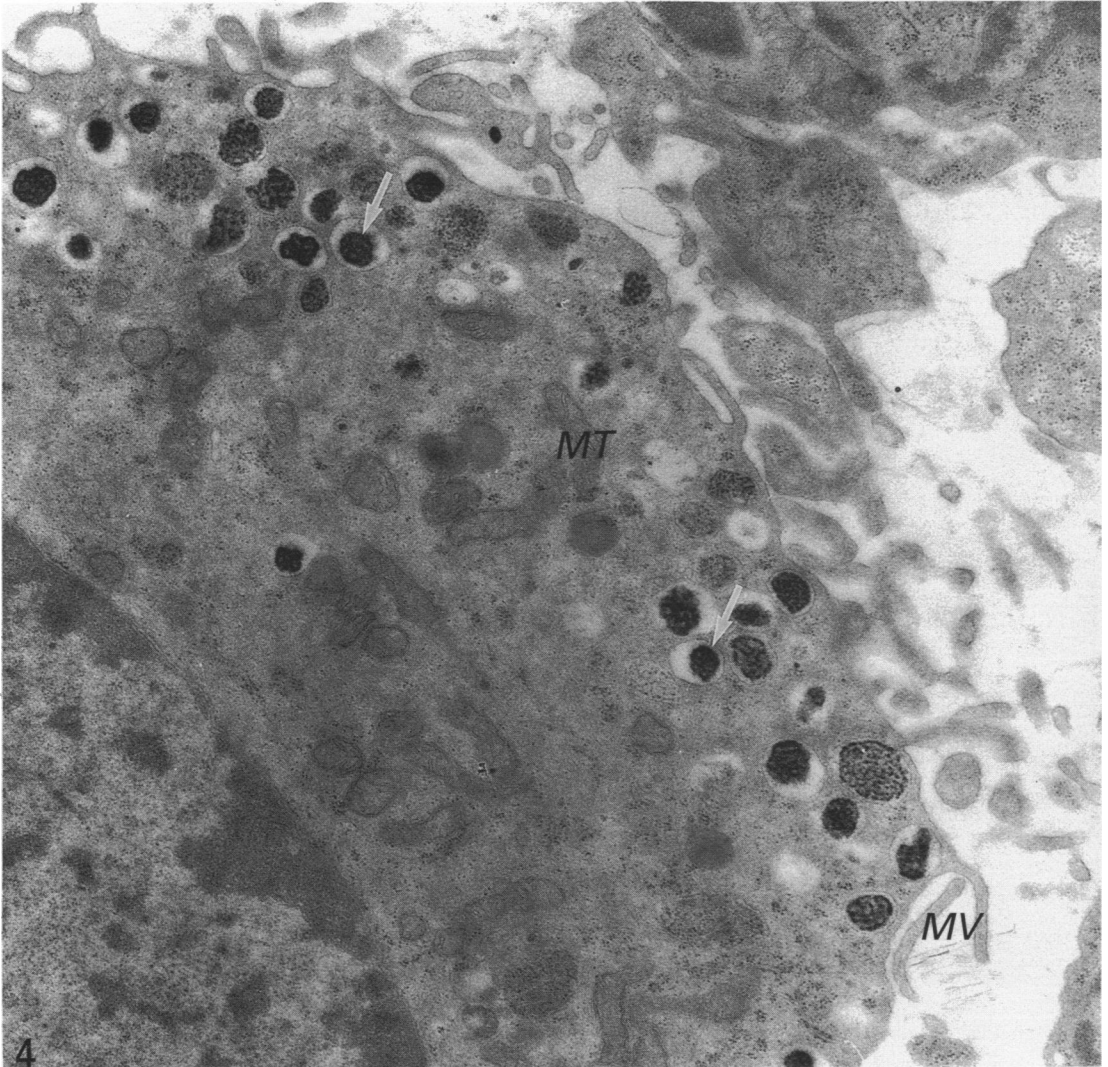


Fig. 4. Menstrual phase of the menstrual cycle, Day 5. Mast cell in the remnants of degenerating endometrium showing granules containing compact granular material (arrows) located on the periphery of the cell. Mitochondria, *MT*; microvilli, *MV*.  $\times 24000$ .

Oedema was observed in the endometrium in the early secretory phase of the menstrual cycle. Mast cells in the endometrium contained granules with a very dense particulate structure. However, constriction of the particulate structures was a very common finding. In the myometrium, invagination of the mast cell membrane was rarely seen but mast cells contained many membrane-bound granules with fragments of scrolls. In the mid-secretory phase mast cells in the endometrium contained particulate granules with a varied substructure; mast cell granules with constriction of particulate contents or partially full of particles or full of dense particulate material were observed. In the endometrial/myometrial junction and in the myometrium, granules containing fragments of scrolls were seen.

In the late secretory phase of the menstrual cycle the gradation in density of mast

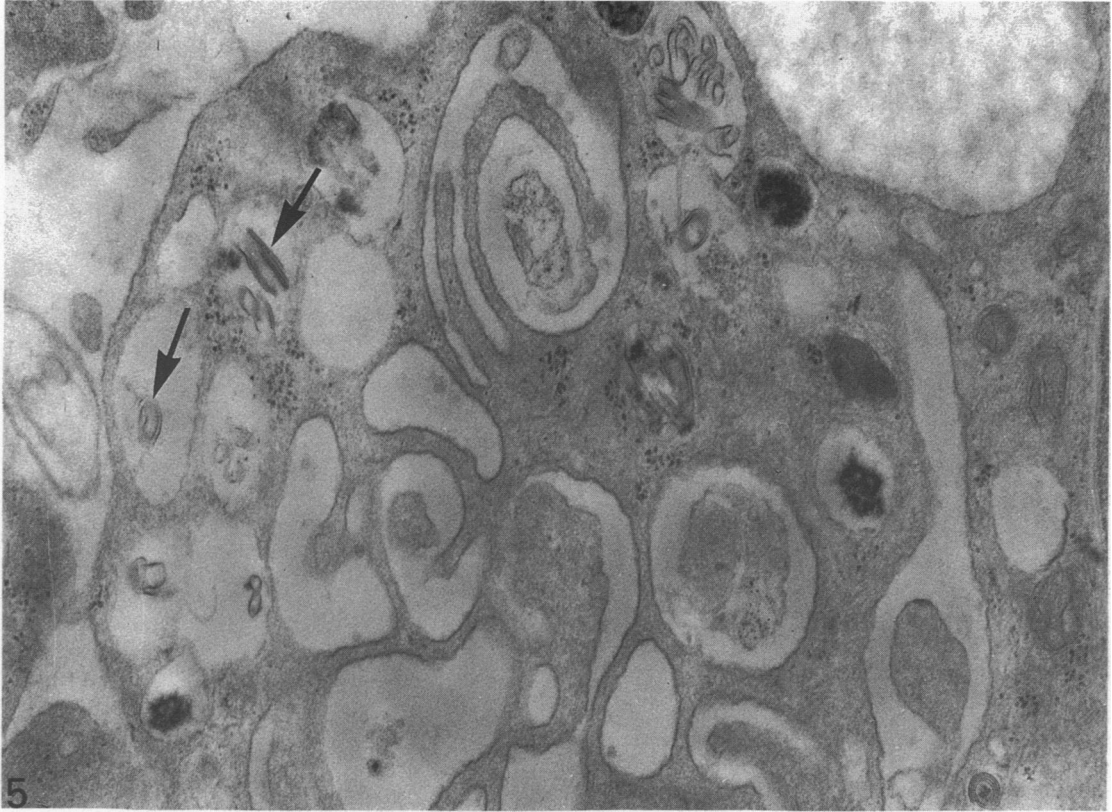


Fig. 5. Menstrual phase of the menstrual cycle, Day 5. Mast cell in the remnants of degenerating endometrium showing fragments of lamellae and scrolls (arrows) and invagination of the cell membrane.  $\times 63000$ .

cells with particulate granules in the endometrium was most striking, with mast cells containing the most electron-dense particulate granules being observed in the basal regions of the endometrium. Invagination of the mast cell membrane and constriction of granular contents were observed in these mast cells. In mast cells in the endometrial/myometrial junction and the myometrium, vacuoles with fragments of whorls and lamellae were seen less frequently than swollen granules with condensed contents (Fig. 9). A large number of mast cells with full-sized granules were also seen (see Fig. 2). Swollen granules were also seen, without condensation of contents. Invagination of the mast cell membrane was frequently seen in all types of mast cells.

#### *Ultrastructure of mast cells in the postmenopausal uterus*

By light microscopy cystic glandular enlargements were seen in most postmenopausal uteri. Both intra- and extracellular inclusions of lipid were particularly abundant in the uterine wall of the older postmenopausal women. Mast cells were rarely seen in the endometrium. Large numbers of mast cells were seen in the myometrial side of the endometrial/myometrial junction and in the deeper layers of the myometrium. No distinct pattern of mast cell location was found. Mast cells with particulate granules were not seen. Mast cells nearest to the endometrial surface were, in general, rounded with few granules; the nucleus was large in relation to the rest of

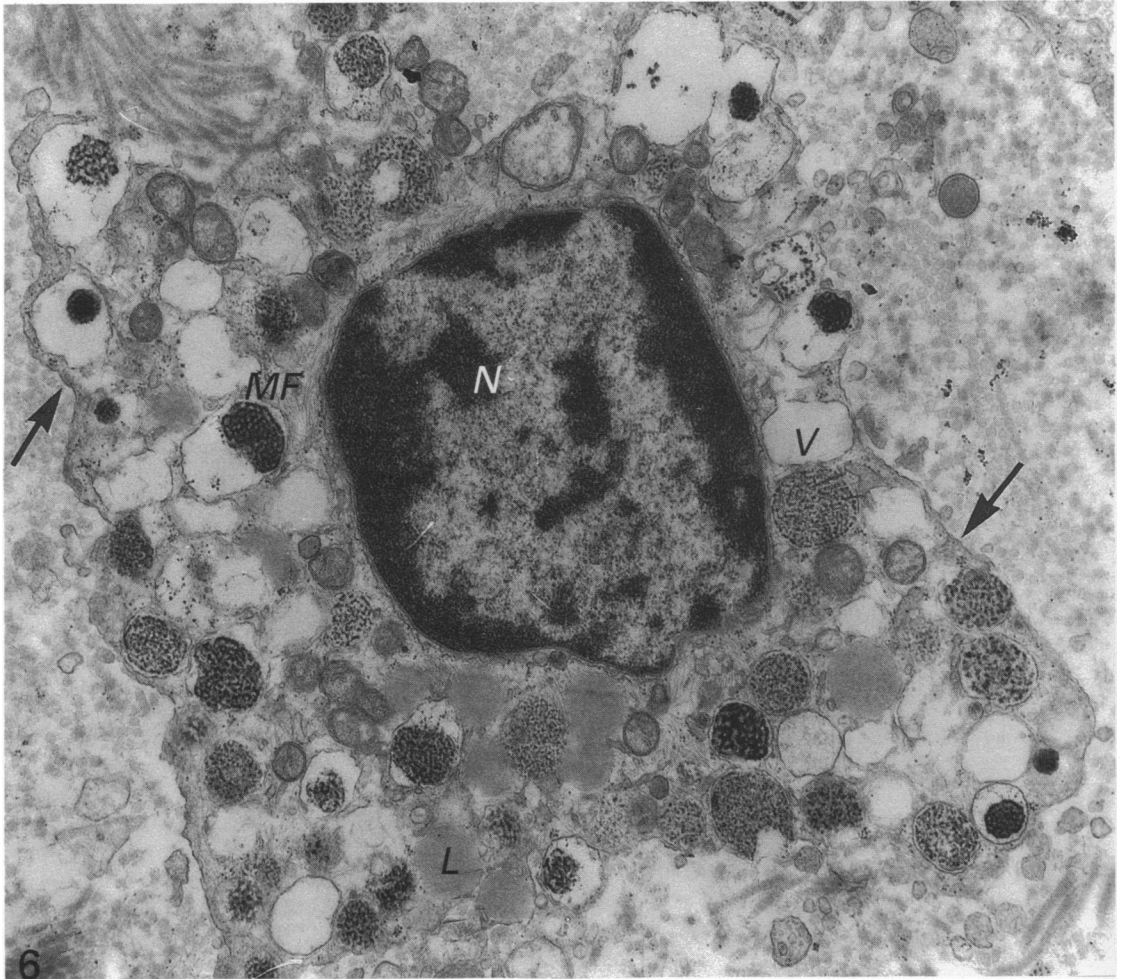


Fig. 6. Late menstrual phase of the menstrual cycle, Day 12. Mast cell in the endometrial/myometrial junction containing particulate granules and many membrane-bound vacuoles (*V*). Nucleus, *N*; lipid, *L*; microfilaments, *MF*; mast cell membrane, arrows.  $\times 21\,000$ .

the cell. In the deeper layers of the myometrium mast cells were seen that were elongated and had more numerous granules (see Fig. 2). Opaque areas, lipid-like in appearance were seen in some granules. Invagination of the mast cell membrane, as seen in specimens from Group 1, was not observed in the postmenopausal uterus. Vacuoles were not frequently seen in mast cells; however, membrane-bound fragments of scrolls were seen. In the older postmenopausal women (11–20 years postmenopausal) all mast cells showed similar granules to those seen in Figure 2.

#### DISCUSSION

The presence of mast cells containing particulate granules has been associated with mast cell degranulation both in the human rectum (Heatley *et al.* 1979) and in the human nose and lung (Freidman *et al.* 1986). It has been suggested that the variety of subgranular structures identified in human mast cells may be due to the handling of



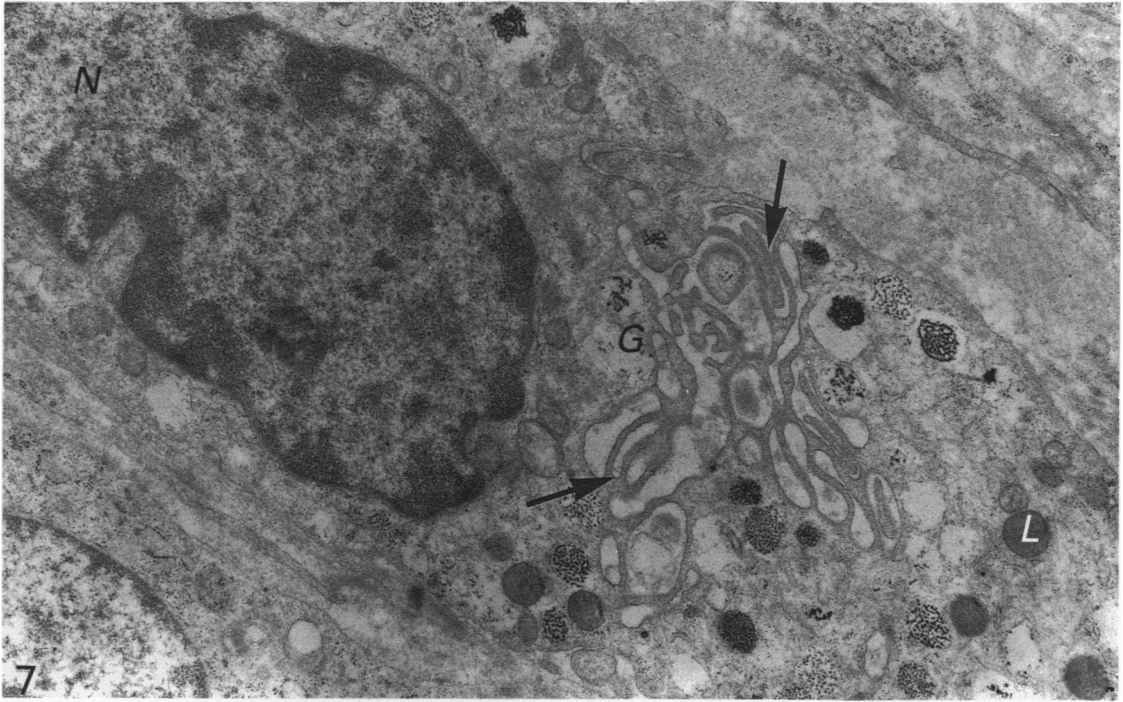


Fig. 7. Mid-proliferative phase of the menstrual cycle. Oval mast cell in the endometrial/myometrial junction containing particulate granules (G) and an invaginated cell membrane (arrows). Nucleus, N; lipid, L.  $\times 16000$ .

tissue or to different fixation times (Freidman *et al.* 1986). All the tissue biopsies in the present study underwent the same preparative procedures for examination by transmission electron microscopy.

The observations of Brinkman (1968), in his study of mast cells in the human bronchial mucosa and submucosa, and those of Steer (1976) in his study of mast cells of the human gastric mucosa were similar to the results presented here for mast cells in the human endometrium. Mast cells with particulate granules were absent in the postmenopausal uterus which suggests a function associated with that of the functional uterine mucous membrane.

The present study indicates that a certain amount of secretion of the contents of mast cell granules occurs throughout the menstrual cycle in the functional and the basal endometrium and to a lesser extent in the endometrial/myometrial border and the myometrium when the appearances are compared with model *in vitro* studies on human lung mast cells where mast cell degranulation or development were observed (Caulfield, Lewis, Heun & Austen, 1980; Dvorak *et al.* 1985). Total degranulation of uterine mast cells was rarely seen.

As well as having pathophysiological functions mast cells also have physiological roles in normal body processes (Riley, 1963; Norrby, Enerback & Franzen, 1976; Padawer, 1979; Azizkhan, Azizkhan, Zetter & Folkman, 1980). In the late secretory phase, although considerable functional activity is present, a large number of mast cells is also seen in the endometrial/myometrial junction and in the myometrium; these did not show signs of degranulation by electron microscopy.

A characteristic feature of mast cells at the early proliferative stage was the presence

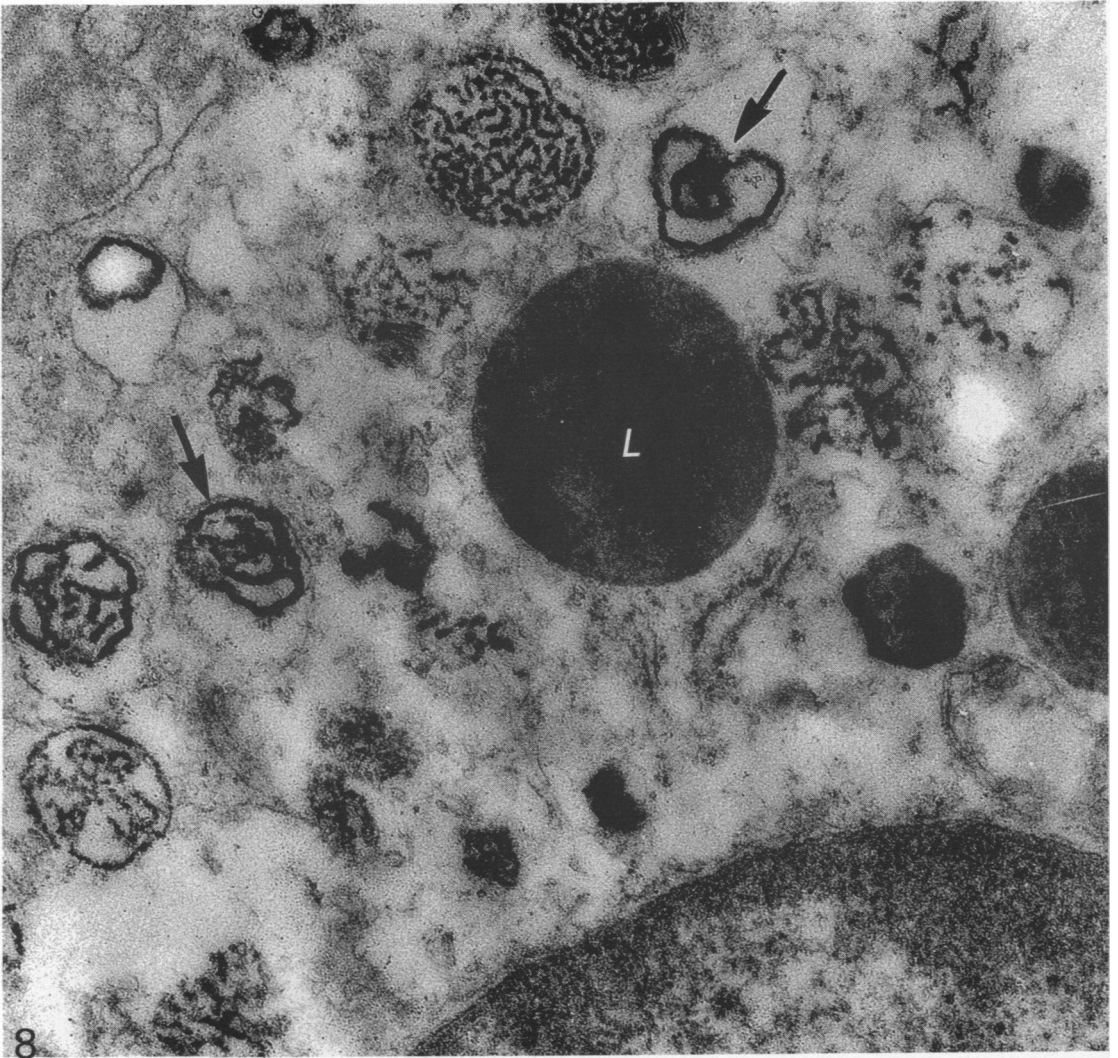


Fig. 8. Early secretory phase of the menstrual cycle. Mast cell in the functional endometrium. Constriction of contents of particulate granules are seen (arrows). Lipid, L.  $\times 35000$ .

of many smooth-surfaced cisternae or vesicles in the cytoplasm which appeared to be associated with the Golgi apparatus. Holm Nielson, Bytzer, Clausen & Chakravarty (1981), in a study of rat mast cell recovery, observed that the dominant feature of the Golgi apparatus was the presence of small vesicles which they suggested could be used in new membrane formation. Invaginations of the mast cell membrane, which was observed to a lesser extent than the smooth-surfaced cisternae or vesicles in the endometrial/myometrial junction and in the myometrium, could also suggest that recovery of mast cells was taking place due to the presence of internal villous projections.

The constriction of mast cell particulate contents observed in the early secretory phase of the menstrual cycle could be compared to the condensation of granule contents described by Dvorak *et al.* (1986) for mast cell granules containing scrolls

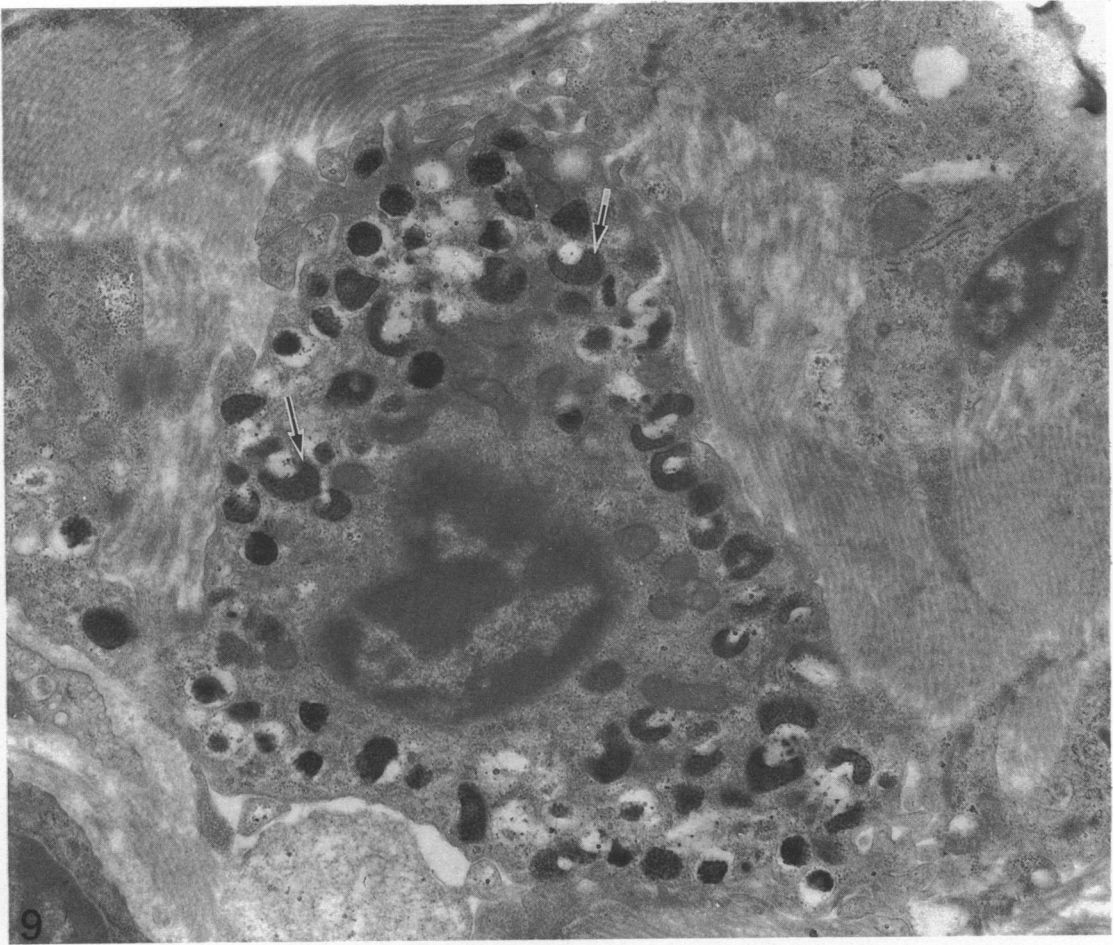


Fig. 9. Late secretory phase of the menstrual cycle. Mast cell in the basal endometrium showing granules with condensed contents (arrows).  $\times 18000$ .

which are undergoing recovery from degranulation. Brandon & Evans (1983) observed a decrease in mast cell numbers in the Syrian hamster before ovulation in the endometrium and myometrium, followed by an increase after ovulation. They reported that the increased numbers were not due to *de novo* synthesis of mast cells.

Total degranulation of mast cells was not observed during menstruation. In the late menstrual phase, degranulation by vacuolation and extensive invagination was observed in the endometrial/myometrial junction and in the myometrium. With sufficient tissue disruption, mast cell granules may reach the intravascular compartment. However their persistence within this compartment may be limited by their uptake and degradation by the endothelial cells that line large vessels (Atkins, Freidman & Metcalfe, 1985). The presence of endogenous heparin anticoagulating activity in the blood is rarely detected (Engelberg, 1977; Campbell, Hector & Gossain, 1979). Lindahl, Pertoft & Seljelid (1979) showed in the mouse that mast cell granules were phagocytosed by macrophages.

Available evidence suggests that mast cells of different animals and mast cells of different tissues of the same animal may be morphologically distinct (Maximow, 1906;

Enerback, 1966*b*; Enerback & Lundin, 1974; Collan, 1972; Steer, 1976; Brinkman, 1968). It cannot be shown from the present *in situ* study whether the presence of granules of differing ultrastructure represent stages in the functional activity of the granules or a developmental stage, or both. However, the results show that mast cell ultrastructure is dependent on the site of sampling within the uterine wall.

#### SUMMARY

During the menstrual cycle a gradation in mast cell granule ultrastructure was observed from the functional endometrium towards the myometrium of the uterus. Mast cells with particulate granules were present in the functional endometrium and those with granules containing identifiable scrolls in the basal layer of the endometrium and in the myometrium; mast cells containing very electron-dense granules were present in the deeper layers of the myometrium. The secretory activity of mast cells throughout the menstrual cycle is described. Mast cell secretion was observed to a lesser extent in the postmenopausal uterus. Mast cells with particulate granules were absent in the postmenopausal uterus and many very electron-dense granules were observed in mast cells in the myometrium.

The study was supported by grants from the Adelaide Hospital Research Foundation and the Medical Research Council of Ireland.

#### REFERENCES

- ATKINS, F. M., FREIDMAN, M. M. & METCALFE, D. D. (1985). Biochemical and microscopic evidence for the internalization and degradation of heparin-containing mast cell granules by bovine endothelial cells. *Laboratory Investigation* **52**, 278–286.
- AZIZKHAN, R. G., AZIZKHAN, J. C., ZETTER, B. R. & FOLKMAN, J. (1980). Mast cell heparin stimulates migration of capillary endothelial cells *in vitro*. *Journal of Experimental Medicine* **152**, 931–944.
- BRANDON, J. M. & EVANS, J. E. (1983). Changes in uterine mast cells during the estrous cycle in the syrian hamster. *American Journal of Anatomy* **167**, 241–247.
- BRINKMAN, G. L. (1968). The mast cell in normal human bronchus and lung. *Journal of Ultrastructure Research* **23**, 115–123.
- CAMPBELL, E. W., HECTOR, D. & GOSSAIN, V. (1979). Heparin activity in systemic mastocytosis. *Annals of Internal Medicine* **90**, 940–941.
- CAULFIELD, J. P., LEWIS, R. A., HEUN, A. & AUSTEN, K. F. (1980). Secretion in dissociated human pulmonary mast cells. *Journal of Cell Biology* **85**, 299–311.
- COLLAN, Y. (1972). Characteristics of non-epithelial cells in the epithelium of normal rat ileum. A light and electron microscope study. *Scandinavian Journal of Gastroenterology* **7**, Suppl. 18, 1–66.
- DRUDY, L., SHEPPARD, B. L. & BONNAR, J. (1990*a*). Mast cells in the normal uterus and in dysfunctional uterine bleeding. *European Journal of Obstetrics, Gynaecology and Reproductive Biology* (In Press).
- DRUDY, L., SHEPPARD, B. L. & BONNAR, J. (1990*b*). The mast cell and histamine concentration of the human postmenopausal uterus (submitted for publication).
- DVORAK, A. M., GALLI, S. J., SCHULMAN, E. S., LICHTENSTEIN, L. M. & DVORAK, H. F. (1983). Basophil and mast cell degranulation: ultrastructural analysis of mechanisms of mediator release. *Federation Proceedings* **42**, 2510–2515.
- DVORAK, A. M., SCHULMAN, E. S., PETERS, S. P., MACGLASHAN, D. W. JR., NEWBALL, H. H., SCHLEIMER, R. P. & LICHTENSTEIN, L. M. (1985). Immunoglobulin E-mediated degranulation of isolated human lung mast cells. *Laboratory Investigation* **53**, 45–56.
- DVORAK, A. M., SCHLEIMER, R. P., SCHULMAN, E. S. & LICHTENSTEIN, L. M. (1986). Human mast cells use conservation and condensation mechanisms during recovery from degranulation. *In vitro* studies with mast cells purified from human lungs. *Laboratory Investigation* **54**, 663–678.
- ENERBACK, L. (1966*a*). Mast cells in rat gastro-intestinal mucosa. I. Effects of fixation. *Acta pathologica et microbiologica scandinavica* **66**, 289–302.
- ENERBACK, L. (1966*b*). Mast cells in rat gastro-intestinal mucosa. II. Dye binding and metachromatic properties. *Acta pathologica et microbiologica scandinavica* **66**, 303–312.
- ENERBACK, L. (1966*c*). Mast cells in rat gastro-intestinal mucosa. III. Reactivity towards compound 48/80. *Acta pathologica et microbiologica scandinavica* **66**, 313–322.

- ENERBACK, L. & LUNDIN, P. M. (1974). Ultrastructure of mucosa mast cells in normal and compound 48/80 treated rats. *Cell and Tissue Research* **150**, 95–105.
- ENGELBERG, H. (1977). Probable physiologic functions of heparin. *Federation Proceedings* **36**, 70–72.
- FOX, C. C., DVORAK, A. M., PETERS, S. P., KAGEY-SOBOTKA, A. K. & LICHTENSTEIN, L. M. (1985). Isolation and characterization of human intestinal mucosal mast cells. *Journal of Immunology* **135**, 483–491.
- FOX, H. (1973). The normal and abnormal endometrium. In *Postgraduate Obstetrical and Gynaecological Pathology* (ed. H. Fox & F. A. Langley), p. 115. Oxford: Pergamon Press.
- FREIDMAN, M. M., METCALFE, D. D. & KALINER, M. (1986). Electron microscopic comparison of human nasal and lung mast cell degranulation. In *Mast Cell Differentiation and Heterogeneity* (ed. A. D. Befus, J. Bienenstock & J. A. Denburg), pp. 367–377. New York: Raven Press.
- HEATLEY, R. V., JAMES, P. D., BIRKINSHAW, M., WENHAM, R. B., MAYBERRY J. & RHODES, J. (1979). The role of intestinal mast cells and eosinophil cells in ulcerative proctocolitis in relation to prognosis and treatment. In *The Mast Cell: Its Role in Health and Disease* (ed. J. Pepys & A. M. Edwards), pp. 716–724. Tunbridge Wells: Pitman Medical.
- HIBBS, R. G., BURCH, G. E. & PHILIPS, J. H. (1960). Electron microscopic observations on the human mast cell. *American Heart Journal* **60**, 121–127.
- HIBBS, R. G., PHILIPS, J. H. & BURCH, G. E. (1960). Electron microscopy of human tissue mast cells. *Journal of the American Medical Association* **174**, 508–510.
- HOLM NIELSON, E., BYTZER, P., CLAUSEN, J. & CHAKRAVARTY, N. (1981). Electron microscopic study of the regeneration *in vitro* of rat peritoneal mast cells after histamine secretion. *Cell and Tissue Research* **216**, 635–645.
- KOBAYASHI, T., MIDTGARD, K. & ASBOE-HANSEN, G. (1968). Ultrastructure of human mast cell granules. *Journal of Ultrastructure Research* **23**, 153–165.
- LINDAHL, U., PERTOFT, H. & SELJELID, R. (1979). Uptake and degradation of mast cell granules by mouse peritoneal macrophages. *Biochemical Journal* **182**, 189–193.
- MAXIMOW, A. (1906). Über die Zellformen des lockeren Bindegewebes. *Archiv für mikroskopische Anatomie und Entwicklungsmechanik* **67**, 680–757.
- NORRBY, K., ENERBACK, L. & FRANZEN, L. (1976). Mast cell activation and tissue cell proliferation. *Cell and Tissue Research* **170**, 289–303.
- NOYES, R. W., HERTIG, A. T. & ROCK, J. (1950). Dating the endometrial biopsy. *Fertility and Sterility* **1**, 3–25.
- PADAWER, J. (1979). Mast cell structure: implications for normal physiology and degranulation. In *The Mast Cell: Its Role in Health and Disease* (ed. J. Pepys & A. M. Edwards), p. 1. Tunbridge Wells: Pitman Medical.
- REYNOLDS, E. S. (1963). The use of lead citrate at high pH as an electron opaque stain in electron microscopy. *Journal of Cell Biology* **17**, 208–212.
- RILEY, J. F. (1963). Functional significance of histamine and heparin in tissue mast cells. *Annals of the New York Academy of Science* **103**, 151–163.
- STEER, H. W. (1976). Mast cells of the human stomach. *Journal of Anatomy* **121**, 385–397.
- STROBEL, S., MILLER, H. R. P. & FERGUSON, A. (1981). Human intestinal mucosal mast cells, evaluation of fixation and staining techniques. *Journal of Clinical Pathology* **34**, 851–888.