

# Sudden death in a patient with chronic lymphocytic leukemia

Eliot R. Beaubien, MD; Thomas W. Wilson, MD;  
Niranjala Satkunam, MB, BS

## Abstract

THE AUTHORS DESCRIBE A 51-YEAR-OLD MAN with chronic lymphocytic leukemia who presented with respiratory distress and then died suddenly while in hospital. Autopsy revealed pulmonary leukostasis and a large intracardiac mass containing mostly mature lymphocytes and fibrin. Although leukostasis and lymphocyte thrombi have been described (albeit rarely) in chronic lymphocytic leukemia, an intracardiac "clot" has not. It seems plausible that this intracardiac mass caused the patient's death.

## Résumé

LES AUTEURS DÉCRIVENT LE CAS D'UN HOMME ÂGÉ DE 51 ANS atteint de leucémie lymphocytaire chronique qui s'est présenté à l'hôpital en état de détresse respiratoire et y est mort subitement. L'autopsie a révélé une leukostase pulmonaire et la présence d'une importante masse intracardiaque contenant surtout des lymphocytes à maturité et de la fibrine. Même si l'on a décrit (quoique rarement) la leukostase et des caillots lymphocytaires dans des cas de leucémie lymphocytaire chronique, on n'a pas décrit de «caillot» intracardiaque. Il semble plausible que cette masse intracardiaque ait causé la mort du patient.

**C**hronic lymphocytic leukemia (CLL) is the most common hematologic malignant disease in adults.<sup>1</sup> Although the disease is often indolent and the patient's life span may be unaffected, serious complications, including infection, hemolysis, bone marrow failure and transition to acute leukemia, can occur. We encountered a patient with CLL and an extraordinarily high peripheral lymphocyte count who died suddenly. There was histologic evidence of leukostasis, a rarely reported complication of CLL,<sup>2-4</sup> but also a large intracardiac mass composed of mature lymphocytes and fibrin. We suggest that this "clot" contributed in large measure to the patient's death.

## Case report

A 51-year-old man presented to the emergency department with a 2-day history of increasing dyspnea, abdominal discomfort and fatigue. CLL had been diagnosed 12 years earlier. He had taken prednisone and chlorambucil in the past but for the previous few months had refused any treatment other than prednisone (25 mg daily). He denied fever, chills, sputum production, bleeding and previous thromboembolic disease.

The patient's temperature was 36.2°C, his respiratory rate 22 breaths/min, his pulse 110 beats/min (regular) and his blood pressure 100/70 mm Hg in both supine and sitting positions. Oxygen saturation was 88% on room air and 95% with oxygen by mask. There were enlarged, nontender lymph nodes in the cervical, axillary and inguinal areas. Coarse crackles were audible throughout both lung fields. The jugular veins were distended to 8 cm above the angle of Louis, and there was marked peripheral edema. The cardiac apex was displaced laterally, there was a right ventricular heave, and third and fourth heart sounds were present. There was marked hepatosplenomegaly.



## Education

## Éducation

Dr. Beaubien is with the Department of Medicine, Dr. Wilson is with the Departments of Medicine and Pharmacology, and Dr. Satkunam is with the Department of Pathology, University of Saskatchewan, Saskatoon, Sask.

*This article has been peer reviewed.*

CMAJ 1998;159:1123-5

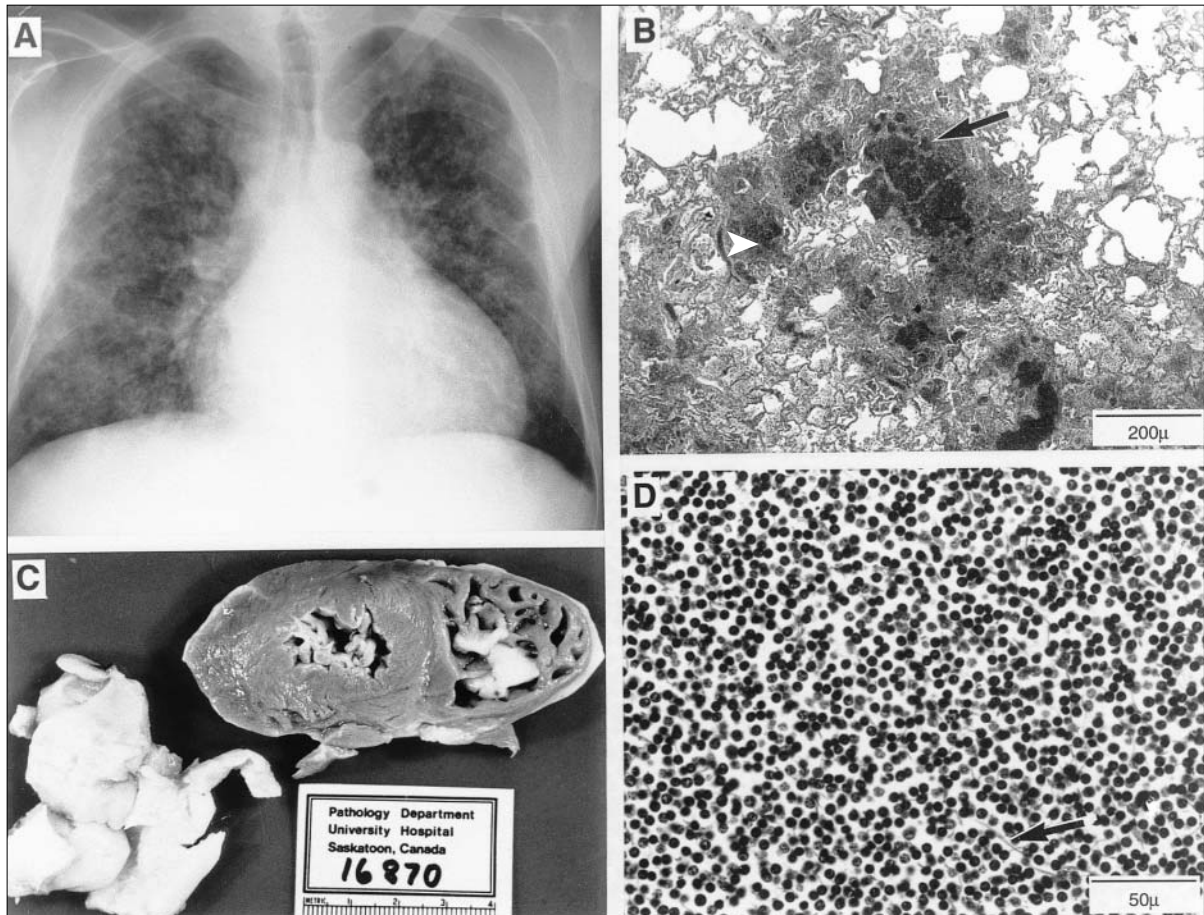


The hemoglobin concentration was 57 (normally 115–165) g/L, the total leukocyte count 824 (normally  $4\text{--}10 \times 10^9/\text{L}$  (95% mature lymphocytes) and the platelet count 15 (normally  $150\text{--}450 \times 10^9/\text{L}$ ). Serum levels of electrolytes, creatinine and liver enzymes were normal, as were the international normalized ratio and partial thromboplastin time. Electrocardiography showed only sinus tachycardia. A chest radiograph (Fig. 1A) revealed multichamber cardiomegaly and bilateral peripheral reticulonodular infiltration.

We administered oxygen by mask, as well as packed erythrocytes, hydrocortisone, furosemide, trimethoprim-sulfamethoxazole (intravenously) and piperacillin-tazobactam (intravenously). Echocardiography showed biventricular enlargement and hypokinesis, enlarged atria, moderate tricuspid and mitral insufficiency, and pulmonary hypertension. The patient remained slightly dyspneic at rest but was able to talk and eat. His temperature remained under  $37^\circ\text{C}$ , his heart rate around 100 beats/min and his blood pressure at 90–112/68–76 mm Hg. Oxygen

saturation, measured transcutaneously, was never below 92%. Suddenly, about 24 hours after admission, the patient became more short of breath and then unresponsive. Cardiopulmonary resuscitation was unsuccessful.

At autopsy, the heart was found to be enlarged (to 560 g), and both ventricles contained large gray-yellow rubbery masses, which were not adherent to the endocardium (Fig. 1C). These masses filled the ventricles and were moulded to the shape of the cavities. Histologic examination (Fig. 1D) showed that they were composed of mature lymphocytes and fibrin, without fungal hyphae. The coronary arteries were normal, and there were no clots in any other major vessel. The lungs were very heavy (more than 1500 g) and nodular in texture. No pus could be expressed. Histologic examination revealed marked obstruction of the blood vessels with mature lymphocytes; in some areas these cells had infiltrated the surrounding interstitium, and hemorrhaging had occurred (Fig. 1B). There was marked hepatomegaly (mass of liver 3230 g) and splenomegaly (mass of spleen 2320 g) due to infiltra-



**Fig. 1.** Patient with chronic lymphocytic leukemia who died suddenly. **A:** Chest radiograph. Multichamber cardiomegaly is accompanied by a peripheral reticulonodular lung infiltrate. **B:** Microscopic section of lung tissue. Mature lymphocytes obstruct small pulmonary vessels (arrow), and there is infiltration and hemorrhage in the interstitial spaces (arrowhead). **C:** The heart. The walls are thickened, and there is an intracardiac mass. **D:** Microscopic section of the intracardiac mass. There are sheets of mature lymphocytes, along with a few fibrin strands (arrow).



tion by mature lymphocytes; the bone marrow was diffusely replaced with mature lymphocytes. Postmortem cultures of blood, lung and the intracardiac mass were negative. Staining for *Pneumocystis carinii* was also negative.

## Comments

The patient we have described had a long-standing diagnosis of CLL, suffered a brief illness and died suddenly. The most striking features at autopsy were the large intracardiac masses found in both ventricles. The masses were quite firm but mobile and could have obstructed the outflow tracts of one or both ventricles, accounting for the suddenness of death. The masses consisted of lymphocytes and fibrin; platelets and erythrocytes were not prominent. We are unable to say for certain whether the masses were present before death; they were not seen in an echocardiogram obtained 15 hours before death. The echocardiogram did show global hypokinesis, which could have prevented the ventricles from expelling what must have been very thick blood. Furthermore, if the clots were a postmortem phenomenon, we might have expected to see similar thrombi in other large arteries or veins; however, none were present.

Thrombosis is a well-recognized complication of malignant diseases, including CLL and related lymphomas.<sup>5</sup> Postulated mechanisms of thrombosis include release of thromboplastin-like material by malignant cells, nonenzymatic activation of factor X by mucin-producing tumours, deficiencies in protein C and platelet activation, a poorly defined condition in which platelets are more prone to aggregate. In a 1974 review, McKee and Collins<sup>6</sup> described intravascular thrombi containing lymphocytes and fibrin in 2 of 33 cases of CLL. Neither patient had an intracardiac mass. A case of Budd–Chiari syndrome in a patient with CLL was attributed to fungal infection.<sup>7</sup> In that instance, the patient had massive ascites in addition to hepatosplenomegaly. Autopsy revealed clots in the hepatic veins and the inferior vena cava as well as an intracardiac clot 1 cm in diameter. All of the clots had hyphae that were easily visible by microscopy, and cultures yielded *Zygomycetes* species. Furthermore, the patient had been in hospital for a month, during which time her condition had deteriorated. The patient we have described had a large intracardiac mass that contained few erythrocytes or platelets and no hyphae. It is possible that the blood products or drug therapy that the patient received triggered the unusual clotting process.

It is likely that the pulmonary hypertension and signs of right-side heart failure in this patient were due to pulmonary vascular occlusion by masses of lymphocytes. A widespread reticulonodular lung infiltrate was evident on radiographs, but there was no histologic or microbiologic sign of infection. In other hematologic malignant diseases with

very high leukocyte counts, leukostasis may occur in the lungs;<sup>8</sup> it typically presents with dyspnea and hypoxia, and an interstitial infiltrate is evident on chest radiography.<sup>9</sup> This complication is seen more commonly in myeloid leukemias, presumably because the abnormal cells are larger, more rigid and more prone to being trapped in the capillaries.<sup>10</sup> Also, cells of the myeloid line are known to adhere to pulmonary endothelial cells in situations where complement is activated.<sup>11</sup> When leukostasis is severe, the pulmonary capillary network can be obstructed, which accounts for hypoxia and pulmonary hypertension. To our knowledge, no such complement-dependent mechanism has been described for lymphocytes. Our patient's extremely high total lymphocyte count may have led to pulmonary leukostasis simply through increased viscosity. In other organs, including the brain, most of the smaller blood vessels were plugged with lymphocytes.

Whether prompt leukapheresis would have been useful here is unknown. Repeated leukapheresis has been used to reduce hyperlymphocytosis and increase erythrocyte and platelet production.<sup>12</sup> A single report of a patient with CLL and radiologic evidence of leukostasis whose condition improved after leukapheresis suggests that this procedure might have been of some benefit.<sup>3</sup>

In summary, we have described a patient with a rare manifestation (leukostasis) of a common disease (CLL). His sudden death may have been due to intracardiac thrombosis, a previously undescribed complication.

## References

1. Flinn IW, Grever R. Chronic lymphocytic leukemia. *Cancer Treat Rev* 1996; 22:1-13.
2. Megaludis AM, Winkelstein A, Miller TR, Zeigler ZR. Leukostasis: a phenomenon of chronic lymphocytic leukemia [abstract]. *Blood* 1987;70(Suppl 1):204A.
3. Alcalay D, Deleplanque P, Maubras MA, Guilhot F. Leucaphérese thérapeutique au cours d'un syndrome de leucostase compliquant une leucémie lymphoïde chronique. *Ann Med Interne* 1988;139(Suppl 1):53-4.
4. Fitzer CWH, Schurr J, Potter van Loon BJ, Schweitzer MJH. Acute cardiorespiratory failure as presenting symptom of chronic lymphocytic leukemia. *Neth J Med* 1996;49:33-7.
5. Bick RL, Strauss JF, Frenkel EP. Thrombosis and hemorrhage in oncology patients. *Hematol Oncol Clin North Am* 1996;10:875-907.
6. McKee LC, Collins RD. Intravascular leukocyte thrombi and aggregates as a cause of morbidity and mortality in leukemia. *Medicine (Baltimore)* 1974;53:463-78.
7. Vallaes JH, Praet MM, Roels HJ, Van Mark E, Kaufman L. The Budd–Chiari syndrome caused by a zygomycete. A new pathogenesis of hepatic vein thrombosis. *Arch Pathol Lab Med* 1989;113:1171-4.
8. van Buchem MA, te Velde J, Willeme R, Spaander PJ. Leukostasis: an underestimated cause of death in leukemia. *Blut* 1988;56:39-44.
9. van Buchem MA, Wondergem JH, Kool LJ, te Velde J, Kluin PM, Bode PJ, et al. Pulmonary leukostasis: a radiologic–pathologic study. *Radiology* 1987; 165:739-41.
10. Lichtman MA. Rheology of leukocytes, leukocyte suspension, and blood in leukemia; possible relationship to clinical manifestations. *J Clin Invest* 1973; 52:350-8.
11. Jacobs HS, Craddock PR, Hammerschmidt DE, Muldow CF. Complement-induced granulocyte aggregation — an unsuspected mechanism of disease. *N Engl J Med* 1980;302:789-94.
12. Marti GE, Folks T, Longo DL, Klein H. Therapeutic cytapheresis in chronic lymphocytic leukemia. *J Clin Apheresis* 1983;1:243-8.

**Reprint requests to:** Dr. Thomas W. Wilson, Room A120, Health Sciences Building, 107 Wiggins Rd., Saskatoon SK S7N 5E5; fax 306 966-6220; wilson@duke.usask.ca