

Anatomy of the rectum and anal canal of the rhesus monkey (*Macaca mulatta*)

INDAR JIT*

*Department of Anatomy, Postgraduate Institute of Medical Education and
Research, Chandigarh, India*

(Accepted 1 December 1973)

INTRODUCTION

Literature dealing with the anatomy of the rectum and anal canal of the rhesus monkey is scanty. Lineback (1961) gave a short description of the gross anatomy. He described two well marked folds at the upper end of the rectum, one on either side, the first on the left and the other a little lower down on the right. He made no mention of the valves of Houston, or the presence of valves and sinuses, in the anal canal. According to Baur (1860) the valves of Houston are peculiar to man. The presence of anal glands has been recorded in 5 out of 10 monkeys by Kratzer & Dockerty (1947). Jit (1961) could not find either the valves of Houston or the anal valves and sinuses in 3 rhesus monkeys which he dissected.

As published accounts of the gross anatomy of the rectum and anal canal in the rhesus monkey are so inadequate, and as there is very little information available about the histological structure of the anal canal and its sphincters, it was decided to study these features in some detail.

MATERIAL AND METHOD

The large gut, including the rectum and the anal canal, was exposed in 15 rhesus monkeys, by opening the abdominal cavity, and examined *in situ*. In addition, the anal canal and rectum, with a small caudal portion of the pelvic colon, were dissected out in 80 monkeys. After examining this segment of the gut externally, it was opened from behind vertically, spread flat and fixed on a glass plate. The internal aspect of the rectum and anal canal was then examined under the dissecting microscope, with particular reference to the presence or absence of valves of Houston, anal valves, rectal columns and a pectinate line.

The specimens were then fixed in 10% formalin and photographed. After fixation, rectangular blocks of tissue about 2×0.5 cm were cut out for sectioning in 25 animals. Care was taken that the block included the hairy skin margin, anal valves (if present), anal pits, and a length of the rectum. Serial sections of the block were then cut at $15 \mu\text{m}$ and stained. If anal glands were not seen in sections cut from one block, other blocks were cut from the same anal canal.

* Supported by a grant from the Indian Council of Medical Research during the years 1971–73.

Staining methods included haematoxylin and eosin, Masson's trichrome method, Verhoeff's and van Gieson's stains, the Gomori hexamine method for enterochromaffin cells, PAS, and Southgate's mucicarmin method.

OBSERVATIONS

Gross anatomy

The large gut is about 100 cm long and can be divided, as in man, into caecum, ascending colon, transverse colon, descending colon, pelvic colon, rectum and anal canal. Based on measurements taken in 15 monkeys, lengths were as follows: caecum 4-9 cm (average 6.5 cm), ascending colon 6-11 cm (average 9 cm), transverse colon 15-67 cm (average 33 cm), descending colon 10-45 cm (average 25 cm), pelvic colon 4-27 cm (average 16 cm) and rectum including the anal canal 5.5-7.5 cm (average 6.5 cm). The caecum is cone-shaped and bears three distinct taeniae, as in the ascending colon. The taeniae are seen separately on the upper three-quarters of the caecum but towards its lower conical end they merge together. This lower portion where the taeniae have merged corresponds to the human vermiform appendix. The ileocaecal valve and frenula are similar to those described in man. The entire large gut, except the rectum, has a mesocolon. The three taeniae, clearly visible in the pelvic colon, spread out and merge together to form a continuous muscular layer in the rectum.

Rectum (Figs. 1-2)

The rectum begins in front of the 3rd or 4th caudal vertebra, and is 4-6 cm long. Keeping to the middle line, it descends first downwards, and then downwards and forwards, until it passes through the levator ani muscle, where it bends downwards and backwards into the anal canal which terminates at the anus. This bend constitutes the perineal flexure of the rectum. The rectum has been found to be devoid of lateral curves, and the valves of Houston are absent.

Fig. 1. The rectum and anal canal *in situ*. The taeniae are seen to spread out on the rectum. Notice the antero-posterior curve of the rectum, perineal flexure, and the anal canal which is directed downwards and a little backwards. $\times \frac{9}{5}$.

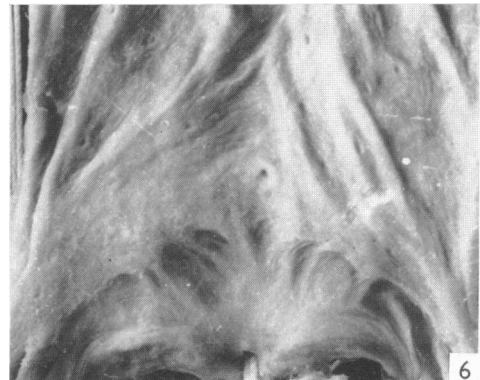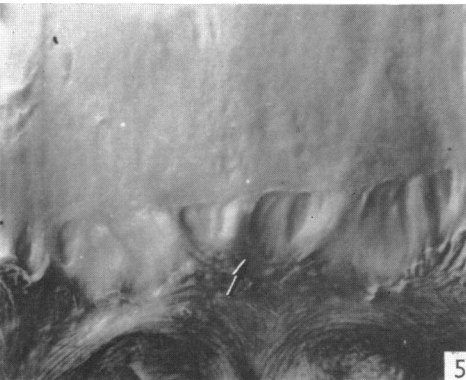
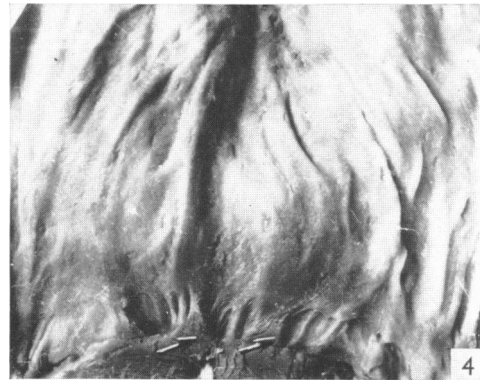
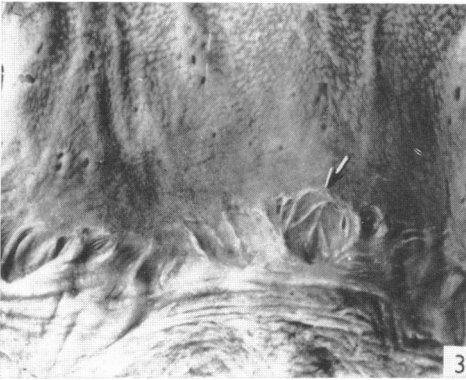
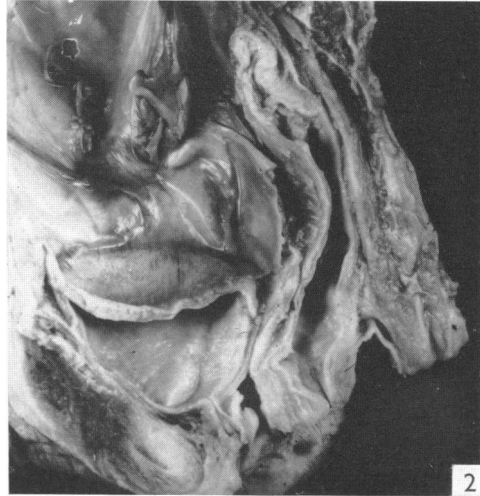
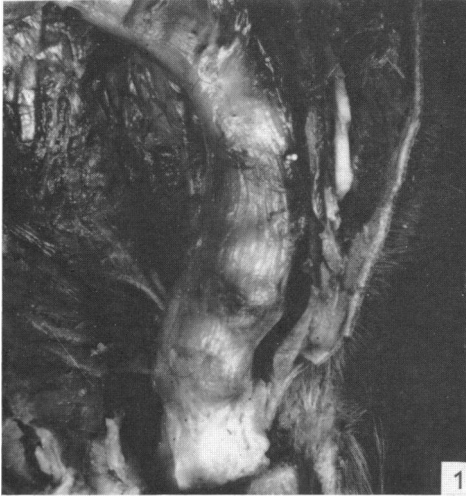Fig. 2. A sagittal section of the pelvis showing the antero-posterior curve of the rectum, perineal flexure, and the anal canal directed downwards and backwards. Lateral curves are absent. $\times \frac{1}{2}$.

Fig. 3. Internal aspect of the anal canal and lower part of the rectum of a monkey showing superficial pits, or depressions, in the middle third of the anal canal. The pits are irregular in shape. A large pit (indicated by an arrow) is seen to be divided into the smaller areas by vertical and oblique ridges. $\times 2$.

Fig. 4. Internal aspect of the anal canal and lower part of the rectum of a monkey. Apart from the pits seen in the middle third of the anal canal, two rudimentary valves (indicated by arrows) are also visible. A pectinate line at the lower margin of the pits is also visible. $\times 2$.

Fig. 5. Anal pits are present in the middle third of the anal canal. A rudimentary anal valve is also visible (indicated by an arrow). A pectinate line is seen at the upper margin of the pits. $\times 2$.

Fig. 6. Inverted valves in the middle third of the anal canal. A pectinate line is visible along the upper margin of the pits. $\times 2$.



Anal canal (Figs. 2–6)

The anal canal is about 1.5 cm in length. Its middle 0.5 cm contains anal pits.

Anal pits (Figs. 3–6)

In the middle third of the anal canal there are some superficial pits or depressions which are irregular, oval or rectangular in shape. The mucous membrane in between the pits is raised into vertical columns which extend for a short distance into the rectum. The total number of pits seen in each anal canal varies from 4 to 12. The depth of the pits cannot be measured as they are quite shallow but their size varies from 3×2 mm to 5×5 mm. Quite often, larger pits are divided into smaller areas by folds of mucous membrane, which may be vertical or oblique (Fig. 3). The distance between the hair line and the lower margin of the pits varies from 3 to 6 mm, the average being 5 mm.

Anal valves (Figs. 4–5)

As a rule anal valves are absent. However, in 4 instances, one or two rudimentary anal valves at the lower margins of the anal pits have been seen, and there are anal sinuses 1–2 mm deep.

Inverted valves (Fig. 6)

Some pits show an inverted valvular appearance with folds of mucous membrane overhanging the pits at their upper margins. No such case has been observed by the author in human anal canals (Jit, 1974).

Pectinate line

As a rule there are no valves, and so the question of the existence of a pectinate line does not arise. However, in some specimens, the lower margins of the pits gives the appearance of a pectinate line (Fig. 4), while in others the upper margins of the pits form a distinct pectinate line (Figs. 5–6).

*Microscopic structure**Rectum*

The structure of the rectum of the rhesus monkey is similar to that of the human rectum. Crypts of Lieberkühn are deep, and have goblet cells in abundance. Typical argentaffin cells are also seen, and their number progressively decreases caudally. The two layers of muscularis mucosae are evident throughout the rectum and the upper part of the anal canal. The mucous membrane and submucosa are infiltrated with lymphoid tissue, including lymph follicles. There are no valves of Houston (*plicae transversales recti*).

Anal canal

Internal anal sphincter (Figs. 7, 10). The caudal 7.5 mm or so of the circular muscle coat of the anal canal gradually thickens to constitute the internal anal sphincter, the lower 5 mm of which has an almost continuous thickness of 1.5 mm, which is 3–4 times the thickness of the circular muscle coat more cranially. The sphincter

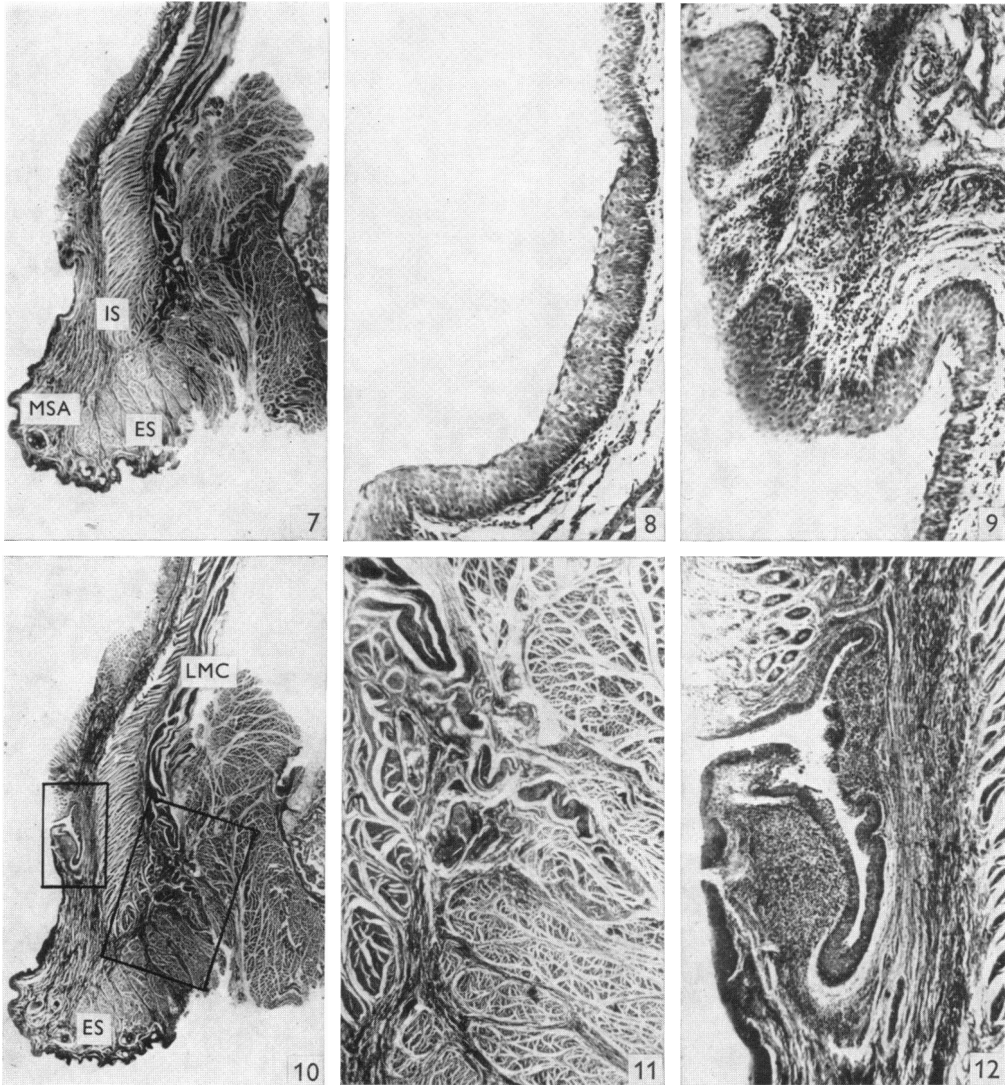


Fig. 7. A coronal section of the lower part of the rectum and anal canal of a monkey showing the internal sphincter (IS) and external sphincter (ES). An anal pit with overhanging upper margin is also visible. Darkly stained muscle fibres are seen in the submucosa caudal to the anal pit constituting muscularis submucosae ani (MSA). $\times 5.4$.

Fig. 8. Shows the mucous lining of the lower part of the pit seen in Fig. 7. Notice that the pit is lined by stratified squamous epithelium. $\times 80$.

Fig. 9. Shows the mucous lining of the upper part of the pit. Notice that a layer of stratified squamous epithelium lines both faces of the overhanging upper margin of the pit. $\times 75$.

Fig. 10. A coronal section of the lower part of the rectum and anal canal of a monkey. A branched anal duct is seen to extend from the anal pit into the submucosa. An extension from the lower end of the longitudinal muscle coat (LMC) of the anal canal is seen to pass through the external sphincter (ES) towards the corium. $\times 5.4$.

Fig. 11. Higher magnification of the field included in the larger inset in Fig. 10 showing muscular extensions from the longitudinal muscle coat passing through the external sphincter towards the corium. $\times 18$.

Fig. 12. Higher magnification of the field included in the smaller inset in Fig. 10 showing a branched anal duct extending from the pit into the submucosa. A concentration of lymphoid tissue is seen round the duct. $\times 32$.

terminates below in a rounded margin. The internal anal sphincter begins comparatively higher up than in man, so far as its relationship with the rectal type of mucous membrane is concerned. At the level of the upper portion of the sphincter, the mucous membrane contains columnar epithelium, crypts of Lieberkühn and lymph follicles.

Longitudinal muscle coat (Fig. 10). About the level of the junction of the upper two-thirds and lower third of the internal sphincter many fibres of the longitudinal muscle coat are replaced by elastic and collagen fibrous septa which, along with some muscular extensions (Fig. 11), pass caudally through the external sphincter and reach the subcutaneous tissue and corium of the peri-anal skin. Such extended muscle fibres seem to be more numerous in the monkey than in man, and the elastic fibres are proportionately decreased. There is no 'anal intermuscular septum' between the caudal end of the internal sphincter, and the lowest (subcutaneous) part of the external sphincter.

External sphincter (Figs. 7, 10). As in man, the anal canal is surrounded by an external anal sphincter continuous cranially with the levator ani. This sphincter, formed by striated muscle fibres, cannot be delineated into the constituent parts described in man: in the monkey it is one continuous muscle.

Mucous membrane (Figs. 7-10, 12). Caudally, the mucous membrane shows a stratified squamous epithelium of 10-15 layers, with a keratinized superficial layer. This type of epithelium lines the lower third of the anal canal up to the level of the lower end of the internal anal sphincter, where the keratinized layer disappears, but stratified squamous epithelium continues. The latter lines the entire pit, including its upper undermined portion and both faces of the inverted valve (if present), and then extends cranially for a short distance until it is replaced by the rectal type of mucosa. The number of layers in the stratified squamous epithelium in the pit (Fig. 8) and outer face of the valve is 8-9, which again progressively increases to 10-15 on the inner face (towards the lumen) of the valve and a little cranially (Fig. 9). Higher up in the anal canal the number of layers is gradually reduced and ultimately a single layer of columnar epithelium with crypts of Lieberkühn and lymph follicles is seen. An occasional argentaffin cell is also seen in the crypts of Lieberkühn.

Anal ducts (Figs. 10, 12). From the anal pits, tubular ducts, which may or may not branch, extend into the submucosa. The number and direction of branches are variable. None of the ducts or their branches are seen to pass through the internal anal sphincter. At their mouths, the ducts are lined by several layers of stratified squamous epithelium, but in their deeper parts the epithelium is transitional. Staining with mucicarmine and PAS shows that they are devoid of any mucus-secreting cells. No acini are seen. There is a concentration of lymphoid tissue surrounding the ducts.

Muscularis submucosae ani (Figs. 7, 10). Distinct plain muscle fibres are seen in the submucosa of the anal canal. Some of these pass caudally through the external sphincter, while proximally they are continuous with the muscularis mucosae of the rectum.

DISCUSSION

Although the existence of transverse folds in the human rectum was mentioned by Morgagni (1729), it was Houston (1830) who gave a fuller description of these folds, which are named after him. A detailed description of their structure and development has been given by Jit (1961). Houston considered them to be a remnant of a spiral fold of mucous membrane in the lower portion of the large gut of the serpent and dogfish, giving the alimentary matter a protracted winding course towards the anus. His view was supported by Vance (1878).

If this view is correct, the valves should be present in animals generally, including the rhesus monkey, but in fact it would appear that the valves of Houston are peculiar to man, and perhaps appeared with the attainment of the upright posture (Baur, 1860).

The structure of the rectum is similar to that seen in man. Deep crypts of Lieberkühn, typical argentaffin cells, abundant goblet cells, two layers of muscularis mucosae, and a concentration of lymphoid tissue, can all be recognized in the rectal wall.

According to Lineback (1961) a well marked internal sphincter is present in the rhesus monkey at the inner end of the anal canal as a thickening of the circular muscle coat, although he does not describe its extent or thickness. In the present investigation it is shown that the caudal 7.5 mm or so of the circular muscle coat gradually thickens to constitute the sphincter, which is 3–4 times the thickness of the circular coat more cranially.

Herrmann & Defosses (1880) and Herrmann (1880) described irregular tubular glands in the wall of the human anal canal, extending from the anal sinuses into the submucosa, and even piercing the internal anal sphincter. Their presence and structure in man have been described by a number of workers, including Johnson (1914), Tucker & Hellwig (1934), Morgan (1936), Krafka (1940) and Kratzer & Dockerty (1947). These glands have also been described in the dog by Herrmann (1880), Hebrant (1899) and Tucker & Hellwig (1934), in the skunk by Blackman (1911), and in the rabbit, guinea-pig and cat by Tucker & Hellwig (1934). Kratzer & Dockerty (1947) examined histologically the anal canals of 10 monkeys, and were able to locate the anal ducts lined by 4 or 5 layers of transitional epithelium in 5 animals. Although they did not find any acini, mucicarmine gave a positive reaction in 'isolated regions of each duct'. As regards the existence of these ducts in the monkey the present findings confirm the work of Kratzer & Dockerty (1947). However, staining with PAS and mucicarmine has failed to detect any mucus secreting cells in the ducts. Therefore, it appears that in the monkey these ducts are functionless. Contrary to the findings of Kratzer & Dockerty (1947), the ducts do not pierce the 'surrounding muscle' i.e. the internal sphincter.

Human anal valves are usually believed to be the remnants of the anal membrane which divided the ectodermal proctodeum from the entodermal hind gut. This view, however, is not supported by the work of Johnson (1914) and Tench (1936). The anal valves do not seem to have been described in other mammals, and in the present study they have been found absent in the monkey. One or two rudimentary anal valves, seen only in 4 instances, do not seem to be of any significance. If such valves are remnants of the anal membrane, there seems to be no reason why they should

not be present in the monkey and other mammals. One is therefore inclined to believe that these valves are peculiar to man, and perhaps appear with the evolution of an upright posture.

Although the presence of plain muscle fibres in the submucosa, constituting a muscularis submucosae ani, has been described in the region of the pecten of the human anal canal (Fine & Lawes, 1940; Wilde, 1948; Jit, 1974), this has not been recorded in any other mammal. The present work shows that plain muscle fibres are present in the submucosa of the anal canal of the rhesus monkey, and are continuous cranially with the definitive muscularis mucosae.

SUMMARY

The gross anatomy of the rectum and anal canal of the rhesus monkey has been studied in 95 animals. The rectum is devoid of the valves of Houston. The middle portion of the anal canal shows 4–12 shallow pits which are irregular in shape and size. As a rule, anal valves are absent but occasionally a rudimentary valve may be seen. A histological study of longitudinal sections of the anal canal and lower rectum in 25 specimens shows the existence of internal and external anal sphincters akin to those seen in man. The lower portion of the longitudinal muscle coat is largely replaced by elastic and collagen fibres which, along with some muscular extensions, pass caudally through the submucous part of the external sphincter to reach the corium of the peri-anal skin. As in man, the external sphincter is formed by striated muscle fibres, but is not delineated into subcutaneous, superficial and deep parts. Branched anal glands, similar to those seen in man, extend from the pits into the submucosa. A muscularis submucosae ani is also present. The epithelium lining the anal canal changes from the keratinizing to the non-keratinizing form of stratified squamous epithelium, and then to single columnar, as one reviews the canal from below upwards.

REFERENCES

- BAUR, H. (1860). Ueber die Falten des Mastdarms. *Beiträge zur Anatomie und Physiologie* 2, Zweiter Teil, 1–38.
- BLACKMAN, M. W. (1911). The anal glands of *Mephitis mephitis*. *Anatomical Record* 5, 491–504.
- FINE, J. & LAWES, C. H. W. (1940). On the muscle-fibres of the anal submucosa with special reference to the pecten band. *British Journal of Surgery* 27, 723–727.
- HEBRANT, G. (1899). Sur les glandes anales du chien, anatomie, physiologie, pathologie. *Annales de médecine vétérinaire* 48, 633–641.
- HERRMANN, G. (1880). Sur la structure et le développement de la muqueuse anale. *Journal de l'anatomie et de la physiologie normales et pathologiques de l'homme et des animaux* 16, 434–472.
- HERRMANN, G. & DEFOSSES, L. (1880). Sur la muqueuse de la région cloacale du rectum. *Comptes rendus hebdomadaires des séances de l'Académie des sciences (Paris)* 90, 1301–1302.
- HOUSTON, J. (1830). Observations on the mucous membrane of the rectum. *Dublin Hospital Reports* 5, 158–164.
- JIT, I. (1961). The structure and development of the valves of Houston. *Indian Journal of Medical Research* 49, 635–647.
- JIT, I. (1974). Structure and development of the human anal sphincters. *In preparation*.
- JOHNSON, F. P. (1914). The development of the rectum in human embryo, *American Journal of Anatomy* 16, 1–57.
- KRAFKA, J., JR. (1940). The creeping epithelium of the anal canal. *American Journal of Surgery* 49, 42–48.
- KRATZER, G. L. & DOCKERTY, M. B. (1947). Histopathology of anal ducts. *Surgery, Gynecology and Obstetrics* 84, 333–338.

- LINEBACK, P. (1961). In *The Anatomy of the Rhesus Monkey* (Ed. C. G. Hartman and W. L. Straus, Jr), pp. 221–223. New York: Hafner.
- MORGAGNI, J. B. (1729). *Adversaria Anatomica* III, 6, Batavia.
- MORGAN, C. N. (1936). The surgical anatomy of the anal canal and rectum. *Post-Graduate Medical Journal* **12**, 287–300.
- TENCH, E. M. (1936). Development of the anus in the human embryo. *American Journal of Anatomy* **59**, 333–345.
- TUCKER, C. C. & HELLWIG, C. A. (1934). Histopathology of anal crypts. *Surgery, Gynecology and Obstetrics* **58**, 145–149.
- VANCE, R. A. (1878). Rudimentary structures in the human rectum. Spiral folds and valvular projections of its mucous membrane. *Medical and Surgical Reporter* **38**, 203–205.
- WILDE, F. R. (1948). The anal intermuscular septum. *British Journal of Surgery* **36**, 279–285.