

Carpometacarpal joint of the human thumb

K. KUCZYNSKI

Department of Anatomy, University of Edinburgh

(Accepted 25 March 1974)

INTRODUCTION

Despite much interest in human thumb movements there is no agreement regarding their terminology or mechanics (for review see Gedda, 1954; Pieron, 1973 and recent French papers: Kapandji, 1972; Duparc, Caffinière & Pineau, 1971). Possibly the position would be clarified if the three joints of the thumb were treated as a functional unit, for there is considerable variation in the contribution which each joint makes to the total movement in different subjects. However, it is beyond question that better understanding of the mechanism of thumb movements requires careful attention to the configurations of the articular surfaces involved. It was therefore decided to begin such an investigation with a detailed examination of the articular surfaces of the human carpometacarpal joint.

MATERIALS

The articulated dry skeletons of 15 hands were examined by inspection and palpation. Two fresh amputation specimens were used for arthrography and for examination of the capsule and cartilage-covered articular surfaces.

OBSERVATIONS

Not all the features described below were developed to an equal degree in every specimen: in some cases the features were marked, in others just discernible.

Trapezial surface of carpometacarpal joint

In surface view this articular area on the dried bone presents a ridge running anterolaterally from the base of the second metacarpal bone (Fig. 1). This ridge, which is concave in its long axis, lies at an angle to the greatest diameter of this surface of the trapezium. It is also slightly curved, with an anteromedial convexity. The ridge is quite pronounced near the base of the second metacarpal, but becomes progressively flatter in a radial direction (Fig. 2). Posteromedially there is an oval, slightly concave extension of the articular surface (marked by A in Fig. 2) the edge of which may be slightly raised posteriorly. Transverse to the ridge is a curved groove (shown in Fig. 3). It can be seen that an object (shown as ▽ in Fig. 3) sliding in the groove would rotate by about 90° in the course of its entire traverse (in some specimens this angle is even greater). At its anteromedial end the groove widens into a small depression (marked by B in Figs. 1 and 2) which is more or less parallel to the

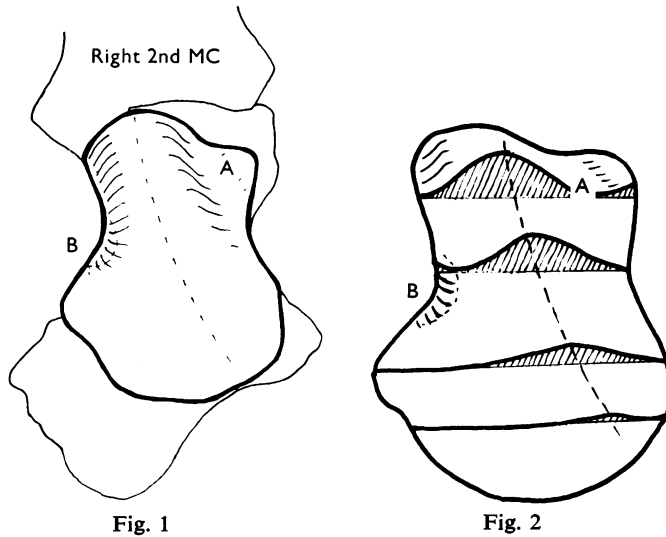


Fig. 1

Fig. 2

For explanation of A, A', B and B' see text.

Fig. 1. Surface view of the trapezium articular area of the carpometacarpal joint of the thumb.

Fig. 2. Notches cut into the trapezium surface to show the profiles of its configuration.

slightly elevated articular margin (profile of the notch in Fig. 2). The part of the trapezium surface anterolateral to the groove (i.e. farthest from the base of the second metacarpal) is larger than the posteromedial part. It is also very much flatter and its anterolateral margin is more or less parallel to the direction of the main groove.

Metacarpal surface

In surface view, the metacarpal articular surface on the dry bone shows many features which approximately match the configuration of the trapezium surface (Fig. 4). In general the posteromedial part of the surface is more concave than the anterolateral part which corresponds to the flatter anterolateral part of the trapezium surface.

There are, however, important differences between the two surfaces.

1. The groove of the metacarpal surface, which corresponds to the ridge of the trapezium surface, is longer but has the same general direction as the ridge. However, the radius of curvature in the plane of the ridge is less in the metacarpal than in the trapezium (Fig. 5a). The greater length is due to extension of the articular cartilage on to the anterolateral and posteromedial aspects of the base of the first metacarpal (Fig. 5b).

2. When the articular surfaces of the trapezium and the first metacarpal are accurately coaptated in such way as to fit edge to edge on the anterolateral aspect, the posteromedial side of the joint opens (interval 3 mm) with the first metacarpal surface projecting farther than the trapezium surface by 3–4 mm (Fig. 6a). Thus in abduction the most convex part of the ridge of the trapezium surface is withdrawn from the most concave part of the groove on the first metacarpal and the flatter anterolateral surfaces are in contact, thus allowing rotatory movement. In life the

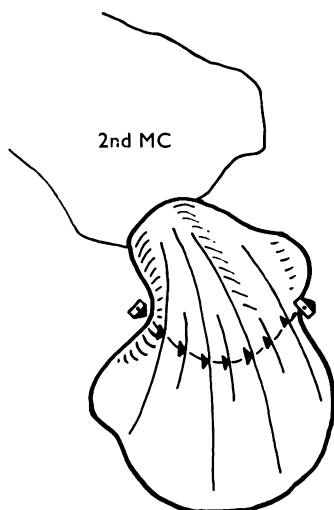


Fig. 3

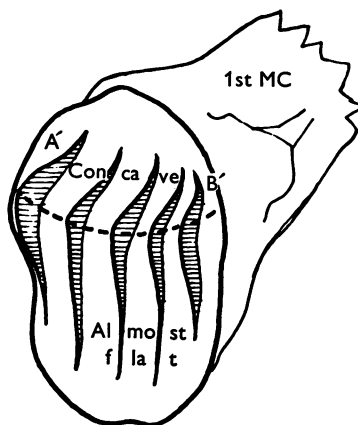


Fig. 4

Fig. 3. Curved groove across the trapezium surface. The line joining the triangles represents the maximal concavity of the groove.

Fig. 4. Configuration of the metacarpal surface of the carpometacarpal joint of the thumb; notches cut into the surface to show the profiles. The interrupted line represents the ridge of the metacarpal surface.

interval on the posteromedial side is presumably filled with synovial folds (usually one on each side of the ridge) while the flatter, anterolateral parts of the trapezium and metacarpal surfaces are sliding on each other.

3. In the adducted position (Fig. 6*b*) the deepest part of the concavity of the first metacarpal fits closely over the maximum convexity of the ridge of the trapezium, while the interval between the flatter surfaces on the anterolateral side of the joint is then presumably filled with a synovial fold. In full adduction the posteromedial surfaces of the first metacarpal and trapezium are in close contact and the range of movement between these surfaces is strictly limited.

4. The relatively flat part of the metacarpal surface is not as wide as the corresponding part of its trapezium partner (arrows, Fig. 7).

The movements of the metacarpal surface on the trapezium

Figure 8 shows the capsule of the carpometacarpal joint of the thumb divided, except posterolaterally, and the first metacarpal dislocated to show the two surfaces of the joint side by side. It can be seen that the concave area of the posteromedial part of the metacarpal surface fits over the most prominent part of the trapezium ridge, while the curved ridge of the metacarpal surface (shown by the interrupted line in Fig. 4) corresponds to the curved, transverse groove on the trapezium. At the same time the convexity A' of the metacarpal surface (see also Figs. 4 and 5*b*) fits into the concavity A of the trapezium. The most posteromedial part of the curved ridge of the metacarpal surface (B', Figs. 4 and 5*b*) fits into the depression B of the

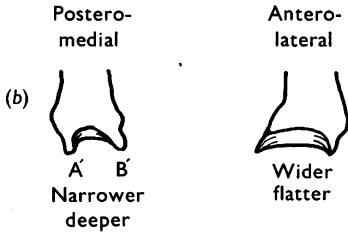
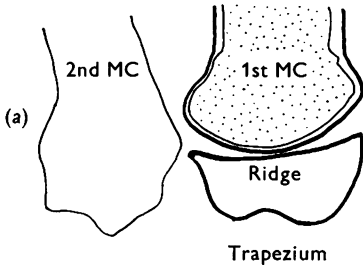


Fig. 5

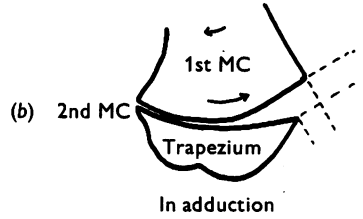
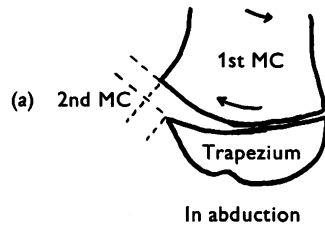


Fig. 6

Fig. 5. (a) Section of the first metacarpal and the trapezium in the plane of the trapezial ridge. (b) Extension of the articular surface on the posteromedial and anterolateral aspects of the base of the first metacarpal.

Fig. 6. (a) In abduction the articular surfaces of the trapezium and the first metacarpal coaptated to fit edge to edge on the anterolateral aspect of the joint. (b) View in adduction.

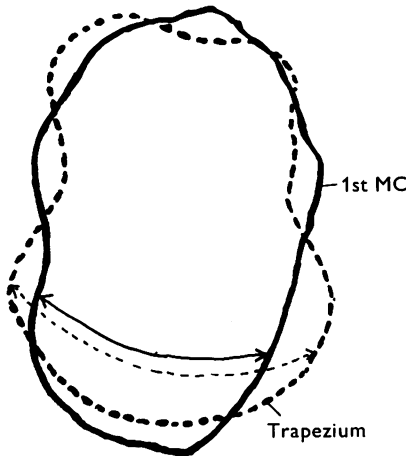


Fig. 7

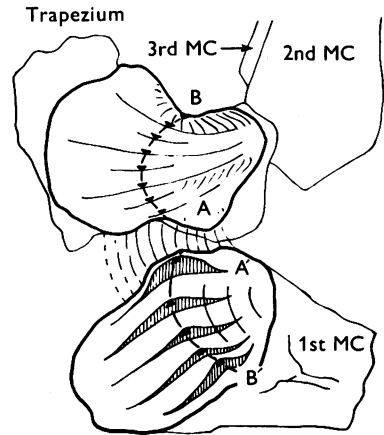


Fig. 8

Fig. 7. Relative width of the anterolateral parts of the trapezial and metacarpal surfaces of the joint.

Fig. 8. The two surfaces of the dislocated joint shown side by side. The lines joining the triangles represent the maximal concavity of the groove of the trapezium and the maximal convexity of the ridge of the metacarpal surface.

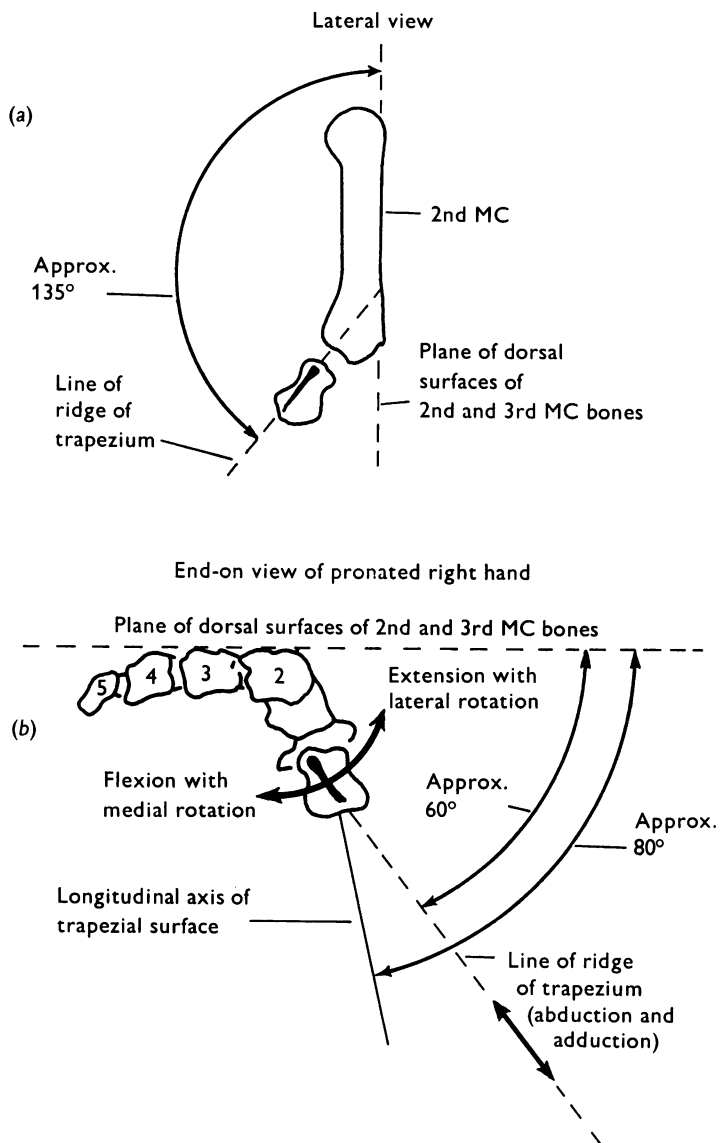


Fig. 9. (a) Direction of the trapezoidal ridge in the lateral view of the hand. (b) End-on view of the pronated right hand showing the paths along which the movements in the carpometacarpal joint take place.

trapezium. The flatter anterolateral part of the metacarpal surface is less extensive and so can slide over the trapezoidal surface following the curvature of the transverse groove on the trapezium. It can be verified again that in abduction and adduction the zone of the metacarpal surface in contact with the trapezium will move along the ridge of the trapezium from the base of the second metacarpal. In abduction the zone of contact moves away and *vice versa* in adduction.

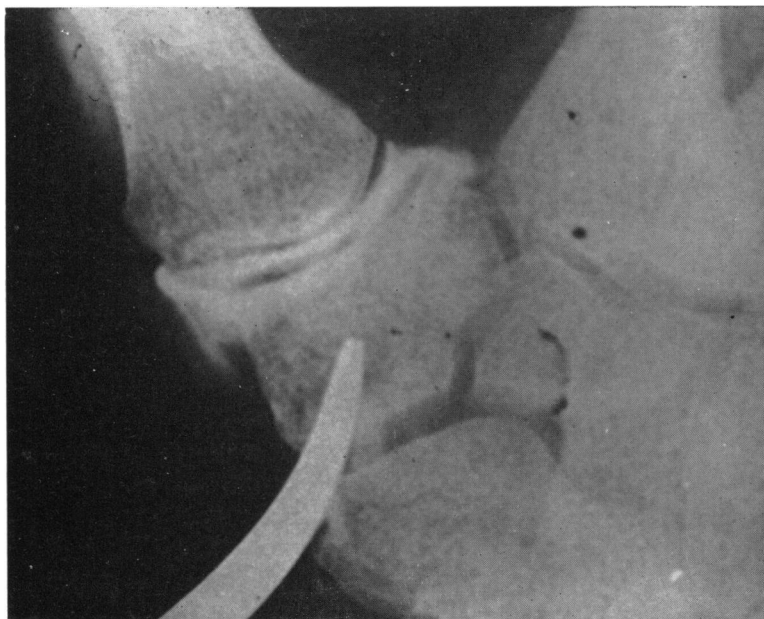


Fig. 10. Arthrogram of fresh amputation specimen showing the carpometacarpal joint of the thumb injected with an opaque medium.

The direction of the longitudinal ridge is from anterolateral proximally to posteromedial distally (Fig. 9). The first metacarpal as a whole cannot be made to be parallel to the combined plane of the dorsal surfaces of the second and third metacarpal bones ('fixed axis of the hand') because it articulates with the anteriorly placed trapezium. On the other hand the *head* of the first metacarpal, at its extremes of movement, can be brought into the plane of the fixed axis of the hand, or into one perpendicular to it; but this is not achieved by simple movement such as flexion or extension, abduction or adduction, but rather by a laboured and contrived combination of movements.

Examination of the fresh amputation specimens

Inspection of the fresh articular surfaces confirms the features described above on the dry specimens.

It is difficult to distend the capsule by injection of the joint with the muscles and tendons *in situ* (this was attempted many times in formalin-fixed material and twice in the fresh amputation specimens). After removal of all muscles and tendons from the region of the carpometacarpal joint of the thumb, however, distension occurs quite easily (Fig. 10). It would appear that coaptation of the articular surfaces in this joint depends to a great extent on the presence of muscles and tendons. There is considerable slack in the capsule and the articular surfaces can be distracted by as much as 3 mm when muscles and tendons are removed.

In fresh specimens there are no definite synovial folds or fringes such as are seen in formalin-fixed specimens, but there is a definite slackness of the synovial lining on coaptation; this lining can be stretched on distraction of the surfaces and produces

a roll-like collar when the distracting force is removed. It seems probable that the folds are not constant or permanent and are formed from the synovial lining where the interval between the articulating surfaces is opened during movement, only to disappear and be formed in another area when the relative positions of the surfaces change.

It is simple to demonstrate that the first metacarpal moves in a curved path parallel to the groove of the trapezoidal surface and that abduction and adduction occurs along the line of the ridge of the trapezoidal surface – the base of the first metacarpal moving towards or away from the base of the second metacarpal.

The first metacarpal was divided transversely at the middle of its shaft and a rigid metal pin was inserted longitudinally through its centre transfixing the trapezium in the mid-position of the joint, i.e. at the meeting point of the ridge and the groove of the trapezoidal surface. This results in the fullest coaptation of the surfaces and excludes all movements of sliding or angulation but leaves the first metacarpal free to rotate on the trapezium around the pin. When the surfaces are pressed together hardly any rotation of the first metacarpal around the pin is possible. As the surfaces are gradually distracted, an increasing amount of rotation up to 20° around the pin is possible. During separation of the surfaces with rotation the capsule becomes gradually twisted and the metacarpal rides up on the ridge of the trapezium.

SUMMARY

Abduction and adduction occur along the ridge of the trapezium in a plane approximately at 60° to the plane of the dorsal surfaces of the second and third metacarpal bones (Fig. 9). During abduction the *head* of the first metacarpal moves in an anterolateral (while the *base* moves in a posteromedial) direction and the opposite occurs in adduction.

In flexion and extension of the abducted first metacarpal, that bone travels along the curved groove of the trapezium (Fig. 9), the axis of movement changing continually. Thus flexion is of *necessity* accompanied by medial rotation of the metacarpal and extension by lateral rotation. In the adducted position these movements of the first metacarpal around its longitudinal axis are very much restricted.

Rotation was shown to occur in the transfixed amputation specimen only when the articular surfaces rode up on each other and the capsule became twisted. It was not possible to assess the role of such rotation and capsule twisting in normal movements of the thumb. It seems probable, however, that in the final stages of extension and associated lateral rotation, the projection A' of the metacarpal surface is arrested by the raised margin of the trapezium posterior to the area A; and further lateral rotation can only occur if the metacarpal rides on the elevated margin of A, a movement which is allowed by the loose capsule. A similar process may take place in the opposite direction when the projection B' of the metacarpal surface rides up from the depression B on the convexity of the ridge of the trapezium, resulting in an additional medial rotation of the first metacarpal.

I am grateful to Professor G. J. Romanes for reading the manuscript and for his valuable comments. I wish to thank Mr T. Patterson for help with the photographic reproductions.

REFERENCES

- DUPARC, J., CAFFINIÈRE, J. Y. DE LA & PINEAU, H. (1971). Approche biomécanique et cotation des mouvements du premier métacarpien. *Revue de chirurgie orthopédique* **57**, 3-12.
- GEDDA, K. O. (1954). Studies of Bennett's fracture. Anatomy, roentgenology and therapy. *Acta chirurgica scandinavica*, Suppl. **193**, 1-114.
- KAPANDJI, I. A. (1972). La rotation du pouce sur axe longitudinal lors l'opposition. Étude géométrique et mécanique de la trapézo-métacarpienne. *Revue de chirurgie orthopédique* **58**, 273-289.
- PIERON, A. P. (1973). The mediamom of the first carpometacarpal joint. An anatomical and mechanical analysis. *Acta orthopaedica scandinavica*, Suppl. **148**, 1-104.