

The development of the olfactory mucosa in the mouse: light microscopy

A. CUSCHIERI* AND L. H. BANNISTER

*Departments of Anatomy and Biology,
Guy's Hospital Medical School, London, SE1, 9RT*

(Accepted 14 August 1974)

INTRODUCTION

It has long been recognized that the primordium of the olfactory organ is the paired olfactory placode which can be distinguished at an early stage of embryonic development as a patch of thickened ectoderm situated on the ventrolateral aspect of the head. Each placode subsequently sinks below the surface to form an olfactory pit. In many vertebrate groups the olfactory organ primordium comes to lie close to the forebrain some time before the olfactory nerve begins to develop and, because of this, some of the earlier investigators assumed a measure of cellular continuity between the organ and the central nervous system (Beard, 1885; Cameron & Milligan, 1914; Frazer, 1953) although this was denied by others (Coghill, 1916; Burr, 1932). The precise origin of the olfactory nerve was also disputed by the early investigators (Balfour, 1877; Marshall, 1878; Beard, 1885; Chiarugi, 1891; Cameron & Milligan, 1914). With superior histological methods, Wilhelm His (1889) and Cajal (1890) demonstrated clearly that the olfactory axons arise from the cells of the placode and grow towards the forebrain. At about the same period of development, Schwann cells, which possibly arise from the placode (Bedford, 1904; Van Campenhout, 1956), appear either before the outgrowth of the axons, as in the chick (Van Campenhout, 1956), or after the axons have emerged, as in mammals (Bedford, 1904; Van Campenhout, 1956).

More recently, a number of brief accounts of the development of the olfactory epithelium have been published by Wesolowski (1970) for the chick, and by Hinds (1972*a, b*), Breiphol (1972), Breiphol, Laugwitz & Bornfeld (1974) and Breiphol, Mestres & Meller (1973) for the mouse. Smart (1971) has also reported the distribution of mitotic figures in the developing olfactory epithelium of mice. The present account is the first of a series of papers on various aspects of the development of the olfactory and vomeronasal epithelia, and is intended to provide a broad outline of the chief events as seen by light microscopy, which will form a frame of reference for more detailed fine structural and histochemical studies.

* Permanent address: Department of Anatomy, Royal University of Malta, Msida, Malta.

MATERIALS AND METHODS

Albino mice of strain SAS, ICI, were used in this investigation. Fetuses were obtained on each day of gestation from the 8th to birth. Animals of 3, 7, 15 and 21 days postnatal age were also used. The fetuses were obtained as a result of nocturnal matings, corroborated by morning inspection for vaginal plugs. Because the precise time of conception was uncertain the day on which a vaginal plug was found was designated as day 0 of gestation. On the appropriate days of gestation pregnant females were killed by cervical dislocation and the fetuses were immediately removed. Neonatal animals were killed by decapitation.

Fetal and young mice were fixed in 10% formalin or in Bouin's fluid for 18 hours. Fetuses aged 8–14 days were fixed whole *in utero* after slitting open the uterine wall. Older fetuses and young animals were decapitated and their heads were immediately immersed in the fixative. After fixation the specimens were transferred to 70% alcohol. Decalcification was required only in postnatal animals and this was carried out in 5.5% disodium ethylene diaminetetracetic acid (EDTA). The specimens were then dehydrated in graded alcohols, cleared in cedar wood oil, embedded in paraffin wax and sectioned at 5–7 μm . Sections were in general stained in haematoxylin and eosin, but some from formalin-fixed tissues were stained by the silver nitrate method of Holmes (1947).

RESULTS

The first stage of development to be examined was that of the 9th day of gestation, when the olfactory placode was recognizable under a dissecting microscope as a circular patch of thickened ectoderm situated on the antero-lateral aspect of the head (Fig. 1). The cells of the placode, in vertical section, appeared to be tall columnar, with oval nuclei, the long axes of which lay perpendicular to the surface. The nuclei were situated at various depths, giving a pseudo-stratified appearance, and formed four or five layers in the thickest central region of the placode, diminishing to a single layer at its periphery, where the placode merged with the surrounding ectoderm (Fig. 2). A wide belt of mesenchyme separated the olfactory placode from the adjacent telencephalon, and the two structures were not in contact at any point.

On the 10th day the olfactory placode had invaginated to form a simple olfactory pit (Fig. 3). The epithelium lining the pit was similar to that of the placode, and merged gradually with the general ectoderm surrounding the external opening. In silver stained preparations prominent cellular processes were clearly visible, extending from the base of the epithelium into the mesenchyme (Fig. 4). It was not possible to follow these processes in serial sections for long distances, and they did not at this stage reach the vicinity of the anterior part of the forebrain, an observation in agreement with that of Hinds (1972*a*). There was at this stage no evidence of an olfactory bulb.

On the 11th day of gestation the olfactory pit was much deeper and had formed secondary recesses. In silver stained sections some epithelial cells showed prominent apical processes resembling dendrites; these extended to the epithelial surface where they ended in irregular swellings (Fig. 5). These dendritic processes were most numerous in the epithelium of the deeper parts of the pit.

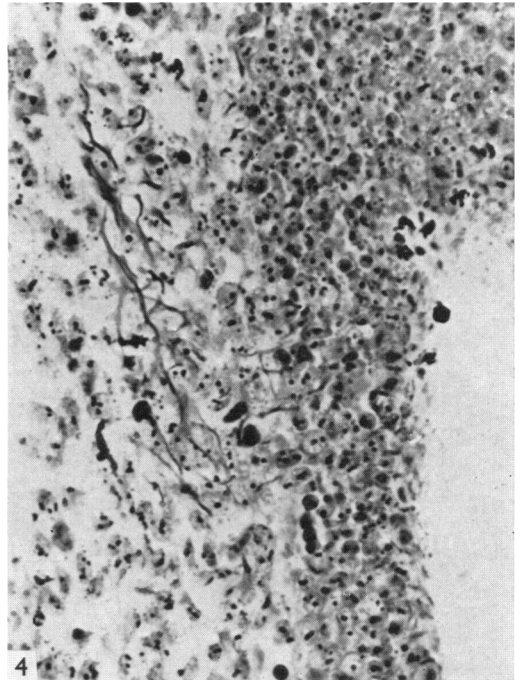
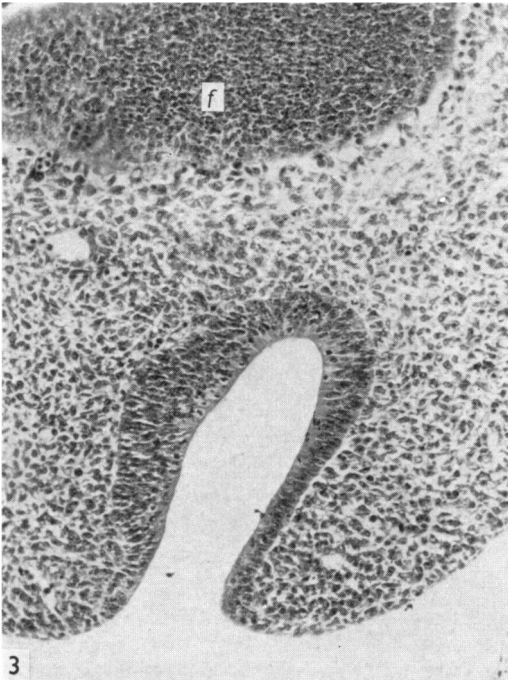
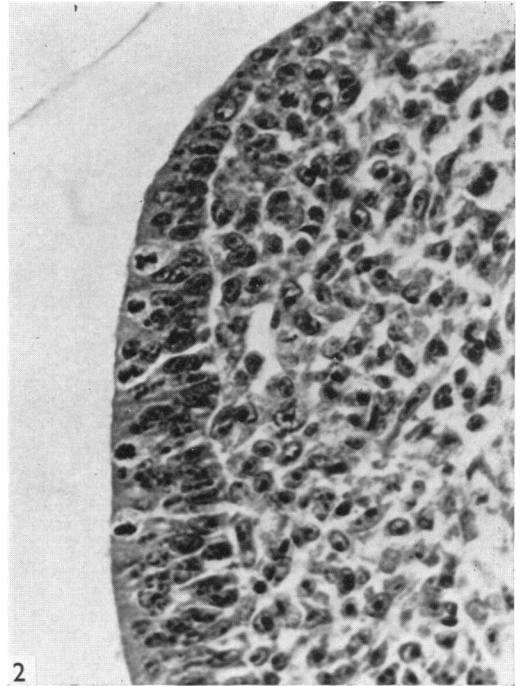
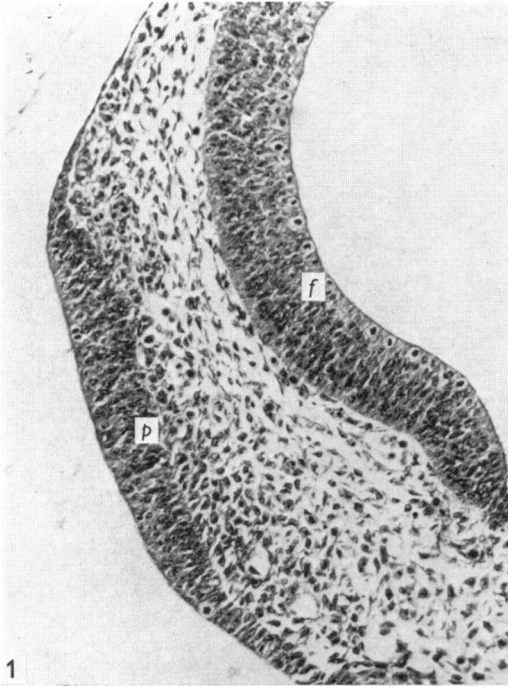


Fig. 1. Coronal section through the head of a 9 day old mouse fetus showing the olfactory placode (*p*) separated from the wall of the forebrain vesicle (*f*) by mesenchyme. H & E; $\times 150$.

Fig. 2. Detail of the junction between the olfactory placode and surrounding ectoderm, at 9 days' gestation. Note the mitotic figures at the surface. H & E; $\times 400$.

Fig. 3. Part of a coronal section through the head of a fetus at 10 days' gestation, showing the olfactory pit and forebrain (*f*); the midline is towards the left. H & E; $\times 130$.

Fig. 4. Part of the olfactory pit at 10 days' gestation showing silver stained axonal processes in the underlying mesenchyme. Holmes' silver; $\times 400$.

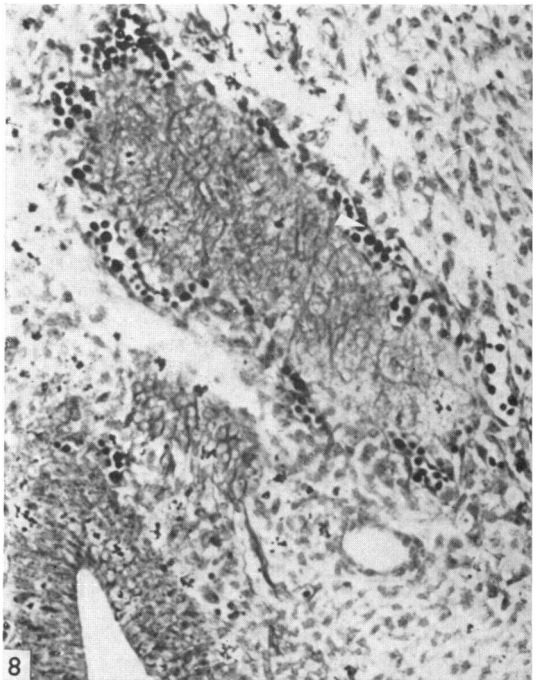
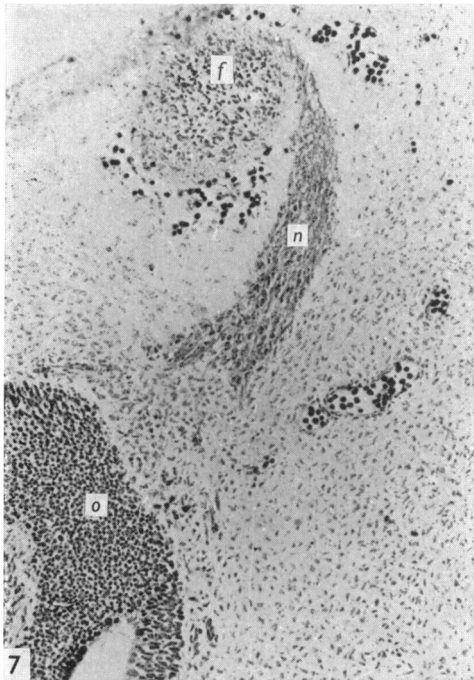
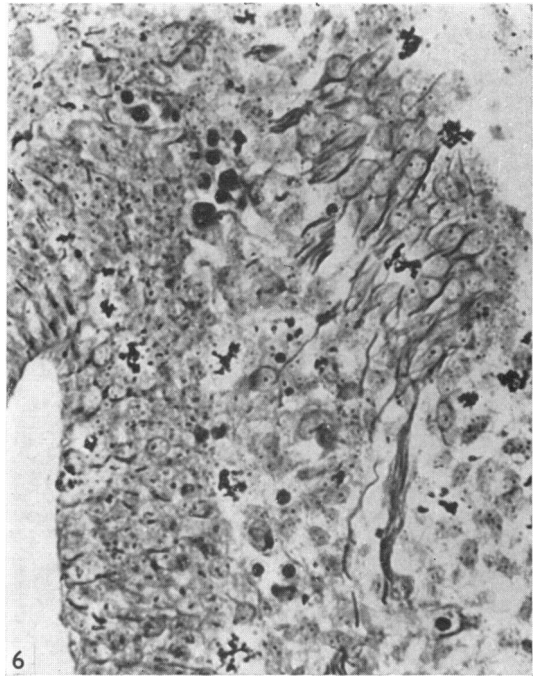
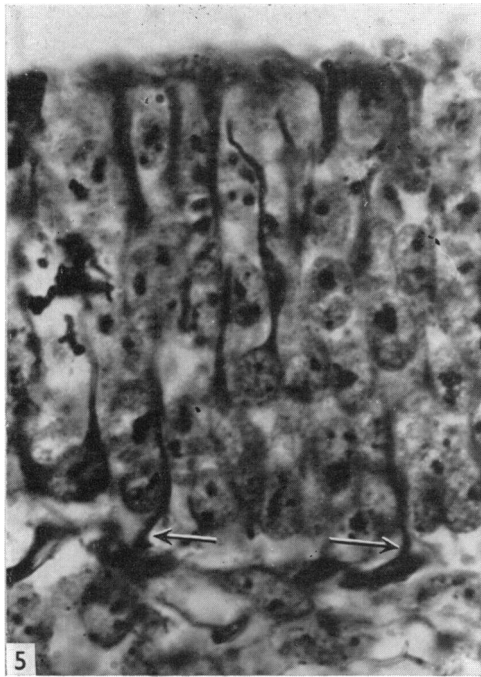


Fig. 5. Olfactory epithelium at 11 days' gestation showing silver stained peripheral processes extending to the surface (above) and central processes extending into the mesenchyme (arrows). Holmes' silver; $\times 900$.

Fig. 6. Silver stained processes accompanied by Schwann cells in the mesenchyme deep to the olfactory epithelium at 11 days' gestation. Holmes' silver; $\times 300$.

Fig. 7. Olfactory nerves (*n*) at 11 days' gestation, extending from the olfactory epithelium (*o*) to the medial aspect of the forebrain (*f*), in a coronal section. Holmes' silver; $\times 100$.

Fig. 8. Silver stained processes within the olfactory vesicle of the forebrain at 11 days' gestation. Holmes' silver; $\times 200$.

At the base of the epithelium the axons of the olfactory nerve were grouped into fasciculi which could be followed into the medial aspect of the anterior forebrain vesicle (Figs. 7, 8). Within the mesenchyme, the fasciculi were associated with prominent cells which showed vesicular, pale nuclei and abundant cytoplasm: these were presumably Schwann cells; they were quite different in appearance from the surrounding mesenchymal cells, which had characteristic oval nuclei (Fig. 6) and sparse cytoplasm.

Also on the 11th day the vomeronasal organ was recognizable as a thickening in the epithelium of the medial wall of the olfactory pit (Fig. 9). By the 12th day this layer had invaginated to form first a groove and then by fusion of the lips of the groove a tubular structure (Fig. 10), opening anteriorly into the main olfactory pit. This diverticulum was lined by thick epithelium similar to that in the olfactory pit. In silver stained preparations nerve fibres could be traced from the base of the vomeronasal epithelium caudally along the margin of the cartilage in the nasal septum. Within the epithelium lining the medial and inferior aspects of the vomeronasal organ dendritic processes terminated at the epithelial surface in small round swellings; this epithelial region subsequently developed into the sensory epithelium of the mature vomeronasal organ, whilst elsewhere the epithelium formed the non-sensory lining.

From the 13th day of gestation onward two types of nuclei were recognizable in the olfactory epithelium (Figs. 12, 13). Nuclei with oval profiles, their long axes perpendicular to the surface, were most abundant in the apical zone of the olfactory epithelium, but some were also present in the basal region. Somewhat paler nuclei, with rounded profiles, occupied the zone situated between these two layers, forming a wide band with a maximum of seven tiers of nuclei. The apical zone of oval nuclei was separated from the surface by a zone of cytoplasm 8–10 μm thick in which mitotic figures were visible. After the 13th day of gestation capillary loops were present in the olfactory epithelium (Fig. 15), but these disappeared soon after birth, remaining longest near the junction with the respiratory epithelium. This loss of vascularity contrasted with the situation in the sensory epithelium of the vomeronasal organ, where intra-epithelial capillaries persisted throughout life.

The distribution of mitotic figures in no way differed from that reported by Smart (1971), being initially (up to 12 days of gestation) restricted to the apical zone of the epithelium (Fig. 9) and subsequently increasing in frequency in the basal and intermediate layers (Fig. 12) as their frequency in the apical layer declined.

After birth mitotic figures were markedly reduced in number so that by 21 days mitotic figures were only rarely observed. In the vomeronasal epithelium a similar pattern of mitotic activity was seen, except that mitoses were distributed initially throughout the thickness of the epithelium, and after birth they were restricted to its boundary with the neighbouring non-sensory epithelium.

The subepithelial glands of Bowman were first observed on the 17th day of gestation in the form of small clumps of cells with large vesicular nuclei growing out of the base of the olfactory epithelium into the underlying mesenchyme (Fig. 16). At this stage the few glands which were visible were short tubular structures, but during the first week after birth they increased rapidly in size and number, and invaded the connective tissue between the olfactory nerve bundles (see also Breiphof, 1972).

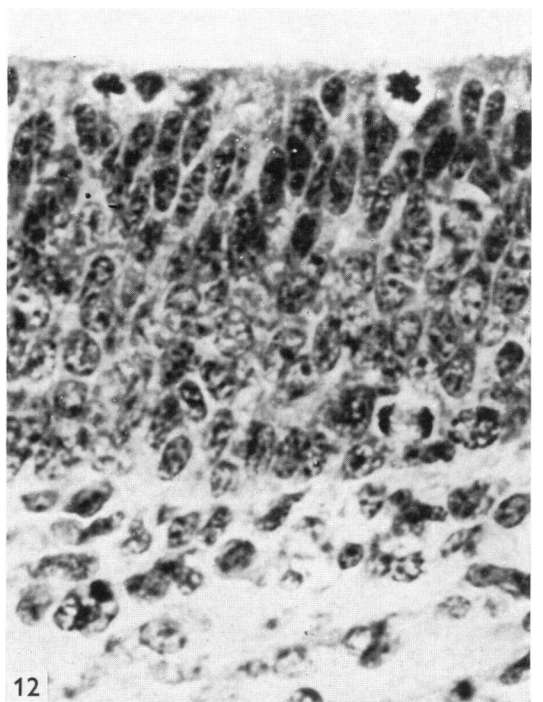
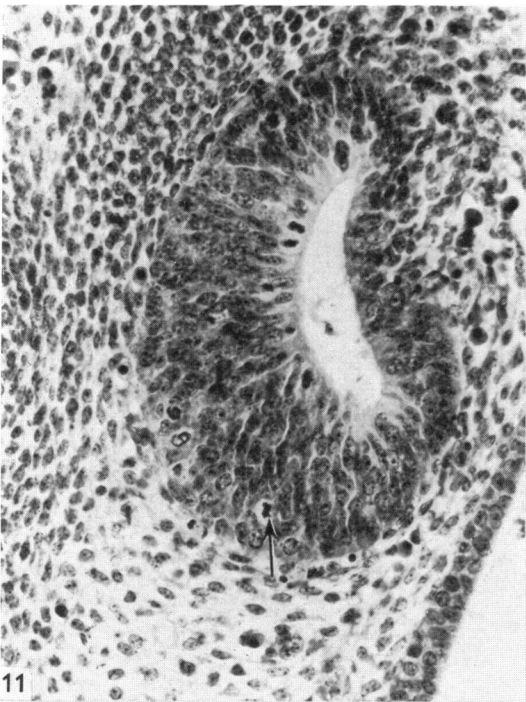
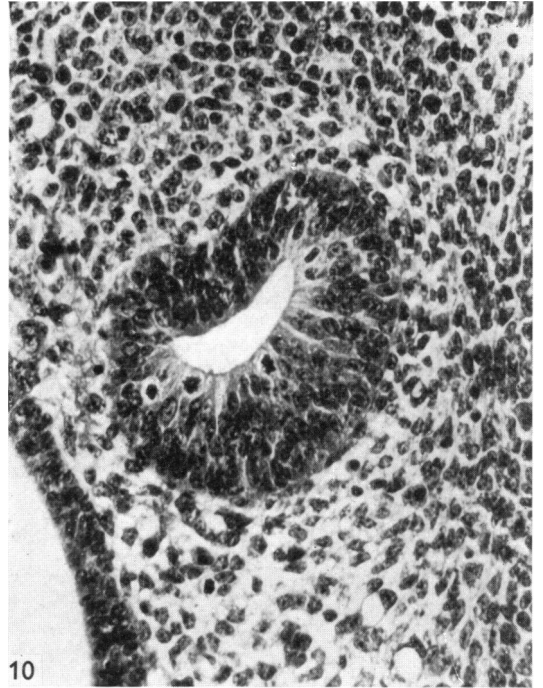
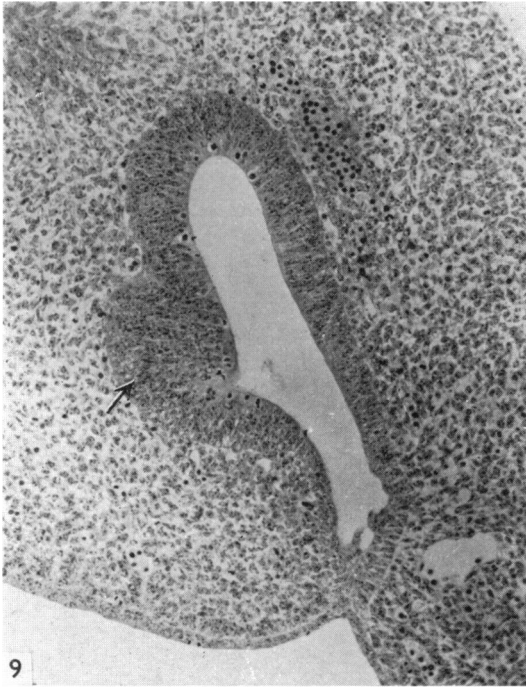


Fig. 9. Olfactory pit in coronal section at 11 days' gestation showing the anlage of the vomeronasal organ as a thickening of the medial wall (arrow). Note mitotic figures at the epithelial surface. H & E; $\times 130$.

Fig. 10. Vomeronasal organ at 12 days' gestation. Note mitotic figures at the surface of the epithelium. H & E; $\times 250$.

Fig. 11. Vomeronasal organ at 13 days' gestation, showing mitotic figures at the surface and also close to the base of the epithelium (arrow). H & E; $\times 200$.

Fig. 12. Olfactory epithelium at 13 days' gestation, showing mitotic figures at the surface and another at the base of the epithelium. Note also the distinction between the elongate, heterochromatic nuclei at the apex and the more rounded and euchromatic ones situated more deeply.

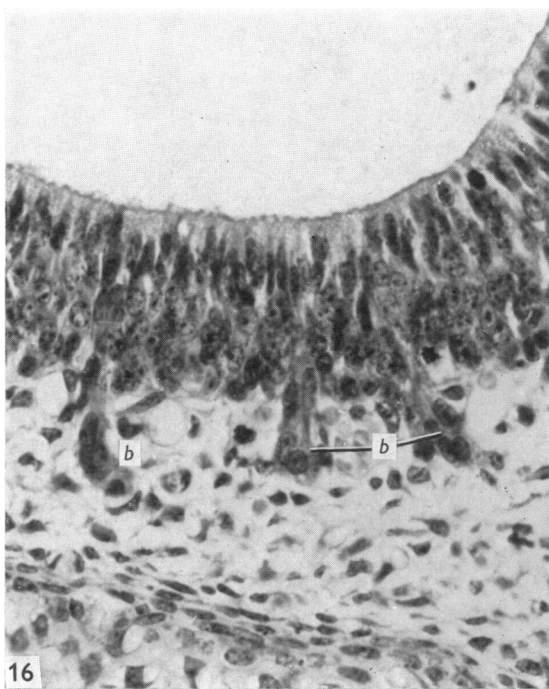
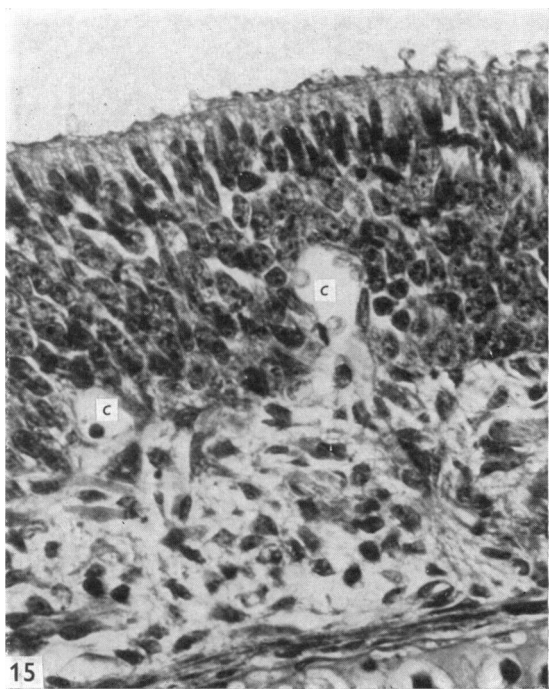
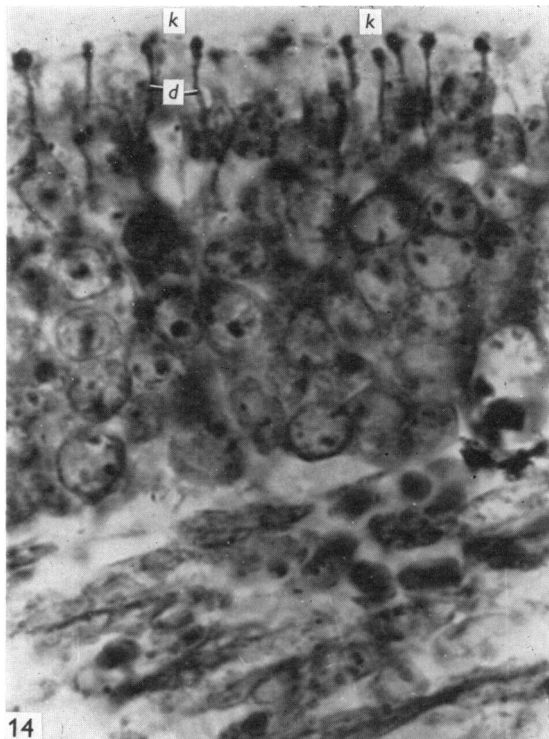
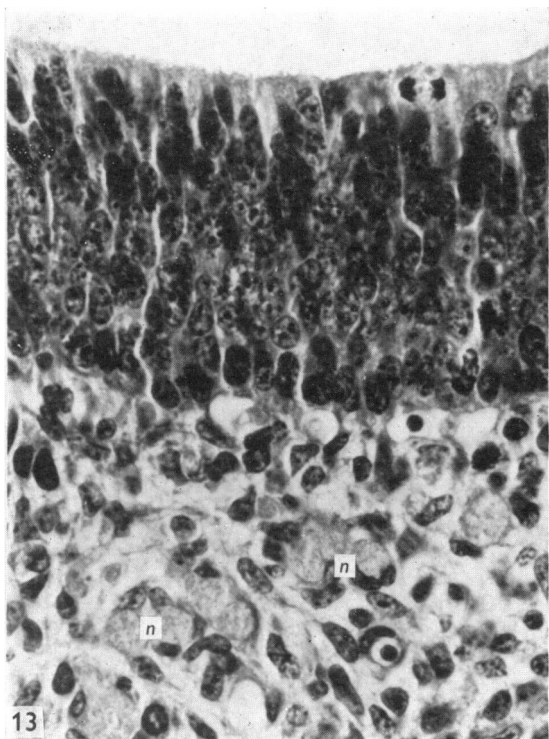
DISCUSSION

From the results reported in this paper it is possible to outline the main events in the development of the olfactory and vomeronasal organs from the 9th day of gestation onwards. The first signs of cellular differentiation within the olfactory placode occur on the 10th day of gestation when fine processes, staining deeply with silver, emerge from the base of the epithelium. Initially these processes, which represent the developing axons of the olfactory nerve, are not accompanied by Schwann cells, these arriving on the 11th day. Next, olfactory dendrites appear in the epithelium (11th day) and at about the same time the central ends of the olfactory axons make contact with the developing olfactory bulb. This timing may be relevant to the suggestion that the differentiation of the receptors is dependent upon contact with the olfactory bulb (Vinnikov & Titova, 1956). It is, however, interesting that Hinds (1972*a, b*) found that, although axons grow into the olfactory bulb on the 11th day of gestation, deep penetration of the bulb only occurs by the 12th day. The signal for dendrite formation may therefore be proximity of the axon to the bulb rather than actual cellular contact between the two.

On the 13th day it is possible to detect differentiation and layering of nuclei within the olfactory epithelium. The rounded nuclei of the developing receptors contrast with the more elongate forms of the embryonic stem cells. It appears that the receptors are formed first in the middle zone of the epithelium, with stem cell nuclei remaining apically and basally. Later, however, the basally situated oval nuclei are no longer visible, and from the 15th day onward the apical layer possesses the appearance and position of the supporting cell nuclei of the fully-formed epithelium. Smart (1971) has shown that in the earlier stages (up to 14 days) the majority of mitoses occur in the apical layer in a manner resembling that of the neural tube (Sauer, 1937), and that later, proliferative activity is transferred to the basal layers, where it continues into postnatal life (Moulton, Celebi & Fink, 1970). It is possible that this transference of cell division is related to the final differentiation of the cells with apical nuclei into supporting cells which have lost the ability to generate new receptors but are, perhaps, still capable of forming additional supporting cells. It is interesting that the basal stem cells, although remaining mitotically active, lose the earlier characteristic form of their nuclei, so that it would be incorrect to assume that the stem cells of the early embryo are entirely comparable with those which carry on receptor cell genesis in later life.

From the results of this study it appears that most of the important features of the mature olfactory epithelium are established by about the 13th day of gestation. This must not, of course, be taken as meaning that the receptors are functional as sensory cells at this stage, or that no more important cytological changes occur in the epithelium. The glands of Bowman, for example, do not begin to emerge from the base of the epithelium until the 17th day, and it is known that various histochemical and cytological events do not occur until shortly before birth (Cuschieri, 1972).

The epithelium is invaded by capillaries on the 15th day, and this may reflect the increasing metabolic demands of the constituent cells as they approach the completion of their maturation. The postnatal retreat of the vasculature to the under-



lying connective tissue may indicate that direct gaseous exchange is now possible between epithelium and atmosphere. In contrast, the mature vomeronasal organ has only a narrow lumen, and connects with the main nasal chamber by a very narrow aperture; its epithelium may therefore be less open to such direct gaseous exchange and it is perhaps significant in this respect that the sensory epithelium of the vomeronasal organ retains its supply of blood throughout life (unpublished observations).

In general the development of the vomeronasal sensory tissue is similar to that of the olfactory organ, except that it begins later. In the more advanced stages the distribution of mitotic activity is more widespread in the epithelium of the vomeronasal organ, and later still, is restricted to its lateral margins. There is no sign of a basal layer of stem cells, and it is interesting that Moulton, Celebi & Fink (1970) report that, unlike the olfactory receptors, vomeronasal receptors are not replaced in mature animals.

SUMMARY

The development of the olfactory and vomeronasal epithelia of the mouse has been investigated from the 9th day of gestation until shortly after birth.

On the 10th day axons emerge from the base of the olfactory epithelium to reach the olfactory bulb primordia on the 11th day, at which time the olfactory dendrites first appear. On the 13th day a distinction between the elongate nuclei of the embryonic stem cells and the rounded nuclei of the differentiating receptors is visible. A basal layer of stem cells remains mitotically active from the 13th day of gestation onwards, and after the 15th day the majority of mitoses occur in this layer. It is suggested that from the 15th day of gestation onwards the nuclei situated most apically become those of the supporting cells. The glands of Bowman are first visible on the 17th day of gestation.

The diverticulum of the vomeronasal organ begins to form on the 11th day and the development of its sensory epithelium resembles that of the olfactory organ except for the absence of basally situated stem cell nuclei in the later stages of the vomeronasal organ.

The authors thank Professor R. Warwick for his encouragement and helpful advice; Mr D. Ristow for histological assistance; and Mr K. Fitzpatrick for photographic help. They are indebted to the Royal University of Malta for financial support given to one of them (A.C.) during the period of this investigation.

Fig. 13. Olfactory epithelium at 14 days' gestation showing dark elongate nuclei at the apex and base, and more vesicular nuclei in the middle. Note mitotic figure at the epithelial surface and olfactory nerve bundles (*n*) deep to the epithelium. H & E; $\times 300$.

Fig. 14. Olfactory dendrites (*d*) and terminal knobs (*k*) in the olfactory epithelium at 15 days' gestation. Holmes' silver; $\times 600$.

Fig. 15. Capillaries (*c*) invaginating the base of the olfactory epithelium at 16 days' gestation. H & E; $\times 200$.

Fig. 16. Olfactory epithelium at 18 days' gestation showing Bowman's glands (*b*) extending into the mesenchyme. H & E; $\times 130$.

REFERENCES

- BALFOUR, F. M. (1877). The development of elasmobranch fishes. *Journal of Anatomy and Physiology* **11**, 406–490.
- BEARD, J. (1885). The system of branchial sense organs and their associated ganglia in Ichthyopsida. *Quarterly Journal of Microscopical Science* **85**, 95–196.
- BEDFORD, E. A. (1904). The early history of the olfactory nerve in swine. *Journal of Comparative Neurology* **14**, 390–410.
- BREIPHOL, W. (1972). Licht- und elektronenmikroskopische Befunde zur Struktur der Bowmanschen Drüsen im Riechepithel der weissen Maus. *Zeitschrift für Zellforschung und mikroskopische Anatomie*, **131**, 329–346.
- BREIPHOL, W., LAUGWITZ, H. J. & BORNFIELD, N. (1974). Topological relations between the dendrites of olfactory cells and sustentacular cells in different vertebrates. An ultrastructural study. *Journal of Anatomy*, **117**, 89–94.
- BREIPHOL, W., MESTRES, P. & MELLER, K. (1973). Licht- und elektronenmikroskopische Befunde zur Differenzierung des Riechepithels der weissen Maus. *Verhandlungen der Anatomischen Gesellschaft* **67**, 443–449.
- BURR, H. S. (1932). An electrodynamic theory of development suggested by studies of proliferation rates in the brain of *Amblystoma*. *Journal of Comparative Neurology* **56**, 347–371.
- CAJAL, S., RAMON Y (1890). Origen y terminacion de las fibras nerviosas olfatorias. *Gaceta medica Catalana* **12**, 6.
- CAMERON, J. & MILLIGAN, W. (1914). The development of the olfactory nerves in vertebrates. *Transactions of the International Congress of Medicine, London; Section 15, Rhinology and Laryngology, Part 2*, 451–465.
- CHIARUGI, G. (1891). Observations sur les premières phases de développement des nerfs encéphaliques chez les mammifères, et, en particulier sur la formation du nerf olfactif. *Archivo italiano di biologia*, **15**, 418–425.
- COGHILL, G. E. (1916). Correlated anatomical and physiological studies of growth of the nervous system of amphibia. II. The afferent system of the head of *Amblystoma*. *Journal of Comparative Neurology* **26**, 247–340.
- CUSCHIERI, A. (1972). The structure and histochemistry of the olfactory and vomeronasal organs in the mouse. Ph.D. Thesis, University of London.
- FRAZER, J. E. (1953). *A Manual of Embryology*. London: Bailliere, Tindall and Cox.
- HINDS, J. W. (1972*a*). Early neuron differentiation in the mouse olfactory bulb. I. Light microscopy. *Journal of Comparative Neurology* **146**, 233–252.
- HINDS, J. W. (1972*b*). Early neuron differentiation in the mouse olfactory bulb. II. Electron microscopy. *Journal of Comparative Neurology* **146**, 253–276.
- HIS, W. (1889). Über die Entwicklung des Riechlappens und des Riechganglions und über diejenige des verlängerten Markes. *Verhandlungen der Anatomischen Gesellschaft* **4**, 63–66.
- HOLMES, W. (1947). In *Recent Advances in Clinical Pathology* (Ed. S. C. Dyke). London: Churchill.
- MARSHALL, M. (1878). The development of the cranial nerves of the chick. *Quarterly Journal of Microscopical Science* **18**, 10–40.
- MOULTON, D. G., CELEBI, G. & FINK, R. P. (1970). Olfaction in mammals. Two aspects: proliferation of cells in the olfactory epithelium and sensitivity to odours. In *Ciba Foundation Symposium on Taste and Smell in Vertebrates*, pp. 227–250. (Ed. G. E. W. Wolstenholme and J. Knight). London: Churchill.
- SAUER, F. W. (1937). Some factors in the morphogenesis of vertebrate embryonic epithelia. *Journal of Morphology* **61**, 563–579.
- SMART, I. (1971). Location and orientation of mitotic figures in the developing mouse olfactory epithelium. *Journal of Anatomy* **109**, 243–251.
- VAN CAMPENHOUT, E. (1956). Le développement embryonnaire comparé des nerfs olfactif et auditif. *Acta oto-rhino-laryngologica belgica* **11**, 279–287.
- VINNIKOV, Y. A. & TITOVA, L. K. (1956). The development of vertebrate sense organs. *Problemy sorr. Embriology (Leningrad)* **89**, 96.
- WESOLOWSKI, H. (1970). Morphological and histochemical studies on the development of the olfactory epithelium in the hen. *Folia biologica* **18**, 71–80.