

From the Divisions of  
\*Neurology and  
†Neuroradiology, Sunnybrook  
and Women's College Health  
Sciences Centre, Sunnybrook  
Site, Toronto, Ont.

This article has been peer reviewed.

CMAJ 2000;162(2):236-8

# Chasing the dragon — neurological toxicity associated with inhalation of heroin vapour: case report

Michael D. Hill,\* Perry W. Cooper,† James R. Perry\*

## Case

A 33-year-old white man was admitted to a Toronto hospital after being found in an unresponsive state by his sister. He was a known drug abuser and had a history of heroin and cocaine use. It was known that he took his heroin not by injection but by inhalation of heated heroin vapours, a method known as “chasing the dragon.” He had last been seen well 3 days previously and had spent the intervening period in bed for unknown reasons.

The patient was intubated at the scene by paramedics and had a Glasgow coma score of 6 upon admission. He was tachypneic (38 breaths/min) but hemodynamically stable, with blood pressure of 150/95 mm Hg, normal sinus rhythm and temperature of 38°C. Neurological examination revealed that he was comatose, unresponsive to verbal or painful stimuli. His pupils were both 4 mm in diameter and reactive, and the fundi were normal. Eye movements were conjugate but roving. Corneal reflexes were present bilaterally. The face was symmetric. The breathing pattern was fast but regular. Motor examination revealed axial myoclonus involving the neck flexors, the pectoral muscles and the abdominal musculature. The patient was diffusely hypotonic, and the limbs withdrew symmetrically on painful stimuli. Reflexes were 1+ throughout, but bilateral Babinski signs were present. General examination revealed no cardiac murmurs, a clear chest and normal abdomen. No needle marks were seen.

Head CT revealed bilateral hypoattenuated regions in the pallidum. Brain MRI demonstrated diffusely abnormal areas of increased T<sub>2</sub> signal intensity involving the deep white matter of both cerebral hemispheres and the cerebellum (Fig. 1). Magnetic resonance angiography demonstrated normal proximal cerebral circulation. Electroencephalography demonstrated diffuse bilateral moderate-voltage theta and delta activity without epileptiform abnormalities. Carbon monoxide was undetectable in the serum. Lumbar puncture showed entirely normal cerebrospinal fluid indices. Chest radiography revealed no pulmonary disease. Creatine kinase was significantly elevated, to 32 930 U/L, with no myoglobinuria. The result of HIV serologic testing was negative. The heroin metabolites O<sup>6</sup>-monoacetylmorphine and morphine were present in the urine.<sup>1</sup> Results of tests for cocaine metabolites and other toxic agents were negative.

The patient recovered only minimally over the ensuing 3 weeks. He died of *Staphylococcus aureus* pneumonia and septicemia on day 26 of admission, having never regained consciousness. No autopsy was performed.

## Comments

Toxin-related diseases of the brain are uncommon. When such toxins affect predominantly the white matter, these diseases are known as toxic leukoencephalopathies. These conditions are rare but often reversible if exposure to the toxic agent is discontinued. Heroin leukoencephalopathy is associated with an estimated mortality rate of 23%.<sup>2</sup> It is rare or unrecognized but has devastating consequences.

Heroin-associated death may be related to acute overdose of high-dose or pure (“Chinese white”) heroin, complications of intravenous drug use such as infection with HIV or hepatitis C, violence or other causes. Heroin was a popular drug in the

late 1960s and early 1970s;<sup>3</sup> its use declined subsequently but is now making a resurgence. Although a lifetime prevalence of heroin use is reported in only 0.5% of the Canadian population, heroin use has been increasing in Toronto, Montreal and Calgary and is best documented in Vancouver.<sup>4</sup> Recent editorials have focused on the need both for increased awareness and for clinical trials of methadone for treating heroin addicts.<sup>5-7</sup> Heroin abuse has been growing in Canada and, combined with cocaine abuse, was the leading cause of death in men 30 to 44 years of age in 1993 in British Columbia.<sup>7</sup>

The neurological complications of heroin use are probably caused by both the drug itself and the method of administration. Heroin addicts experience illnesses affecting all parts of the neuraxis including brain abscess,<sup>8</sup> transverse myelitis,<sup>9</sup> neuropathy<sup>10,11</sup> and rhabdomyolysis with myoglobinuria.<sup>12,13</sup>

A new addition to this list, heroin vapour leukoencephalopathy, was first reported in 1982 from Amsterdam.<sup>2</sup> Since then, cases have been reported sporadically from both Europe and the United States.<sup>14,15</sup> To date, fewer than 100 cases have been reported. Although heroin is commonly taken by injection, it may also be taken by inhalation of heated vapours. Users heat the powder on aluminum foil and inhale the smoke. This practice is known as “chasing the dragon,” “chinesing” or “chinese blowing.”

Thorough investigation of the original cohort of 47 patients from Amsterdam, including autopsy for 10 of them, toxicologic analysis of heroin samples, investigation of unaffected heroin addicts and testing of the effects of heroin vapour in animal models, failed to find a toxicologic cause of the leukoencephalopathy.<sup>2</sup> The autopsies revealed severe changes in the white matter, termed vacuolating myelinopathy; this lesion was characterized by formation of vacuoles in the oligodendroglia, resulting in spongiform degeneration. Although several additive substances were discovered in the heroin samples, none were known or shown to produce the histopathological changes in the rat

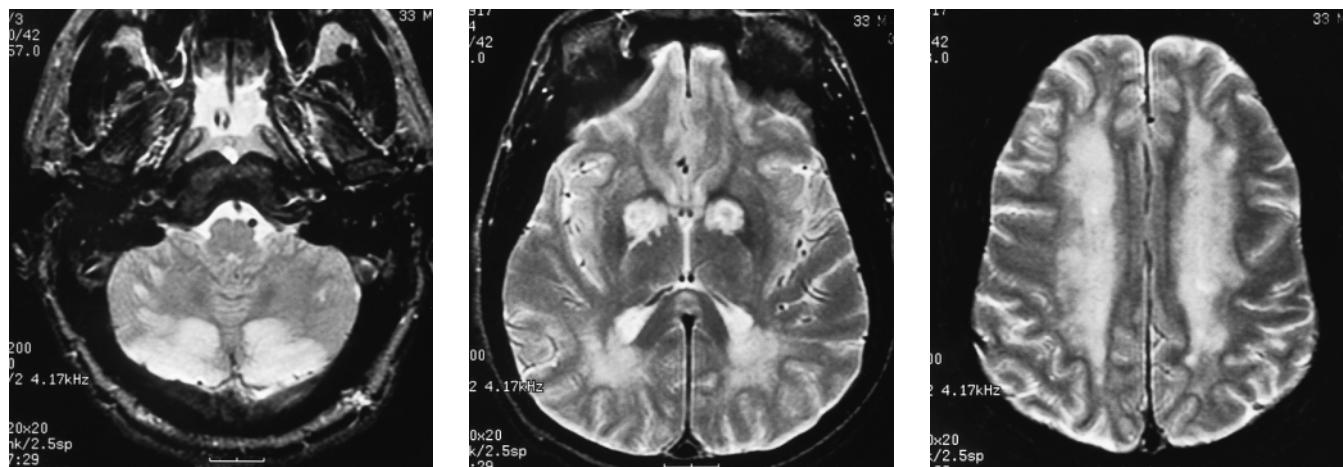
or the rabbit model. The authors speculated that an as-yet-unidentified toxic substance is released when heroin is heated.<sup>2</sup>

One case involving a similar vacuolating myelinopathy of the brain was reported in association with intravenous heroin overdose.<sup>16</sup> Similarly, one case of delayed spongiform leukoencephalopathy has been reported after multi-drug overdose, but heroin was not implicated;<sup>17</sup> the authors attributed their findings to cocaine. Perez and associates<sup>18</sup> reported a case of acute leukoencephalopathy isolated to the cerebellum in the 2½-year-old child of a heroin addict; the child’s gastric contents, urine and delayed hair samples contained heroin. Therefore, inhalation of heroin pyrolysate may not be the sole way of acquiring this toxic leukoencephalopathy.

Anoxia may cause acute leukoencephalopathy. Ginsberg and colleagues<sup>19</sup> first described the pathology of anoxic leukoencephalopathy, postulating that the lack of anastomoses in the arterial supply to the cerebral deep white matter promotes susceptibility to infarction. The case reported here had many parallels to the first of the 35 cases described by Ginsberg and colleagues;<sup>19</sup> both showed bilateral pallidal infarcts and diffuse spongiform white matter disease associated with heroin overdose. In contrast, none of the original Amsterdam cohort<sup>2</sup> and none of the other cases described by Ginsberg and colleagues<sup>19</sup> had pallidal infarction.

The pallidum may be acutely sensitive to metabolic stress. Bilateral pallidal lesions are often seen in carbon monoxide poisoning but are also reported in drowning, strangulation and thyroid storm.<sup>20-24</sup> We speculate that in severe cases, the toxic effects of heroin vapour may result in both pallidal lesions and spongiform leukoencephalopathy.

We wonder whether some drug addicts take heroin by inhalation to avoid the well-advertised dangers of injection drug use. It is uncertain whether leukoencephalopathy due to heroin vapour inhalation is rare, perhaps due to a sporadic toxin introduced during production, or more com-



**Fig. 1:** T<sub>2</sub>-weighted transverse magnetic resonance images of the brain demonstrating high signal intensity in the cerebellar white matter and cortex (left), bilaterally in the pallidum (middle) and in the white matter of the cerebral hemispheres (right).

mon and unrecognized. In otherwise undiagnosed acute leukoencephalopathy, clinicians should consider the possibility of heroin vapour inhalation.

Competing interests: None declared.

## References

- Fehn J, Megges G. Detection of O<sup>6</sup>-monoacetylmorphine in urine samples by GC/MS as evidence for heroin use. *J Anal Toxicol* 1985;9:134-8.
- Wolters EC, van Wijngaarden GK, Stam FC, Rengelink H, Lousberg RJ, Schipper MEI, et al. Leucoencephalopathy after inhaling "heroin" pyrolysate. *Lancet* 1982;2(8310):1233-7.
- DuPont RL. Profile of a heroin-addiction epidemic. *N Engl J Med* 1971; 285:320-4.
- Poulin C, Fralick P, Whynot EM, el-Ghuebaly N, Kennedy D, Bernstein J, et al. The epidemiology of cocaine and opiate abuse in urban Canada. *Can J Public Health* 1998;89:234-7.
- Fischer B, Rehm J. The case for a heroin substitution treatment trial in Canada. *Can J Public Health* 1997;88:367-70.
- De Burger R. Heroin substitution in Canada: A necessary public health intervention? [editorial]. *Can J Public Health* 1997;88:365.
- Brands B, Marsh DC. Methadone maintenance treatment: a Canadian perspective [editorial]. *CMAJ* 1997;157:399-401.
- Hersheve GL, Davis LE, Bicknell JM. Primary cerebellar brain abscess from nocardiosis in a heroin addict. *Neurology* 1988;38:1655-6.
- Richter RW, Rosenberg RN. Transverse myelitis associated with heroin addiction. *JAMA* 1968;206:1255-7.
- Loizou LA, Boddie HG. Polyradiculoneuropathy associated with heroin abuse. *J Neurol Neurosurg Psychiatry* 1978;41:855-7.
- Amnueilaph R, Boonigird P, Leechawengwongs M, Vejajiva A. Heroin neuropathy [letter]. *Lancet* 1973;818:1517-8.
- De Gans J, Stam J, van Wijngaarden GK. Rhabdomyolysis and concomitant neurological lesions after intravenous heroin abuse. *J Neurol Neurosurg Psychiatry* 1985;48:1057-9.
- Schreiber SN, Liebowitz MR, Bernstein LH, Srinivasan K. Limb compression and renal impairment (crush syndrome) complicating narcotic overdose. *N Engl J Med* 1971;284:368-9.
- Tan TP, Algra PR, Valk J, Wolters EC. Toxic leukoencephalopathy after inhalation of poisoned heroin: MR findings. *AJNR Am J Neuroradiol* 1994; 15:175-8.
- Kriegstein AR, Armitage BA, Kim PY. Heroin inhalation and progressive spongiform leukoencephalopathy [letter]. *N Engl J Med* 1997;336:589-90.
- Rizzuto N, Morbin M, Ferrari S, Cavallaro T, Sparaco M, Boso G, et al. Delayed spongiform leukoencephalopathy after heroin abuse. *Acta Neuropathol (Berl)* 1997;94:87-90.
- Nuytten D, Wyffels E, Michiels K, Ferrante M, Verbraeken H, Dailemans R, et al. Drug-induced spongiform leukoencephalopathy, a case report with review of the literature. *Acta Neurol Belg* 1998;98:32-5.
- Perez ER, Maeder P, Rivovier L, Deonna T. Toxic leukoencephalopathy after heroin ingestion in a 2.5 year old child [letter]. *Lancet* 1992;340:729.
- Ginsberg M, Hedley-Whyte T, Richardson EP. Hypoxic-ischemic leukoencephalopathy in man. *Arch Neurol* 1976;33:5-14.
- Schwartz A, Hennerici MD, Wegener OH. Delayed choreoathetosis following acute carbon monoxide poisoning. *Neurology* 1985;35:98-9.
- Choi IS. Delayed neurological sequelae in carbon monoxide intoxication. *Arch Neurol* 1983;40:433-5.
- Murray RR, Kapila A, Blanco E, Kagen-Hallet KS. Cerebral computed tomography in drowning victims. *AJNR Am J Neuroradiol* 1984;5:177-9.
- Hori A, Hirose G, Kataoka S, Tsukada K, Furui K, Tonari H. Delayed post anoxic encephalopathy after strangulation: serial neuroradiological and neurochemical studies. *Arch Neurol* 1991;48:871-4.
- Page SR, Scott AR. Thyroid storm in a young woman resulting in bilateral basal ganglia infarction. *Postgrad Med J* 1993;69:813-5.

**Reprint requests to:** Dr. Michael D. Hill, Department of Clinical Neurosciences, University of Calgary, Foothills Hospital, Rm. MRG 005, 1403 29th St. NW, Calgary AB T2N 2T9