

## An electron microscopic study of the pericytes of the developing capillaries in human fetal brain and muscle

GRETA ALLSOPP AND H. J. GAMBLE

*Department of Anatomy,  
St Thomas's Hospital Medical School, London, England*

(Accepted 27 January 1978)

### INTRODUCTION

From many ultrastructural studies it is well established that a capillary is a tube formed by a single layer of endothelial cells surrounded by a glycoprotein basal lamina which is split at intervals to enclose flattened and sometimes branched perivascular cells, or pericytes.

Fetal capillaries, generally more complex than adult ones, have been studied in various tissues of different species including the developing central nervous system of man. Bauer & Vester (1970) in an extensive study of the capillaries in the human fetal brain concentrated on cytological detail, while Hauw, Berger & Escourolle (1975*a, b*) attempted to catalogue capillaries of human fetal cerebellum and olfactory bulb (including those grown in tissue culture) according to size. Very recently Povlishock, Martinez & Moosy (1977) have shown something of the elaborate relationships which may occur between endothelial cells and pericytes in the telencephalic germinal matrix, and the studies now reported extend these observations.

### MATERIALS AND METHODS

Parts of the cerebrum were dissected from human fetuses of 5, 6, 7.5 and 10 cm crown-rump length together with the superior rectus oculi muscle from fetuses of 5, 9.2, 12 and 24 cm crown-rump length. The fetuses were obtained at hysterotomy and believed to be normal.

The cerebrum was bathed *in situ* in chilled 5% glutaraldehyde and placed in this solution after removal. Material was taken from the frontal and temporal lobes of the 5 cm specimen, the frontal and occipital lobes of the 6 cm specimen, the frontal lobe of the 7.5 cm specimen, and the frontal, parietal and occipital lobes of the 10 cm specimen.

Small pieces of the superior rectus oculi muscle were removed and these, together with the brain specimens, were placed in buffered glutaraldehyde for about 4 hours. After several rinses in chilled 10% glucose, similarly buffered, the specimens were further fixed in buffered 1% osmium tetroxide for 1 hour. After dehydration and embedding in Araldite, thick sections (about 1  $\mu\text{m}$ ) were stained with a mixture of Azur II and methylene blue (Richardson, Jarett & Fink, 1960) and examined by light microscopy.

Thin sections were mounted on uncoated grids, stained with uranyl acetate and examined in an A.E.I. EM6B electron microscope.

Serial sections were often obtained although the exact sequence was not always certain on the grid. Preservation of tissue was generally good.

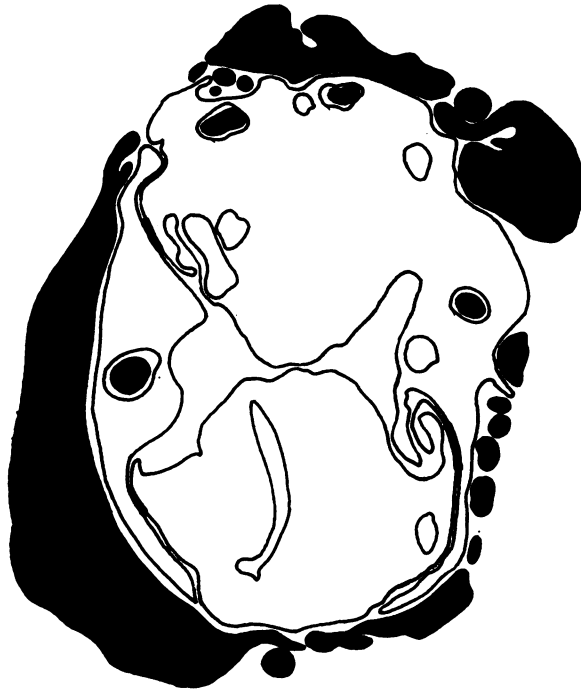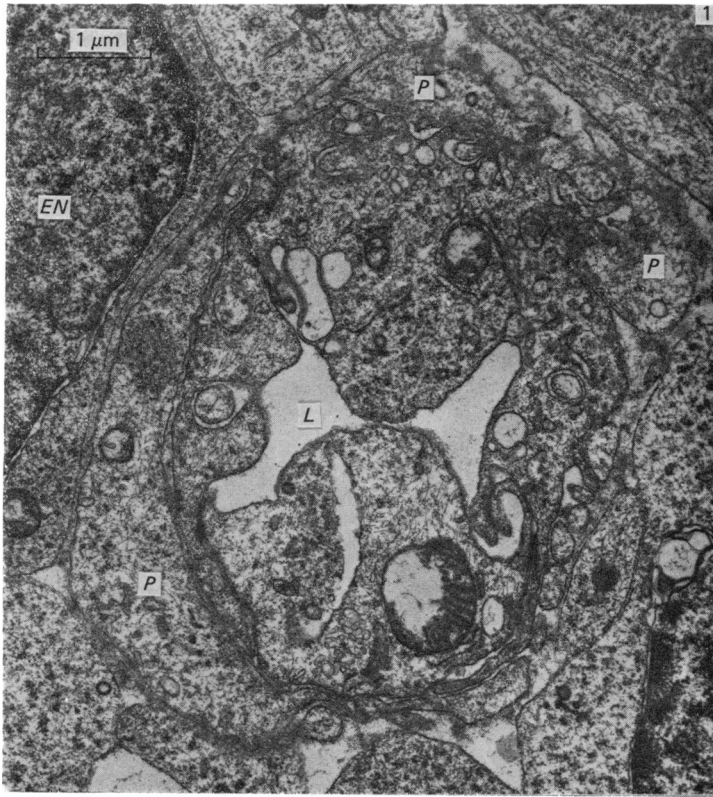


Fig. 1A

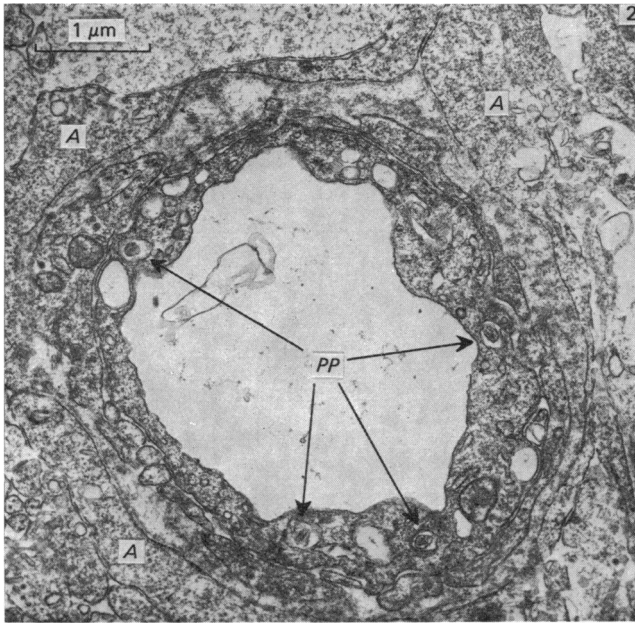


Fig. 2. From the temporal lobe of the brain. The electron micrograph shows a single-cell capillary with no cell junctions. Small pericyte processes enwrap the capillary, and tiny pegs of their cytoplasm are received into endothelial cell sockets (PP, pericyte pegs arrowed). Apart from these sockets in the endothelium, large vacuoles are present giving the cytoplasm a 'Swiss-cheese' appearance. Loosely packed basal lamina surrounds the capillary which is, in turn, enwrapped by processes of astrocyte cells (A). 5 cm crown-rump length human fetus.  $\times 15000$ .

In the case of the brain sections, those of the 5, 6 and 7.5 cm fetuses were cut at right angles to the surface of the brain, passing through the entire cerebral hemisphere wall from pia to ependyma. In the 10 cm specimen all sections were cut tangential to the brain surface.

Because of the general similarity of the material from the 5 cm, 6 cm and 7.5 cm specimens, only the first and last of these three stages are described here.

## RESULTS

### *Brain of 5 cm fetus*

The capillaries in this specimen were almost always surrounded by a basal lamina, but this was usually of a very loose texture (Figs. 1, 2). Its thickness was sometimes as great as  $0.5 \mu\text{m}$  but this was commonly much reduced where it was split to contain a cytoplasmic process, and particularly a thick process, of a pericyte.

The plasma membrane of endothelial cells was of increased electron density

Fig. 1. From the frontal lobe of the brain. An electron micrograph shows a three-endothelial-cell capillary enclosing a small lumen (L), and lying among the ependymal cells of the cerebral hemisphere. Two ependymal cell nuclei are shown (EN). Pericytes (P) are embedded within the capillary basal lamina, and small pericyte pegs enclosed in endothelial cell sockets can be identified. 5 cm crown-rump length human fetus.  $\times 15000$ .

Fig. 1A. Line drawing of Fig. 1 showing pericyte processes (shaded) and their relationships with the underlying endothelium.

where intercellular contacts were formed and where it covered flaps of cytoplasm extending either into the lumen of the vessel, or outwards between pericyte processes (Fig. 1): the line drawing in Figure 1A should help to clarify the situation. The membrane also delimited deep indentations of the cells which received pericyte processes (Figs. 1, 2).

Pericyte bodies, or their attenuated cytoplasmic processes, were almost always present on the capillaries seen in this specimen, sometimes as a single process wrapping as much as half the perimeter of the vessel, but much more often as numerous tiny processes, together with a few larger ones, which almost completely invested the tube of endothelium. Minor processes frequently indented the underlying endothelial cells, but processes projecting outward (into surrounding nervous tissue) were rare. Pericyte cytoplasm was seldom seen to contain organelles other than occasional mitochondria and coated vesicles and scattered profiles of granular endoplasmic reticulum.

The 'perivascular space' surrounding these capillaries, i.e. the space containing the basal lamina of endothelial cells and pericytes, was never seen to contain fibrils. It was bounded, variously, by ependymal cells (Fig. 1) and cytoplasmic processes of astrocytes (Fig. 2) and, occasionally, by axons and neurons which abutted directly on the basal lamina.

Capillaries were the only blood vessels present in this specimen and mitotic figures were never seen in endothelial cells or pericytes.

#### *Brain of 7.5 cm fetus*

Basal lamina surrounded all the capillaries examined, filling the relatively wide (0.4  $\mu\text{m}$ ) 'perivascular space' with a loosely packed fibrillar matrix which was less electron-dense than the surrounding tissues. The blood vessels in this specimen were never larger than capillaries and, as with the younger specimen, on no occasion was there any evidence of mitosis in the endothelial cells or pericytes.

The shape of the endothelial cells, however, was very elaborate, with complex interdigitating junctions between neighbours and peg-like processes which were received into sockets in pericyte processes. An extreme example has been found in which, in a single section, 15 or more endothelial cell processes have been identified within the surrounding pericyte processes. Very occasionally the reverse situation was encountered, with pegs of pericyte penetrating the endothelium.

On occasion, an outward projecting process of endothelial cell cytoplasm penetrated through and beyond the investing basal lamina into the neuropil (see Fig. 3A). Also in this section, and in one nearly serial with it, the pericyte was deep fissured close to its nucleus.

Specialized contact areas between pericytes and endothelial cells were observed, although rarely, in this specimen; an example is shown in Figure 4. This 'contact' could also be seen in a near serial section; in other sections this particular 'contact' had disappeared but a second 'specialized contact' between another pericyte cell process and the endothelium was identified. The basal lamina of this capillary contained some tiny fibrils of about 22 nm diameter which were thought to be immature collagen fibrils.

#### *Brain of 10 cm fetus*

As in the smaller specimens the only blood vessels present were capillaries, and mitotic figures were never observed. Basal lamina surrounded every capillary, being

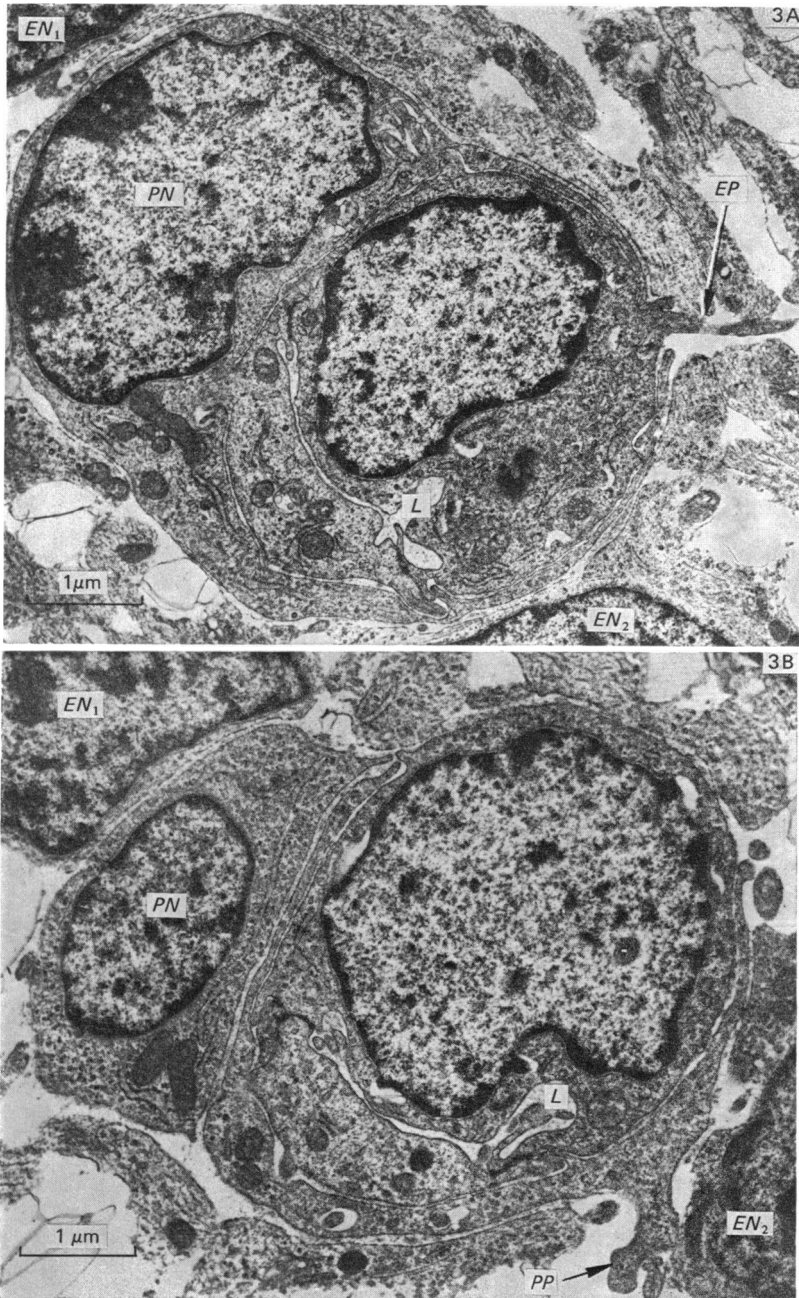


Fig. 3A. From the frontal lobe of the brain a two-endothelial-cell capillary with a small slit-like lumen (*L*) is wrapped almost completely by a nucleated pericyte (*PN*). An endothelial cell process (*EP*, arrowed) leaves the capillary where the pericyte arms finish and passes into the neuropil. Parts of two ependymal cell nuclei can be identified (*EN*<sub>1</sub>, *EN*<sub>2</sub>). 7.5 cm crown-rump length human fetus.  $\times 15000$ .

Fig. 3B. A near-serial section of Fig. 3A to show the nucleated pericyte split away from its processes by a fissure containing basal lamina. A small process of pericyte (*PP*, arrowed) is seen to leave the capillary to penetrate the neuropil. The same two ependymal cell nuclei identified in Fig. 3A are seen here (*EN*<sub>1</sub>, *EN*<sub>2</sub>). 7.5 cm crown-rump length human fetus.  $\times 15000$ .

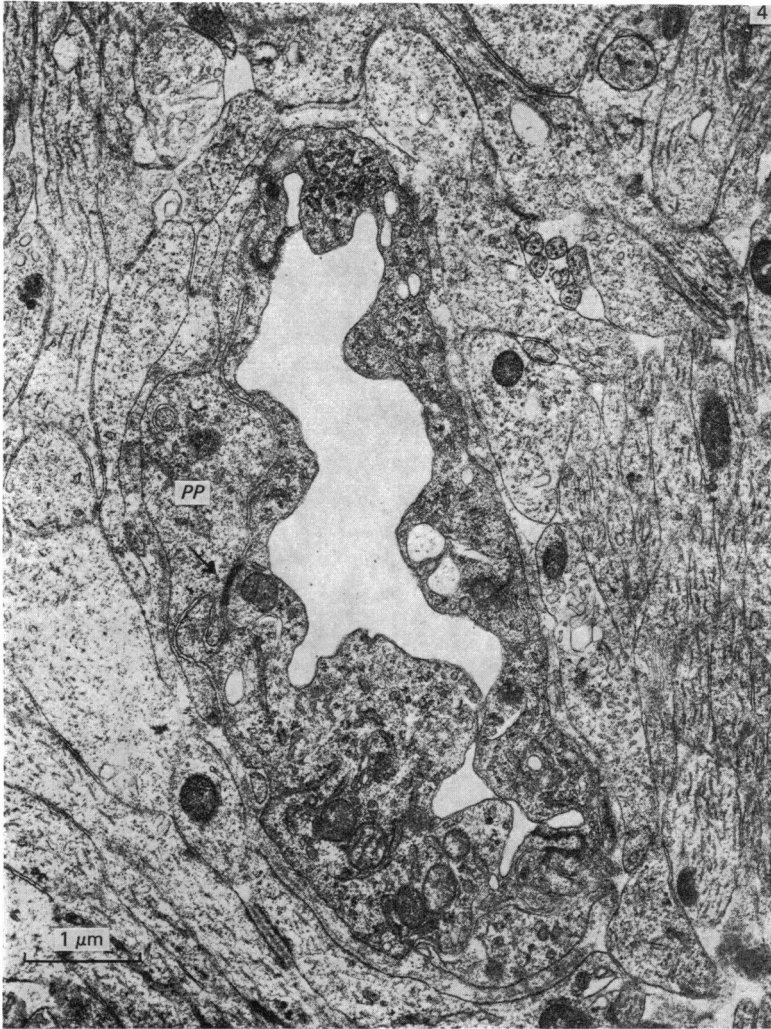


Fig. 4. From the frontal lobe of the brain. An electron micrograph of a two-endothelial-cell capillary which is in part covered by pericyte processes, one of which (*PP*) is seen to have a small thickening of the plasma membrane (arrowed), adjacent to a peg and socket formation. A corresponding thickening of the plasma membrane is found on the underlying endothelium. The capillary is enwrapped by basal lamina and this, in its turn, by processes of astrocytes. A few tiny fibrils, possibly developing collagen, can be identified in association with the basal lamina. 7.5 cm crown-rump length human fetus.  $\times 15000$ .

very electron-dense around those from the frontal and parietal lobes, and of variable density in the occipital lobe where the lamina was very thick.

As in the endothelial cells of the smaller specimens, some vacuolar structures indented the outer aspect of the cell: these contained cross sectioned cytoplasmic processes of the investing pericytes (Fig. 5). At the same time, cytoplasmic processes of the endothelial cells formed slender flaps projecting into the lumen as well as peg-like processes, sometimes bent and bifurcated, which projected outwards into pericytes or between their cytoplasmic processes (Figs. 5, 6). Serial sections showed that the solid endothelial core in Figure 5 was the blind end of a capillary.

In this specimen, pericytes were very variable in the extent to which they covered

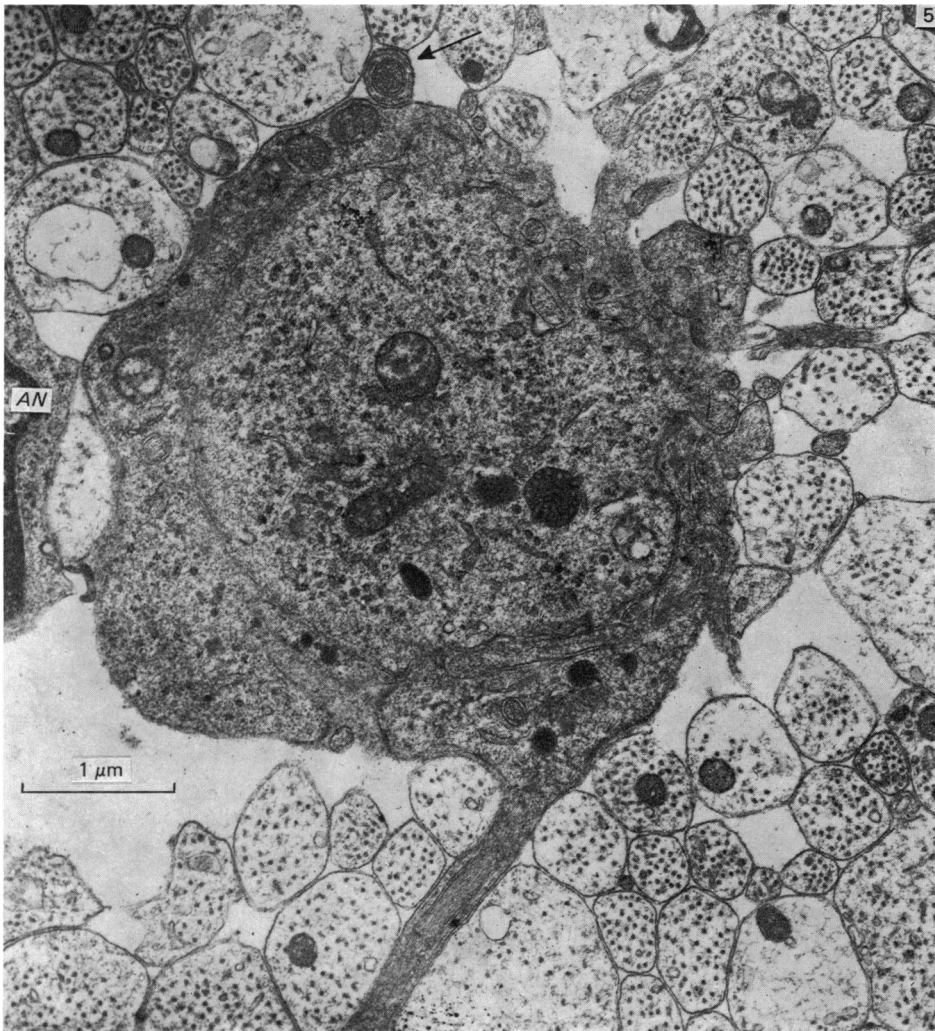


Fig. 5. From the frontal lobe of the brain. In this electron micrograph both axons and astrocytic cell processes, one of which is nucleated (*AN*), abut on to the capillary basal lamina which is very electron-dense and fairly sparse in places. The most striking feature of this section is the long endothelial cell process enwrapped by a pericyte, dissecting its way through the surrounding neuropil. Similar processes, with a less definable structure, can also be seen within the neuropil. A cross section of a pericyte with an endothelial core can be seen adjacent to the capillary (arrowed). 10 cm crown-rump length human fetus.  $\times 20000$ .

the tube of endothelial cells. Sometimes they formed no more than a thin and incomplete investing layer, sometimes an incomplete but slightly more elaborate investment involving peg and socket relationships with endothelial cells (Fig. 6). Peg-like projections of pericyte cytoplasm were occasionally seen inserted into socket-like indentations of the underlying endothelial cells. Similar projections of the endothelial cells were similarly, but more frequently, received into the pericytes, and were sometimes so long as to extend as cores through outward projections of the pericytes into the surrounding neuropil (Fig. 5). In fact 'pegs' of all these kinds were frequently bent and sometimes bifurcated, as were the sockets into which they were received. When cut transversely they appeared as a solid core

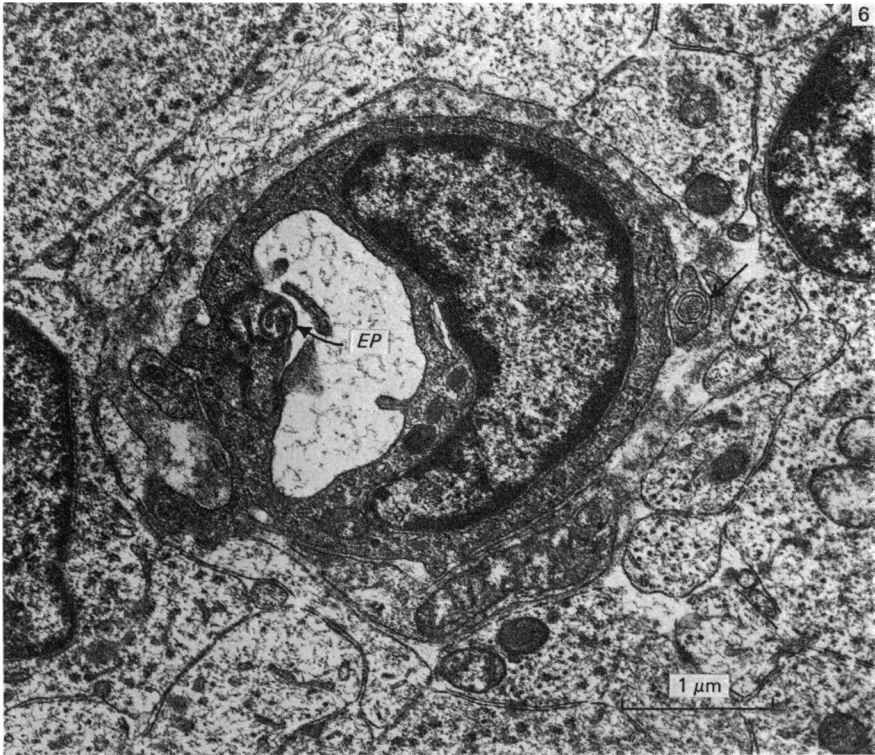


Fig. 6. From the occipital lobe of the brain. A single nucleated endothelial cell forms a capillary. At the cell junction a second endothelial cell process (*EP*, arrowed) is situated on the luminal aspect of the endothelium to which it is joined by a tight junction. In other near serial sections this inner endothelial cell process is either absent or is incorporated into the capillary wall. The basal lamina of the capillary is wide, and envelops three pericyte processes, one of which enwraps a core of endothelium (arrowed). Another endothelial cell process at one point traverses the basal lamina to abut against the astrocytic end-feet surrounding the vessel. 10 cm crown-rump length human fetus.  $\times 20000$ .

surrounded by a ring: when cut longitudinally, as three parallel processes (bounded by six parallel membranes).

No special features of cytoplasm or membrane were observed. As in the 7.5 cm specimen, a peg of endothelial cell cytoplasm extended through the basal lamina and between pericytes to contact the neuropil directly.

In the 10 cm specimen it was noteworthy that the immediate surroundings of the blood capillaries varied greatly. In Figure 5, for example, the vessel is almost wholly surrounded by rounded profiles, most probably representing axons, while in Figure 6 the vessels have relatively small parts of their surfaces confronting axons, the greater part facing astrocytic processes. On occasion confrontation was with the perinuclear regions of neurons or neuroglial cells.

#### *Superior rectus oculi muscle*

Basal lamina was always present on the muscle capillaries (although sometimes absent from the muscle cells and from Schwann cells of the nerve bundles within the muscle), but it was less thick and less dense on the 5 cm specimen than in the older specimens.

Pericyte processes surrounding the capillaries were relatively sparse in all the



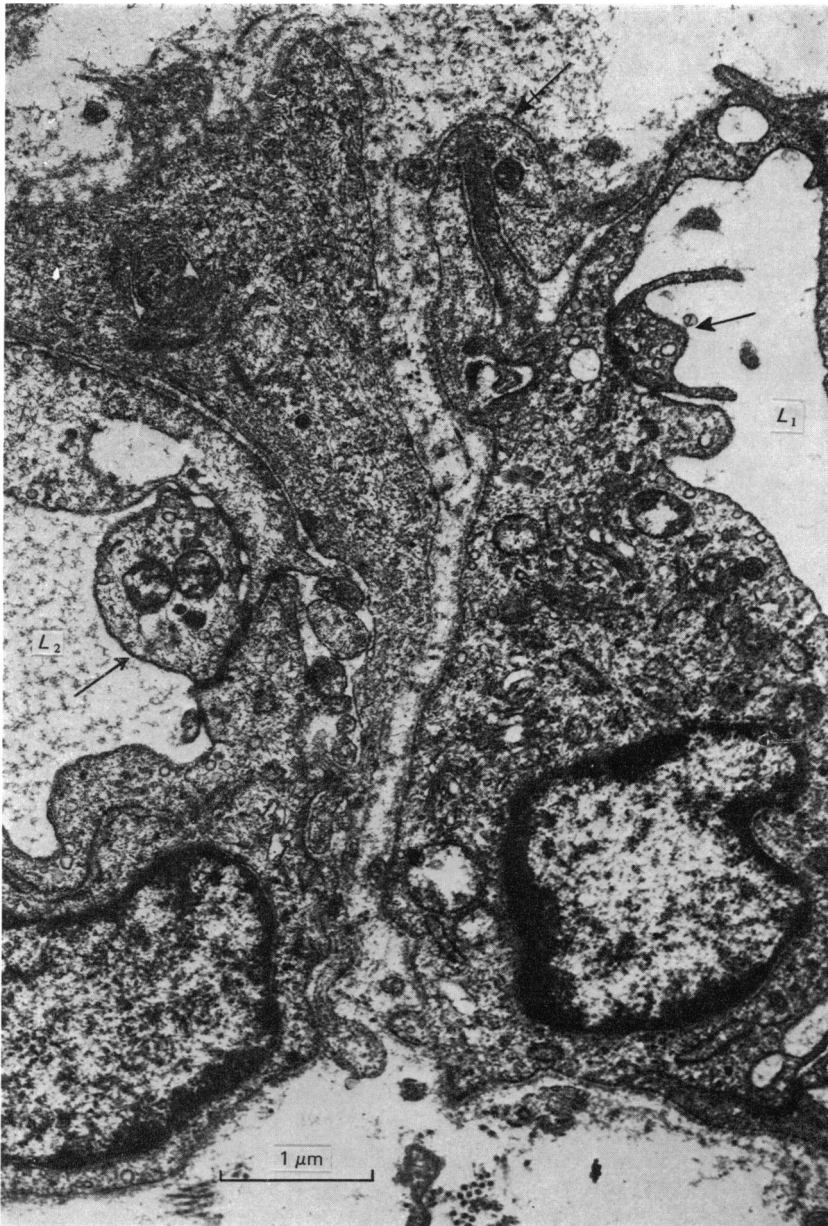


Fig. 7. From the superior rectus oculi muscle. Two adjacent capillaries with their respective lumina ( $L_1$ ,  $L_2$ ) both contain endothelial cell processes on the luminal aspects (arrowed), which are attached to the bounding endothelium by button-like tight junctions. A few pericyte processes are enveloped within the basal laminae of the capillaries. One such process is penetrated by a peg from the adjacent endothelial cell (crossed arrow). 12 cm crown-rump length human fetus.  $\times 20000$ .

specimens examined. They were invariably present, however, where abluminal processes of endothelium projected away from the capillary. On these occasions small processes of pericyte followed the endothelial cell closely (Fig. 7, 12 cm specimen). This relationship of pericyte and endothelial cell could be likened to

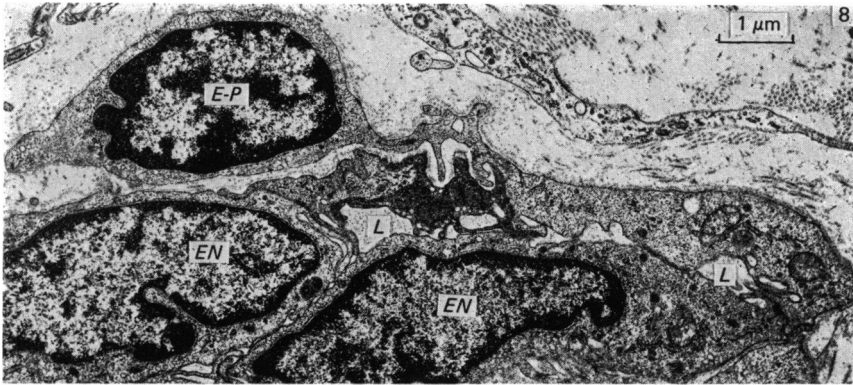


Fig. 8. From the superior rectus oculi muscle. A nucleated pericyte 'oblique' endothelial cell (*E-P*) forms part of the capillary wall like an endothelial cell but at the same time is embedded within the capillary basal lamina like a pericyte. Two slit-like portions of the lumen (*L*) of the capillary are bounded by five other endothelial cells, two of which are nucleated (*EN*). 12 cm crown-rump length human fetus.  $\times 10000$ .

the peg and socket arrangements described earlier, and was commonly found in all the specimens except the 5 cm one, where very few pericytes were identified.

Figure 8 shows a capillary with a cell in its wall resembling a pericyte in some respects but an endothelial cell in others. At its margins it is involved in junctional complexes with endothelial cells. It is, of course, possible that the cell is in fact endothelial throughout, its seemingly outlying part being in the wall of a branched vessel.

#### DISCUSSION

There are two rather striking differences, one intrinsic and one extrinsic, between cerebral and muscular capillaries in the human fetus. Firstly, pericytes form an extremely complex interrelationship with endothelial cells in cerebral vessels, but are relatively sparse and simple in those of muscle. Secondly, scattered connective tissue forms an open milieu for muscle capillaries, but entire capillaries are closely invested by packed neuropil. In their dimensions and in the form of their endothelial cells the vessels from the two tissues are much alike, but there are differences, which are discussed below.

In the embryo pericytes are said to be derived from the mesenchyme around primitive vessels (Sethi & Brookes, 1971). This could well be true of intramuscular vessels in the earliest stages of myotube formation when some mesenchyme is still present, and of the earliest vessels of the C.N.S. when these are exclusively located on its outer aspect in the loose connective tissues (at least akin to mesenchyme) from which leptomeninges will be derived. In fetuses of the ages and sizes examined here, however, mesenchyme *per se* is no longer present.

Looped vessels penetrating into the C.N.S. from the overlying pial vessels may be assumed to include pericytes with the endothelial cells, but in the development of new vascular sprouts, since the C.N.S. contains no mesodermal elements, the new pericytes must either be derived from newly budded endothelial elements, or from the budding of pericytes on the older, more proximal parts of the vessel. Mitotic division of pericytes during wound healing has been described (Cliff, 1976), and of course tissue responses to injury often mimic the normal developmental processes; however, the possibility that pericytes might be derived from endothelial

cells cannot be dismissed lightly, especially as the two cell types are often almost identical in appearance. Kuwabara & Cogan (1963) observed that, in the capillaries of the retina of the rat, mural cells appeared to arise from the same fetal anlagen that gave rise to endothelium. These authors regarded pericytes as cells outside the vessel wall, in contradistinction to 'mural cells' which were within the substance of the wall, i.e. were enveloped by the basal lamina of the capillary. Nowadays such mural cells would be regarded as definitive pericytes. A 'third cell type' ('pericyte') in the renal glomerulus was seen by Farquhar & Palade (1961) to extend narrow necked but bulbous cytoplasmic projections between endothelial cells into the vascular lumen; while Schoefl (1963), studying capillaries after wounding, described a periendothelial cell which, when traced through serial sections, became continuous with the inner (endothelial) wall of the vessel. A very similar condition is shown in our Figure 8. Also 'endothelial cells' may be found in the position of pericytes with or without (Bauer & Vester (1970), their Figs. 1 and 2, respectively) forming specialized contacts with neighbouring endothelial cells and, having no contact with the vascular lumen. Such identifications clearly cannot always be wholly reliable. Crocker, Murad & Geer (1970) studied wound healing in the hamster and proposed that the numerous areas of close association between endothelial cells and pericytes present at 14 days were in some way responsible for the control of capillary proliferation and the reduction in capillary numbers, and restoration of the endothelium to a uniform thickness by 21 days. This suggestion conforms with that of Kuwabara & Cogan (1963) who found that new vessels in the retina only develop from vessels without mural cells. Thus in the fetus new vessels stop growing at the time mural cells appear (5th month). Similarly, loss of mural cells in pathological conditions is accompanied by a proliferation of the vessels. Kuwabara & Cogan were at pains to differentiate between mural cells and pericytes in retinal capillaries. Cliff (1976) and Majno (1965) disagreed, believing mural cells and pericytes to be identical.

Forbes, Rennels & Nelson (1977) have described small areas of specialized membrane apposition between pericytes and endothelial cells in adult mouse myocardium. These areas resembled the junctions between adjacent endothelial cells, and were thought to be the means by which pericyte contraction was transmitted to the endothelial cylinder.

In the present material, on only one occasion were specialized contacts between pericytes and endothelial cells seen (see Fig. 4, 7.5 cm specimen) apart from the rather special case where (Fig. 8) a cell appeared to be a pericyte and an endothelial cell at the same time. The examination of serial sections showed that these 'contacts' involved only small and isolated areas.

The roles most frequently attributed to pericytes are: (1) support for endothelial cells; (2) potential phagocytic activity and (3) source of undifferentiated mesenchymal cells in repair and inflammation (Cliff, 1976). The cerebral blood vessels surrounded by a closely packed array of glial and neuronal processes would at first sight appear to be admirably supported, but it must be remembered that the brain has the consistency and strength of blancmange and it maintains its shape only because it is suspended in cerebrospinal fluid. An extensive system of pericytes embedded in a continuous basal lamina may therefore be essential for capillary support in a tissue with such mechanical deficiencies. It is to be remembered, however, that only vessels of capillary type were seen in the material examined; none had yet developed muscle cells in their walls.

One must suppose that the appearance of collagen fibrils and, later, of smooth muscle cells around brain capillaries depend on local cellular activities, and it seems probable that the pericytes are responsible for both collagen formation and muscle development since no other cells are present. In developing voluntary muscles, however, capillaries are surrounded from very early on by loose connective tissue, and the later acquisition of smooth muscle cells by those which develop into arterioles and venules, does not demand the transformation of pericytes. One may well attribute the large provision of pericytes in developing cerebral capillaries to the need for stem cells as more elaborate vessels are formed, since no other cells are available. It is clear that new vessel production in the C.N.S. occurs by invasion, but this could take place by a process of dissection between elements of neuropil without any active tissue destruction. This would presumably involve amoeboid movements at the ends of outgrowing endothelial cells; however, only tiny outlying cytoplasmic processes have actually been seen.

The endothelial cell processes are often received into sockets in the overlying pericytes and so do not contact neuropil at all. Pericytes themselves are sometimes provided with cytoplasmic processes which penetrate among elements of the surrounding neuropil. They may be simple, but are sometimes hollowed out to contain a smaller peg of cytoplasm from the underlying endothelium. Projecting processes of cytoplasm, whether from endothelial cell or pericyte, show no special features, and it is not possible to attribute a particular function to them; they may indicate the means by which new elements of the capillary system dissect into the neuropil or, equally, the means by which capillaries are held in place.

Peg and socket interrelationships, but of pericyte peg into endothelial cell socket, have been described by Matsusaka (1975) in the choriocapillaris and retinal capillaries (where they are more frequent) of the adult human eye. He did not observe (as in our material is the more frequent occurrence) endothelial cell pegs received into pericytic sockets, although he did mention a rather simpler situation where processes project from the outer surface of endothelial cells and enter into a close relationship with the inner surface of the pericyte. He suggested that peg formation by pericytes might serve to anchor them firmly to endothelial cells, but went on to suggest that the processes might accept or release some information concerning blood circulation. We do not feel able to express any opinion on this matter since the peg-like processes, whether endothelial or pericytic, in our material exhibit no special cytoplasmic features.

Stensaas (1975), studying the pericytes in the basal forebrain of the neonatal rabbit, was in agreement with Matsusaka with respect to his findings of pericytes indenting the endothelium; he also failed to find any specialized appositional relations between the cells. Powlislock *et al.* (1977) observed interdigitation of pericytes and endothelial cells in the capillaries of the telencephalic germinal matrix in the human fetus. In their Figures 3 and 7, pericyte and endothelial cell simply interdigitate, whereas in their Figures 6, 9 and 10 they described a stub-like extension on the abluminal surface of the endothelial cell, which, with the pericyte, was reminiscent of a ball and socket arrangement. Powlislock *et al.* proposed that the function of these relationships was to serve as points of relative fixation for pericyte/endothelial cell interactions. They made no mention of pericyte indenting the endothelium, although in their Figure 6 there appear to be two rounded profiles of pericyte pegs enclosed by the endothelium.

Reference to peg and socket relationships between endothelial cells and pericytes

has not been found elsewhere in the literature, although some electron micrographs have been published which confirm their existence in other situations and species, e.g. Bauer & Vester (1970) in the human fetal brain, Roy, Hirano, Kochen & Zimmerman (1974) in the chick cerebral blood vessels, and Hauw *et al.* (1975*a, b*) in the cerebellum and olfactory bulb of the human fetus; Hauw *et al.* (1975*b*) did mention intermingling of endothelial cells and pericyte processes.

Dyson, Jones & Kendrick (1976) used a special lead perfusion technique to demonstrate endothelial cell processes in the neuropil surrounding blood capillaries of the developing rat cerebral cortex (without demonstrating their continuity with endothelial cells). The fine structure of these processes in their illustrations are not very clear, but they do not seem to resemble very closely the endothelial cell/pericyte complexes described here and illustrated in Figures 3, 5 and 6.

As mentioned above, capillaries in developing striated muscle are relatively poorly provided with pericytes, and those which are present show none of the outward projecting processes of cytoplasm so frequently seen in cerebral capillaries. Where pericyte processes were present, however, they were frequently situated so as to receive pegs from the underlying endothelium (see Fig. 7). Muscle capillaries lie in extensive endomyseal spaces, and their growth does not necessitate any process of dissection among closely packed cellular elements. They are also, from the earliest stage examined, associated with collagen fibrils which must hold them, albeit loosely, in place among the contractile elements. Too close attachment to the contracting elements, such as might be provided by radiating cytoplasmic processes, could well reduce their efficiency as blood vessels by producing excessive deformation of the lumen.

#### SUMMARY

Capillaries of the developing cerebral cortex were examined by electron microscopy and compared with those developing in the superior rectus oculi muscle.

The pericytes of cerebral vessels were found to be of very elaborate form and involved in complex 'peg and socket' relationships with endothelial cells. They were numerous and formed an almost complete investment of the endothelium. In the muscle, by contrast, pericytes were rare, although often of complex form.

Cerebral capillaries were always completely and closely invested by neuropil, in marked contrast to the very loose connective tissues in the vicinity of muscle capillaries. The significance of the findings is discussed.

We wish to thank Mr G. Maxwell for providing the sections studied in this work, and Mr Yurdakul Mustafa for much of the photography. We are also indebted to Miss Veronica Beams for secretarial assistance, and to Professor R. W. Taylor for his help in obtaining the fetuses. We also gratefully acknowledge financial support from The National Fund for Research into Crippling Diseases.

#### REFERENCES

- BAUER, K. FR. & VESTER, G. (1970). Das elektronenmikroskopische Bild der Hirnkapillaren menschlicher Feten. *Fortschritte der Neurologie, Psychiatrie und ihrer Grenzgebiete* **38**, 269–318.
- CLIFF, W. J. (1976). *Blood Vessels, Biological Structure and Function*, vol. 6. (ed. R. J. Harrison, R. M. H. McMinn & J. E. Treherne). Cambridge: Cambridge University Press.
- CROCKER, D. J., MURAD, T. M. & GEER, J. C. (1970). Role of pericyte in wound healing. An ultrastructural study. *Experimental and Molecular Pathology* **13**, 51–65.
- DYSON, S. E., JONES, D. G. & KENDRICK, W. L. (1976). Some observations on the ultrastructure of developing rat cerebral capillaries. *Cell and Tissue Research* **173**, 529–542.

- FARQUHAR, M. G. & PALADE, G. E. (1961). Glomerular permeability. II. Ferritin transfer across the glomerular capillary wall in nephrotic rats. *Journal of Experimental Medicine* **114**, 699-716.
- FORBES, M. S., RENNELS, M. L. & NELSON, E. (1977). Ultrastructure of pericytes in mouse heart. *American Journal of Anatomy* **149**, 47-69.
- HAUW, J. J., BERGER, B. & ESCOUROLLE, R. (1975a). Electron microscopic study of the developing capillaries of human brain. *Acta neuropathologica* **31**, 229-242.
- HAUW, J. J., BERGER, B. & ESCOUROLLE, R. (1975b). Ultrastructural observations on human cerebral capillaries in organ culture. *Cell and Tissue Research* **163**, 133-150.
- KUWABARA, T. & COGAN, D. G. (1963). Retinal vascular patterns. VI. Mural cells of the retinal capillaries. *Archives of Ophthalmology* **69**, 492-502.
- MAJNO, G. (1965). Ultrastructure of the vascular membrane. In *Handbook of Physiology* (ed. W. F. Hamilton & P. Dow), section 2, Circulation. Vol. 3, pp. 2293-2375. Washington: American Physiology Society.
- MATSUSAKA, T. (1975). Tridimensional views of the relationship of pericytes to endothelial cells of capillaries in the human choroid and retina. *Journal of Electron Microscopy* **24**, 13-18.
- POVLISHOCK, J. T., MARTINEZ, A. J. & MOOSSY, J. (1977). The fine structure of blood vessels of the telencephalic germinal matrix in the human fetus. *American Journal of Anatomy* **149**, 439-452.
- RICHARDSON, K. C., JARETT, L. & FINK, E. H. (1960). Embedding in epoxy resin for ultrathin sectioning in electron microscopy. *Stain Technology* **35**, 315-323.
- ROY, S., HIRANO, A., KOCHEN, J. A. & ZIMMERMAN, H. M. (1974). The fine structure of cerebral blood vessels in chick embryo. *Acta neuropathologica* **30**, 277-285.
- SCHOEFL, G. I. (1963). Studies on inflammation, III. Growing capillaries: their structure and permeability. *Virchows Archiv, A* **337**, 97-141.
- SETHI, N. & BROOKES, M. (1971). Ultrastructure of the blood vessels in chick allantois and chorio-allantois. *Journal of Anatomy* **109**, 1-15.
- STENSAAS, L. J. (1975). Pericytes and perivascular microglial cells in the basal forebrain of the neonatal rabbit. *Cell and Tissue Research* **158**, 517-541.