

The structure of the excurrent ducts of the testis of the guinea-fowl (*Numida meleagris*)

T. A. AIRE, J. S. AYENI AND M. O. OLOWO-OKORUN

Department of Veterinary Anatomy, University of Ibadan, Kainji Lake Research Institute, New Bussa and Department of Physiology and Pharmacology, University of Ibadan, Nigeria

(Accepted 2 November 1978)

INTRODUCTION

The morphology of the reproductive organs of certain avian species, including the domestic fowl (Gray, 1937; Stoll & Maraud, 1955; Lake, 1957; Tingari, 1971; Budras & Sauer, 1975), turkey (Hess, Thurston & Biellier, 1976), duck (Marchand & Gomot, 1973) and Japanese quail (Aire, 1979) has been studied. Seasonal changes in the reproductive organs of the duck have been reported by Marchand & Gomot (1973).

The guinea-fowl is a highly prized game bird on the African continent (Farkas, 1965). This bird is presently being domesticated at the University of Ibadan, Nigeria, and several studies of its biology are in progress.

The purpose of this present study was to establish the normal structure of the epididymal region and ductus deferens of the guinea-fowl as a basis for future studies of the cyclic changes that occur throughout the year in the reproductive organs.

MATERIALS AND METHODS

Nine sexually mature male guinea-fowl were studied during their breeding season.

Some of the tissues obtained from the epididymal region and from the cranial, middle and caudal portions of the ductus deferens were fixed in Bouin's fluid. They were processed conventionally, sectioned in paraffin at 5–7 μm , and stained with either haematoxylin and eosin or Masson's trichrome.

Tissues from the same organs and regions were also fixed by immersion, or by perfusion through the left ventricle of the heart for 30 minutes, with 3% glutaraldehyde buffered with 0.067 M cacodylate solution. The tissues were subsequently processed and embedded in Epon as if for electron microscopy but instead semithin sections were cut and stained with toluidine blue.

RESULTS

The active testis of the guinea-fowl is small compared to the fowl testis. Our male birds weighed between 996 and 1660 g live. Their two testes together weighed between 2.55 and 5.17 g. Each testis is about 2.5 cm in length, and is white and soft. The epididymal region is remarkably small, flattened, and attached to the medial side of the testis. It is about 1.5 cm long. The ductus deferens is wavy in outline and begins at the caudal end of the epididymal region; it is initially very narrow but

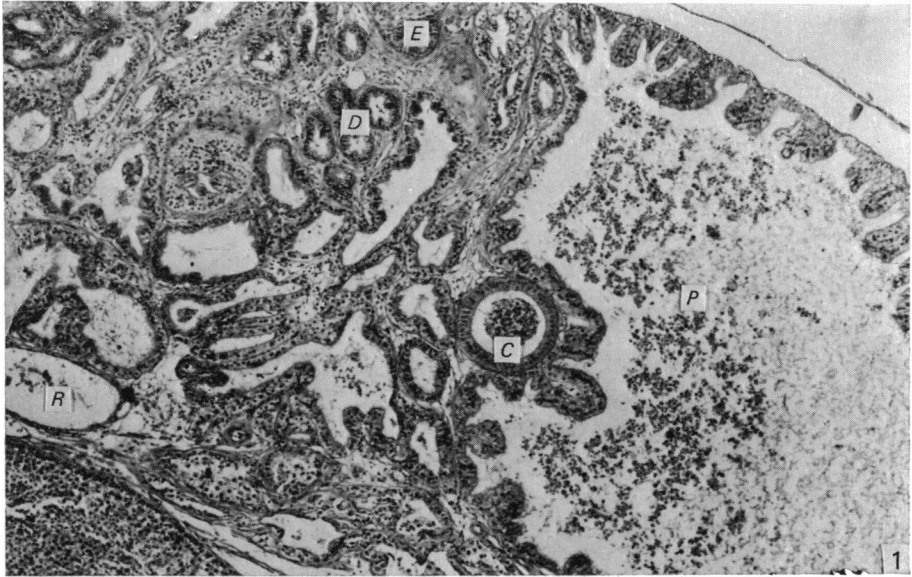


Fig. 1. Part of the epididymal region showing transverse sections of the proximal efferent ductules (*P*), distal efferent ductules (*D*), ductus epididymidis (*E*), rete testis (*R*) and connecting ductule (*C*). Haematoxylin and eosin. $\times 51$.

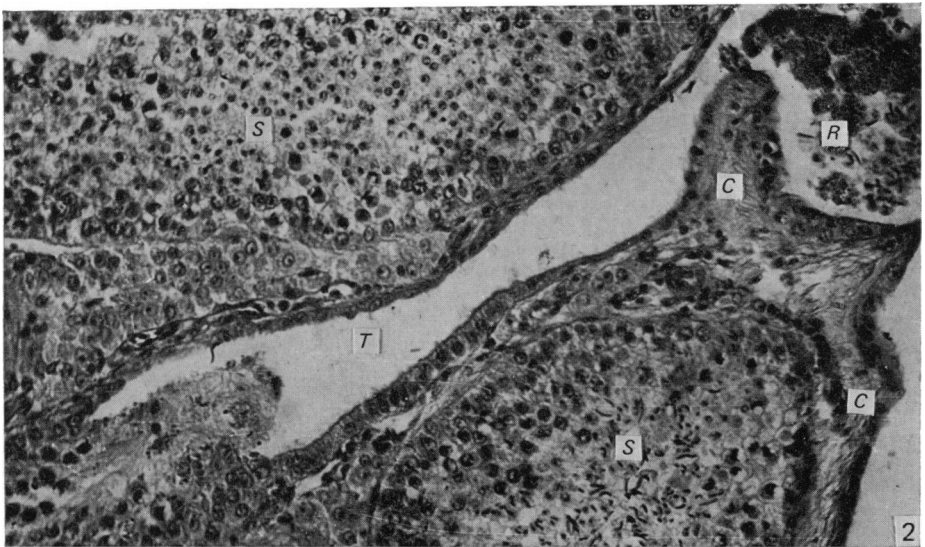


Fig. 2. Part of the testis showing the tubulus rectus (*T*), seminiferous tubules (*S*), rete testis (*R*) and testicular capsule (*C*). Haematoxylin and eosin. $\times 128$.

gradually widens from about mid-way along its length. The ductus terminates in a straight portion with a narrower diameter than either the preceding portion or the succeeding portion (the receptacle) of the duct. The receptacle is about 3 mm in diameter and opens by way of a short papilla into the urodeum of the cloaca.

Figure 1 shows a large part of a longitudinal section of the epididymal region, exhibiting portions of the component ductules and ducts.

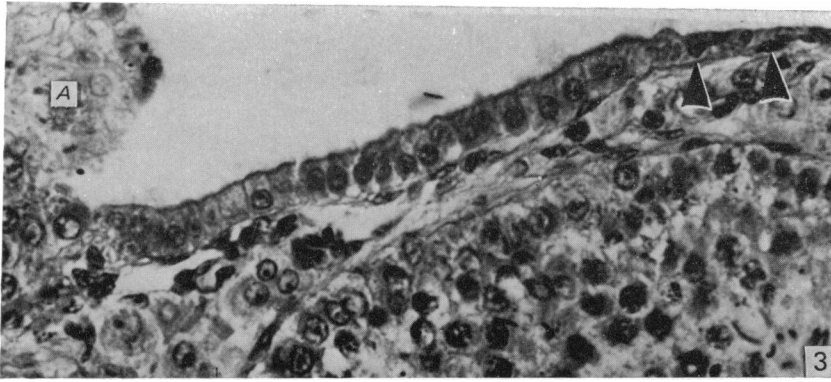


Fig. 3. Higher view of the epithelia of the tubulus rectus and rete testis. *A*, amorphous plug at entrance of seminiferous tubule into the tubulus rectus. Note the change from the cuboidal epithelium in the tubulus rectus to the squamous epithelium in the rete testis (arrowheads). Haematoxylin and eosin. $\times 512$.

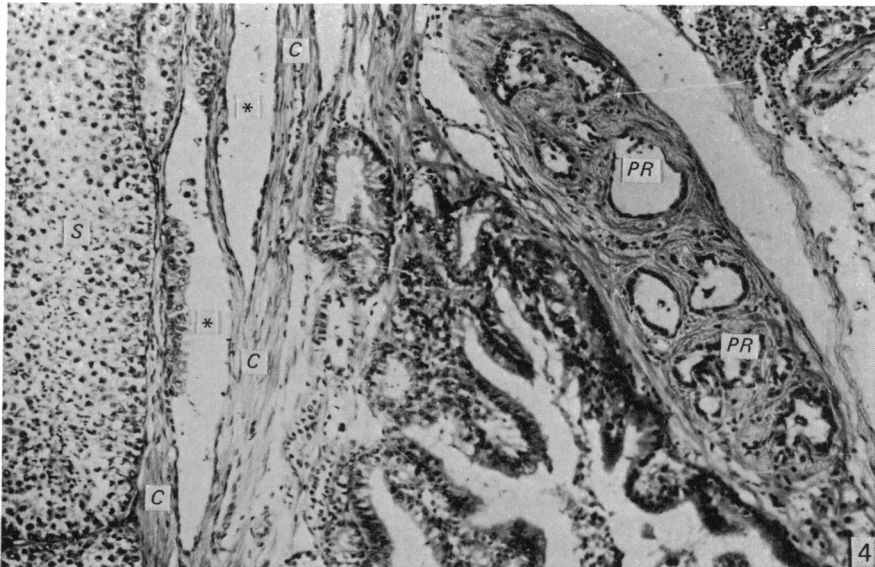


Fig. 4. Rete testis lacunae and sections of seminiferous tubules (*S*) in the testis. Note rete lacunae (*) in testicular capsule (*C*) and in peripheral portion of the epididymal region (*PR*). $\times 128$.

The tubuli seminiferi recti and rete testis

The seminiferous tubules of the testis terminate by becoming straight ducts (tubuli seminiferi recti) (Fig. 2). These ducts are lined by a simple high cuboidal epithelium which becomes squamous as the ducts approach the rete testis into which they open (Fig. 3). The epithelial height varies from $11.2 \mu\text{m}$ at the tubular end to $5.6 \mu\text{m}$ at the rete end of the duct. The straight ducts measure up to $78.4 \mu\text{m}$ in length and $51.1 \mu\text{m}$ in diameter in a good section. A plug of amorphous material projects into the initial, usually expanded, portion of the straight duct. The rete consists of wide spaces or lacunae (Fig. 4) both within the testicular capsule and just outside the capsule, and connects testicular tissue to the epididymal region. The rete is lined by

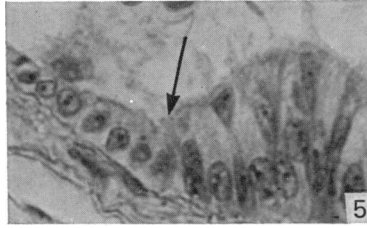


Fig. 5. Rete testis epithelium abruptly changes to proximal efferent ductular epithelium (arrow). Haematoxylin and eosin. $\times 512$.

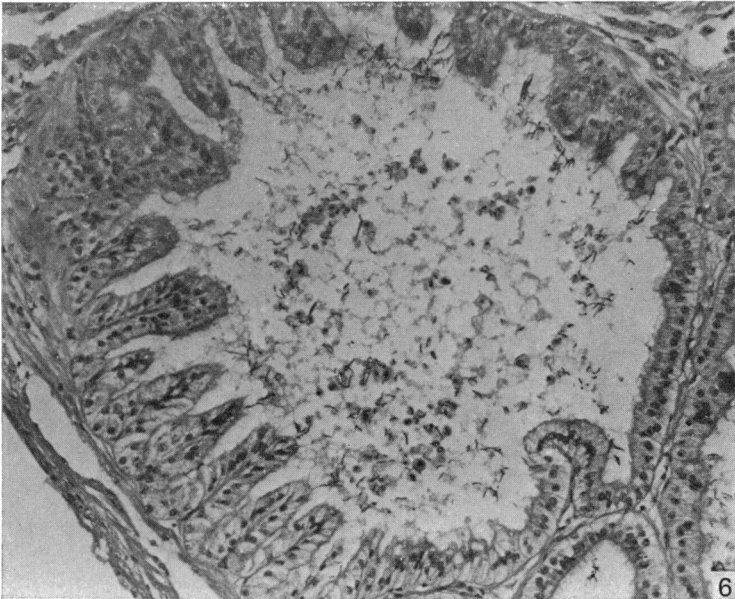


Fig. 6. Proximal efferent ductule showing folding of the epithelial lining. Note the sparse content of germ cells in the lumen. Masson's trichrome stain. $\times 128$.

squamous epithelium $4.2\text{--}7.0\ \mu\text{m}$ thick. The rete spaces are to be found on the lateral as well as on the cranial and caudal surfaces of the epididymal region. The contents of the rete are sparse, mainly spermatozoa and desquamated immature germ cells.

The ductuli efferentes

The rete testis continues into the ductuli efferentes proximales (Budras & Sauer, 1975) where there is an abrupt change in epithelial cell height from the squamous rete cells to the columnar cells of the efferent ductule (Fig. 5).

The proximal efferent ductules have the greatest diameter ($88.2\text{--}253.0\ \mu\text{m}$) of the tubules in the epididymal region, and their epithelial lining ($16.8\text{--}28.0\ \mu\text{m}$ high), as well as the basal lamina, is often thrown into folds which project into the lumen (Fig. 6). There are two main cell types in the epithelium: non-ciliated and ciliated. The non-ciliated cell always extends from the lumen to the basal lamina, and its nucleus, which is round or oval, occupies the basal half of the cell (Fig. 7). Microvilli or stereocilia project from the luminal surface of the cell into the ductular lumen. The ciliated cell does not always appear to reach the basal lamina: thus it often

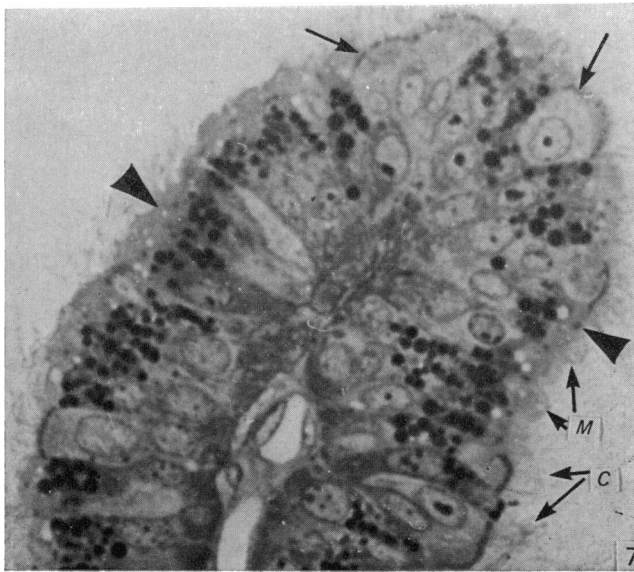


Fig. 7. Epon-embedded section of the proximal efferent ductule. Note the presence of vacuoles and dense globules in the non-ciliated cells (arrowheads). Note also that the ciliated cells (arrows) appear truncated and are light-staining. *M*, microvilli of non-ciliated cells; *C*, cilia of ciliated cells. Toluidine blue. $\times 1600$.

appears to be truncated between adjacent cells. The nuclei of ciliated cells are to be found mostly in the luminal half of the cell; that is why the epithelium is pseudostratified. The shape of the nucleus of the ciliated cell varies from oval to highly elongated, apparently conforming to the overall shape of the basal portion of the cell. Cilia project freely from the luminal cell surface into the ductular lumen. The luminal surface of the ciliated cell is considerably broader than that of the non-ciliated cell. The ciliated cell also often appears more lightly stained than the non-ciliated cell in histological sections.

The lumen of the proximal efferent ductule contains only a few spermatozoa and immature germ cells, and sometimes parts of the desquamated epithelium from somewhere along the ductule itself. The ductule is usually empty.

The ductuli efferentes distales connect the proximal efferent ductules to the ductus epididymidis via the connecting ductules. The distal efferent ductules are by far the most numerous ductules in sections of the epididymal region (Fig. 8), but their diameter ($30.2\text{--}72.8\ \mu\text{m}$) is much less than that of the proximal efferent ductules which occupy more area than any other duct in the epididymal region. The outline of the ductule is almost always circular or oval in cross section, with little or no folding of the wall. The epithelium also consists of ciliated and non-ciliated cells of the same general form as those in the proximal efferent ductule (Fig. 9). The ciliated cells are, however, generally more darkly staining in the distal efferent ductules than those in the proximal ductules. Perhaps the most striking differences which exist between the proximal and distal efferent ductules are to be found in the non-ciliated cells. In Epon-embedded tissue, the non-ciliated cell of the proximal ductule shows numerous apical vacuoles of varying size (Fig. 7). Below these are numerous dark-staining globules, often tightly packed along the length of the cell up to the level of the nucleus. The vacuoles and globules are not seen below the

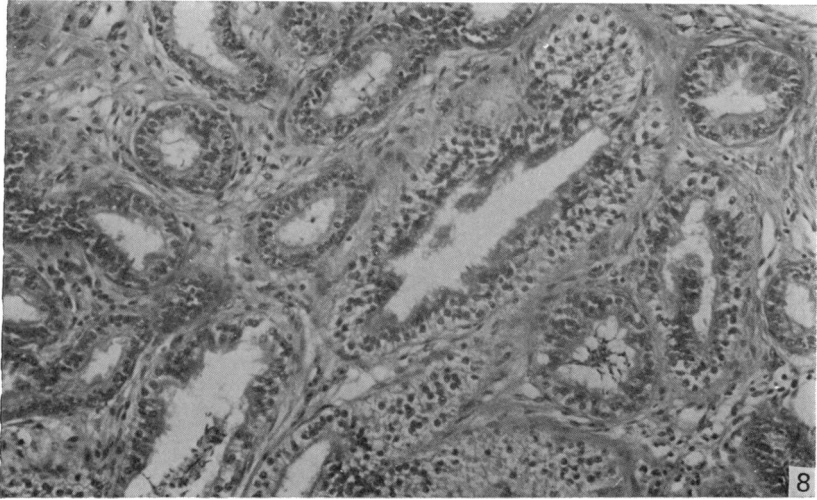


Fig. 8. Transverse sections of distal efferent ductules in the epididymal region. Masson's trichrome stain. $\times 128$.

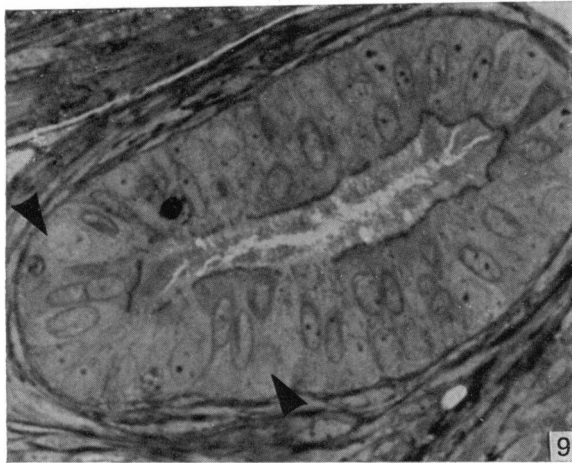


Fig. 9. Epon-embedded section of the distal efferent ductule. Note that neither apical vacuoles nor dense globules are present in the non-ciliated cells (arrowheads). Note also the overwhelming number of ciliated cells in the epithelium. Toluidine blue. $\times 1280$.

nucleus. Neither vacuoles nor globules are seen in the non-ciliated cells of the distal tubules (Fig. 9).

The connecting ductules

These link the efferent ductules with the ductus epididymidis. They are hardly distinguishable from the latter. Both ducts are lined by an epithelium ($21.0\text{--}25.2\ \mu\text{m}$ and $22.5\text{--}44.8\ \mu\text{m}$ high for the connecting ductule and ductus epididymidis, respectively) consisting mainly of non-ciliated cells (Figs. 10, 11). Occasional basal cells, whose nuclei are oval and small, lie on the basal lamina (Fig. 11). The non-ciliated cells of the connecting ductules and ductus epididymidis are columnar, and their nuclei, which are spherical, are located about mid-way along the length of the cell. All the non-ciliated cells have similar staining properties and shape. Unlike the

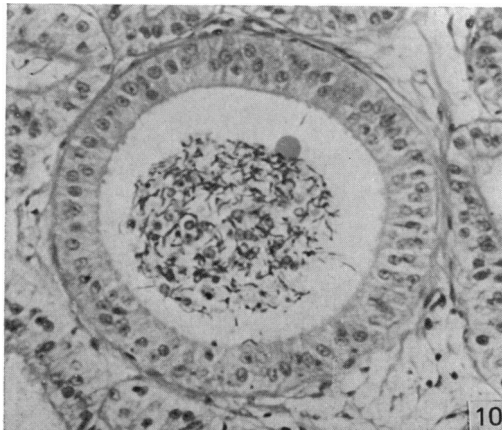


Fig. 10. Transverse section of the connecting ductule showing the dense cellular content. Haematoxylin and eosin. $\times 192$.

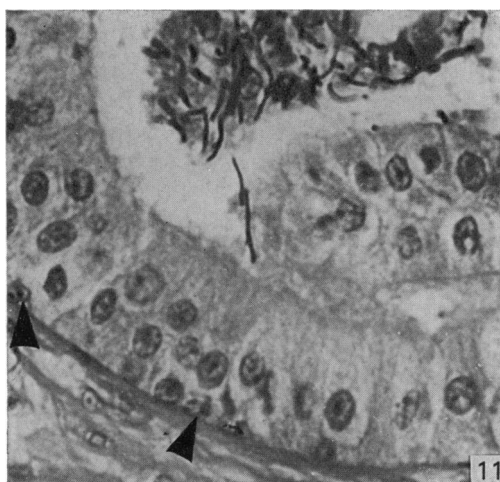

Fig. 11. Part of the ductus epididymidis. Note the dense spermatozoal content and presence of a few basal cells (arrowhead). Haematoxylin and eosin. $\times 512$.

non-ciliated cells of the efferent ductules, they bear only a few short microvilli which are not easily discernible in histological preparations.

The luminal contents of both the connecting ductules and the ductus epididymidis consist of densely-packed spermatozoa interspersed with a few degenerating, more primitive germ cell series (Figs. 10, 11).

The ductus deferens

The ductus deferens arises from the caudal part of the epididymal region where the ductus epididymidis ends. The diameter of the ductus deferens is initially narrow (about $155 \mu\text{m}$) but it begins to increase gradually about mid-way along its length ($639.8 \mu\text{m}$) until it attains its greatest diameter (about 1 mm) just before it opens into the straight pars recta of the ductus deferens. The duct assumes a wavy outline as it progresses caudally. Just before it opens into the receptacle the duct straightens out for about 0.5 cm to form the pars recta. The receptacle is a barrel-shaped

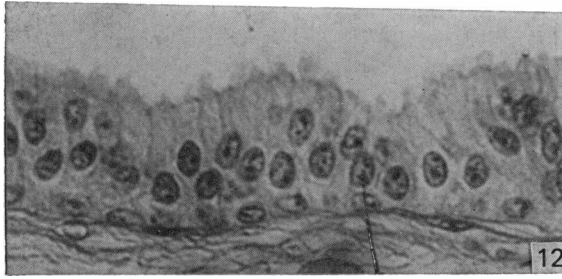

Fig. 12. Middle portion of the ductus deferens. Blebs of the apical cell surfaces are present. Basal cells occur randomly. Haematoxylin and eosin. $\times 512$.

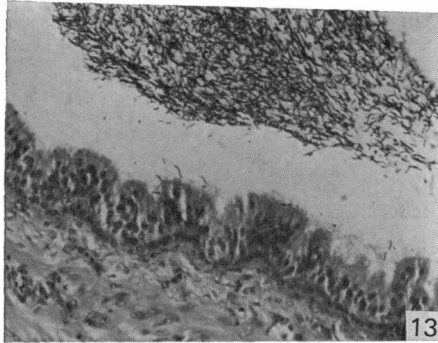


Fig. 13. Caudal portion of the ductus deferens showing folding of the epithelium. Note the definite layer of basal cells. Haematoxylin and eosin. $\times 128$.

enlargement which opens by way of a short papilla into the urodeum of the cloaca. It is about 3 mm in diameter and thick-walled.

The cells of the epithelial lining of the ductus deferens are similar to those of the connecting ductule and ductus epididymidis, namely columnar non-ciliated and basal cells.

The cranial portion of the ductus deferens starts with a folded epithelial lining (about $35.6 \mu\text{m}$ high) involving the basal lamina, as in the ductus epididymidis. But the folds soon smooth out to give a regular epithelium in which several basal cells occur. The epithelium remains in this form in the middle portion of the ductus deferens, except that more basal cells are encountered (Fig. 12). In the caudal portion of the duct, folds of the epithelium, which do not involve the basal lamina to any marked extent, may occur. This has the effect of increasing the surface area of the internal lining of this part of the duct (Fig. 13). A definite layer of basal cells is obvious.

The columnar cells of the cranial and middle, but not the caudal portions of the duct, exhibit small blebs on their luminal surfaces.

The epithelial lining of the receptacle of the ductus deferens consists also of non-ciliated columnar cells whose nuclei are, however, elongated and occupy the middle of the cells (Fig. 14). Several deep grooves or crypts containing spermatozoa are present between folds of the epithelium of this structure (Fig. 15).

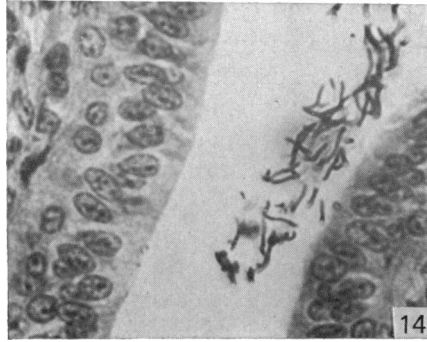


Fig. 14. Epithelial lining of the receptacle of the ductus deferens. Haematoxylin and eosin. $\times 512$.

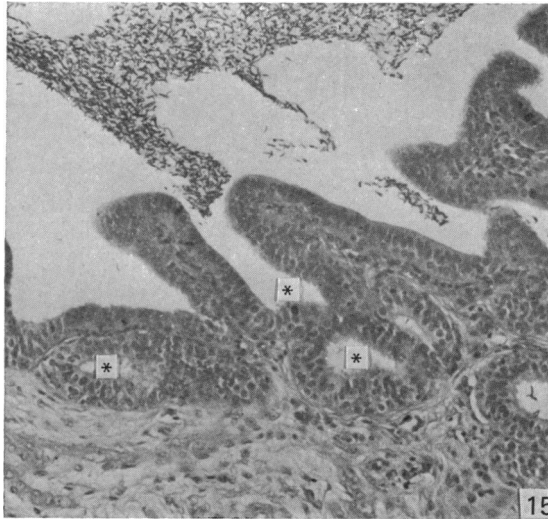

Fig. 15. Low power of the epithelial lining of the receptacle of the ductus deferens. Note the presence of crypts and their cross sections (*). Haematoxylin and eosin. $\times 128$.

DISCUSSION

The epididymal region of the guinea-fowl is similar in general structure and composition to that of the fowl (Stoll & Maraud, 1955; Lake, 1957; Tingari, 1971), turkey (Hess *et al.* 1976) and Japanese quail (Aire, 1979). The nomenclature used for some of the tubules in the present work, namely for the two portions of the efferent ductules, follows Budras & Sauer (1975). It has also been adopted for the Japanese quail (Aire, 1979).

Well-formed intratesticular tubuli recti were encountered in the guinea-fowl. Distinct tubuli recti are also present in the Japanese quail (Aire, 1979). Gray (1937) reported their presence in the domestic fowl, but Tingari (1971) considered them to be absent in that species. A plug of amorphous material projects from the terminal portion of the seminiferous tubule into the lumen of the tubulus rectus in some cases; this is reminiscent of the situation in mammals where Sertoli cells form cytoplasmic plugs which project into the tubulus rectus. Whether the plugs observed in the guinea-fowl are similar in origin and structure to those observed in mammals is not certain.

The rete testis of the guinea-fowl is both intracapsular and extracapsular. An intratesticular portion of the rete was not seen, the greater part being extracapsular.

Budras & Sauer (1975) considered that the efferent ductules of the domestic fowl consisted of two portions, the one (proximal efferent ductule) leaving the rete testis and opening into the other (distal efferent ductule). Tingari (1971) did not describe such a division of the efferent ductules. Both the proximal and distal efferent ductules are lined by an epithelium composed of ciliated and non-ciliated cells. The connecting ductules are lined by an epithelium composed of non-ciliated cells with only a few basal cells. The only difference between the connecting ductules and ductus epididymidis is the greater diameter of the latter. That there are two portions of the efferent ductule is not unique to the bird. Reid & Cleland (1957) and Ladman & Young (1958) described differences in the cellular composition of the proximal and distal segments of the efferent ductules of the rat and guinea-pig, respectively.

The cellular composition of both the proximal and distal efferent ductules is similar, but there are more ciliated cells in the distal than in the proximal segment. Similar observations have been made in the turkey (Hess & Thurston, 1977). There is a remarkable difference between the proximal and the distal efferent ductules in the structure of the non-ciliated cells. As has been found in the fowl (unpublished), Japanese quail (Aire, 1979) and turkey (Hess & Thurston, 1977), in the present study on Epon-embedded material the non-ciliated cells of the proximal ductule have numerous, easily seen vacuoles, and dense globules occupying the supranuclear portion of the cytoplasm of the cell. These organelles are largely absent in the non-ciliated cells of the distal efferent ductule. The present authors, therefore, propose to categorize the non-ciliated cell of the proximal efferent ductule as non-ciliated Type I and that of the distal efferent ductule, non-ciliated Type II. Tingari (1972) and Hess & Thurston (1977) described only the Type I cell in the chicken and turkey, respectively. The connecting ductules, ductus epididymidis and ductus deferens are lined by an epithelium made up of non-ciliated, columnar cells. The present authors, therefore, include this columnar cell in the guinea-fowl in a category of non-ciliated Type III cells: these are equivalent to Tingari's (1972) non-ciliated Type II cells. The non-ciliated Type III cell is different histologically from both the Type I and II cells of the efferent ductules in lacking the vacuoles and globules of Type I, and the long microvilli or stereocilia of both Types I and II. Ultrastructural studies, so far unpublished, have indicated further structural differences between these cell types.

SUMMARY

The epididymal region of the guinea-fowl was studied in sexually mature birds. The structure of the epididymal region was generally similar to that already described for the domestic fowl, turkey and Japanese quail. Well formed, intratesticular tubuli recti were seen connecting the seminiferous tubules with the rete testis. The latter consists of both intracapsular and extracapsular portions. Six main cell types were recognised in the region: the rete testis was lined by squamous cells, the proximal efferent ductules by ciliated and non-ciliated Type I cells, the distal efferent ductule by ciliated and non-ciliated Type II cells, and the connecting ductules, ductus epididymidis and ductus deferens were lined by non-ciliated Type III and basal cells. The cell classification adopted in this study is discussed.

REFERENCES

- AIRE, T. A. (1979). The epididymal region of the Japanese quail (*Coturnix coturnix japonica*). *Acta anatomica* **103**, 305–312.
- BUDRAS, K. D. & SAUER, T. (1975). Morphology of the epididymis of the cock (*Gallus domesticus*) and its effect upon the steroid sex hormone synthesis. I. Ontogenesis, morphology and distribution of the epididymis. *Anatomy and Embryology* **148**, 175–196.
- FARKAS, T. (1965). Interesting facts about the crowned Guinea fowl (*Numida meleagris*). *Fauna Flora, Pretoria* (English edition) **16**, 23–28.
- GRAY, J. G. (1937). The anatomy of the male genital ducts of the fowl. *Journal of Morphology* **60**, 394–405.
- HESS, R. A. & THURSTON, R. J. (1977). Ultrastructure of the epithelial cells in the epididymal region of the turkey (*Meleagris gallopavo*). *Journal of Anatomy* **124**, 765–778.
- HESS, R. A., THURSTON, R. J. & BIELLIER, H. V. (1976). Morphology of the epididymal region and ductus deferens of the turkey (*Meleagris gallopavo*). *Journal of Anatomy* **122**, 241–252.
- LADMAN, A. J. & YOUNG, W. C. (1958). An electron microscopic study of the ductuli efferentes and rete testis of the guinea pig. *Journal of Biophysical and Biochemical Cytology* **4**, 219–225.
- LAKE, P. E. (1957). The male reproductive tract of the fowl. *Journal of Anatomy* **91**, 116–129.
- MARCHAND, C. R. & GOMOT, L. (1973). Étude histologique et cytologique des testicules et des voies génitales du canard de Barberie (*Cairina moschata* L.) en activité sexuelle. *Journées de Recherches Avicoles et Cunicoles*, **12–14**, 127–134.
- REID, B. L. & CLELAND, K. W. (1957). The structure and function of the epididymis. *Australian Journal of Zoology* **5**, 223–246.
- STOLL, R. & MARAUD, (1955). Sur la constitution de l'épididyme du coq. *Compte rendu des séances de la Société de biologie* **149**, 687–689.
- TINGARI, M. D. (1971). On the structure of the epididymal region and ductus deferens of the domestic fowl (*Gallus domesticus*). *Journal of Anatomy* **109**, 423–435.
- TINGARI, M. D. (1972). The fine structure of the epithelial lining of the excurrent duct system of the testis of the domestic fowl (*Gallus domesticus*). *Quarterly Journal of Experimental Physiology* **57**, 271–295.