

A New Composite Gastric Seromuscular and Omental Pedicle Flap

Yuzuru Kamei, M.D., and Shuhei Torii, M.D.

*From the Department of Plastic and Reconstructive Surgery,
Nagoya University School of Medicine, Nagoya, Japan*

Objective

The authors performed a study to see if gastric seromuscular patch elevation is anatomically feasible and to estimate the maximum size of the patch relative to its blood supply.

Summary Background Data

A flap composed of greater omentum and a full-thickness segment of the greater curvature of the stomach, based on the right gastroepiploic artery, was first described in 1977. Elevation of the greater omentum along with a seromuscular patch of stomach has not been reported previously.

Methods

Angiography was performed via the right gastroepiploic artery in a stomach obtained from ten patients who underwent gastrectomy, then india ink was injected. The stomach was then fixed in 10% formalin, and histochemical examination was performed to determine if seromuscular patch elevation was possible.

Result

Results of the angiography and injection experiment of india ink indicated that the territory of a single gastric ramus was approximately 5 cm × 5 cm in both anterior and posterior walls of the stomach. Histology revealed that the gastric rami lay between the muscular layer and the mucosa.

Conclusion

The authors believed that a composite gastric seromuscular patch and omental pedicle flap would be clinically applicable. The authors also believed that the maximum size of the patch was 10 cm × 10 cm. They used this flap to successfully treat three patients with chronic soft-tissue defects—two bronchopleural fistulae and a radiation ulcer.

Elevation of an omental flap along with a full-thickness segment of the greater curvature of the stomach, based on the right gastroepiploic artery, was first described in 1977.¹ An omental flap with a gastric seromuscular patch has not been reported previously. This study

was performed to see if gastric seromuscular patch elevation is anatomically feasible and to estimate the maximum size of the patch relative to its blood supply. We also report its use to repair chronic soft-tissue defects in three patients.

Address reprint requests to Yuzuru Kamei, M.D., Department of Plastic and Reconstructive Surgery, Nagoya University School of Medicine, 65 Turumai Showa-ku Nagoya, 466, Japan.

Accepted for publication February 9, 1994.

MATERIALS AND METHODS

Angiography was performed via the right gastroepiploic artery in a stomach obtained from ten patients

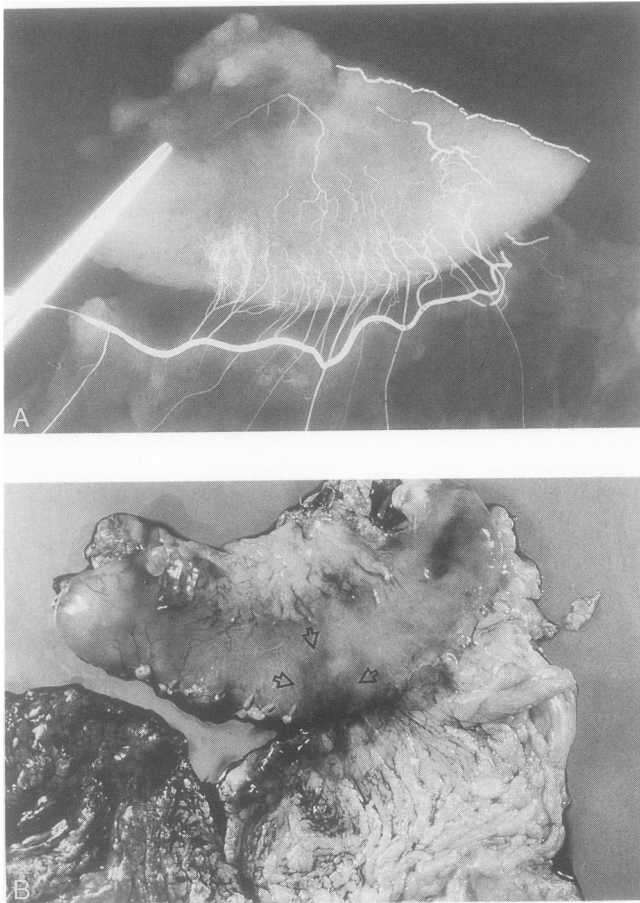


Figure 1. The territory of a single gastric ramus was approximately 5 cm \times 5 cm in both anterior and posterior walls of the stomach. Arrows demarcate the territory of a single gastric ramus.

who underwent gastrectomy, and then india ink was injected. From these studies, the maximum size of a patch, based on a single gastric ramus, was estimated.

The stomach was then fixed in 10% formalin, and his-

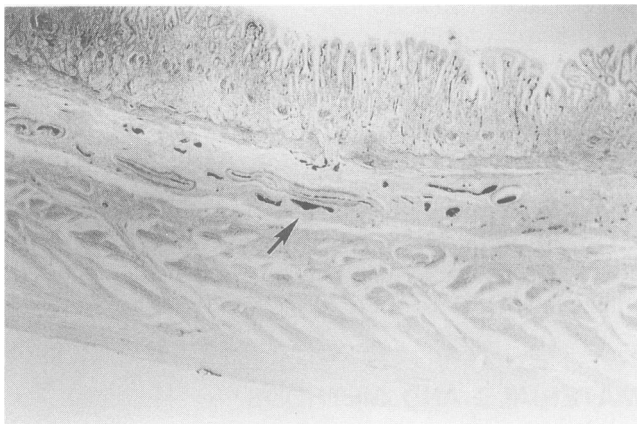


Figure 2. The gastric rami lay between the muscularis and the mucosa. (arrow: india ink)

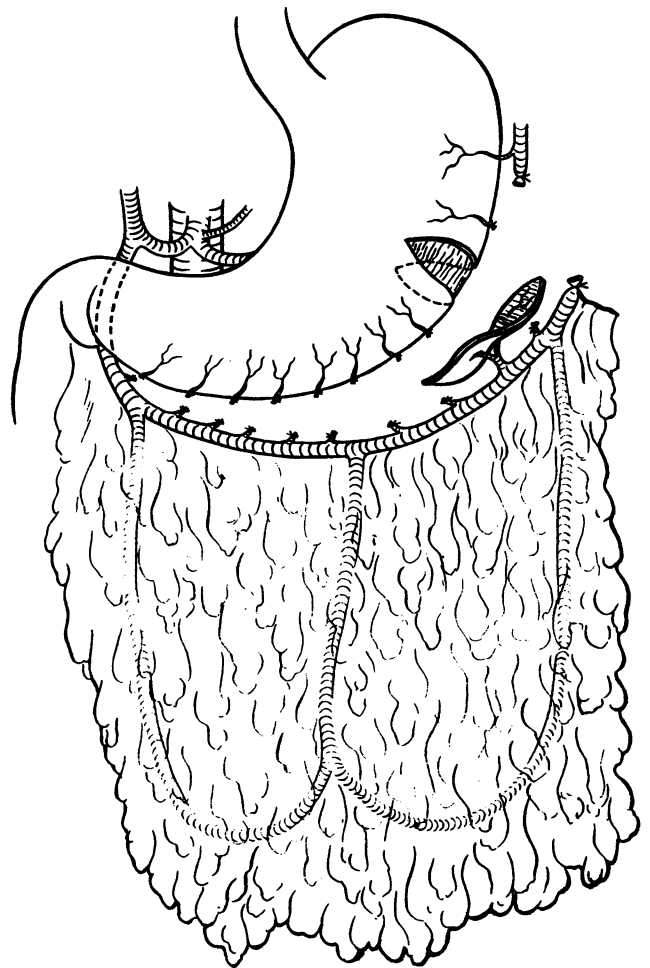


Figure 3. Schematic of composite flap.

tochemical examination was performed to determine if seromuscular patch elevation was possible.

RESULTS

Results of the angiography and injection experiment of india ink indicated that the territory of a single gastric ramus was approximately 5 cm \times 5 cm in both anterior and posterior walls of the stomach (Fig. 1). Thus, we estimated that the maximum size of a single ramus-based patch was approximately 10 cm \times 5 cm.

Histology revealed that the gastric rami lay between the muscular layer and the mucosa (Fig. 2). This suggests that a seromuscular patch could be elevated from the greater curvature of the stomach with sufficient blood supply.

Considering these findings, we believed that a composite gastric seromuscular patch and omental pedicle flap would be clinically applicable (Fig. 3). We also believed that the maximum size of the patch was 10 cm \times 10 cm,

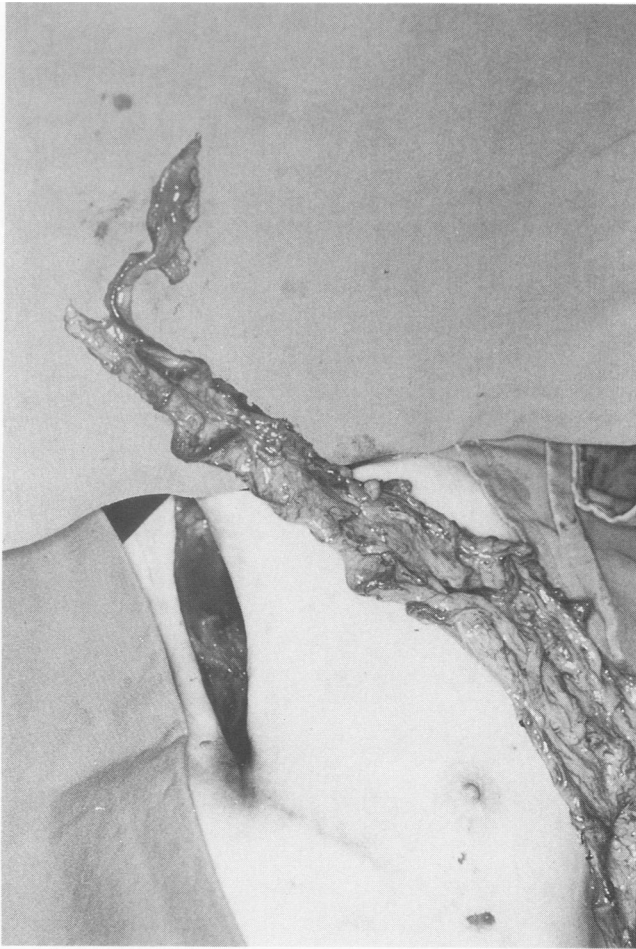

Figure 4. The composite flap in patient 1. The size of the patch was 8 cm × 6 cm, and the length of the pedicle was approximately 30 cm.

because two gastric rami could be taken without serious complications.

We used this procedure to treat three patients—two with bronchopleural fistulae and one with a radiation ulcer after radical mastectomy.

CASE REPORTS

Case 1

A 62-year-old man underwent right upper lobectomy for pulmonary tuberculosis approximately 40 years before admission. From 1985 to 1987, he underwent a thoracoplasty and two thoracostomies for a recurrent bronchopleural fistula. In September 1991, the patient again noticed purulent discharge from the operative scar. The patient was admitted to the hospital for definitive treatment. On admission, the patient was cachectic. Cultures of the discharge showed no growth. Bronchography and fistulography demonstrated a tract between the right middle lobar bronchus (B4) and a moderate-sized abscess cavity. The patient was brought to the operating room and a

thoracotomy was performed in the left semilateral position through the fourth left intercostal space. The abscess cavity was opened and curetted. The end of the fistula entering the cavity was identified, and measured approximately 5 mm in diameter. Next, the abdomen was opened through a vertical midline incision, and a composite gastric seromuscular and omental pedicle flap was elevated (Fig. 4). The size of the patch was 8 cm × 6 cm, and the length of the pedicle was approximately 30 cm. The flap was tunnelled retrosternally into the chest. The gastric patch was used to close the fistula, so that it could withstand 30 mm Hg of bronchial pressure, and the abscess cavity was packed with omentum. The patient had an uncomplicated recovery and was extubated on the 11th postoperative day. Postoperative bronchography showed that closure of the fistula was successful (Fig. 5). Gastroscopy revealed elevation of the mucosa, similar to a submucosal tumor. The patient remains well and has no symptoms of a recurrent fistula 2 years after surgery.

Case 2

A 71-year-old woman underwent right radical mastec-

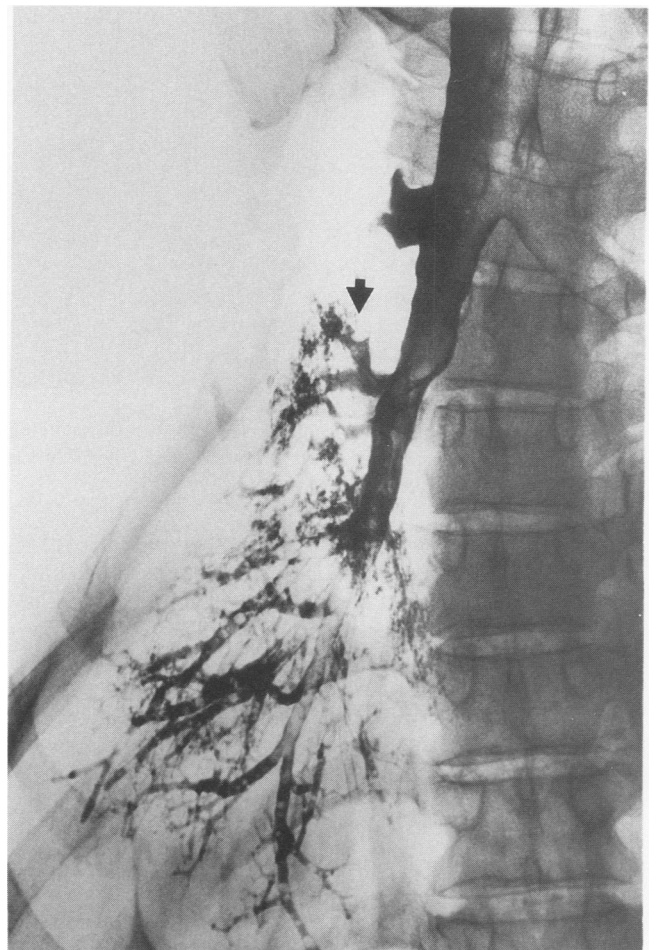

Figure 5. Postoperative bronchography in patient 1 showing that closure of the fistula was successful. (arrow)

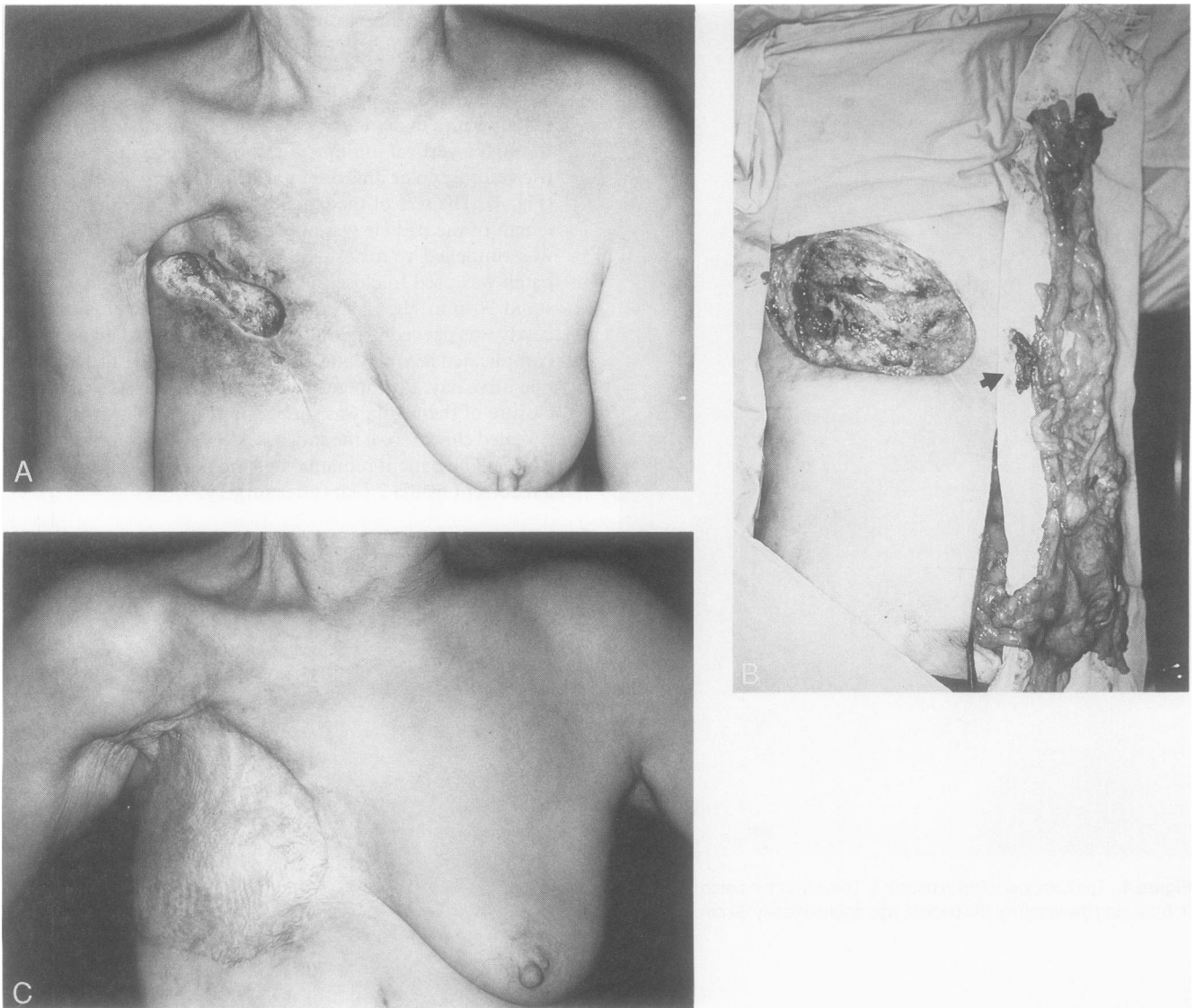


Figure 6. Patient 2. Necrotic skin and ribs 4 through 7 were resected. The flap was elevated, and the postoperative course was uneventful. (arrow: seromuscular patch)

tomy for breast cancer, followed by radiation therapy, 14 years before admission. In 1991, the patient noticed an ulceration of her chest and was treated conservatively as an outpatient without success. On April 2, 1992, the patient was brought to the operating room for definitive repair. Necrotic skin and ribs 4 through 7 were resected, resulting in a soft-tissue defect of the chest wall measuring 17 cm × 11 cm, with a full-thickness defect of 2 cm × 5 cm. As in Case 1, a composite gastric seromuscular and omental pedicle flap was elevated. The seromuscular patch was sutured to the full-thickness defect so that it withstood 50 mm Hg of intrathoracic pressure, and the soft-tissue defect was covered with omentum. A meshed skin graft was applied over the omentum and was dressed with compression bandages. The patient was kept at bed rest for 7 days, and her postoperative recovery was uneventful (Fig. 6).

Case 3

A 70-year-old man underwent left upper lobectomy for lung cancer on April 20, 1992. His postoperative course was complicated by dyspnea and pneumonia, resulting in adult respiratory distress syndrome. On May 6, 1992, a right open lung biopsy was performed, resulting in a pneumothorax. Closed pleural drainage was instituted, but the pneumothorax did not resolve. On May 19, 1992, the patient had purulent discharge from the thoracic drain, and empyema was diagnosed. On May 21, 1992, a thoracotomy was performed through the sixth intercostal space for definitive treatment of the pneumothorax and empyema. There were five bullae of the medial lobulus and two bullae at the inferior lobulus and abscess cavity. After thoracic irrigation, pneumonorrhaphy was attempted, but one bulla could not be sutured because of the friability

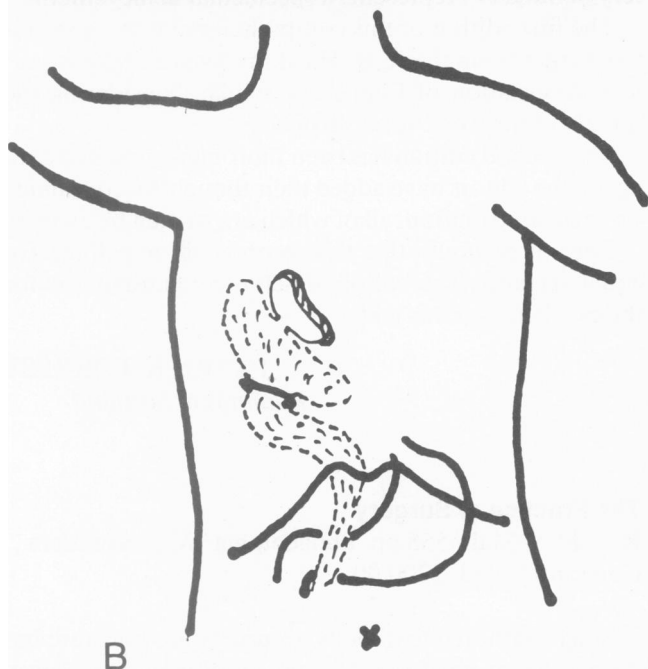
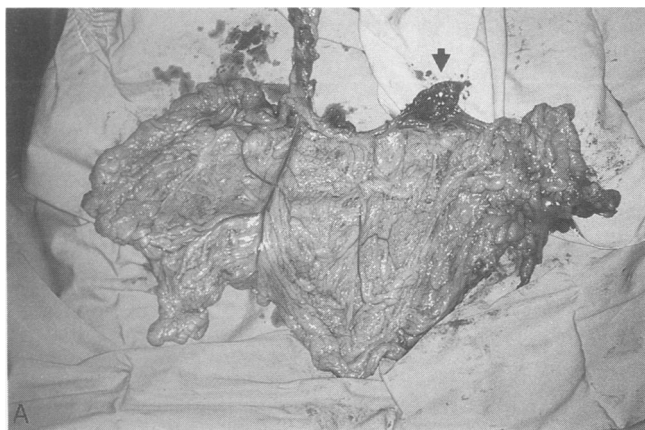


Figure 7. The gastric seromuscular patch, with omentum, was transferred into the chest subcutaneously. (arrow: seromuscular patch)

of the lung. The abdomen was opened through a vertical midline incision, and the composite flap was elevated (Fig. 7). The size of the patch was 10 cm × 5 cm, and the length of the pedicle was approximately 25 cm. The gastric seromuscular patch, with omentum, was tunnelled into the chest subcutaneously. The patch was applied to the bulla, which could not be sutured, so that it withstood 30 mm Hg of bronchial pressure, and the abscess cavity was packed with omentum. The superior lobulus was not observed because of adhesions. After surgery, there was no air leakage, but 3 days postoperatively, the patient developed an air leak and underwent repeat thoracotomy. A bulla was noted at the inferior lobulus, and pneumonorrhaphy was successfully performed. The gastric seromuscular and omental pedicle flap had taken well, and it again

resisted 30 mm Hg of bronchial pressure. The patient had no further air leakage; however, his dyspnea persisted, and he died on June 11, 1992.

DISCUSSION

A flap composed of the greater omentum and a segment of the greater curvature of the stomach, based on the right gastroepiploic artery, was first described in 1977.¹ The gastric mucosa, however, contains goblet cells and other secretory cells that continue to secrete actively, even after loss of vagal stimulation.^{1,2} Furthermore, the maximum size of the patch based on its blood supply has not been studied previously.

Our study demonstrated that a seromuscular patch with sufficient blood supply can be elevated from the greater curvature of the stomach, and that the maximum size of the patch is approximately 10 cm × 10 cm. Using this new procedure, we succeeded in treating three patients with soft-tissue defects.

Several technical points must be stressed. First, the use of a composite gastric seromuscular and omental pedicle flap requires continuity of the right gastroepiploic and omental vessels, and preservation of the gastric rami. When the gastric rami are ligated one by one, an omental flap of sufficient length can be created. While raising the seromuscular patch, it is important to stay in the plane between muscle and mucosa to prevent contamination. Inflation of the stomach with a nasogastric tube facilitates harvest of the seromuscular patch.

The use of muscle flaps to close fistulae or infected wounds has been reported previously.³ However, this type of flap is not well suited to fill a complex space or to provide immediate, air-tight, or water-tight closure. We believe that this new procedure is useful for complex defects, or those that need an immediate, air-tight, or water-tight seal.

Acknowledgments

The authors thank Dr. Kondo, the director of Daido Hospital, for allowing us to use the gastrectomy specimen.

References

1. Parachristou D, Fortner JG. Experimental use of a gastric flap on an omental pedicle to close defects in the trachea, pharynx or cervical esophagus. *Plast Reconstr Surg* 1977; 59:382-385.
2. Baudet J. Reconstruction of the pharyngeal wall by free transfer of the greater omentum and stomach. *Int J Microsurg* 1979; 1:53-59.
3. Miller JI, Mansour KA, Nahai F, et al. Single-stage complete muscle flap closure of the postpneumonectomy empyema space: a new method and possible solution to a disturbing complication. *Ann Thorac Surg* 1984; 38:227-231.