

# Repair of Abdominal Aortic Aneurysm by Transfemoral Endovascular Graft Placement

Wesley S. Moore, M.D., and Candace L. Vescera, R.N.

*From the UCLA Center for the Health Sciences Department of Surgery, Los Angeles, California*

---

## Purpose

The authors describe the initial clinical experience with a new device, approved by the FDA for investigation, for repair of abdominal aortic aneurysm by transfemoral endovascular insertion of an aortic graft.

## Methods

Sixty-nine patients with abdominal aortic aneurysms were screened, and ten were found to be suitable for endovascular grafting. Repair was done in the operating room using general anesthesia. One femoral artery was surgically exposed, and the device, containing a premeasured graft with proximal and distal self-expanding fixation devices, was inserted with fluoroscopic control through an open arteriotomy.

## Findings

Eight of ten patients underwent successful graft placement, and two patients required conversion to an open repair. On follow-up, six of eight patients who underwent graft placement functioned normally, with documented aneurysm thrombosis. Two patients who underwent graft placement functioned normally, with contrast computed tomography evidence of incomplete aneurysm thrombosis, but without further expansion.

## Conclusion

Transfemoral repair is safe and appears to be effective. Phase II study currently is appropriate, with need for long-term follow-up.

---

Since the original report by DuBost et al., which described direct repair of abdominal aortic aneurysm, excision and graft replacement has become the standard surgical management.<sup>1</sup> This has been an extremely suc-

cessful procedure and accounts for approximately 40,000 operations in the United States annually. In spite of this, approximately 15,000 patients die from ruptured abdominal aortic aneurysms in the United States each year, making aneurysm rupture the thirteenth leading cause of death.<sup>2</sup> The reason for the high incidence of rupture is accounted for in two ways. First, the diagnosis may not have been made until rupture occurs, or the diagnosis may have been made, but surgery was withheld because of the patient's increased risk of operation compared with a relatively small aneurysm size. Although there are reports from centers of excellence documenting

---

Supported in part by a research grant from Endovascular Technologies, Inc., Menlo Park, California.

Address reprint requests to Wesley S. Moore, M.D., Professor of Surgery, Chief, Section of Vascular Surgery, Department of Surgery, UCLA Center for the Health Sciences, 10833 LeConte Ave., Room 72-215, Los Angeles, CA 90024-6904.

Accepted for publication April 11, 1994.

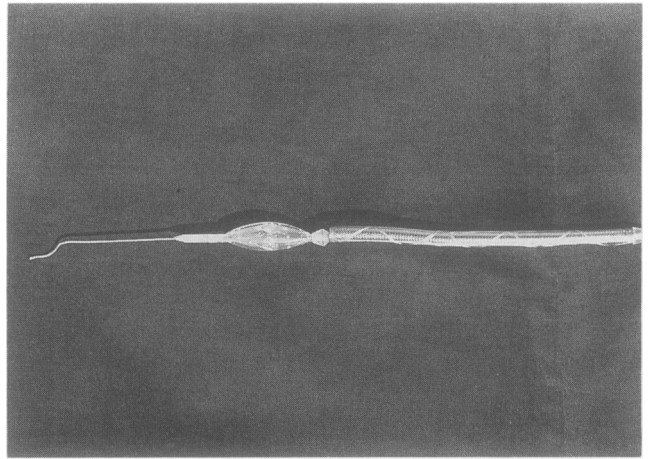
the mortality rate for elective repair to be in the range of 3% to 5%,<sup>3-8</sup> community-based reports suggest that the overall mortality rate may be in the range of 10% to 14%.<sup>9</sup> For this reason, there has been a tendency to recommend elective operation for those patients who are at high risk for rupture. Patients with aneurysms 5.0 cm in diameter or less usually are observed for follow-up until they have documented evidence of further enlargement. Furthermore, patients who are at increased risk for operation or who are believed to have limited life expectancy are usually treated nonoperatively.

The introduction of a simpler and safer approach for direct repair of abdominal aortic aneurysm would make it reasonable to take a more aggressive approach to the management of patients with smaller aneurysms or higher risk patients, and hopefully would reduce the mortality from aneurysm rupture and lower the morbidity and mortality rates for elective repair. This report documented our initial clinical experience with a new device, approved by the FDA for clinical investigation, which permits the repair of abdominal aortic aneurysm by a transfemoral endovascular graft placement.

## METHODS AND MATERIALS

### The Endovascular Graft (EGS) System

The EGS system consists of an introducer sheath and a catheter-based delivery system containing a graft of appropriate size with self-expanding fixation devices at each end. The sheath is designed to be inserted into an open femoral arteriotomy, over a guide wire, and advanced up the iliac artery into the aneurysm. The sheath measures 28 French in diameter. The sheath comes in a partially collapsed configuration and is expanded with an obturator once it has been positioned appropriately. The opening of the sheath is guarded with an iris-type diaphragm that is controlled with a gate valve that provides a blood-tight seal while permitting the operator to perform instrumentation through the sheath. The catheter delivery system is a coaxial unit that contains an intrinsic guide wire at its leading edge, a capsule containing the compressed graft, a retractable capsule jacket that permits graft delivery, and a movable balloon catheter, which is used to seat and drive in the hooks of the proximal and distal fixation devices into the aortic wall. The handle of the coaxial catheter delivery system provides several control options for the operating surgeon. A knob permits the retraction of the capsule jacket to initiate graft deployment once it is in the appropriate anatomic position. The balloon catheter can be manipulated axially to provide centering over the proximal and distal fixation devices and has a port for inflation. Finally, the coaxial system contains a "pusher bar," which permits final adjustment for the point of distal graft deployment.

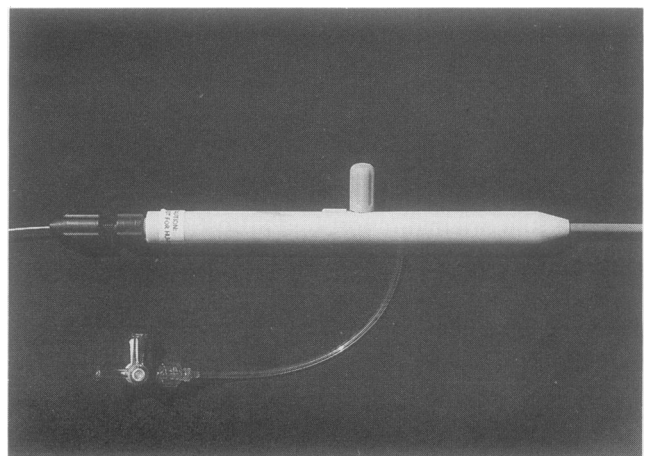


**Figure 1.** Distal end of catheter delivery system. This demonstrates an intrinsic flexible guide wire, an expandable balloon, and a jacketed capsule containing the prosthetic graft.

### Implantation Technique

The patient undergoes a standard work-up and bowel preparation appropriate for conventional repair of abdominal aortic aneurysm. The procedure is done in the operating room using general anesthesia with monitoring appropriate for conventional aneurysm repair. We use the Skytron 3100 operating table (Skytron, Grand Rapids, MI), which has a movable table top and permits eccentric placement of the pedestal to allow for the use of a portable C-arm for imaging of the patient's abdomen. Fluoroscopy is performed with the OEC-Diasonics digital imaging system with road map capability (OEC-Diasonics, Salt Lake City, UT).

The patient is positioned supine on the operating ta-



**Figure 2.** Handle of the coaxial delivery system. This demonstrates the knob that can be used to retract the jacket for graft delivery. Access for inflation of the balloon also is available, as well as a port for flexion and angiographic imaging.

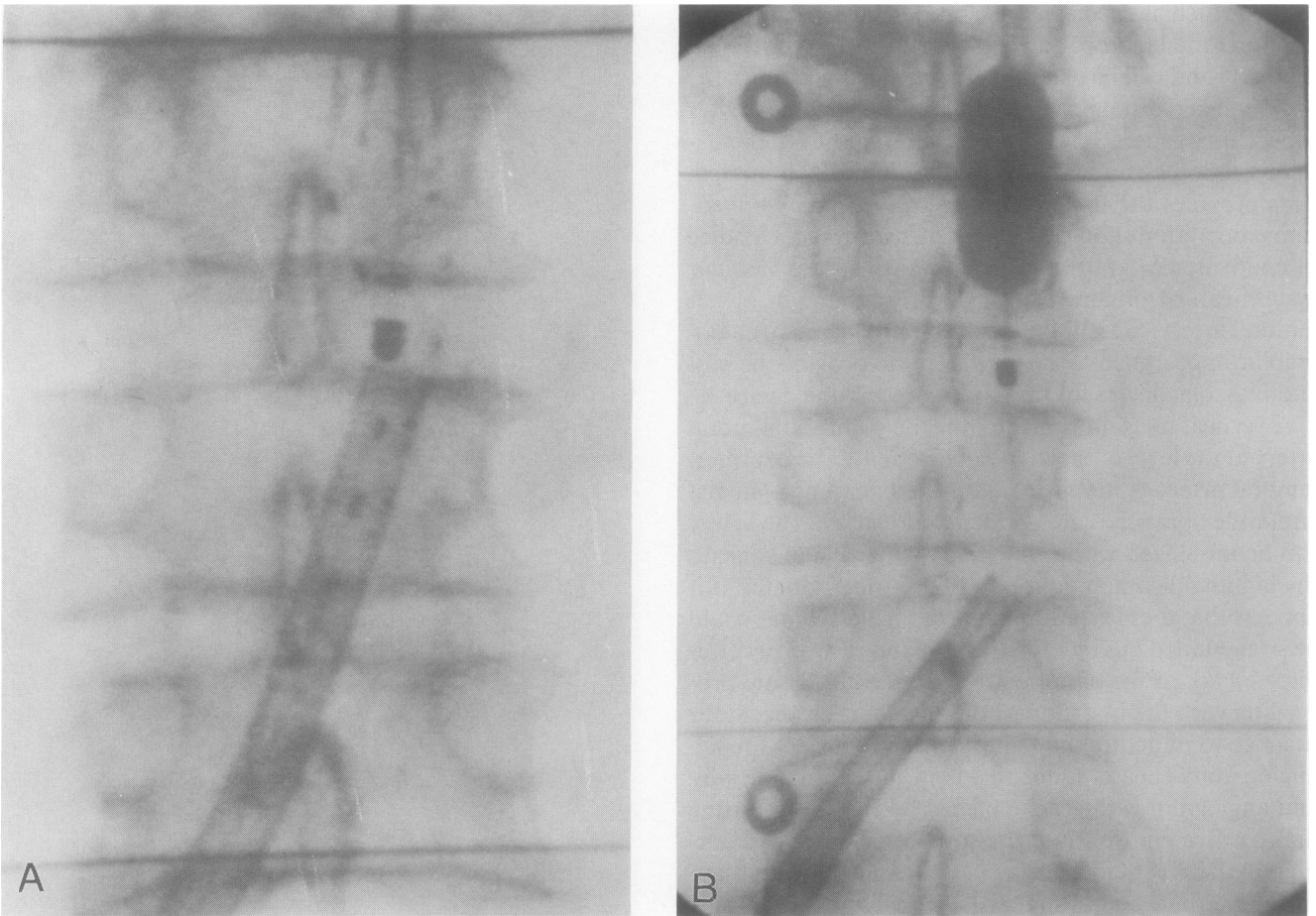
ble, on which has been placed a marker board. The board has horizontal radiopaque cursors that can be controlled remotely and will be used to fluoroscopically identify the proximal and distal positions for graft deployment. After satisfactory general anesthesia has been induced, the patient's abdomen and both groins are surgically prepared. This provides the opportunity to convert to a conventional operation should that need arise during the course of endovascular grafting. The approach to the vascular system can be obtained through either the right or left femoral artery. Selection is based on preoperative angiographic appearance of the iliac artery to provide the best endovascular access for the guide wire and the device.

A vertical incision is made over the common femoral artery at the level of the inguinal ligament. The common femoral artery is mobilized, and the lateral and medial circumflex branches are divided and ligated. The artery can be mobilized within the perivascular plane beneath the inguinal ligament and into the retroperitoneum if it appears that there is redundancy of the vessel that could be straightened out by mobilization and provide a better directed access for placement of the sheath. Before proceeding with the insertion of the sheath, it has been our practice to puncture the femoral artery with a 9-French angiography sheath. Once this is in place, a guide wire and angiogram catheter are passed up the sheath, using fluoroscopic control, into the suprarenal aorta. An aortogram then is obtained using pressure injection and capturing the image with digital fluoroscopy on both tape and superimposed road mapping. Once the road map image has been obtained, the cursors in the marker board then are positioned to demonstrate the optimum location for the proximal and distal extremities of the graft. Then the guide wire is reinserted through the angiogram catheter up into the suprarenal aorta, and the angiogram catheter and sheath are removed. Five thousand units of heparin are given; the femoral artery is clamped proximally and distally, and an oblique transverse arteriotomy then is made, incorporating the puncture site from the angiogram sheath. The 28-French introducer sheath that is a component of the EGS system then is passed over the guide wire, through the femoral arteriotomy, up the iliac artery, and into the abdominal aorta. The distal end of the sheath is positioned in the distal portion of the proximal neck, providing the best and most direct access for the coaxial graft/catheter delivery system. Then the obturator is advanced to fully expand the sheath; it is left in place for 2 minutes to be certain that the sheath will remain expanded fully. Then the obturator is removed, leaving the sheath in place. Hemostasis is achieved by the valve at the working end of the sheath. The coaxial catheter delivery system containing the graft of appropriate diameter and length then is passed up the sheath, using fluoroscopy, until the proxi-



**Figure 3.** Operative photograph showing the introducer sheath in place in the femoral artery. The coaxial catheter has been passed up the sheath with the proximal valve maintaining hemostasis.

mal fixation device, which is radiopaque, is positioned at the optimum point of the proximal aneurysm neck, as determined previously by cursor placement. The capsule jacket then is retracted carefully, and the proximal self-expanding attachment system will spring open and engage the aorta. Then the balloon angioplasty catheter is activated for positioning and drawn through the graft so that it is positioned and centered across the proximal stent. The catheter is inflated with radiopaque contrast material so that it can be observed fluoroscopically. The intraluminal balloon pressure is maintained at 2.0 atmospheres of 1 minute. This serves to drive the pins that are around the circumference of the attachment system into the wall of the aneurysm for purposes of fixation. Then the balloon is deflated, rotated, and inflated a second time. This is done to make certain that there is no eccentricity of force used to seat the proximal fixation device. With the balloon expanded, the introducer sheath, which initially had been placed within the aneurysm, is backed out so that the sheath lies no further proximally than the



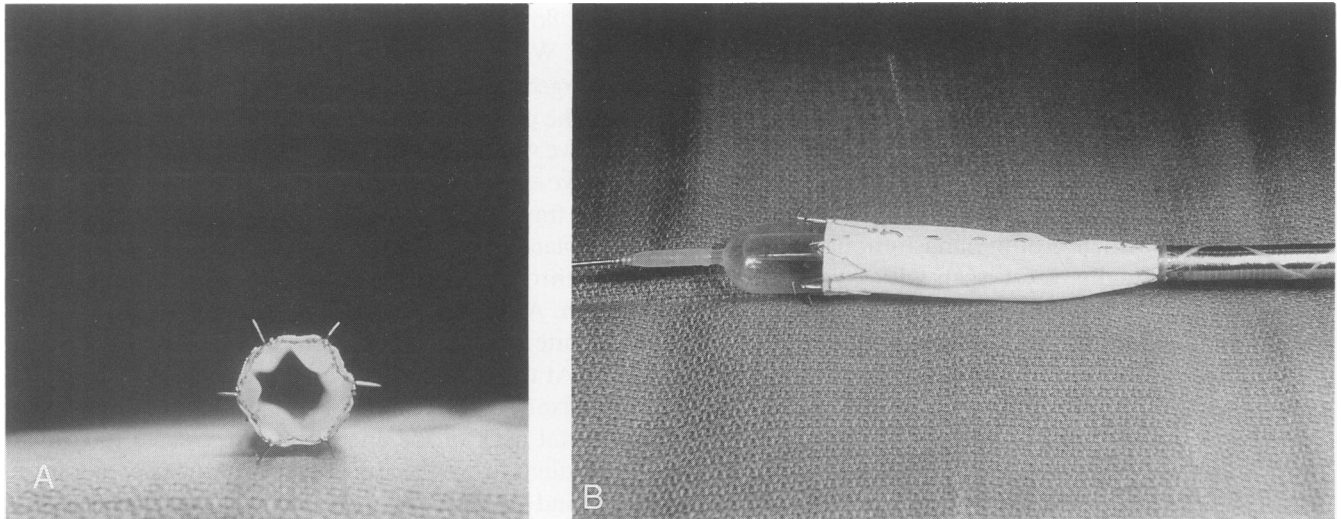
**Figure 4.** (A) Operative photograph taken from the digital imaging system demonstrating the introducer sheath within the abdominal aorta. Horizontal lines proximally and distally represent the cursor markers for proximal and distal deployment. The proximal fixation device has just been deployed opposite the proximal cursor. (B) The balloon has been positioned across the proximal fixation device and inflated. This is centered across the proximal cursor.

common iliac artery. The capsule jacket is fully retracted, and the catheter is withdrawn to deploy the distal attachment system appropriate to the distal cursor. The balloon catheter is deflated and pulled distally to be positioned opposite the distal attachment system. Balloon inflation then is performed in a similar manner as the proximal inflation described. This serves to seat the pins of the distal attachment system within the distal neck of the aneurysm. Once this is completed, the catheter system is withdrawn through the sheath. An angiography catheter then is passed through the sheath, over a guide wire, and positioned in the suprarenal aorta. Then a completion angiogram is obtained that demonstrates the position and function of the graft and looks for any evidence of incomplete circumferential seal with perianastomotic reflux into the aneurysm sac. Once it has been determined that there has been satisfactory graft deployment and function, the sheath is removed, the femoral

arteriotomy is repaired, and the incision is closed. The patient then is sent to the recovery room to awaken from general anesthesia and is transferred to a regular room. Intensive care is not required. The patient may have a regular meal that evening and will be discharged the following morning, after postoperative imaging studies have been obtained.

### Criteria for Patient Selection

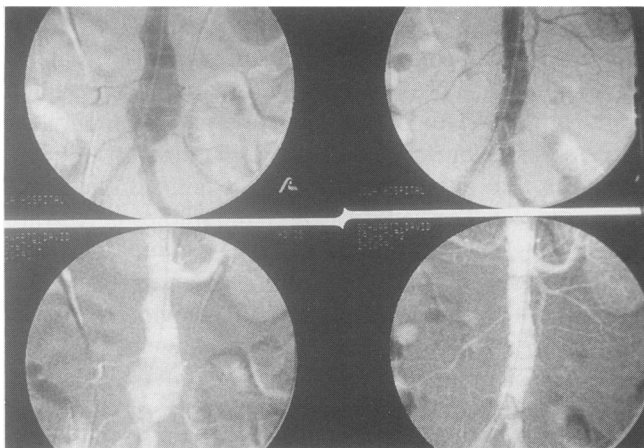
Currently, the EGS system is designed to place a tube graft and therefore, is appropriate only for patients whose aneurysms are confined to the infrarenal abdominal aorta. For the patient to be a suitable candidate, there must be an anatomically defined proximal and distal neck to the abdominal aortic aneurysm. The neck must not be larger than 24.0 mm in diameter, and ideally, should be 1.5 cm or longer in length. The length of the



**Figure 5.** (A) End-on photograph of the prosthetic graft to demonstrate the fixation pins in profile. (B) The balloon within the graft is being inflated; this demonstrates how the pins will be driven into the wall of the aorta.

aneurysm, from proximal to distal neck, must not exceed 13.0 cm. The iliac system must have a diameter of approximately 8.0 mm or larger to accommodate the working sheath. Finally, preoperative angiography must demonstrate the absence of a collateral mesenteric flow pattern to assure us that there is not dependency on flow through the inferior mesenteric artery to maintain intestinal circulation. Ideally, the inferior mesenteric artery would be occluded. However, patency of the inferior mesenteric artery is acceptable, providing that the angiogram demonstrates a normal celiac and superior mesenteric artery.

The patient's general health must be sufficiently good to make him/her a candidate for conventional repair of



**Figure 6.** The preoperative road map image of a patient with abdominal aortic aneurysm on the left followed by the completion mapped image after insertion of the endovascular graft on the right.

abdominal aortic aneurysm because the need to perform conventional repair may be precipitated by a mistaken deployment of the endovascular graft. It is conceivable, in the future, that this device may be used for poor-risk patients, once greater experience has been obtained to provide assurance that the need for conversion to an open operation would be unlikely.

### Methods of Patient Assessment and Follow-Up

Once a patient has been documented to have an abdominal aortic aneurysm, either by physical examination or ultrasound study, a computed tomography (CT) scan is obtained of the abdominal aorta using 5.0 mm cuts. The CT scan is examined for the presence of a proximal and distal neck of appropriate diameter. If it appears that the patient has an anatomic configuration that is suitable for endovascular grafting, and if the patient is a reasonable candidate for operation, then the next procedure would be a contrast angiogram. At our center, we have preceded the contrast angiogram with a magnetic resonance angiogram for study purposes. The contrast angiogram must be performed using a marker catheter containing radiopaque marks at a measured interval. This provides the opportunity to confirm the length of the graft required and to reconfirm the diameter compared with CT examination. The use of a marker catheter corrects for magnification factor and parallax.

A rigid protocol for postoperative evaluation has been defined as a part of a Phase 1, FDA-approved, clinical trial. On the first postoperative day, the patient obtains a plain film of the abdomen, which documents the exact



anatomic position of the graft as seen by the radiopaque self-expanding fixation devices at each graft extremity and by a pair of parallel radiopaque lines that go the length of the graft and are located 180° apart. This demonstrates that the graft is oriented properly and that there has been no twist or rotation. Then a color-flow duplex scan is obtained to demonstrate flow through the graft and to look for evidence of perianastomotic reflux into the aneurysm. Finally, a CT scan with contrast is obtained to document the position of the graft, its function, and the presence or absence of contrast-enhanced blood within the aneurysm sac. The patient is re-examined at 6 weeks by both physical examination as well as plain film, color-flow duplex, and contrast-enhanced CT study. This sequence is repeated at 6 months and again at 1 year. If there is any concern about the findings on any of these studies, a contrast angiogram may be obtained at any time. This follow-up permits not only the documentation of the functioning of the graft but also the condition of the defunctionalized aneurysm sac with respect to the presence or absence of continued contrast enhanced blood and aneurysm size.

## RESULTS

### Population Screened

In the 12-month interval from October 1992 through September 1993, 69 patients with diagnosed abdominal aortic aneurysms were screened in regard to their candidacy for endovascular grafting. Their ages ranged from 51 to 88 years, with a mean age of 71 years. The maximum diameter of their aneurysms ranged from 3.5 to 11.0 cm, with a mean of 5.8 cm.

Of the patients screened, nine were identified as having anatomic and clinical characteristics, making them satisfactory candidates for the EGS system. One patient with documented evidence of recent expansion of a 10.5 cm symptomatic abdominal aortic aneurysm who was a pulmonary cripple on home oxygen was entered into the study on a compassionate use basis. The clinical characteristics and measurements of these ten patients are summarized in Table 1.

The first EGS device was deployed at UCLA Medical Center on February 10, 1993. From that date until November 1993, an additional nine devices were inserted at UCLA, bringing this to a series of ten patients. Eight of the ten grafts were considered an immediate success and have been entered into the follow-up protocol. Two graft deployments were considered failures. The first failed deployment occurred in a 71-year-old white male with a 5.0 cm abdominal aortic aneurysm. After graft deployment, the completion angiogram appeared to show constriction of the graft. In spite of this, the patient had ex-

cellent flows through the graft and had normal femoral pulses. We elected to observe this patient, and he was discharged on the first postoperative day. Three days later, the patient returned complaining of back pain. Because we were concerned about the angiographic appearance, we elected to convert that patient to an open repair. At the time of operation, it was noted that the graft had been placed between the aneurysm sac and the laminated thrombus rather than within the lumen of the aneurysm. A second patient failure occurred in a 76-year-old white male with a 7.0 cm abdominal aortic aneurysm. At the time of deployment, it was evident that the distal fixation device did not seat in what we thought was the distal neck of the aneurysm. We elected to convert that patient to an open repair. At the time of exploration, we found that in fact, there was no distal neck present and that the iliac arteries were aneurysmal. The conventional repair required a bifurcated graft.

The operating room time for a successfully deployed endovascular grafts ranged from 104 to 255 minutes, with an average of 174 minutes. Transfusion was not required. After awakening in the recovery room, all patients were transferred to regular ward care, and none required intensive care. None of these patients suffered cardiac, pulmonary, or wound complications. Six of these patients were discharged from the hospital on their first postoperative day, and two patients were discharged on the second postoperative day.

Fifty-nine patients were deemed unsuitable for endovascular grafting at this time. The reasons are summarized in Table 2. The most common reason for rejection was absence of a distal neck.

### Follow-Up Status

There has been one late death, which occurred in the patient with advanced pulmonary disease, in whom the graft was placed on a compassionate basis. This patient died 8 months postoperatively from respiratory failure. Unfortunately, a postmortem examination was declined by the family. Seven of the eight patients who underwent successful implantation are alive at the time of this presentation. Follow-up clinical and imaging studies have been completed on schedule. Imaging studies were available through 6 months for the one patient who died. Four of the eight patients had normal completion angiography at the time of operation with no evidence of perianastomotic reflux. Postoperative follow-up CT scans have demonstrated no evidence of contrast enhancement within the aneurysm sac, and color-flow duplex scan studies demonstrate normal graft flow without perianastomotic reflux. Four patients demonstrated small areas of perianastomotic reflux, either on completion angiogram, color-flow duplex, or contrast-enhanced CT ex-

**Table 1. PATIENT/GRAFT CHARACTERISTICS**

Patient	Age (yrs)	Aneurysm Diameter (cm)	OR Time (mins)	Graft Diameter (mm)	Length (cm)
1	74	4.9	166	18	10.5
2	58	4.9	179	24	12.5
3	82	10.5	104	24	11
4	80	5.5	170	24	11
5	75	6.2	203	22	10.5
6	71	5.8		Converted to open operation	
7	77	5.0	255	22	11
8	76	6.0		Converted to open operation	
9	84	5.0	189	22	10.5
10	73	5.0	127	24	13

amination. Of these, two continue to demonstrate perianastomotic reflux, but have shown no evidence of aneurysm enlargement—one at 1 year and one at 6 months after implantation. The other two patients demonstrated perianastomotic reflux or aneurysm contrast enhancement at their 6-week study, but both had gone on to resolution with complete aneurysm thrombosis at the time of their 6-month examination. Therefore, six of eight patients, either immediately or during the course of follow-up, have completely normal functioning grafts without any function of their thrombosed aneurysms. Two patients continue to demonstrate some evidence of perianastomotic reflux, but have shown no evidence of aneurysm enlargement. These two patients continue to be observed closely.

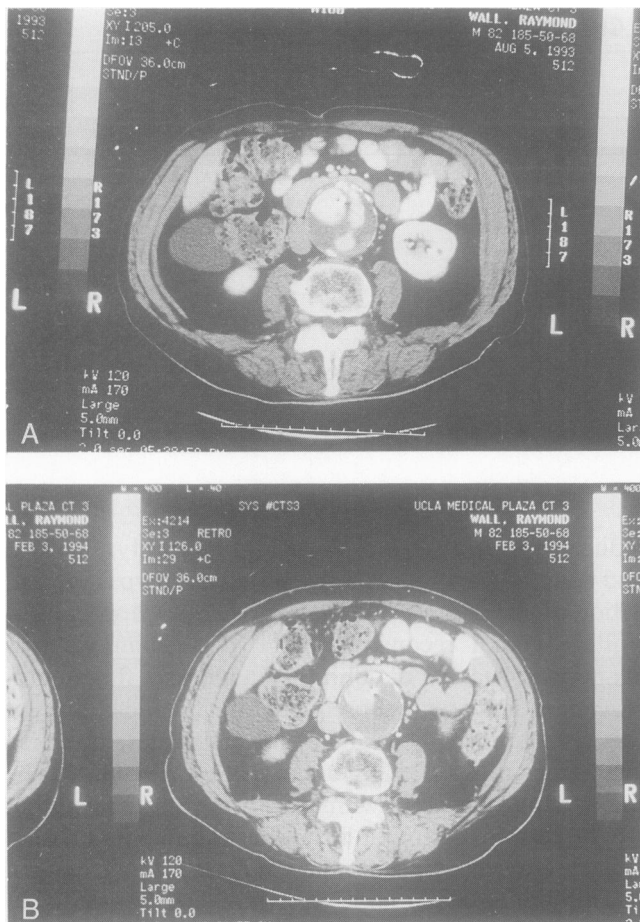
## DISCUSSION

There have been many attempts to simplify the management of patients with abdominal aortic aneurysms to

reduce perioperative morbidity and mortality. Blaisdell and colleagues introduced the concept of bypass and ligation of aneurysm using the extracavitary approach of axillobifemoral reconstruction.<sup>10</sup> This technique was abandoned because of continued aneurysm function of several patients with subsequent rupture. The concept was re-examined by Leather and colleagues, who also abandoned this procedure because of poor results.<sup>11</sup> The use of an in-lying graft with a rigid ring at each end that would permit the simple insertion and securing with a ligature placed outside around the neck of the aneurysm in a circumferential manner also has been reported.<sup>12</sup> In the late 1970s and 1980s, several groups began to experiment with the concept of transfemoral endovascular placement of a graft within the aorta bridging the aneurysm. Cragg and co-workers described their experience with a Nitinol wire prosthesis placed percutaneously through the femoral artery using a large introducer sheath.<sup>13</sup> Balko and colleagues described their experience with transfemoral placement of a polyurethane graft. This was introduced through a 15-French catheter at the time of repair and subsequently removed during its transabdominal repair. The experiment was done to demonstrate the feasibility of maneuvering the graft into position.<sup>14</sup> The concept of inserting the graft with the metallic stents at either end has been considered, and at least four patents exist for this process.<sup>15-18</sup> Ultimately, the leadership in this field was taken by Parodi and colleagues, who designed an aortic prosthesis with a modified Palmaz stent at each end of the graft that could be delivered through a sheath and expanded into position using a balloon catheter. Parodi's laboratory experience dated to 1976, and he reported his first clinical experience in 1991.<sup>19</sup> The EGS system, described in this report, was developed and patented by Lazarus in 1987. It currently is the only device that has received FDA approval for investigation. The first clinical implantation of this

**Table 2. REASONS FOR PATIENT DISQUALIFICATION**

Reason	No. of Patients
No distal neck proximal to bifurcation	34
No proximal neck	4
Iliac artery diameter too small	4
Contained aneurysm rupture	4
Thoraco-abdominal aneurysm	3
Clinical contra-indication for operation	3
Abdominal aneurysm too small	3
Proximal neck too large for available grafts	2
Aberrent renal artery originating from aneurysm	1
Concomitant iliac artery aneurysm	1



**Figure 7.** (A) A 6-week CT scan of a patient undergoing transfemoral endovascular repair of an abdominal aortic aneurysm. The contrast enhancement outlines the graft, but also shows extraluminal contrast within the aneurysm. (B) The same patient at 6 months. The CT scan shows that all of the contrast is within the graft, and there is no evidence of contrast-enhanced blood within the aneurysm. The aneurysm is completely thrombosed.

device was performed at UCLA Medical Center on February 10, 1993. Since then, an additional nine devices have been deployed. Eight of these ten were successful, and the early follow-up was sufficiently encouraging to the FDA that they have given approval to proceed with the Phase II portion of this study. During the Phase II portion of the study, a total of 15 centers will randomly allocate patients with abdominal aortic aneurysms, suitable for EGS implantation, to either conventional operation or endovascular graft repair. The objective of the Phase II portion of the study will be to compare the 12-month morbidity, mortality, and cost between the experimental and control groups. It also will permit the opportunity to accumulate a large number of patients with transfemoral endovascular graft placement for intermediate and late follow-up. There are a number of unanswered questions that must be clarified before this tech-

nique can be considered sufficiently competitive with conventional operation, and before its unrestricted use. First of all, the security of proximal and distal fixation must be established over a period of long-term observation. Back bleeding from patent lumbar arteries and the inferior mesenteric artery may or may not contribute to continued pressurization of the aneurysm sac with maintenance of patency and potential for future rupture. It is not known at this point how frequent these vessels will undergo thrombosis after successful endovascular graft deployment. Therefore, continued observation of patients in the experimental group is essential. To date, there has been no evidence of aneurysm enlargement, and hopefully that will prove to be the case during the course of longer follow-up.

The tube graft, in its current configuration, clearly has major limitations with respect to patients presenting with abdominal aortic aneurysms. This is exemplified by the fact that only 10 of 69 patients screened were found to be suitable for endovascular graft deployment. The most common cause of rejection was the absence of a distal neck. Current attempts at developing a bifurcated graft for endovascular graft replacement are well advanced. Experimental reports have already been published,<sup>20</sup> and anecdotal experience of patients treated with the bifurcated graft in Europe have been described informally. Once a reliable bifurcated graft system is available, applicability of endovascular grafting to a larger portion of the aneurysm population will be possible.

The use of endovascular grafting is not limited to patients with abdominal aortic aneurysms. Reports of using endovascular grafts to line segments of artery after balloon angioplasty and bridging arteriovenous fistulae already have been published.<sup>21,22</sup> There also has been an experience with endovascular graft repair with aneurysms of the descending thoracic aorta.<sup>23</sup>

The final area of concern in this new and rapidly emerging field has to do with the issue of training. At the present time, this is clearly a surgical procedure, but additional skills of guide wire manipulation, catheter placement, fluoroscopic imaging, and angiography definitely are required. Individual surgeons may possess all of these skills, or it may be reasonable to use a team approach, incorporating a surgeon and an interventional radiologist to perform these procedures. Both options are workable, and a decision of which option to use will be based on individual institutional experience. During the investigative phase of this device, there is a window of opportunity to develop guidelines for the use of endovascular graft technology and the development of a registry so that the cumulative experience with endovascular graft placement may be documented carefully. The national vascular societies, with cooperation of the Na-



tional Institutes of Health and the Food and Drug Administration, already have taken the leadership in the development of these two areas of endeavor.

## References

- Dubost C, Allary M, Oconomos N. Resection of an aneurysm of the abdominal aorta: reestablishment of the continuity by preserved human arterial graft with the result after five months. *Arch Surg* 1952; 64:405–408.
- Goldstone J. Aneurysms of the aorta and iliac arteries. In Moore WS, ed. *Vascular Surgery: A Comprehensive Review*. Philadelphia: WB Saunders and Co, 1993, p 401–423.
- O'Donnell TF Jr, Darling RC, Linton RR. Is 80 years too old for aneurysmectomy? *Arch Surg* 1976; 111:1250–1257.
- Whittemore AD, Clowes AW, Hachtman HB, Mannick JA. Aortic aneurysm repair reduced operative mortality associated with maintenance of optimal cardiac performance. *Ann Surg* 1980; 120: 414–421.
- Crawford ES, Saleh SA, Babb JW III, et al. Infrarenal abdominal aortic aneurysm: factors influencing survival after operations performed over a 25-year period. *Ann Surg* 1981; 193:699–709.
- Reigel MM, Hollier LH, Kazmier MJ, et al. Late survival in abdominal aortic aneurysm patients: the role of selective myocardial revascularization on the basis of clinical systems. *J Vasc Surg* 1987; 5:222–227.
- Bernstein EF, Dilley RB, Randolph HF III. The improving long term outlook for patients 70 years of age with abdominal aortic aneurysms. *Ann Surg* 1988; 207:318–322.
- Hollier LH, Taylor LM, Ochsner J. Recommended indications for operative treatment of abdominal aortic aneurysms: report of the Subcommittee of the Joint Council of the Society for Vascular Surgery and the North American Chapter of the International Society for Cardiovascular Surgery. *J Vasc Surg* 1992; 15:1046–1056.
- Veith FJ, Goldsmith J, Leather RP, Hannan EL. The need for quality assurance in vascular surgery. *J Vasc Surg* 1991; 13:523–526.
- Blaisdell FW, Hall AD, Thomas AN. Ligation treatment of abdominal aortic aneurysms. *Am J Surg* 1965; 109:560–564.
- Leather RP, Shah DM, Goldman M, et al. Non-resective treatment of abdominal aortic aneurysms: Use of thrombosis and axillofemoral bypass. *Arch Surg* 1979; 114:1402–1408.
- Lemolle GM, Spagna BM, Strong MD. Rigid intraluminal prosthesis for replacement of the thoracic and abdominal aorta. *J Vasc Surg* 1984; 1:22–26.
- Cragg A, Lund G, Rysavy J, et al. Non-surgical placement of arterial endoprosthesis: A new technique using nitinol wire. *Radiology* 1983; 147:261–263.
- Balko A, Piasecki GJ, Shah BM, et al. Transfemoral placement of intraluminal polyurethane prosthesis for abdominal aortic aneurysm. *J Surg Res* 1986; 40:305–309.
- Chaudhury MH. Method for performing aneurysm repair. U.S. Patent Number 4,140,126; 1979.
- Kornberg E. Aortic graft device and method for performing an intraluminal abdominal aortic aneurysm repair. U.S. Patent Number 4,562,596; 1986.
- Kornberg E. Device and method for performing an intraluminal abdominal aortic aneurysm repair. U.S. Patent Number 4,617,932; 1986.
- Lazarus HM. Intraluminal graft device, system and method. U.S. Patent Number 4,787,899; 1988.
- Parodi JC, Palmaz JC, Barone HD. Transfemoral intraluminal graft implantation for abdominal aortic aneurysms. *Ann Vasc Surg* 1991; 5:491–499.
- Chuter TAN, Green RN, Ouriel J, et al. Transfemoral endovascular aortic graft placement. *J Vasc Surg* 1993; 18:185–197.
- Marin ML, Veith FJ, Panetta TF, et al. Percutaneous transfemoral stented graft repair of a traumatic femoral arteriovenous fistula. *J Vasc Surg* 1993; 18:298–301.
- Marin ML, Veith FJ, Panetta TF, et al. Transfemoral stented graft placement of occlusive arterial disease for limb salvage: a preliminary report (Abstract no. 0054). *Circulation* 1993; 88:1–11.
- Moon MR, Dake MD, Pelc LR, et al. Intravascular stenting of acute experimental type B dissections. *J Surg Res* 1993; 54:381–388.

## Discussion

**DR. FRANK J. VEITH (New York, New York):** I would like to congratulate Dr. Moore on a most exciting presentation. There is little doubt in my mind that transluminally placed endovascular stented grafts will have a major impact on the way arterial lesions are treated.

Over the last year and a half, we have placed 51 endovascular stented grafts to treat a variety of arterial lesions in 40 patients. Unlike Dr. Moore's cases, most of our patients had major systemic or local contraindications to standard operative repair and many were too sick to undergo general or even regional anesthesia.

Since November, 1992, we have inserted via transfemoral routes seven stented grafts for aortic or aorto-iliac aneurysms. Results in some of these otherwise inoperable patients have been dramatic, with the patient leaving the hospital in 2 to 3 days with their aneurysm fully excluded.

However, we have had one death from multiorgan failure secondary to microembolization, a problem that Dr. Parodi, the father of this technique, has seen in three patients and one that we believe requires attention and care to prevent. I would like to ask Dr Moore if he has seen any evidence of this microembolization even though his patient population differed considerably from ours.

Aside from the aortic aneurysms, we have also used endovascular stented grafts to treat common iliac (2) and popliteal aneurysms (1) with uniform success and follow-up now extending over one year. Similarly with the eight traumatic arterial lesions, stented graft repair has been uniformly successful and our longest follow-up now extends to 16 months.

Finally, our most interesting early results with these endoluminal grafts have been in patients with arteriosclerotic occlusive disease at the aorto-iliac and/or the femoropopliteal levels. The aorto-iliac grafts have been particularly gratifying. Only 1 of the 17 patients with one or two grafts in this location has had a graft failure. Here also our follow-up exceeds 1 year.

We therefore believe these endovascular grafts may become quite important in the treatment of various arterial lesions. However, many of these procedures have been difficult and complex and their exact role and long-term effectiveness remain to be defined. Dr. Moore is to be commended for bringing this important new development to our attention.

**DR. CALVIN B. ERNST (Detroit, Michigan):** Clearly, endo-