

# Prospective Evaluation of Laparoscopic-Assisted Large-Bowel Excision for Cancer

Samuel P. Y. Kwok, F.R.C.S.(Ed.), F.R.A.C.S., W. Y. Lau, F.R.C.S.(Ed.), F.R.A.C.S., F.A.C.S.,  
P. Declan Carey, F.R.C.S.(I), Seamus B. Kelly, F.R.C.S.(I), K. L. Leung, F.R.C.S.(Ed.),  
and Arthur K. C. Li, M.A., M.D., F.R.C.S., F.R.A.C.S.

*From the Department of Surgery, the Chinese University of Hong Kong, Prince of Wales  
Hospital, Shatin, Hong Kong*

---

## Objective

The authors described their experience with laparoscopic-assisted colorectal resection for colorectal carcinoma, both curative and palliative, with emphasis on patient selection. The techniques of the operations were described.

## Summary Background Data

Laparoscopic colorectal procedures for treatment of benign lesions have been shown to be less painful and to enhance early postoperative recovery. However, use of laparoscopic procedures for treatment of colorectal cancer are controversial. The authors have used laparoscopic techniques for curative and palliative resections of colorectal carcinoma with satisfactory early results.

## Methods

One hundred patients with colorectal carcinoma were selected over a 30-month period for laparoscopic-assisted colon and rectal resection. For 17 patients, laparoscopy revealed bulky tumor or locally advanced disease, and open surgery was performed. For 83 patients, laparoscopic-assisted colorectal resections were attempted. Procedural data and postoperative results were entered prospectively. The median follow-up period was 15.2 months (range, 2.5-32.7 months).

## Results

Fourteen of 83 patients eventually required conversion to open surgery. The median operative time was 180 minutes. The patients could return to a normal diet in a median of 4 days. The median number of doses of analgesics required was two, and the median hospital stay was 6 days. The morbidity rate was 12%, and there was no deaths attributable to the procedure. There were four distant recurrences and one pelvic recurrence.

## Conclusions

Laparoscopic-assisted colorectal resection for selected patients is feasible, and early postoperative results are encouraging. This procedure does not appear to be associated with an excessive recurrence rate, and long-term follow-up is necessary for late survival figures.

---

Since the successful introduction of laparoscopic cholecystectomy, which revolutionized the surgical approach to cholecystectomy worldwide, the feasibility of the laparoscopic approach for many other general surgical operations, such as appendectomy, repair of perforated peptic ulcer, hernia repair, Nissen fundoplication,<sup>1</sup> esophagectomy, gastrectomy, adrenalectomy, and colectomy<sup>2,3</sup> has been demonstrated and reported. To explore the limits of laparoscopic surgery for the treatment of colorectal diseases, researchers have performed various laparoscopic and laparoscopic-assisted colorectal procedures, including colostomy,<sup>4</sup> total colectomy,<sup>5</sup> segmental bowel resection,<sup>6</sup> anterior resection,<sup>7</sup> abdominoperineal resection of the rectum,<sup>8</sup> Hartmann's operation, and rectopexy. Some larger series of laparoscopic-assisted colonic resection have demonstrated good results.<sup>3,6,9,10</sup> However, the literature on laparoscopic procedures in dealing with colorectal malignancy is scanty. The question of whether the benefits of laparoscopic operations will extend to patients with colorectal cancer and whether the laparoscopic technique is adequate in terms of tumor clearance remains largely unanswered.<sup>11-13</sup> Encouraged by our early results with laparoscopic-assisted colectomy in treatment of cancer,<sup>14,15</sup> we attempted curative and palliative laparoscopic-assisted colorectal excision for tumors at all levels. In the current study we reported on our experience with laparoscopic-assisted colorectal excision for cancer for our first 100 cases.

## PATIENTS AND METHODS

From April 1992 to October 1994, we have attempted laparoscopic-assisted colonic or colorectal resection for 100 selected patients with colorectal carcinoma at the Prince of Wales Hospital. In the first 30 cases (phase 1), we chose to perform laparoscopic surgery for patients older than 65 years of age and/or patients with metastatic disease not treatable by surgery. Patients were excluded if they had a distal rectal tumor requiring anastomosis within 5 cm of the dentate line. Laparoscopic abdominoperineal resection of the rectum was performed for tumors 5 cm or less from the anal verge or below without anastomosis.

On the basis of our experience with the converted cases in phase 1, we altered our selection criteria accordingly. In the subsequent 70 cases, we attempted laparoscopic procedures, curative or palliative, for all age groups. We

excluded patients who had a distal rectal tumor requiring anastomosis within 5 cm of the dentate line, patients with bulky tumors (6 cm or larger) or locally advanced disease (infiltrating adjacent organs) on examination, patients who had undergone previous major abdominal operations, patients who did not consent to the procedure, and patients who presented with intestinal obstruction or perforation.

All patients underwent preoperative colonoscopy and biopsy. Barium enema studies were performed for lesions 30 cm or more from the anal verge to localize the lesions radiologically. Ultrasonography was used to gauge the size of the lesions and to look for evidence of infiltration to adjacent organs. Computed tomography scanning was used if locally advanced disease was suspected. Chest radiography and ultrasonography of the liver were performed to reveal distant metastases.

Bowel preparation with 4 L polyethylene glycol electrolyte solution was performed the day before surgery, and systemic prophylactic antibiotics were administered at induction of anesthesia. A urinary catheter and a nasogastric tube were used for all patients.

Operation time was measured from the first incision to reversal of anesthesia. Postoperative analgesia was provided on demand with use of pethidine (1 mg/kg administered intramuscularly). Data were entered prospectively.

## Surgical Techniques

The techniques of laparoscopic-assisted colon or rectal excision were still evolving at the time of this series. In the initial period, the operations were performed by a team of four surgeons, including the camera operator. Pneumoperitoneum was introduced through a subumbilical incision with the Veress needle. Four accessory ports were introduced under laparoscopic guidance and used by the operating surgeon and the assisting surgeons. With the experience gained from the first few cases, we were adept with the laparoscopic techniques in colon and rectal excision. We were comfortable with only three surgeons and three working ports. We also converted to the open laparoscopy technique, with the laparoscope inserted at the subumbilical port site. We described below the techniques that we are using currently in our laparoscopic-assisted colon and rectal excisions.

## Positioning

All patients were placed in the Lloyd Davies position with a head-down tilt and with the right arm alongside the body. One monitor was put on either side of the patient so that the chief surgeon and the assisting surgeons could see the monitors. For left hemicolectomy, sigmoid

---

Address reprint requests to Arthur K. C. Li, M.A., M.D., F.R.C.S., F.R.A.C.S., Department of Surgery, The Chinese University of Hong Kong, Prince of Wales Hospital, Shatin, New Territories, Hong Kong.

Accepted for publication April 3, 1995.

colectomy, anterior resection of the rectum, and abdominoperineal resection of the rectum, the chief surgeon and the camera operator stood on the right side of the patient, with the latter toward the head of the patient. The other assistants stood on the patient's left side. The scrub nurse stood to the right of the chief surgeon and at the foot of the patient.

For right hemicolectomy and transverse colectomy, the patient, monitors, and nurse were positioned as above. The chief surgeon stood between the patient's legs, the camera operator on the patient's left, and the other assistant on the patient's right.

### Port Sites

Pneumoperitoneum was induced with open technique through a 10- to 11-mm port at the subumbilical position. The laparoscope, which had a camera attached, was then inserted through the subumbilical port to guide the positioning of the other three ports. For left-sided colonic lesions and rectal lesions, two 12-mm ports were positioned along the right midclavicular line, one at the level of the umbilicus and one at the level of the anterior superior iliac spine for the use of the chief surgeon. Another 12-mm port was positioned on the left midclavicular line at the level of the anterior superior iliac spine for the use of the assistant.

For right hemicolectomy and transverse colectomy, two 12-mm ports were positioned suprapubically just above the pubic tubercle on either side for the use of the chief surgeon. The other 12-mm port was positioned in the right upper quadrant for the use of the assistant.

### Procedures

The laparoscopic-assisted operation consisted of (1) mobilization of the relevant segment of bowel loop; (2) division of the lymphovascular pedicle; (3) division of the associated mesentery; (4) mobilization of the rectum in anterior resection and abdominoperineal resection; (5) division of the distal and proximal bowel ends; and (6) anastomosis, either intracorporeal or extracorporeal.

For right hemicolectomy, transverse colectomy and left hemicolectomy, bowel loop mobilization, and division of the lymphovascular pedicle and associated mesentery were achieved with laparoscopic-guided dissection. Division of the lymphovascular pedicle was completed with the endoGIA 30 (AutoSuture, div. of U.S. Surgical Corp., Norwalk, CT). The bowel loop was at this stage mobile enough to be exteriorized through an extended assistant port site (right side for right hemicolectomy and transverse colectomy, left side for left hemicolectomy) and was protected with a plastic bag. The bowel ends were divided outside the wound, and an anastomo-

sis was created extracorporeally with either sutures or staples. The completed anastomosis was internalized, and the mesenteric defect was closed with endoscopic hernia staples under laparoscopic guidance.

For sigmoid colectomy and anterior resection, the operative steps from mobilization of the sigmoid colon and the rectum, and division of the inferior mesenteric vessels and associated mesentery up to the distal bowel division using endoGIA 30 (applied one or more times) were all achieved under laparoscopic guidance. The proximal cut end of the bowel was then exteriorized through the extended left side of the port and protected with a plastic bag, and the proximal division of the bowel was made extracorporeally. The anvil of the premium CEEA (Autosuture, U.S. Surgical Corp.) was then inserted into the proximal bowel end and secured with a 2/0 prolene purse-string suture. The bowel end was then internalized and the extended wound closed. Pneumoperitoneum was again induced and a stapled anastomosis was fashioned intracorporeally under laparoscopic guidance using the double-stapling technique.

For abdominoperineal resection of the rectum, the mobilization of the sigmoid colon and the rectum and division of the inferior mesenteric vascular pedicle were the same as in laparoscopic-assisted anterior resection. However, the bowel proximal to the tumor, instead of distal, was divided using the endoGIA. With the help of the perineal surgeon, the rectum was fully mobilized and the specimen retrieved through the perineal wound. The pelvic peritoneum was reconstructed with endoscopic hernia staplers, and a terminal colostomy was fashioned through an extended left lower quadrant port site.

### RESULTS

From April 1992 to October 1994, we have chosen 107 patients with colorectal cancer for laparoscopic-assisted colorectal procedures, of whom 100 underwent laparoscopic-assisted colorectal excisions for colorectal carcinoma. Of the remaining seven patients, two underwent laparoscopic colotomy and polypectomy for colonic adenomas, one underwent laparoscopic anterior resection for rectal adenoma, two underwent laparoscopic rectopexy for complete rectal prolapse, one underwent sigmoid colectomy for sigmoid volvulus, and one laparoscopic right hemicolectomy for colonic lymphoma.

Of the 100 patients selected for laparoscopic-assisted colon and rectal excision for colorectal carcinoma, 52 were male and 48 female, with age ranging from 16 to 87 years (mean, 67.3 years; SD, 11.9 years). The distribution of Dukes' staging was 9 patients with stage A, 39 with stage B, 24 with stage C, and 28 with stage D disease. The median follow-up period was 15.2 months (range, 2.5–32.7 months). The distribution of the carcinoma

along the large bowel was as follows: 18 patients, cecal or ascending colon; 2, transverse colon; 5, descending colon; 27, sigmoid colon; 30, rectum; and 18, anorectum requiring abdominoperineal resection.

According to the different selection criteria, the series can be divided into phases 1 (initial 30 cases) and 2 (subsequent 70 cases). The selection criteria used in phase 2 were based on the experience gained from phase 1.

For the purposes of analysis, the patients were categorized into three groups: group A, completed laparoscopic-assisted procedure; group B, attempted laparoscopic-assisted procedure followed by conversion to conventional laparotomy; and group C, laparoscopy only without attempted laparoscopic-assisted procedure followed by conventional laparotomy. In group C, laparoscopic assisted procedure was not attempted because laparoscopy revealed that the tumor was either too bulky or locally advanced with infiltration to adjacent organs or the abdominal wall, which was not evident in preoperative investigations. Data on patients in group C were not analyzed further because the procedure used was essentially a diagnostic laparoscopy combined with a conventional open colectomy, which was not one of the procedure of interest in the current article.

In phase 1, 18 patients were in group A, 9 in group B, and 3 in group C. In phase 2, 51 patients were in group A, 5 in group B, and 14 in group C.

The distribution of the laparoscopic-assisted procedures used in groups A and B is shown in Figure 1. Of the 83 procedures in groups A and B, 62 were performed with curative intent and 21 with palliative intent. Of the 14 conversions, 9 were in phase 1 and only 5 in phase 2. Therefore, the conversion rate, after excluding the cases in group C, in phase 1 was 33.3% (9 of 27 patients) and in phase 2 was 8.9% (5 of 56 patients). The low conversion rate in phase 2 is attributed to a strict selection criteria, and laparoscopy helped to exclude cases that were likely to be converted.

An analysis of the perioperative results of the 83 patients in groups A and B revealed a median operating time of 180 minutes (range, 120–320 minutes), and median intraoperative blood loss was 325 mL (range 50–3000 mL). The patients could resume a normal, full diet in a median of 4 days (range, 1–15 days). The median postoperative hospital stay was 6 days (range, 2–33 days).

The median postoperative analgesic requirement in group A was 2 doses (range, 0–39 doses) of pethidine (1 mg/kg administered intramuscularly) and that of group B was 4.5 doses (range, 1–15 doses). The difference in analgesic requirement was statistically significant according to the Mann–Whitney *U* test ( $p = 0.04$ ). In further analysis of group A, the analgesic requirement for the laparoscopic-assisted abdominoperineal resection patients with perineal wounds (median, 7 doses; range,

1–39 doses) was significantly more than that for the rest of group A, for whom all wounds in the abdomen were minimal without perineal wounds (median, 2 doses; range, 0–16 doses) (Mann–Whitney *U* test,  $p = 0.04$ ).

In the completed laparoscopic-assisted large-bowel resection group (group A), the mean number of lymph nodes harvested on histopathologic examination was 12.8 (SD, 7.0). The mean length of distal safety margin of the rectum in the fixed shrunken specimen was 3.2 cm (SD, 1.8 cm) in cases of completed laparoscopic-assisted anterior resection for rectal carcinoma. All resection margins, including distal and lateral resection margins, were clear of tumors for all patients undergoing surgery with curative intent.

The overall complication rate in the current series was 12% (10 of 83 patients). There were two major complications. One patient had small-bowel perforation presenting as peritonitis on day 1, requiring a laparotomy. The other patient had a ureteric injury that was made after conversion to formal laparotomy during a difficult laparoscopic abdominoperineal resection of the rectum. Other minor complications included two cases of retention of urine, one case of deep vein thrombosis, one case of incisional hernia, and four cases of minor wound infection. Fortunately, there was no incidence of anastomosis leakage in the whole series. At the time of this writing, there were five cases of recurrence among patients receiving curative surgery. Four were cases of distant metastases, including lung, liver, ovary and carcinomatosis peritonei with port site recurrence. One patient had a locoregional recurrence in the pelvic region. One patient who had undergone a palliative laparoscopic-assisted right hemicolectomy had a recurrence in the abdominal wound through which the specimen was delivered.

There were two perioperative deaths, one due to cerebrovascular accident and the other due to aspiration pneumonia. Both perioperative deaths were unrelated to the laparoscopic procedures. Five patients in the entire series died of advanced malignancy.

## DISCUSSION

Laparoscopic cholecystectomy has rapidly established its role in place of open surgery since Philippe Mouret performed the first laparoscopic cholecystectomy during a laparoscopic gynecologic operation in March 1987 in France.<sup>16</sup> However, laparoscopic large-bowel surgery has not received the same degree of acceptance by the surgical community,<sup>12,13</sup> although initial series have shown promising results.<sup>6,9</sup> This lack of acceptance exists for two main reasons. First, laparoscopic large-bowel surgery is much more complicated than laparoscopic cholecystectomy, and more advanced laparoscopic techniques are required.<sup>17</sup> Second, the efficacy of laparo-

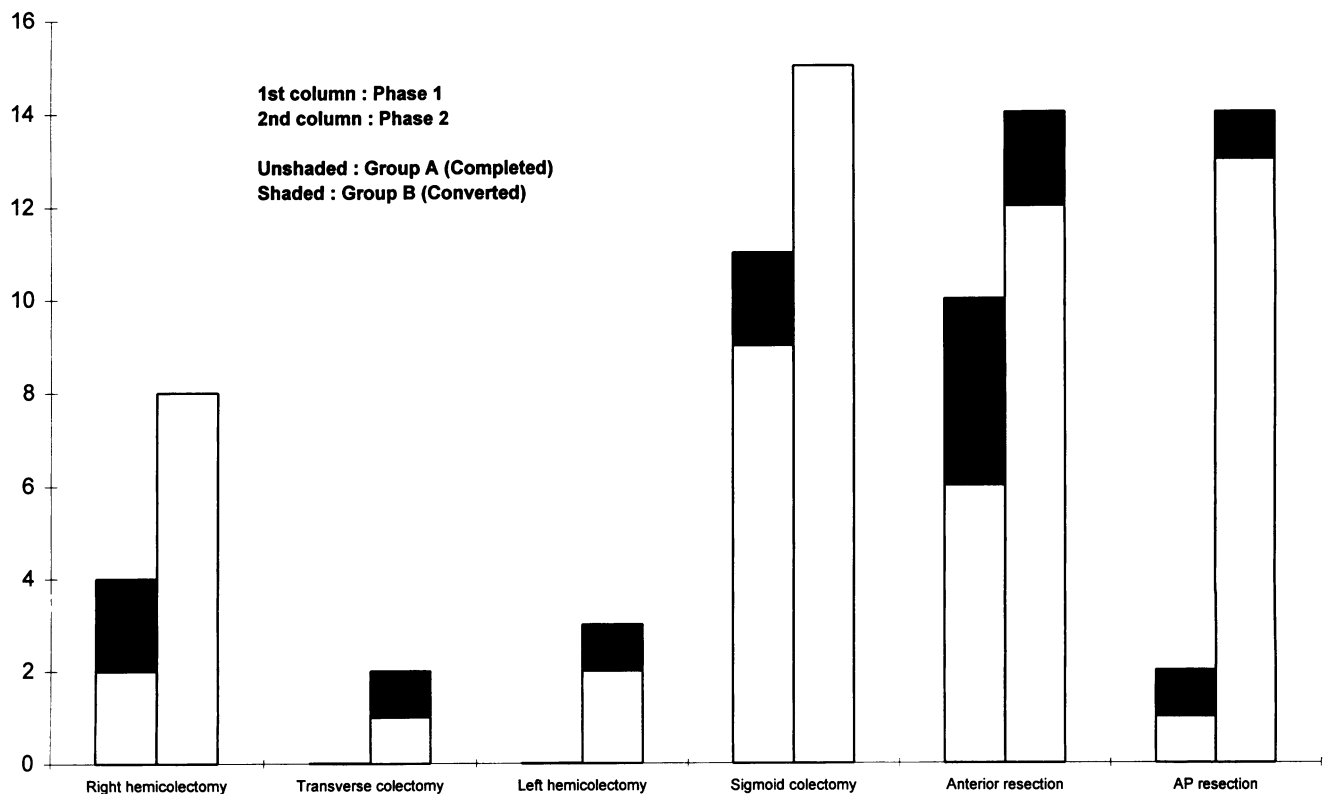


Figure 1. Case distribution by procedures and phase.

scopic large-bowel resection for cancer is unproven.<sup>12,13</sup> People have questioned whether laparoscopic colectomy can achieve the same degree of tumor clearance as in conventional open surgery<sup>13</sup> and whether laparoscopic surgery actually enhances tumor dissemination.<sup>18</sup>

Our large initial series of 100 cases of laparoscopic-assisted colectomy for colorectal cancer is promising in terms of favorable early postoperative results and medium term recurrence rates and survival figures. There is a suggestion of less postoperative pain, reflected by the requirement for less analgesia, earlier return of bowel function, and shorter hospital stay compared with conventional open surgery, as documented in our early comparative study.<sup>14</sup> Although it has been suggested that early postoperative oral intake may not be related to the minimally invasive approach,<sup>19</sup> we believe that the improved morbidity in terms of less pain (leading to earlier mobilization) and earlier return to normal diet have led to shorter hospital stay, and these are the major benefits of the minimally invasive surgery. The much better cosmetic result and patient satisfaction associated with the laparoscopic approach is difficult to quantify and measure. Whether the laparoscopic approach causes less immunosuppression as a result of less trauma is debatable. However, recent evidence showing unimpaired immune functions and attenuation of metabolic and inflamma-

tory responses after laparoscopic cholecystectomy compared with open cholecystectomy is encouraging.<sup>20,21</sup>

We began to perform laparoscopic-assisted colectomy in humans only after acquiring the technique of laparoscopic bowel surgery in the porcine model and also after gaining enough laparoscopic surgical experience in humans by performing laparoscopic cholecystectomy and laparoscopic appendectomy. We are very cautious in our case selection criteria to select patients with distant metastases or patients who are relatively old, so that survival will not be adversely affected in phase 1 of our series. In fact, once we started performing the laparoscopic-assisted colectomy in humans, we were confident that we could perform the laparoscopic dissection in the same way as in laparotomy procedures and that we could actually go through the same tissue planes, and we believe that the same amount of tissue is removed, hence the tumor clearance achieved should be the same.

Adequate oncologic resection of the large bowel has been shown to be feasible in dogs<sup>22</sup> and cadavers.<sup>23</sup> Adequate lymphadenectomy in laparoscopic bowel surgery in humans can be achieved in the same way as in open surgery, as demonstrated in our experience and in that of others.<sup>24</sup> In the current series, the number of lymph nodes harvested and the noninvolvement of all distal and lateral margins further supports the feasibility of ad-

equate oncologic clearance in laparoscopic colorectal resection.

This is also reflected by the acceptable recurrence rate in the current series, and most of the recurrences are actually distant metastasis. Therefore, locoregional clearance by laparoscopic technique is reliable.

The single incidence of abdominal wound recurrence in the palliative right hemicolectomy case (in the extended port site incision through which the specimen was exteriorized) occurred early in our series, before we practiced wound protection with use of a plastic bag. This recurrence is believed to be due to tumor cell seeding during specimen extraction through the abdominal wound. The single incidence of port site recurrence as part of the widespread carcinomatosis peritonei occurred in a curative sigmoid resection. We did not observe isolated port site recurrence, as has been reported in other series, probably due to a different mechanism by which tumor cells spread to the port sites other than by direct tumor-wound contact.<sup>18</sup>

The conversion rate can be markedly reduced by careful case selection. In our experience with conversion in our early cases, we learned that the main reasons for difficult laparoscopic dissection and eventual conversion to laparotomy are bulky tumors and locally advanced disease infiltrating adjacent organs, abdominal walls, or pelvic side walls. Therefore, in the phase 2 selection criteria, we excluded cases of tumors more than 6 cm in greatest dimension and locally advanced disease. This selection policy has lowered our conversion rate from 33.3% to 8.9%. If preoperative investigation fails to demonstrate bulky tumors or locally advanced disease, laparoscopy itself often can be very useful for finding such tumors, and formal laparotomy should follow rather than laparoscopic dissection, which is likely to end up in a conversion. Tumor located in the lower third of the rectum was also excluded in our series, because the straight endoscopic stapler that is used in distal rectal division cuts the rectum at an angle instead of straight across, which could compromise the distal margin in low tumors.

Gross obesity was noted to be one contributing factor leading to conversion to an open procedure in laparoscopic-assisted colorectal excision, as has been reported in other series in the literature.<sup>2,9</sup> However, in the patient population in Hong Kong, gross obesity was not encountered commonly. Therefore obesity was not an exclusion criterion in the current series, nor was it a cause leading to conversion.

We perform laparoscopic-assisted colectomy rather than total laparoscopic colectomy alone, which has been reported to be feasible.<sup>25</sup> We believe that because a small wound in the abdomen is used to extract the specimen, except in abdominoperineal resection of the rectum, that

wound may be used in performing part of the operation extracorporeally, which greatly expedites the whole procedure. The length of the wound (median, 5 cm in the current series) for specimen extraction is mainly determined by the size of the tumor. This wound is usually adequate for exteriorization of the whole bowel loop for a colectomy, provided that the bowel loop is adequately mobilized and the vascular pedicle is divided under laparoscopic guidance. In the case of laparoscopic-assisted anterior resection, the anastomosis is performed intracorporeally with the use of a transanal circular stapler under laparoscopic guidance, because it is difficult to perform the anastomosis either at the abdominal wound or through the abdominal wound, especially for lower anastomoses because of the short rectal stump.

The question of whether laparoscopic-assisted large-bowel resection is advantageous over conventional open operation in terms of less morbidity and acceptable recurrence and survival rates has to be answered by a carefully conducted randomized trial. We believe it to be so, as the current study has shown, for selected patients with colorectal cancer.

## References

1. Jamieson GG, Watson DI, Britten-Jones R, et al. Laparoscopic Nissen fundoplication. *Ann Surg* 1994; 220:137-145.
2. Falk PM, Beart RW Jr., Wexner SD, et al. Laparoscopic colectomy: a critical appraisal. *Dis Colon Rectum* 1993; 36:28-34.
3. Monson JRT, Darzi A, Carey PD, Guillou PJ. Prospective evaluation of laparoscopic-assisted colectomy in an unselected group of patients. *Lancet* 1992; 340:831-833.
4. Lyerly HK, Mault JR. Laparoscopic ileostomy and colostomy. *Ann Surg* 1994; 219:317-322.
5. Wexner SD, Johansen OB, Noguera JJ, Jagelman DG. Laparoscopic total abdominal colectomy: a prospective trial. *Dis Colon Rectum* 1992; 35:651-655.
6. Dean PA, Beart RW Jr., Nelson H, et al. Laparoscopic-assisted segmental colectomy: early Mayo Clinic experience. *Mayo Clin Proc* 1994; 69:834-840.
7. Plasencia G, Jacobs M, Verdeja JC, Viamonte M IIqI. Laparoscopic-assisted sigmoid colectomy and low anterior resection. *Dis Colon Rectum* 1994; 37:829-833.
8. Kockerling F, Gastinger I, Schneider B, et al. Laparoscopic abdominoperineal excision of the rectum with high ligation of the inferior mesenteric artery in the management of rectal carcinoma. *Endosc Surg Allied Technol* 1993; 1:16-19.
9. Zucker KA, Pitcher DE, Martin DT, Ford RS. Laparoscopic-assisted colon resection. *Surg Endosc* 1994; 8:12-18.
10. Phillips EH, Franklin M, Carroll BJ, et al. Laparoscopic colectomy. *Ann Surg* 1992; 216:703-707.
11. Beart RW Jr. Laparoscopic colectomy: status of the art. *Dis Colon Rectum* 1994; 37:S47-S49.
12. O'Rourke NA, Heald RJ. Laparoscopic surgery for colorectal cancer. *Br J Surg* 1993; 80:1229-1230.
13. Colons and keyholes [editorial]. *Lancet* 1992; 340:824-825.
14. Tate JJT, Kwok S, Dawson JW, et al. Prospective comparison of laparoscopic and conventional anterior resection. *Br J Surg* 1993; 80:1396-1398.

15. Kwok SPY. Laparoscopic colectomy: a real option. In: Kwok SPY, ed. *Grand Rounds in Surgery* 1994. Hong Kong: The Chinese University Press, 1994:167-174.
16. Perissat J. Laparoscopic cholecystectomy: gateway to the future [editorial]. *Am J Surg* 1991; 161:408.
17. Geis WP, Coletta AV, Verdeja JC, et al. Sequential psychomotor skills development in laparoscopic colon surgery. *Arch Surg* 1994; 129:206-212.
18. Nduka CC, Monson JRT, Menzies-Gow N, Darzi A. Abdominal wall metastases following laparoscopy. *Br J Surg* 1994; 81:648-652.
19. Binderow SR, Cohen SM, Wexner SD, Noguera JJ. Must early postoperative oral intake be limited to laparoscopy? *Dis Colon Rectum* 1994; 37:584-589.
20. Kloosterman T, von Blomberg BME, Borgstein P, et al. Unimpaired immune functions after laparoscopic cholecystectomy. *Surgery* 1994; 115:424-428.
21. Jakeways MSR, Mitchell V, Hashim IA, et al. Metabolic and inflammatory responses after open or laparoscopic cholecystectomy. *Br J Surg* 1994; 81:127-131.
22. Bohm B, Milsom JW, Kitago K, et al. Laparoscopic oncologic total abdominal colectomy with intraperitoneal stapled anastomosis in a canine model. *J Laparoendosc Surg* 1994; 4:23-30.
23. Decanini C, Milsom JW, Bohm B, Fazio VW. Laparoscopic oncologic abdominoperineal resection. *Dis Colon Rectum* 1994; 37:552-558.
24. Gray D, Lee H, Schlinkert R, Beart RW Jr. Adequacy of lymphadenectomy in laparoscopic-assisted colectomy for colorectal cancer; a preliminary report. *J Surg Oncol* 1994; 57:8-10.
25. Darzi A, Super P, Guillou PJ, Monson JR. Laparoscopic sigmoid colectomy: total laparoscopic approach. *Dis Colon Rectum* 1994; 37:268-271.