

Report

Homozygosity Mapping of Portuguese and Japanese Forms of Ataxia-Oculomotor Apraxia to 9p13, and Evidence for Genetic Heterogeneity

Maria do Céu Moreira,^{1,2} Clara Barbot,^{2,3} Nobutada Tachi,⁵ Naoki Kozuka,⁵ Pedro Mendonça,² José Barros,⁴ Paula Coutinho,^{2,6} Jorge Sequeiros,² and Michel Koenig¹

¹Institut de Génétique et de Biologie Moléculaire et Cellulaire, CNRS/INSERM/Université Louis-Pasteur, Illkirch, C.U. de Strasbourg, France; ²UnIGENE-IBMC, and ICBAS, Universidade do Porto, ³Department of Neurology, Hospital Maria Pia, and ⁴Department of Neurology, Hospital Geral de Sto. António, Porto, Portugal; ⁵School of Health Sciences, Sapporo Medical University, Sapporo, Japan; and ⁶Division of Neurology, Hospital de S. Sebastião, Santa Maria da Feira, Portugal

Ataxia with oculomotor apraxia (AOA) is characterized by early-onset cerebellar ataxia, ocular apraxia, early areflexia, late peripheral neuropathy, slow progression, severe motor handicap, and absence of both telangiectasias and immunodeficiency. We studied 13 Portuguese families with AOA and found that the two largest families show linkage to 9p, with LOD scores of 4.13 and 3.82, respectively, at a recombination fraction of 0. These and three smaller families, all from northern Portugal, showed homozygosity and haplotype sharing over a 2-cM region on 9p13, demonstrating the existence of both a founding event and linkage to this locus, *AOA1*, in the five families. Three other families were excluded from this locus, demonstrating nonallelic heterogeneity in AOA. Early-onset cerebellar ataxia with hypoalbuminemia (EOCA-HA), so far described only in Japan, is characterized by marked cerebellar atrophy, peripheral neuropathy, mental retardation, and, occasionally, oculomotor apraxia. Two unrelated Japanese families with EOCA-HA were analyzed and appeared to show linkage to the *AOA1* locus. Subsequently, hypoalbuminemia was found in all five Portuguese patients with *AOA1* with a long disease duration, suggesting that *AOA1* and EOCA-HA correspond to the same entity that accounts for a significant proportion of all recessive ataxias. The narrow localization of *AOA1* should prompt the identification of the defective gene.

The hereditary ataxias are a heterogeneous group of diseases characterized by cerebellar ataxia associated with a number of different neurological, ophthalmological, or general signs. These diseases represent 10% of nervous-system genetic disorders. In 1988, Aicardi et al. (1988) reviewed 14 ataxic patients, including six cases previously reported in Japan, United Arab Emirates, and Portugal (Inoue et al. 1971; Araie et al. 1977; Morcos et al. 1982; Awaya et al. 1985, 1986), all of whom had a neurological presentation similar to that of ataxia-telangiectasia (AT [MIM 208900]), but without any of its extraneurological features. In fact, the presence of oculomotor apraxia, defined as the limitation of ocular

movements on command, dissociated from pursuit movements, is a major clinical feature of this pathology (Barbot et al., in press), as it is in AT and in spinocerebellar ataxia type 2 (SCA2 [MIM 601517]). This new form of recessive ataxia with oculomotor apraxia (AOA [MIM 208920]) was considered rare, and few reports were published thereafter. In 1992, Uekawa et al. presented cases of early-onset cerebellar ataxia with hypoalbuminemia (EOCA-HA) in three Japanese consanguineous families. Several similar reports were subsequently made in Japan (Fukuhara et al. 1995; Kubota et al. 1995; Sekijima et al. 1998; Tachi et al. 2000), including one in which oculomotor apraxia and choreoathetosis were noted in two sibs after 13 years of disease duration (Hanihara et al. 1995). Mental retardation was noted in several patients (Fukuhara et al. 1995; Sekijima et al. 1998; Tachi et al. 2000). Except for the presence of mental retardation, these Japanese forms of ataxia showed a remarkable clinical resemblance to AOA.

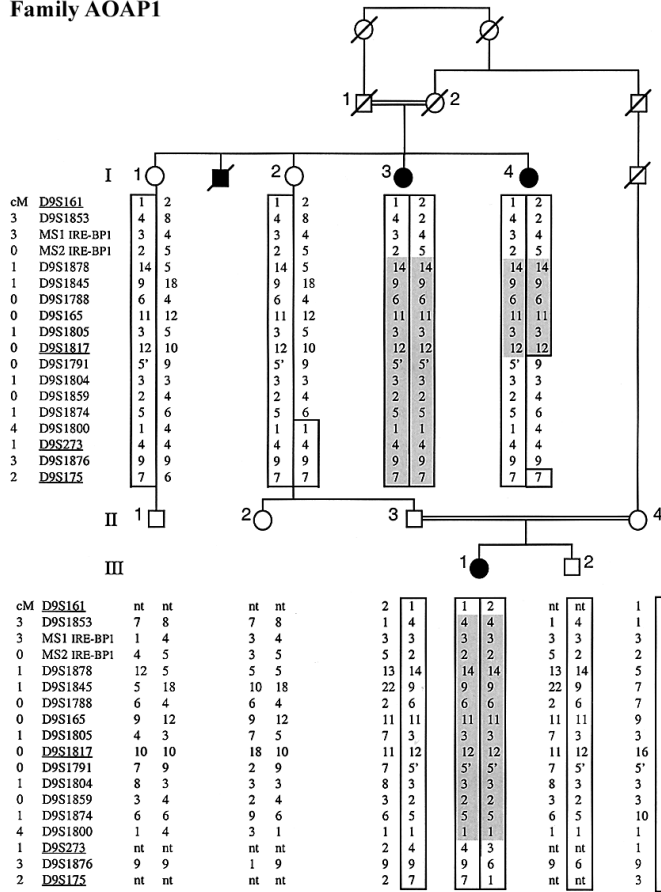
In Portugal, fourteen families with AOA (24 living

Received October 10, 2000; accepted for publication December 8, 2000; electronically published January 22, 2001.

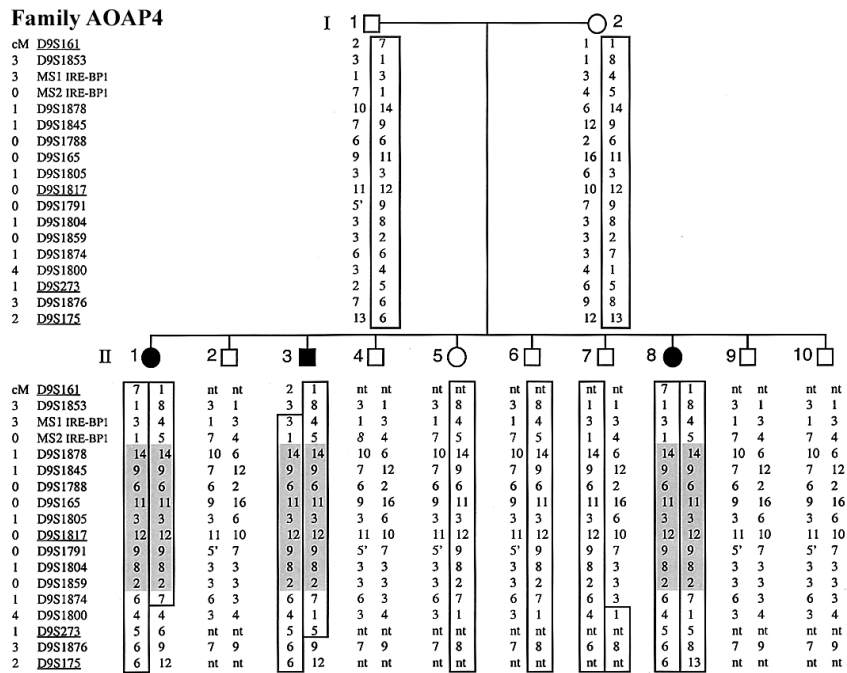
Address for correspondence and reprints: Dr. Michel Koenig, Institut de Génétique et de Biologie Moléculaire et Cellulaire, 1 rue Laurent Fries BP 163, 67404 Illkirch, France. E-mail: mkoenig@igbmc.u-strasbg.fr

© 2001 by The American Society of Human Genetics. All rights reserved. 0002-9297/2001/6802-0022\$02.00

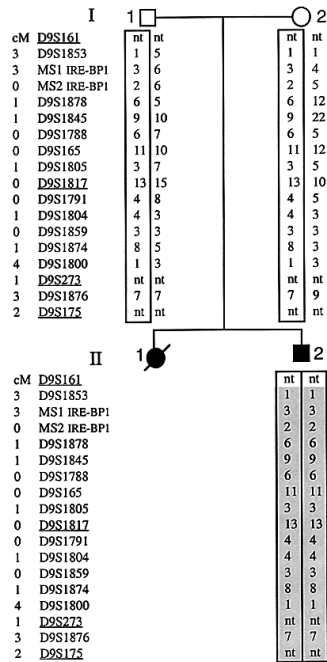
Family AOAP1



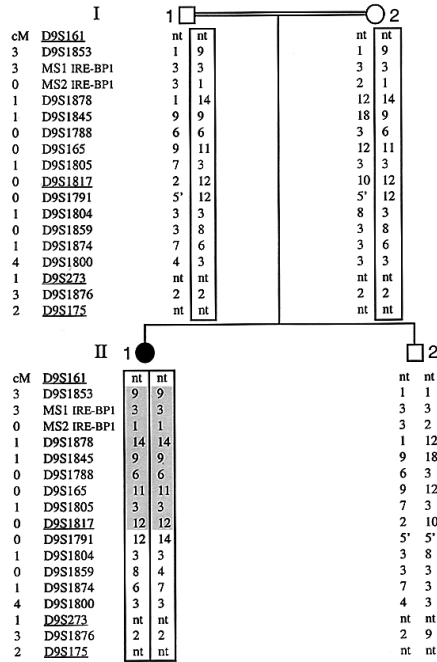
Family AOAP4



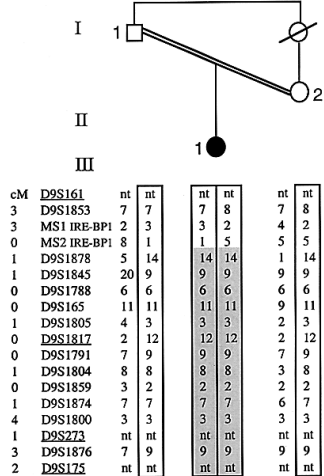
Family AOAP5



Family AOAP7



Family AOAP11



Family AOAP9

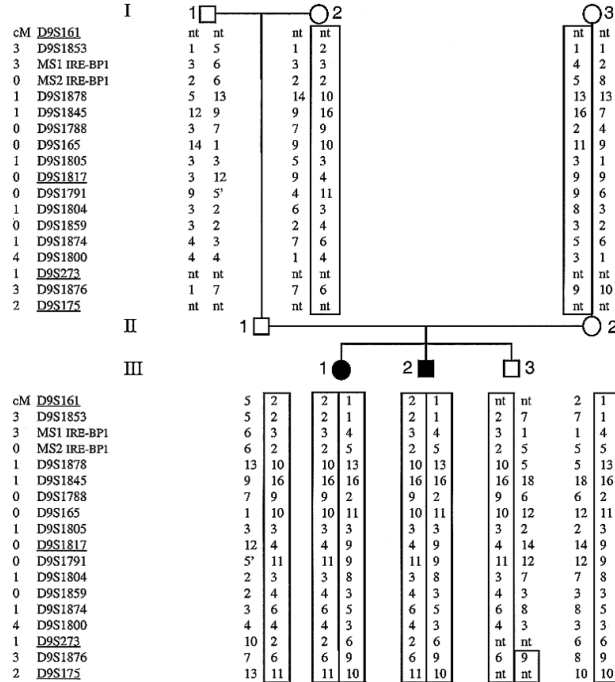


Figure 1 Simplified pedigrees of the families with AOA that show linkage to 9p13, and of family AOAP9. Markers are shown, from top to bottom, in their pter-qtter order (from GeneMap'99). Haplotypes linked to the disease are boxed, and homozygosity in patients is shaded in gray. Distance (cM) to the previous marker is indicated before each marker (Fondation Jean Dausset-CEPH; The Sanger Centre). Markers that were part of the initial whole-genome screening are underlined. nt=not tested. The 5' allele of D9S1791 is intermediate between alleles 5 and 6 (a single-nucleotide variation).

Table 1

Two-point LOD Scores of AOA, for the D9S1817-D9S1878 Haplotype, in Portuguese and Japanese Families Sharing Founding Haplotypes

FAMILY	LOD SCORE AT $\theta =^a$						
	0	.01	.05	.1	.2	.3	.4
Portuguese:							
AOAP1	4.13	4.05	3.73	3.32	2.46	1.58	.73
AOAP4	≥3.82	≥3.75	≥3.49	≥3.14	≥2.41	≥1.63	≥.84
AOAP5	≥1.74	≥1.70	≥1.56	≥1.38	≥1.01	≥.65	≥.30
AOAP7	2.42	2.37	2.15	1.88	1.30	.73	.26
AOAP11	.90	.88	.79	.68	.46	.26	.11
Total	≥13.01	≥12.75	≥11.72	≥10.40	≥7.64	≥4.85	≥2.24
Japanese:							
AOAJ1	≥2.34	≥2.29	≥2.12	≥1.89	≥1.42	≥.94	≥.46
AOAJ2	≥2.34	≥2.29	≥2.12	≥1.89	≥1.42	≥.94	≥.46
Total	≥4.68	≥4.58	≥4.24	≥3.78	≥2.84	≥1.88	≥.92

^a A gene frequency of .005 and a linked haplotype frequency of $\sim 7 \times 10^{-4}$ (calculated as the product of the frequency of the individual alleles estimated in the reference populations) were used for LOD-score calculations. Control samples, representing 45 Portuguese and 34 Japanese independent chromosomes, were analyzed for estimation of allele frequencies. Minimal LOD-score values are given for families (AOAP4, -P5, -J1, and -J2) with ancient nondocumented consanguinity, for whom second-degree consanguinity was assumed.

patients) had been identified (relative frequency of 13.8% of all recessive ataxias in Portugal). The majority were ascertained during a systematic population-based survey of hereditary ataxias and spastic paraplegias that has been conducted in Portugal since 1993 (Silva et al. 1997). This survey already has been completed in 12/18 districts in mainland Portugal and on Madeira Island, including a total population of 5,288,510 inhabitants.

The remaining patients were referred by their neurologists.

Families AOA-P1 through -P11 have been described elsewhere (Barbot et al., in press). All patients presented with progressive cerebellar ataxia starting at 1-15 years of age (mean age = 5 years), axonal neuropathy, and oculomotor apraxia, which was usually noticed a few years after the onset of gait ataxia. Through use of mag-

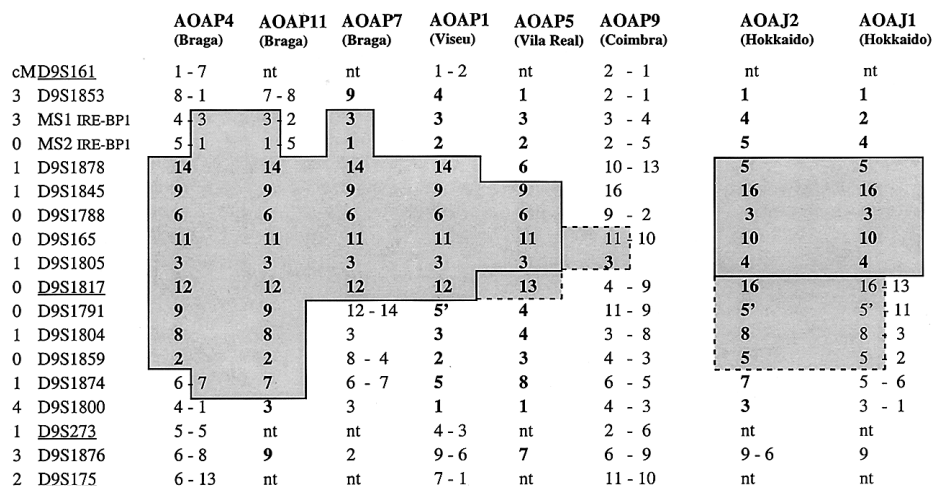


Figure 2 Haplotypes in families AOAP1, -P4, -P5, -P7, -P11, and -P9 and in AOAJ1 and -J2. Homozygous alleles are indicated only once per family. Alleles homozygous by descent are in boldface. The shared haplotypes are boxed and shaded in gray. Alleles that might belong to the founding haplotypes are boxed with dotted lines. Allele 13 from marker D9S1817 (in family AOAP5) might diverge from the founding haplotype by recombination or might derive from the founding allele (12) by slippage mutation of the marker. Phase in family AOAJ1 could not be inferred, since samples of the parents were not available. The dotted box above AOAJ1 and -J2 indicates that one haplotype of AOAJ1 might be identical to the homozygous AOAJ2 haplotype.

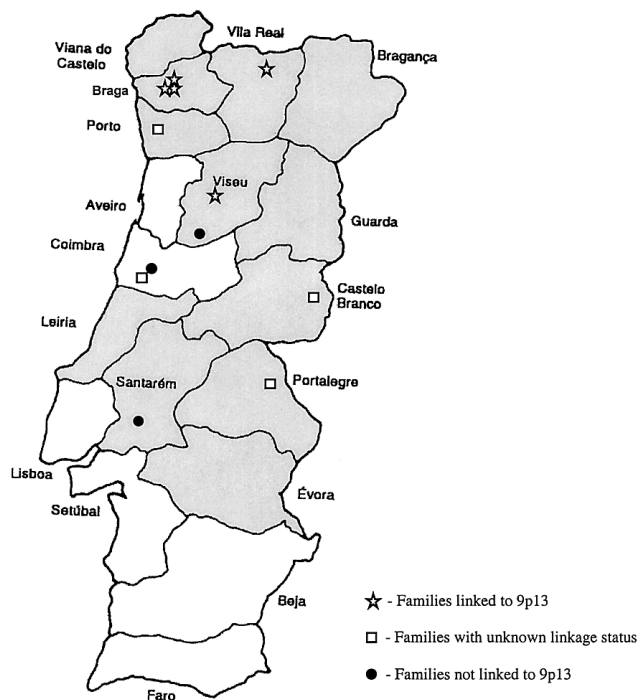


Figure 3 Geographical distribution, on the Portuguese mainland, of families with AOA. Districts where the survey is already completed are shaded in gray. Family AOAP13 is not represented, because of its African (Cabo Verde) origin. The three families in the Braga region that show linkage to 9p are AOAP4, -P7, and -P11, which share the largest region of linkage disequilibrium (fig. 2).

netic-resonance imaging, cerebellar atrophy was found in all patients studied. None had mental retardation, telangiectasia, or immunodeficiency, which excluded the diagnosis of AT. Disease progression was slow and compatible with long survival, despite severe motor handicap. All three patients in family AOAP10 had optic atrophy beginning late in life. The two patients of family AOAP9 and the one patient of AOAP2 had early dystonia, associated with mask-like facies (Barbot et al., in press). Patients from families AOAP13 (originating from Cabo Verde, an ancient Portuguese colony) and AOAP14 also fulfilled the diagnostic criteria for AOA, as defined by Barbot et al. (in press), whereas the patient from family AOAP12 had an atypical presentation (pyramidal signs, spasticity, hyperreflexia, and ankle clonus) and was excluded from the linkage study. A diagnosis of Friedreich ataxia (MIM 229300) was excluded in all cases, by a molecular test. Families AOAP1, -P3, -P7, -P10, -P11, and -P13 were documented as consanguineous, and family -P13 was suspected to have ancient consanguinity. Appropriate informed consent and blood samples were obtained from available family members. The study was approved by the Conselho Nacional de Ética para as Ciên-

cias da Vida and by the Comissão de Ética do Hospital Geral de Santo António-Porto.

Five informative Portuguese families (AOAP1, -P3, -P4, -P9, and -P10) were screened for linkage with the markers of the ABI PRISM Linkage Mapping Set, version 2 (PE Biosystems). These markers were selected from the Généthon human linkage map (Dib et al. 1996) and are spaced every 10 cM, on average. We looked for markers that segregated, with a minimum of recombination events, with the disease and that showed homozygosity in the consanguineous families (AOAP1, -P3, and -P10). No such marker was found, suggesting genetic heterogeneity among the five families. The largest family, AOAP1, was then analyzed separately. Only one marker, D9S1817, showed no recombination and was homozygous in the two affected grandaunts and in the affected grandniece, all born from consanguineous parents (fig. 1). Moreover, the two distal markers (D9S273 and D9S175), which were, respectively, 7 cM and 12 cM distant, were also homozygous in the grandaunts, suggesting a larger region of homozygosity, a phenomenon related to the closer consanguinity of their parents. A denser set of chromosome 9 (pericentromeric and proximal short-arm) markers flanking D9S1817 was then analyzed in this family (Dib et al. 1996; Généthon). A 2-cM region of six consecutive markers on 9p13 (the D9S1878-D9S1817 haplotype) was found to be homozygous in all three patients (fig. 1). Larger regions of homozygosity were found in one of the grandaunts and in the grandniece. LOD-score calculation, including the consanguinity loops (Lathrop et al. 1985; Ben Hamida et al. 1993), gave a value of 4.13 at a recombination fraction (θ) of 0, indicating linkage between the disease and the D9S1878-D9S1817 haplotype (table 1).

All other Portuguese families with AOA were analyzed with respect to the same region on chromosome 9. Two other consanguineous families (AOAP7 and -P11), as well as families in whom consanguinity was not suspected (AOAP4 and -P5), showed homozygosity over regions containing the D9S1878-D9S1817 haplotype (fig. 1). In addition, segregation among the 10 children in AOAP4 indicated linkage to 9p13 (fig. 1). The final argument in favor of linkage in the five homozygous families was the sharing of the D9S1878-D9S1817 haplotype between families AOAP1, -P4, -P7, and -P11, and of a shorter, four-marker haplotype between these four families and family AOAP5 (fig. 2), strongly suggesting an ancient founding event. The inference of a common founding ancestor is in agreement with the origin of all five families in northern Portugal (fig. 3). This result led to the conclusion that AOA is genetically homogeneous among the five families and that the LOD scores could be combined for linkage purposes; this approach yielded a cumulative LOD score of 13.01 at $\theta = 0$ (table 1).

Linkage in families AOAP6, -P10, and -P13 was ex-

Table 2**Serum Albumin and Total-Cholesterol Values, According to Linkage Status and Disease Duration**

Family	Status of Linkage to 9p13	Patient ^a	Disease Duration at Time of Sampling (years)	Serum Albumin ^b (g/dl)	Total Cholesterol ^c (mM)
AOAP1	Linked	1	5	...	Normal
		2	58	2.3	11
		3	38	2.5	8.2
AOAP2	Unknown	4	7	4.2 ^d	4.7
		4	10	4.4 ^d	5.6
AOAP3	Unknown	5	14	3.0	5
AOAP4	Linked	8	17	3.2 ^d	...
		8	18	2.7 ^d	5.2
AOAP5	Linked	12	15	3.5	3.8
AOAP6	Not linked	13	8	4.2	5.1
		14	15	3.7	4.3
AOAP7	Linked	15	11	3.8	5.6
AOAP8	Unknown	16	19	2.8	...
AOAP9	Unknown	17	20	2.7	7.6
		18	23	2.5	5.4
AOAP10	Not linked	20	52	4.1	5.2
AOAP11	Linked	22	21	3.4	7.3
AOAJ1 ^e	Linked	1	26	2.9	6.5
		2	25	3.0	6.2
		3	19	2.7	6
AOAJ2 ^e	Linked	4	18	2.9	6.8
		5	14	2.8	6.2

^a Numbering according to Barbot et al. (in press), for AOAP, and Tachi et al. (2000) for AOAJ.

^b Normal values range from 3.7 to 5.1 g/dl.

^c Normal values range from 3.6 to 5.6 mM.

^d Serum albumin in patients 4 and 8 was measured at two different times.

^e Serum albumin and total cholesterol values, from Tachi et al. (2000), are reported here for comparison.

cluded for this locus, since the two affected sibs in each family were discordant over the entire region from D9S1876 to D9S1853 (data not shown). In addition, the patients of families AOAP10 and -P13 showed no homozygosity over the critical interval despite consanguinity of the parents, further supporting the conclusion that nonallelic genetic heterogeneity is present among the Portuguese patients. The locus on 9p13 was named "AOA1". In the other five families (AOAP2, -P3, -P8, -P9, and -P14), we could make no conclusions about linkage to 9p13. Family AOAP3 may be excluded, since the single affected child is not homozygous for the critical interval despite second-degree consanguinity of the parents. Family AOAP9 had a LOD score of 0.75, supporting linkage. The maternal chromosome in each of the two patients shared alleles 3–11 of D9S1805–D9S165 with the Portuguese ancestral founding haplotype (fig. 2). The identification of additional markers is needed to establish whether AOAP9 is related to the same Portuguese founding event. The frequency of the four-allele founding haplotype in families showing linkage to 9p13 and in families with unknown linkage status was compared with the estimated frequency of this haplotype in the control group by the χ^2 test of homogeneity;

a statistically significant difference was found ($P < .001$), confirming the presence of linkage disequilibrium.

Four Japanese patients (cases 2–5 in Tachi et al. 2000) belonging to two families (here referred to as "AOAJ1" and "AOAJ2"), were subsequently analyzed. Patients 2 and 3 are sister and brother. Their older affected sister (patient 1) is deceased, and no DNA sample was available. Patients 4 and 5 are sisters. Consanguinity has not been documented in either of the families, which are not related to one another, although they both originate from Hokkaido Prefecture. The patients presented with recessive cerebellar ataxia with early onset (at age 2–5 years), hypoalbuminemia, peripheral neuropathy, and mild to moderate mental retardation (Tachi et al. 2000). The five patients had marked atrophy of the cerebellum. Patients 1–3 had pes cavus; none had scoliosis or dystonia. On further examination, all five patients also presented with oculomotor apraxia (K. Sasaki, personal communication). The two patients in each family were concordant for segregation of the AOA1 locus. In addition, the patients in family AOAJ2 were homozygous over a 14-marker haplotype, and the patients in family AOAJ1 were homozygous over an 8-marker haplotype (fig. 2), indicating ancient consanguinity. When second-

degree or more-distant consanguinity was assumed, the combined LOD score supporting linkage for AOAJ1 and AOAJ2 was ≥ 4.68 (table 1). Moreover, the two Japanese haplotypes were identical over five contiguous markers, which again suggested the existence of a common ancestor (fig. 2). Taken together, the data indicate that the loci for AOA1 and EOCA-HA are located within the same interval and that they may result from mutations in the same gene.

Levels of serum albumin and of total cholesterol, which are reduced and increased, respectively, in patients with EOCA-HA who have a long disease duration (Hanihara et al. 1995; Tachi et al. 2000), were subsequently measured in several Portuguese patients with AOA (table 2). Levels of serum albumin were indeed reduced in all five patients with AOA1 who had ≥ 15 years of disease duration, whereas levels of total serum cholesterol were high in three patients and were normal in two. In contrast, two patients (14 and 20) who were from families showing no linkage to *AOA1* and who also had ≥ 15 years of disease duration, were found to have both levels of serum albumin and levels of total cholesterol within the normal range.

Several recombinations in phase-known haplotypes, as well as recombinations inferred from heterozygosity in patients born from consanguineous parents, place the *AOA1* locus between D9S1791 (proximal) and D9S1853 (distal). In addition, the historic recombination in family AOAJ1 also involves marker D9S1817 (fig. 2), indicating that it is the proximal marker closest to the *AOA1* locus. On the other hand, comparison of the five Portuguese families that share an ancestral haplotype also points to the occurrence of a historic recombination involving D9S1878, on the distal side (fig. 2). The estimated genetic distance between D9S1817 and D9S1878 is ~ 2 cM. The gene encoding cytosolic aconitase (also known as "IRE-BP1") is located close to D9S1878 and appears to be a good candidate gene for AOA1, since IRE-BP1 controls cytosolic iron homeostasis (Gray et al. 1993; Hirling et al. 1994), and cytosolic aconitase is secondarily inactivated in Friedreich ataxia (Rötig et al. 1997). We identified two CA/TG microsatellite polymorphisms in a bacterial-artificial-chromosome clone, RP11-334P12 (GenBank), containing IRE-BP1 (primer pairs MS1IRE-BP1 [5'-cttggctactatagcc-3' and 5'-cacttgtagttttccatc-3'] and MS2IRE-BP1 [5'-gtctctagtaagaacatac-3' and 5'-ctctaaaacagtgcctc-3']), and tested them on the Portuguese and Japanese families with AOA. The recombinations indicated that IRE-BP1 is excluded from the *AOA1* critical interval and is located just distal to D9S1878 (fig. 2).

AOA has been recognized in diverse populations, including in the Japanese population (Inoue et al. 1971; Araie et al. 1977; Awaya et al. 1985, 1986; Aicardi et al. 1988) and, so far, appears to represent the second-

most-common cause of recessive ataxia in Portugal (Moreira et al. 1999; Barbot et al., in press). On the other hand, a new entity, EOCA-HA, is receiving growing attention in Japan (Uekawa et al. 1992; Fukuhara et al. 1995; Hanihara et al. 1995; Sekijima et al. 1998; Tachi et al. 2000). In the present study we have identified the *AOA1* locus on 9p13 in a significant portion of the Portuguese families, and we have demonstrated locus heterogeneity in AOA. Surprisingly, we found that two Japanese families with EOCA-HA show linkage to the same region. Clinical and biochemical reevaluation revealed that our patients with EOCA-HA indeed had oculomotor apraxia and that the Portuguese patients with AOA1 had hypoalbuminemia. It now becomes important that all patients diagnosed with EOCA-HA be reevaluated for oculomotor apraxia and that all patients diagnosed with AOA be reevaluated for hypoalbuminemia and for hypercholesterolemia. None of these features can, however, be regarded as diagnostic criteria in early cases, since oculomotor apraxia usually develops only a few years after the onset of cerebellar ataxia (Barbot et al., in press), and since hypoalbuminemia is marked only in patients in their 20s (Hanihara et al. 1995). Linkage analysis and more-precise clinical criteria for diagnosis of AOA1 should now allow for better diagnosis of the disease, and for an estimation of the incidence of this condition worldwide.

The existence of genetic heterogeneity among patients with AOA is likely to complicate the accurate diagnosis of this condition. Among families that do not show linkage to 9p13, patients from family AOAP6 are clinically indistinguishable from patients with AOA1, whereas patients from family AOAP10 additionally show optic atrophy, found after extended duration of the disease in all three patients (one deceased). On the other hand, mental retardation does not seem to be either an exclusion criterion or an inclusion criterion for AOA1, since all five Japanese patients showing linkage had mild to moderate mental retardation (Tachi et al. 2000), whereas it was not a feature of the Portuguese patients (Barbot et al., in press), suggesting possible allelic heterogeneity. The precise mapping of the *AOA1* locus within a 2-cM region should prompt the identification of the defective gene and of the corresponding mutations and should therefore help to answer these questions.

Acknowledgments

We wish to express our gratitude to all patients and families for their participation and for their collection of genealogical data, and to Drs. R. Chorão, C. Ferreira, I. Fineza, K. Dias, J. P. Monteiro, J. C. Moniz, M. M. Costa, and K. Sasaki. We are indebted to Prof. J.-L. Mandel, for support and fruitful discussions; to our colleagues in the research and diagnostic laboratories, for support and help in all data verification; and

to D. Sommer-Stephan, S. Vicaire, E. Troesch, F. Ruffenach, and I. Colas, for excellent technical help. Family characterization and DNA sampling were supported by Comissão de Fomento da Investigação em Cuidados de Saúde, Portuguese Ministry of Health (grant 207/99) and by grants from Fundação para a Ciência e a Tecnologia (Portuguese Ministry of Science and Technology) and from the Portuguese Ministry of Health (projects STRDA/C/SAU/277/92 and PECS/C/SAU/219/95). Genetic studies were supported by funds from the Institut National de la Santé et de la Recherche Médicale, the Centre National de la Recherche Scientifique, the Hôpitaux Universitaires de Strasbourg, and the Human Frontier Science Program (to M.K.). M.C.M. has graduate fellowship PRAXIS XXI/BD/18169/98, and P.M. has technical fellowship PRAXIS/P/SAU/13226/2000/BTI, from Fundação para a Ciência e a Tecnologia–Portugal.

Electronic-Database Information

Accession numbers and URLs for data in this article are as follows:

- Fondation Jean Dausset–CEPH, <http://www.cephb.fr/> (for the CEPH–Généthon integrated genetic map and for distances between chromosome 9p markers)
 GenBank, <http://www.ncbi.nlm.nih.gov/Genbank/index.html> (for BAC sequence of RP11-334P12)
 GeneMap'99, <http://www.ncbi.nlm.nih.gov/genemap99/> (for marker order, mapped genes and expressed-sequence tags)
 Généthon, <http://www.genethon.fr/> (for markers used in the refinement of the candidate zone on chromosome 9p)
 Online Mendelian Inheritance in Man (OMIM), <http://www.ncbi.nlm.nih.gov/Omim/> (for AT [MIM 208900], SCA2 [MIM 601517], AOA [MIM 208920], and Friedrich ataxia [MIM 229300])
 Sanger Centre, The, <http://www.sanger.ac.uk>

References

- Aicardi J, Barbosa C, Andermann E, Andermann F, Morcos R, Ghanem Z, Fukuyama Y, Awaya Y, Moe P (1988) Ataxia-ocular motor apraxia: a syndrome mimicking ataxia-telangiectasia. *Ann Neurol* 24:497–502
- Araie M, Ozawa T, Awaya Y (1977) A case of congenital ocular motor apraxia with cerebellospinal degeneration. *Jpn J Ophthalmol* 21:355–365
- Awaya Y, Sugie H, Fukuyama Y (1985) A variant type of early onset spinocerebellar degeneration with ocular motor apraxia and choreoathetosis. *Jpn J Pediatr* 89:2651–2658
- (1986) A hereditary variant of spinocerebellar degeneration associated with choreoathetosis and ocular motor apraxia of early onset. *Acta Paediatr Jpn* 28:271
- Barbot C, Coutinho P, Choro R, Ferreira C, Barros J, Fineza I, Dias K, Monteiro JP, Guimarães A, Mendonça P, Moreira MC, Sequeiros J. Recessive ataxia with ocular apraxia: review of 22 Portuguese patients. *Arch Neurol* (in press)
- Ben Hamida C, Doerflinger N, Belal S, Linder C, Reutenauer L, Dib C, Gyapay G, Vignal A, Le Paslier D, Cohen D, Pandolfo M, Mokini V, Novelli G, Hentati F, Ben Hamida M, Mandel J-L, Koenig M (1993) Localization of Friedreich ataxia phenotype with selective vitamin E deficiency to chromosome 8q by homozygosity mapping. *Nat Genet* 5:195–200
- Dib C, Fauré S, Fizames C, Samson D, Drouot N, Vignal A, Millasseau P, Marc S, Hazan J, Seboun E, Lathrop M, Gyapay G, Morissette J, Weissenbach J (1996) A comprehensive genetic map of the human genome based on 5,264 microsatellites. *Nature* 380:152–154
- Fukuhara N, Nakajima T, Sakajiri K, Matsubara N, Fujita M (1995) Hereditary motor and sensory neuropathy associated with cerebellar atrophy (HMSNCA): a new disease. *J Neurol Sci* 133:140–151
- Gray NK, Quick S, Goossen B, Constable A, Hirling H, Kuhn LC, Hentze MW (1993) Recombinant iron-regulatory factor functions as an iron-responsive-element-binding protein, a translational repressor and an aconitase: a functional assay for translational repression and direct demonstration of the iron switch. *Eur J Biochem* 218:657–667
- Hanihara T, Kubota H, Amano N, Iwamoto H, Iwabuchi K (1995) Siblings of early onset cerebellar ataxia with hypoalbuminemia. *Rinsho Shinkeigaku* 35:83–86
- Hirling H, Henderson BR, Kuhn LC (1994) Mutational analysis of the [4Fe-4S]-cluster converting iron regulatory factor from its RNA-binding form to cytoplasmic aconitase. *EMBO J* 13:453–461
- Inoue N, Izumi K, Mawatari S, Shida K, Kuroiwa Y (1971) Congenital ocular motor apraxia and cerebellar degeneration—report of two cases. *Rinsho Shinkeigaku* 11:855–861
- Kubota H, Sunohara N, Iwabuchi K, Hanihara A, Nagatomo H, Amano N, Kosaka K (1995) Familial early onset cerebellar ataxia with hypoalbuminemia (in Japanese). *No To Shinkei* 47:289–294
- Lathrop GM, Lalouel JM, Julier C, Ott J (1985) Multilocus linkage analysis in humans: detection of linkage and estimation of recombination. *Am J Hum Genet* 37:482–498
- Morcos R, Andermann F, Andermann E, Ghanem, Awaya Y, Fukuyama Y (1982) Ataxia-ocular motor apraxia: a rare autosomal recessive disorder. *Neurology* 32:A82
- Moreira MC, Miranda C, Barbot C, Coutinho P, Sequeiros J (1999) Recessive ataxias in Portugal. *Arq Med* 13:39–45
- Rötig A, de Lonlay P, Chretien D, Foury F, Koenig M, Sidi D, Munnich A, Rustin P (1997) Aconitase and mitochondrial iron-sulphur protein deficiency in Friedreich ataxia. *Nat Genet* 17:215–217
- Sekijima Y, Ohara S, Nakagawa S, Tabata K, Yoshida K, Ishigame H, Shimizu Y, Yanagisawa N (1998) Hereditary motor and sensory neuropathy associated with cerebellar atrophy (HMSNCA): clinical and neuropathological features of a Japanese family. *J Neurol Sci* 158:30–37
- Silva MC, Coutinho P, Pinheiro CD, Neves JM, Serrano P (1997) Hereditary ataxias and spastic paraplegias: methodological aspects of a prevalence study in Portugal. *J Clin Epidemiol* 50:1377–1384
- Tachi N, Kozuka N, Ohya K, Chiba S, Sasaki K (2000) Hereditary cerebellar ataxia with peripheral neuropathy and mental retardation. *Eur Neurol* 43:82–87
- Uekawa K, Yuasa T, Kawasaki S, Makibuchi T, Ideta T (1992) A hereditary ataxia associated with hypoalbuminemia and hyperlipidemia—a variant form of Friedreich's disease or a new clinical entity? *Rinsho Shinkeigaku* 32:1067–1074