

Gastric Juice Protects Against the Development of Esophageal Adenocarcinoma in the Rat

Adrian P. Ireland, F.R.C.S.(I),* Jeffrey H. Peters, M.D.,* Thomas C. Smyrk, M.D.,†
Tom R. DeMeester, M.D.,* Geoffrey W. B. Clark, F.R.C.S.(Ed),* Sidney S. Mirvish, Ph.D.,‡
and Thomas E. Adrian, Ph.D.§

From the Department of Surgery, University of Southern California, School of Medicine, Los Angeles, California; the Department of Pathology, Clarkson Memorial Hospital,† Omaha, Nebraska; the Eppley Institute for Research in Cancer, University of Nebraska Medical Center,‡ Omaha, Nebraska; and the Department of Biochemical Sciences, Creighton University,§ Omaha, Nebraska*

Objective

The authors investigate the effects of gastric juice on tumorigenesis in a rat model of esophageal adenocarcinoma.

Summary Background Data

In rats treated with the carcinogen methyl-n-amylnitrosamine, squamous cancer of the esophagus develops in a time- and dose-dependent manner. When methyl-n-amylnitrosamine treatment is preceded by an operation to induce reflux of duodenal and gastric juice into the esophagus, there is an increased yield of esophageal tumors, many of which are adenocarcinomas. When only gastric juice refluxes into the esophagus, the tumor yield is less and adenocarcinomas are not found.

Methods

Two hundred seventy 8-week old Sprague-Dawley rats were studied. Twenty unoperated rats served as controls. The remaining rats underwent the following operations: esophagoduodenostomy with gastric and vagal preservation to induce duodenogastroesophageal reflux (n = 48); esophagoduodenostomy with antrectomy and Billroth 1 reconstruction to produce reflux of duodenogastric juice with the exclusion of the antrum (n = 53); esophagoduodenostomy with proximal gastrectomy to induce hypergastrinemia and reflux of duodenogastric juice with exclusion of the body and forestomach (n = 51); esophagoduodenostomy plus total gastrectomy to produce reflux of duodenal juice alone (n = 50); and esophagoduodenostomy with vagal and gastric preservation but with division of the duodenum just beyond the pylorus and reimplantation into the jejunum, 13 cm distal to the esophagoduodenostomy. This produced reflux of duodenal juice with gastric juice diverted downstream, (n = 48). At 10 weeks of age, all rats were given 4 weekly doses of carcinogen (methyl-n-amylnitrosamine, 25 mg/kg intraperitoneally), and survivors were killed at 36 weeks of age.

Results

The prevalence rate of esophageal adenocarcinoma was 30% in rats with duodenogastroesophageal reflux and 87% in rats with reflux of duodenal juice alone. Fifty-six

percent of rats with reflux of duodenogastric juice with exclusion of the antrum and 72% of rats with reflux of duodenogastric juice with the exclusion of the body and forestomach developed adenocarcinoma, showing a progressive increase in the prevalence of adenocarcinoma as less gastric juice was permitted to reflux with duodenal juice into the esophagus.

Conclusion

In this rat model, the presence of gastric juice in refluxed duodenal juice protects against the development of esophageal adenocarcinoma. The protective effect appears to be due to acid secretion from the stomach. Continuous profound acid suppression therapy may be detrimental by encouraging esophageal metaplasia and tumorigenesis in patients with duodenogastric reflux.

For unknown reasons, the incidence of adenocarcinoma of the esophagus and cardia in the United States is increasing at a rate faster than that of any other tumor.¹⁻³ The presence of Barrett's metaplasia with specialized intestinal epithelium is the main risk factor for these tumors. This epithelium is an acquired condition after a peculiar type of healing of esophageal mucosal injury from reflux disease.⁴ Longitudinal studies have documented progression from metaplasia to dysplasia to carcinoma, thereby linking the common malady of gastroesophageal reflux disease with one of the most lethal human malignancies.^{5,6}

The gastric juice refluxing into the esophagus in patients with gastroesophageal reflux disease contains gastric secretions, such as acid and pepsin, and biliary and pancreatic secretions, such as bile and trypsin, which have refluxed into the stomach from the duodenum.

Early studies in the rat⁷⁻¹⁰ showed that reflux of combined duodenal and gastric juices into the esophagus caused severe esophagitis in all animals. Reflux of duodenal juice resulted in the same degree of esophageal injury in gastrectomized animals.

Evidence from both human clinical studies¹¹⁻¹⁷ and animal models¹⁸⁻²⁷ incriminate esophageal exposure to duodenal juice as a key factor in the genesis of specialized intestinal metaplasia and the development of adenocarcinoma.

It has been shown²⁸ that in rats treated with the esophageal specific carcinogens 2,6-dimethylnitrosomorpho-

line or methyl-n-amyl nitrosamine, squamous esophageal cancer develops in a time- and dose-dependent fashion. The organ-specific effect of the carcinogen is probably due to the presence of specific cytochrome p450 isoenzymes that activate the carcinogen in the target organ.²⁹ When the rat esophagus is exposed to a mixture of gastric and duodenal juice by either esophagejunostomy²⁴ or esophagoduodenostomy²⁵ and carcinogen is administered, the yield of tumors at 22 to 24 weeks postoperatively is increased. There also is a change in histology because in addition to squamous carcinomas, adenocarcinomas are found. In contrast, when there is an increased esophageal exposure to gastric juice without duodenal juice²⁵ and rats are treated with carcinogen, there is no increase in tumor yield and adenocarcinomas are not found.

Further experiments with this model system have shown that reflux of both pancreatic and biliary components of duodenal juice contribute to the development of adenocarcinoma²⁶ and that a high-fat diet promotes tumorigenesis.²⁷ The aim of the current study was to investigate the role of gastric juice in the genesis of esophageal adenocarcinoma in this rat model.

MATERIALS AND METHODS

Two hundred seventy 8-week old male Sprague-Dawley (Harlan, Indianapolis, IN) rats were studied. Twenty of these served as unoperated controls. The remaining animals underwent the surgical procedures outlined.

Operations were performed after an acclimatization period of 4 days. Rats were kept in hanging cages on a 12-hour light-and-dark cycle at a temperature of 70 F and a humidity of 60%. Water and standard chow (Teklan Rodent diet 8604, Harlan) were given *ad libitum*. Food was discontinued the evening before surgery, and water was discontinued on the morning of surgery. Rats were anesthetized with an intramuscular injection of xylazine hydrochloride (18 mg/kg) and ketamine (72 mg/kg), with further doses administered intraperitoneally during surgery, as required. Before closure, 0.5 to

Presented at the 116th Annual Meeting of the American Surgical Association, April 18-20, 1996, Phoenix, Arizona.

Supported by grant number IRG-21-34 from the American Cancer Society (Dr. Peters) and grant RO1-CA-35168 and core grant 35627 from the National Cancer Institute and core grant SIG-16 from the American Cancer Society (to Dr. Mirvish and Eppley Institute).

Address reprint requests to Tom R. DeMeester, M.D., University of Southern California School of Medicine, Department of Surgery, 1510 San Pablo Street, Suite 514, Los Angeles, CA 90033-4612.

Accepted for publication April 22, 1996.

* Dr. Clark's current address is the Department of Surgery, University Hospital of Wales, Cardiff, United Kingdom.

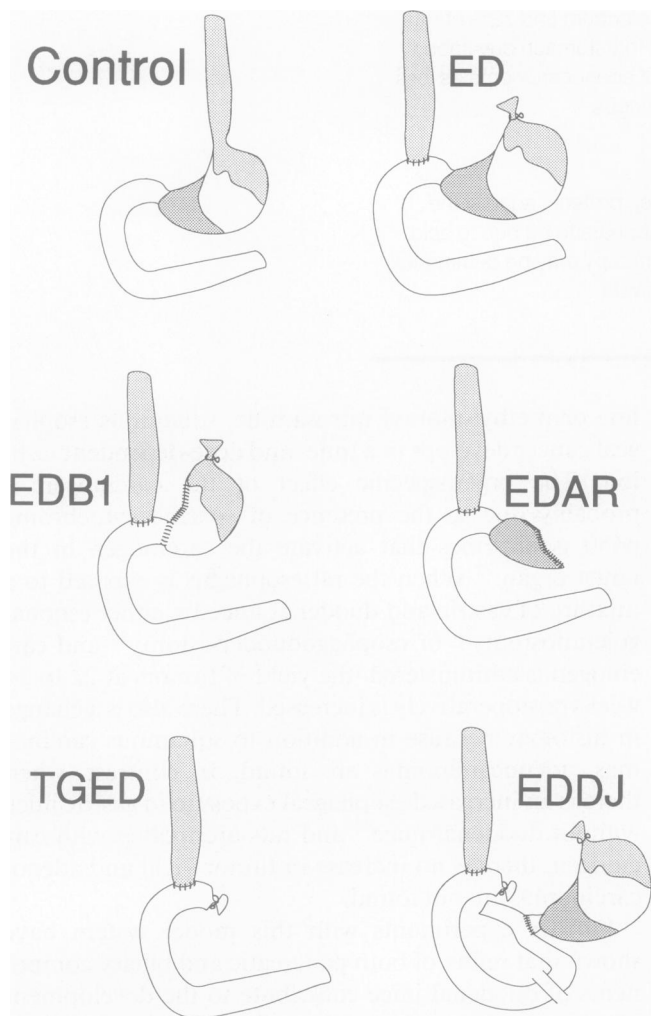


Figure 1. Reflux models. The normal anatomy of the rat stomach is depicted in a control. There is a squamous forestomach that is shaded the same as the esophagus. The distal shaded area in the stomach represents the antrum. In the EDDJ model, the distance between the esophagoduodenostomy and the duodenojejunostomy was 13 cm. The operative procedures are described in the section on reflux models. ED = esophagoduodenostomy alone; EDB1 = esophagoduodenostomy, antrectomy with Billroth 1 reconstruction; EDAR = esophagoduodenostomy, proximal gastrectomy, and antral retention; TGED = total gastrectomy with esophagoduodenostomy; EDDJ = esophagoduodenostomy, division of the proximal duodenum, and implantation of the duodenum attached to the stomach into the jejunum.

1.5 mL of 0.9% sodium chloride was instilled into the peritoneal cavity. Water was permitted when the rats awoke, and chow was provided the next day.

Two weeks after the operation, rats were transferred to a chemical fume hood and injected intraperitoneally once a week for 4 weeks with the carcinogen methyl-n-amyl nitrosamine at a dose of 25 mg/kg. This permitted 2 weeks of recovery time for the operated rats. The carcinogen was diluted in 0.9% sodium chloride so that 1 mL of solution was administered for each 100-g weight

of rat (concentration 2.5 mg/mL). The synthesis of the carcinogen has been described previously.²⁷ Control (unoperated) rats were injected similarly at 10 weeks of age.

Rats were weighed regularly during the course of the experiment. Any rats that became ill or that lost weight rapidly were killed. The experiment was ended when rats were 36 weeks of age, and the surviving rats were killed.

Reflux Models

All operated rats underwent esophagoduodenostomy. The esophagus was separated from the posterior vagal trunk and left gastric vessels, tied with silk at the gastroesophageal junction, and divided 2 mm proximal to the tie. The anterior vagus was divided when the esophagus was cut. A 4-mm duodenotomy was made 1 cm distal to the pylorus, and the esophagus was anastomosed to the duodenum, end to side, with eight interrupted stitches of 7-0 polypropylene (Fig. 1).^{25,27}

Esophagoduodenostomy Alone

In 48 animals, esophagoduodenostomy was the only procedure performed. The purpose of the anastomosis was to induce the reflux of both gastric and duodenal juice into the esophagus (Table 1). This preparation is denoted as ED in Figure 1.

Esophagoduodenostomy with Resection of the Antrum and Gastroduodenostomy

Fifty-three rats underwent esophagoduodenostomy followed by resection of the antrum. The stomach was divided along a line connecting points half the distance between the pylorus and the squamous forestomach on the greater curvature and where the forestomach meets the glandular stomach on the lesser curvature. This line was chosen because it approximated the transition between the antral and body mucosa on histologic examination of resected specimens. The left gastric vessels and posterior vagal trunk were preserved. The distal duodenum was anastomosed to the stomach, with 6-0 polyglactin (Billroth 1). In this model, the esophagus is exposed to a mixture of duodenogastric juice, with the exclusion of the antrum. Consequently, less acid should be produced by the stomach in this preparation compared with esophagoduodenostomy alone, resulting in lower acid exposure to the esophagus. This preparation is denoted as EDB1 in Figure 1.

Esophagoduodenostomy with Resection of the Proximal Stomach and Retention of the Antrum

In 51 rats, the proximal stomach was resected after esophagoduodenostomy. The left gastric vessels and posterior vagus were ligated and cut, the stomach was divided through the aforementioned line, and the distal

Table 1. EXPERIMENTAL DESIGN

	Control	ED	EDB1	EDAR	TGED	EDDJ
MNAN	+	+	+	+	+	+
Vagotomy*	—	—	—	+	+	—
Gastrin†	↔	↔	↓	↑	↓	↔
Juices refluxing into the esophagus						
Duodenal juice	—	+	+	+	+	+
Gastric juice‡	—	+++	++	+	—	—

ED = esophagoduodenostomy alone; EDB1 = esophagoduodenostomy, antrectomy with Billroth 1 reconstruction; EDAR = esophagoduodenostomy, proximal gastrectomy, and antral retention; TGED = total gastrectomy with esophagoduodenostomy; EDDJ = esophagoduodenostomy, division of the proximal duodenum, and implantation of the duodenum attached to the stomach into the jejunum.

* All operated rats had division of the small anterior vagus nerve on transection of the esophagus. In this context vagotomy refers to the status of the larger posterior nerve.

† Predicted change in plasma gastrin; a retained antrum with resection of most of the acid secreting part of the stomach should result in hypergastrinemia in the EDAR group.

‡ The predicted relative amounts of acid permitted to reflux into the esophagus.

stomach was closed with 6-0 polyglactin. In this preparation, there is increased esophageal exposure to duodenogastric juice, with the exclusion of the body and forestomach. The preparation should induce hypergastrinemia because most of the acid-secreting part of the stomach has been resected. This preparation is denoted as EDAR in Figure 1.

Total Gastrectomy with Esophagoduodenostomy

In 50 rats, a total gastrectomy was performed after the esophagoduodenostomy. The posterior vagus and left gastric vessels were ligated and cut, and the duodenal stump was tied with silk. In this preparation, the esopha-

gus is exposed only to duodenal juice. This preparation is denoted as TGED in Figure 1.

Esophagoduodenostomy with Division of the Proximal Duodenum and Implanting the Duodenum Attached to the Stomach into the Jejunum

Forty-eight rats had an esophagoduodenostomy, after which the duodenum was divided between the esophagoduodenostomy and the pylorus. The distal end of the duodenum was tied with silk. The duodenum attached to the stomach was anastomosed with interrupted 7-0 polypropylene to the jejunum, end to side, 3 cm distal to

Table 2. STUDY POPULATION

	Control	ED	EDB1	EDAR	TGED	EDDJ
Entered	20	48	53	51	50	48
Excluded						
Early*	0	7	11	6	7	2
Carcinogen†	1	1	1	3	0	3
Late‡	1	0	0	3	4	3
Analyzed						
Early death§	0	1	6	6	10	2
Killed	18	39	35	33	29	38
Total analyzed¶	18	40	41	39	39	40

ED = esophagoduodenostomy alone; EDB1 = esophagoduodenostomy, antrectomy with Billroth 1 reconstruction; EDAR = esophagoduodenostomy, proximal gastrectomy, and antral retention; TGED = total gastrectomy with esophagoduodenostomy; EDDJ = esophagoduodenostomy, division of the proximal duodenum, and implantation of the duodenum attached to the stomach into the jejunum.

Values are the number of rats entering the study and numbers excluded by group.

* Early exclusions, rats that died before injection with carcinogen.

† Carcinogen death exclusions, rats that died during the course of carcinogen administration.

‡ Late exclusions, rats that died or were killed after carcinogen administration and before the end of the experiment that are excluded from analysis.

§ Rats that are included in the analysis that died or were killed before the end of the experiment.

|| Number of rats, in each group completing the entire study period.

¶ Number of rats used for analysis.

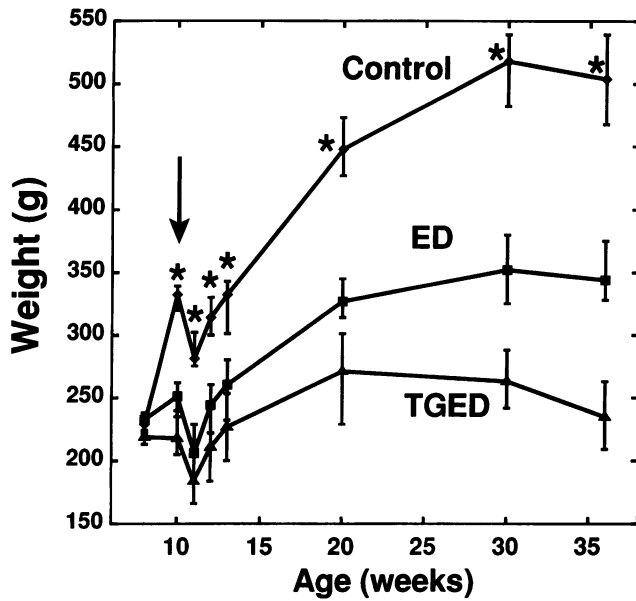


Figure 2. Time course of weight changes in control, ED, and TGED groups. Points represent the median and the error bars represent the interquartile range. The arrow denotes the time of injection of the first dose of carcinogen. Rats in the EDB1 group showed a weight profile similar to ED group. The EDAR and EDDJ groups showed a weight pattern intermediate between the TGED and ED groups. The decrease in weight at the last point plotted is due to an overnight fast of the rats before death. *Controls > ED > TGED, $p < 0.001$. ED = esophagoduodenostomy alone; TGED = total gastrectomy with esophagoduodenostomy; EDB1 = esophagoduodenostomy, antrectomy with Billroth 1 reconstruction; EDAR = esophagoduodenostomy, proximal gastrectomy, and antral retention; EDDJ = esophagoduodenostomy, division of the proximal duodenum, and implantation of the duodenum attached to the stomach into the jejunum.

the ligament of Treitz. The distance between the esophagoduodenostomy and the duodenojejunostomy was 13 cm. Consequently, the esophagus is exposed only to du-

odenal juice with gastric juice discharged into the intestine distally. Preservation of the stomach maintains its hormonal effects. This preparation is denoted as EDDJ in Figure 1.

Handling of Specimens

Before death, the rats were fasted overnight and anesthetized as for surgery. Five mL of blood was drawn from the inferior vena cava, emptied into a tube containing edetic acid, and placed on ice. The sample was centrifuged at 30,000 rpm for 30 minutes at 4 C, and the hematocrit level was estimated. The rats were killed with an overdose of phenobarbital. The esophagus was resected from below the larynx to the stomach in controls and to the duodenum in operated rats. One to 2 mm of duodenal mucosa was left attached to the specimen. The esophagus was opened longitudinally, the length and diameter were measured, and the organ was weighed and photographed. The esophagus was divided into 2 to 3 longitudinal strips that were rolled up like a jelly roll, fixed in 10% buffered formalin, and embedded in paraffin blocks for histologic examination.

Histologic Analysis

Histologic sections were read in a blind fashion. The jelly-rolled, paraffin-embedded tissues were cut and stained with hematoxylin and eosin. Selected specimens were stained with mucicarmine. The esophagus was examined for the presence of acute inflammation, ulceration, chronic inflammation, squamous hyperplasia, benign papillomas, metaplastic columnar epithelium, squamous carcinoma, and adenocarcinoma. A specimen was defined as having squamous hyperplasia when there was papillary elongation or basal cell

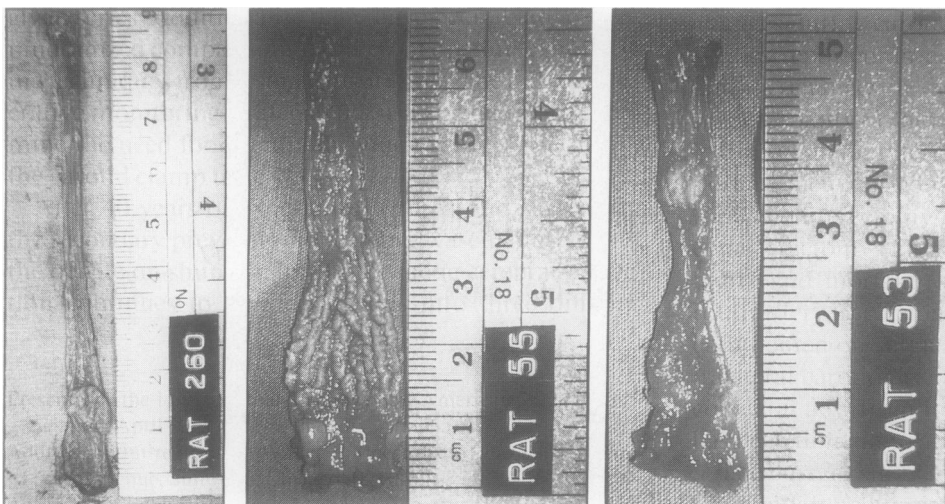


Figure 3. Gross pictures of resected esophagi. The esophagus on the left was excised from a control rat and the two on the right are from operated rats. There is a benign papilloma visible in the control rat and a small tumor visible in the distal esophagus of the operated rat in the middle. Histologic examination of the lower part of the esophagus of the rat on the right revealed severe papillomatosis. Compared with the control rats, the esophagus of the operated rats is shorter and wider. The esophagus of the operated rats has a tree bark appearance.

Table 3. SUMMARY OF GROSS RAT AND ESOPHAGEAL CHARACTERISTICS

	Control	ED	EDB1	EDAR	TGED	EDDJ
n	18	40	41	39	39	40
Gross characteristics of esophagus						
Length* (mm)	95 (93-98)	69 (64-74)	72 (69-76)	68 (62-71)	63 (59-68)	68 (64-72)
Diameter† (mm)	7 (6-7)	14 (13-15)	15 (13-16)	14 (13-15)	14 (12-17)	15 (14-18)
Weight‡ (mg/100 g)	62 (56-67)	218 (186-250)	247 (201-291)	238 (186-307)	316 (239-377)	332 (251-406)
Rat characteristics						
Hematocrit§ (%)	48 (47-51)	37 (33-43)	41 (37-45)	35 (27-43)	47 (34-54)	34 (24-39)
Body weight (g)	504 (468-539)	337 (296-365)	344 (328-375)	279 (248-324)	235 (209-263)	300 (281-331)

ED = esophagoduodenostomy alone; EDB1 = esophagoduodenostomy, antrectomy with Billroth 1 reconstruction; EDAR = esophagoduodenostomy, proximal gastrectomy, and antral retention; TGED = total gastrectomy with esophagoduodenostomy; EDDJ = esophagoduodenostomy, division of the proximal duodenum, and implantation of the duodenum attached to the stomach into the jejunum.

Data are presented as the median with the interquartile range in parentheses.

* Esophageal length, significant differences: Control > rest, EDB1 > (ED + EDAR + EDDJ) > TGED.

† Esophageal diameter, significant differences: Control < rest, ED < EDDJ.

‡ Weight of esophagus (mg esophagus/100 g of rat). Significant differences: Control < rest, (ED + EDAR + EDB1) < (TGED + EDDJ).

§ Hematocrit, significant differences: Control > rest except TGED, TGED > (EDDJ + EDAR + ED), EDB1 > (EDAR + EDDJ).

|| Weight of rat at 36 weeks postoperatively, significant differences: Control heavier than rest, (EDB1 + ED) > (EDDJ + EDAR) > TGED.

hyperplasia. "Papillomatosis" was the term chosen to describe a common finding of basal cell hyperplasia, papillary elongation, and hyperkeratosis. The degree of papillomatosis was progressively graded from 0 to 4. A squamous papilloma was diagnosed when there was a localized papillary proliferation of benign squamous epithelium.

Columnar metaplasia was defined as the presence of unequivocal columnar epithelium above the anastomosis. Tumors were defined on the basis of malignant cells infiltrating the mucosa or deeper layers of the esophageal wall. Squamous tumors were defined as tumors with a pure squamous morphology. Tumors with definite adenomatous elements were classified as adenocarcinoma.

Table 4. PREVALENCE OF HISTOLOGICAL ABNORMALITIES

	Control	ED	EDB1	EDAR	TGED	EDDJ
n	18	40	41	39	39	40
Squamous hyperplasia	(18)	(100)	(100)	(100)	(100)	(100)
Papillomatosis						
Mild	(6)	(100)	(100)	(100)	(100)	(100)
Severe*	(0)	(56)	(65)	(51)	(59)	(77)
Inflammation						
Acute†	(0)	(38)	(52)	(49)	(59)	(66)
Ulceration‡	(0)	(23)	(38)	(35)	(38)	(56)
Chronic§	(17)	(72)	(85)	(78)	(48)	(82)
Benign papilloma	2 (11)	7 (18)	3 (7)	1 (3)	4 (10)	2 (5)
Metaplasia	0 (0)	4 (10)	11 (27)	4 (10)	9 (23)	14 (35)
Invasive tumors						
Adenocarcinoma	0 (0)	12 (30)	23 (56)	28 (72)	34 (87)	35 (88)
Squamous carcinoma	0 (0)	19 (48)	23 (56)	19 (49)	25 (64)	16 (40)

ED = esophagoduodenostomy alone; EDB1 = esophagoduodenostomy, antrectomy with Billroth 1 reconstruction; EDAR = esophagoduodenostomy, proximal gastrectomy, and antral retention; TGED = total gastrectomy with esophagoduodenostomy; EDDJ = esophagoduodenostomy, division of the proximal duodenum, and implantation of the duodenum attached to the stomach into the jejunum. Data are presented as the number of rats in each group with the pathological finding with prevalence (%) in parentheses.

* Prevalence of severe papillomatosis, (grade 2 or greater), significant differences: Control < all, $p < 0.001$, EDAR < EDDJ, $p = 0.03$.

† Acute inflammation, significant differences: Control < all, $p < 0.001$, ED < EDDJ, $p = 0.02$.

‡ Ulceration, significant differences: Control < (EDAR + EDB1 + EDDJ + TGED), $p < 0.002$, Control < ED, $p = .04$, ED < EDDJ, $p < 0.005$.

§ Chronic inflammation, significant differences: Control < (ED + EDAR + EDB1 + EDDJ), $p < 0.001$. Control < TGED, $p = 0.04$, TGED < (EDAR + EDB1 + EDDJ), $p < 0.009$.

|| Columnar metaplasia, significant differences: Control < (EDB1 + EDDJ + TGED), $p < 0.05$, EDDJ > (ED + EDAR), $p < 0.02$.

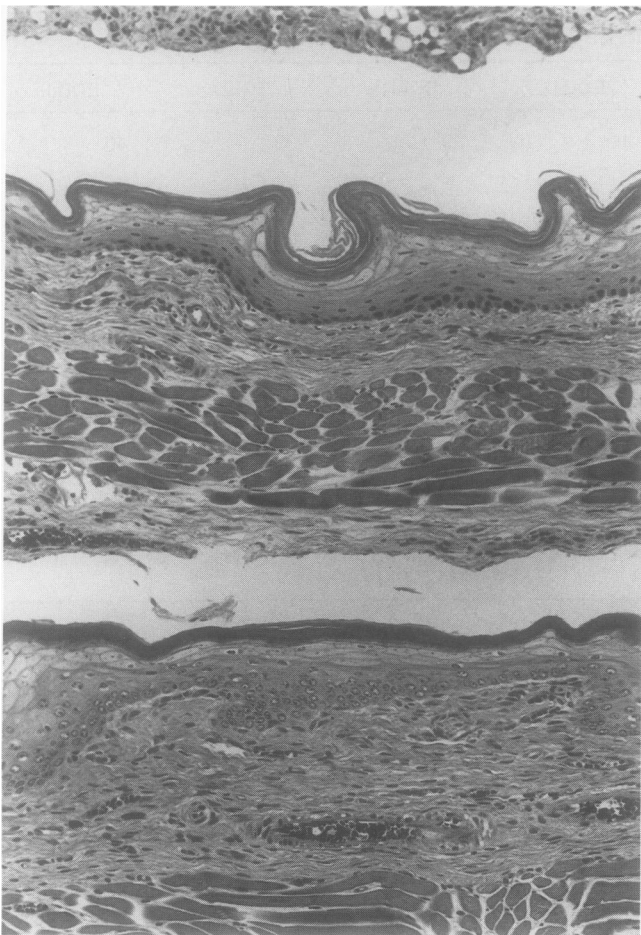


Figure 4. An example of the esophagus from a control rat (original magnification $\times 13.2$). This shows the normal appearance of the rat esophagus. The esophagus has been jelly-rolled to permit examination of the entire length of the esophagus. The middle section of the figure shows a longitudinal section of esophagus with adjacent layers of the jelly roll above and below.

For each tumor, the diameter, location, and depth of invasion were measured. Location was recorded as the distance between the lower border of the tumor and duodenal anastomosis. Depth of invasion was classed as confined to the mucosa or submucosa, into the muscularis propria, and through the muscularis propria.

Exclusions

Table 2 summarizes the number of rats entered in the study and those excluded. The reasons for exclusion were the death of a rat before the first rat to die of an esophageal tumor and the inability to evaluate the esophageal mucosa for tumor. Thirty-three rats (12%) died perioperatively before the administration of carcinogen. Nine rats died during carcinogen administration. Death was due to pneumonia

with severe esophagitis in two rats, severe ulcerative esophagitis in two rats, and for undetermined reasons in five rats. Eleven rats that died subsequently were excluded. Three of these died without an esophageal tumor before the first tumor death occurred. In eight rats, it was impossible to evaluate the esophagus for the presence of tumor because of massive abscess in seven and autolysis in one.

Twenty-four rats that did not survive for the entire study period but died after the first tumor death 72 days after surgery are included in the analysis. Eighteen were killed because of rapidly decreasing weight, and six died. Death occurred at 77, 110, 122, 128, 140, 150, 160 to 170 (5 rats), 170 to 179 (5 rats), and 180 to 195 (8 rats) days after the operation. All but two of these rats had tumors. After the exclusions, 217 rats were included in the analysis.

Statistics

Before beginning the study, a sample size analysis (power 0.8, $p = 0.05$) indicated that a study group of 40 animals was

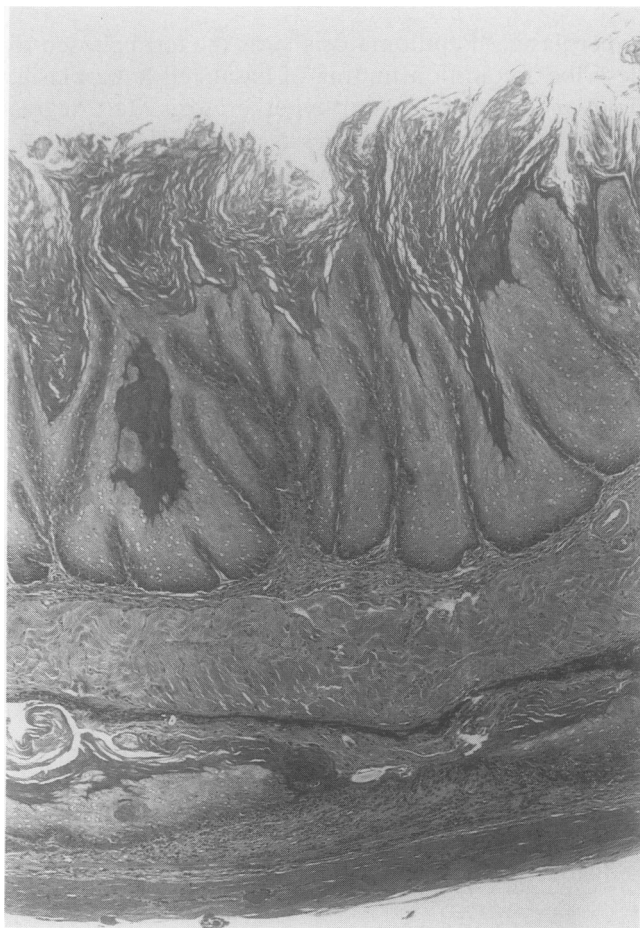

Figure 5. An example of papillomatosis (original magnification $\times 13.2$). Most of the operated rats showed evidence of papillomatosis, which was characterized by basal cell hyperplasia, papillary elongation, and hyperkeratosis. In comparison to the esophagus of a control rat (Fig. 4), the esophagus is thickened.

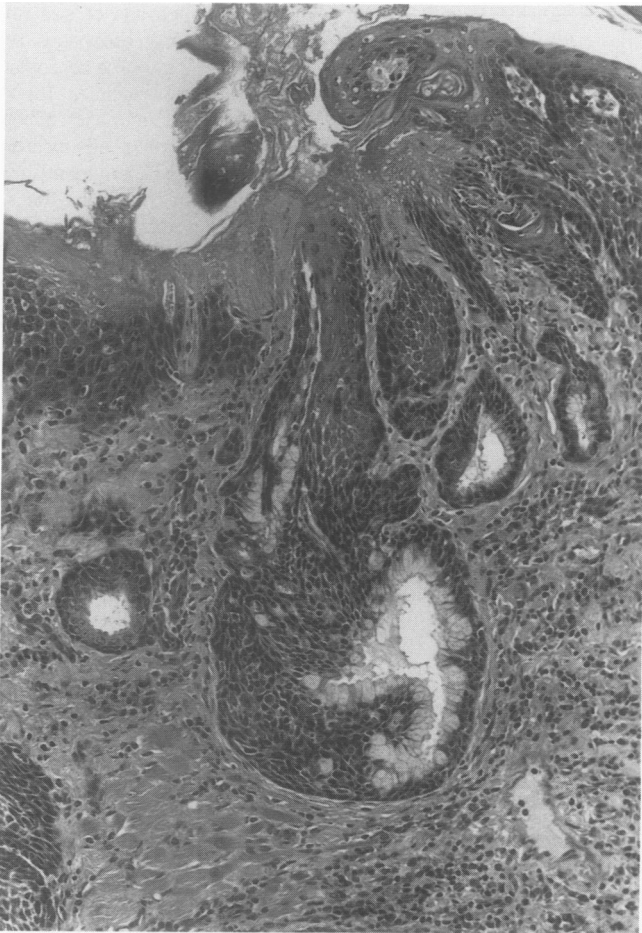

Figure 6. An example of columnar metaplasia (original magnification $\times 33$). There is a focus of mucus-containing cells forming a gland-like structure. The presence of mucins was confirmed by mucicarmine stains. There is squamous epithelium toward the surface and both proximal and distal to the area of metaplasia. This was the most common appearance of metaplasia that occurred as "islands" in the distal esophagus.

needed to detect a difference between the expected frequency of adenocarcinoma of 30% in the esophagoduodenostomy group and a decrease to 10% or less or an increase to 55% or more. To detect a difference at these levels required that 50 animals in each group undergo surgery. This allowed for a perioperative mortality rate of 20%.

The chi-square test was used to compare proportions between more than two groups. Fisher's exact test was used to compare proportions between individual groups. The Kruskal-Wallis test was used to compare continuous data between more than two groups. The Mann-Whitney *U* test was used to compare continuous data between individual groups. A *p* value of <0.05 was accepted to denote statistical significance. Data are expressed as median with interquartile range (25th–75th percentile), in parentheses, unless otherwise indicated.

This study protocol was approved by the Institutional and

Animal Review Boards of the University of Southern California.

RESULTS

Gross Findings

At the start of the experiment, rats had similar weights. They dramatically lost weight after the first injection with methyl-*n*-amyl nitrosamine, and thereafter gained weight. The rate of weight gain was slower in the operated rats than in controls. Of the operated rats, those with a total gastrectomy had the lowest weight whereas those that underwent esophagoduodenostomy and antral resection weighed the most (Fig. 2). Rats that underwent esophagoduodenostomy alone had a weight profile similar to those that underwent esophagoduodenostomy and antral resection. The weights of rats that underwent

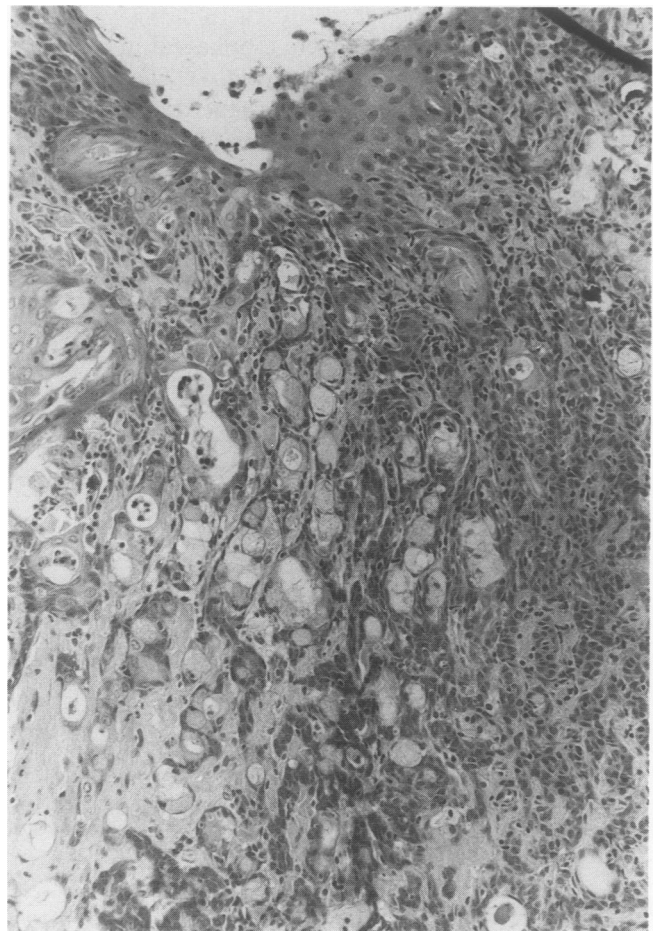


Figure 7. An example of an adenocarcinoma (original magnification $\times 33$). Toward the lumen (top of figure), there are nests of squamous epithelium; however, in the deeper part of the tumor, there are rudimentary glands and cells with intracytoplasmic mucin vacuoles. The presence of mucins in these tumors was confirmed by mucicarmine stains.

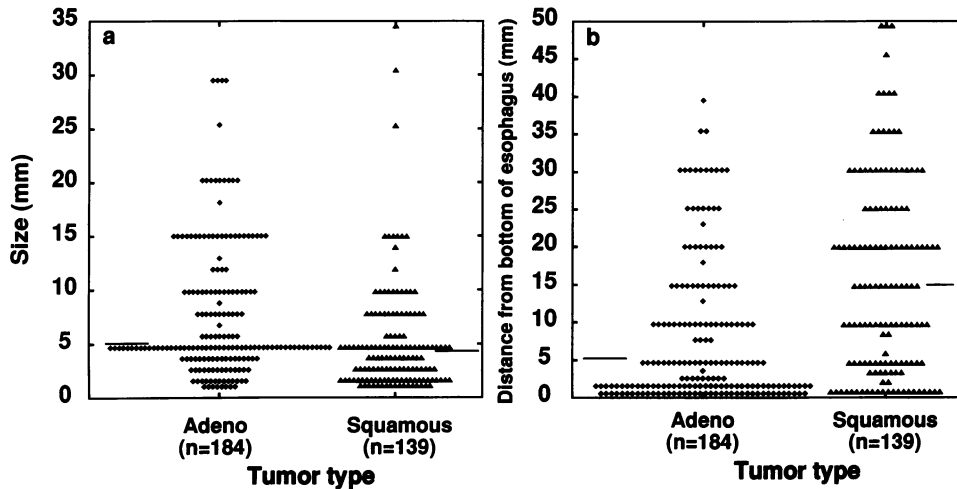


Figure 8. Comparison of size (a) and tumor location in esophagus (b) by histology of tumor. The horizontal bar represents the median. (a) The Y axis denotes the size of each tumor measured in millimeters. Adenocarcinomas were larger than squamous carcinomas ($p < 0.001$). (b) The Y axis represents the distance measured histologically from the bottom of the esophagus to the lower border of the tumor. Many adenocarcinomas occur above the esophagoduodenostomy, but most were seen in the distal part of the esophagus. Squamous cancers occurred higher up in the esophagus than adenocarcinomas ($p < 0.001$).

esophagoduodenostomy with antral preservation or with the stomach reimplanted distally ranged between these groups.

There was evidence of severe esophageal mucosal injury in most of the operated rats (Fig. 3). The only operated rats that did not have severe macroscopic changes were rats in whom a large “ballcock” tumor had developed in the distal esophagus. The tumor may have permitted healing by stopping reflux.

The esophageal specimen was significantly shorter and more dilated in the operated rats compared with controls (Table 3). The shortening can be explained only partially by the smaller size of the operated rats. Esophagoduodenostomy entails mobilization and transection of the esophagus, leaving 2 to 3 mm of esophageal stump at-

tached to the stomach. This mobilization also could contribute to shortening. However, the normal intra-abdominal extent of the rat esophagus was present in the control group, but in the operated rats, the esophagoduodenal anastomosis was pulled up into the hiatus and, in some rats, into the chest. This suggests that the severe inflammation seen in these specimens had caused shortening of the esophagus. Inflammatory injury to the circular muscles may be responsible for the dilatation observed. Strictures were not found.

The weight of esophagus expressed as grams of esophagus per 100 g of rat showed a significant difference between the control and operated animals (Table 3). The esophagus appeared grossly and histologically thickened, particularly in rats after esophagoduodenostomy with gastric reimplantation. The hematocrit level was signifi-

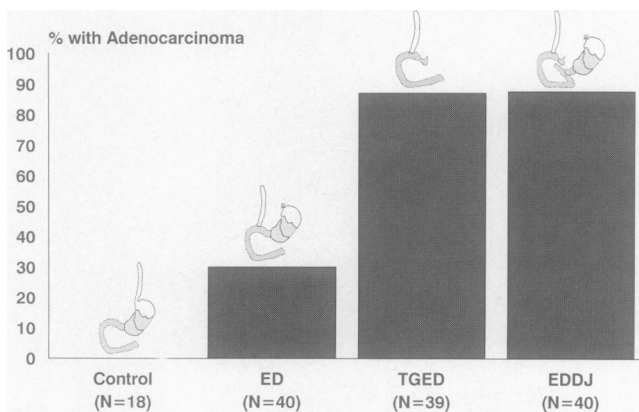


Figure 9. The effect of the absence of gastric juice on the prevalence of esophageal adenocarcinoma. Significant differences: control < (ED + TGED + EDDJ), ED < (TGED + EDDJ), $p < 0.001$. ED = esophagoduodenostomy alone; TGED = total gastrectomy with esophagoduodenostomy; EDDJ = esophagoduodenostomy, division of the proximal duodenum, and implantation of the duodenum attached to the stomach into the jejunum.

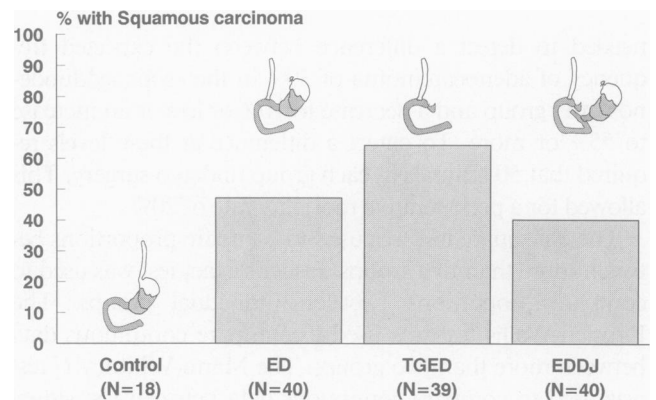


Figure 10. The effect of the absence of gastric juice on the prevalence of esophageal squamous carcinoma. Significant differences: control < (ED + TGED + EDDJ), $p < 0.001$. ED = esophagoduodenostomy alone; TGED = total gastrectomy with esophagoduodenostomy; EDDJ = esophagoduodenostomy, division of the proximal duodenum, and implantation of the duodenum attached to the stomach into the jejunum.

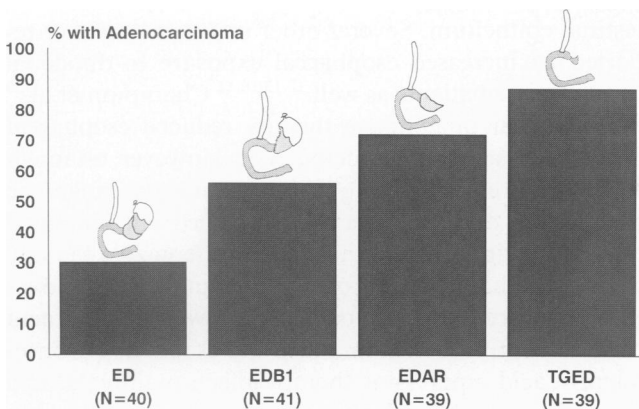


Figure 11. The effect of the extent of gastric resection on the prevalence of esophageal adenocarcinoma. Significant differences: ED < EDB1 ($p = 0.02$), ED < (EDAR + TGED) ($p < 0.001$), EDB1 < TGED ($p < 0.002$). ED = esophagoduodenostomy alone; EDB1 = esophagoduodenostomy, antrectomy with Billroth 1 reconstruction; EDAR = esophagoduodenostomy, proximal gastrectomy, and antral retention; TGED = total gastrectomy with esophagoduodenostomy.

cantly lower in the operated rats than in the controls, except for those that underwent total gastrectomy (Table 3).

Histologic Findings

All of the operated rats and 18% of the control rats had squamous hyperplasia. This finding was more extensive in the former. Mild papillomatosis was present in 6% of control rats and in all of the operated rats. Severe papillomatosis was more common in the rats with esophagoduodenostomy with distal gastric reimplantation than in rats with esophagoduodenostomy with exclusion of the forestomach and body. Acute inflammation and ulceration were more common in the reimplantation group than in the rats with duodenogastroesophageal reflux (Table 4).

Histologic examination of the control rats showed a typically normal rat esophagus appearance (Fig. 4). In contrast, the esophagus of the operated rats was thickened with evidence of basal cell hyperplasia, papillary elongation, and hyperkeratosis (Fig. 5).

The area at the anastomosis usually was covered by duodenal epithelium for 1 to 2 mm. None of the rats in this study developed a long continuous sheet of columnar epithelium extending into the esophagus from the duodenum. However, areas of columnar metaplasia within the esophagus were common (Table 4). The typical appearance is shown in Figure 6. There was squamous epithelium proximal and distal to an island of mucus containing goblet cells that formed a gland-like structure. The presence of mucus-containing cells was confirmed by mucicarmine stains (not shown). These ar-

was not in continuity with submucosal esophageal glands or esophageal ducts. Metaplasia was found most frequently in the distal esophagus as these "islands."

Adenocarcinomas were a spectrum of tumors that showed both squamous and adenomatous features, some that were almost pure adenocarcinoma (Fig. 7). Many rats had several tumors.

Comparison of Squamous and Adenocarcinomas

One or more adenocarcinomas occurred in 132 rats. Of these, 45 rats had two or more tumors, for a total number of 184 adenocarcinomas. These were compared with 139 squamous carcinomas seen in 102 rats, of which 27 rats had two or more. Compared with squamous tumors, adenocarcinomas were larger and situated closer to the distal end of the esophagus (Fig. 8).

The depth of invasion of the 184 adenocarcinomas was mucosal or submucosal in 25%, into the muscularis propria in 31%, and through the muscularis propria in 44%. The corresponding figures for the 139 squamous tumors were 55%, 32%, and 13%, respectively. These differences were statistically significant ($p = 0.001$), indicating that adenocarcinomas were more invasive. No evidence of distant metastases were found at autopsy.

Gastric Juice and Tumorigenesis

When gastric and duodenal juice refluxed into the esophagus of carcinogen-treated rats, there was a significant increase in the prevalence of tumors—from 0% in rats without reflux to 30% esophageal adenocarcinoma and 48% esophageal squamous carcinoma in rats with reflux of gastroduodenal juice ($p < 0.001$; Figs. 9 and 10).

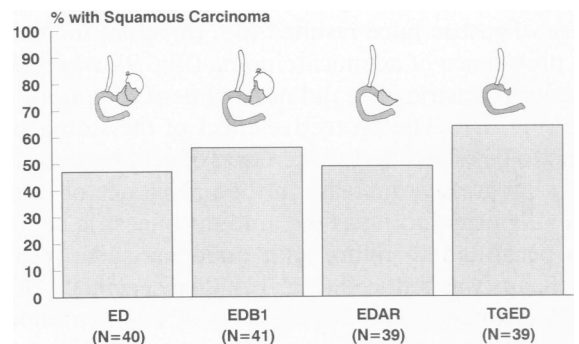


Figure 12. The effect of the the extent of gastric resection on the prevalence of esophageal squamous carcinoma. There were no significant differences. ED = esophagoduodenostomy alone; EDB1 = esophagoduodenostomy, antrectomy with Billroth 1 reconstruction; EDAR = esophagoduodenostomy, proximal gastrectomy, and antral retention; TGED = total gastrectomy with esophagoduodenostomy.

When all gastric juice is removed by either gastrectomy or reimplantation of the stomach distal to the esophagoduodenostomy and duodenal juice refluxes unbuffered into the esophagus, there is an increase in the prevalence of esophageal adenocarcinoma from 30% to 87% and 88%, respectively ($p < 0.001$; Fig. 9). This point is further emphasized because in all but 10 of the 79 animals with total gastrectomy or distal implantation of the stomach developed esophageal adenocarcinoma (Table 4). In contrast, there was no increase in the prevalence of squamous cancer (Fig. 10).

Extent of Gastric Resection and Tumorigenesis

When duodenal juice refluxes into the esophagus and the amount of gastric juice permitted to mix with the duodenal juice is reduced progressively by surgically altering the amount and character of the stomach, there is a progressive increase in the prevalence of esophageal adenocarcinoma (Fig. 11). In contrast, the extent of gastric resection does not alter the prevalence of squamous carcinoma (Fig. 12).

DISCUSSION

This experiment shows that, in a rat tumor model, duodenogastroesophageal reflux potentiates the development of tumors within the esophagus. Furthermore, the reflux of duodenal juice is associated with a shift in tumor histology from squamous carcinoma to adenocarcinoma. The preferential location of the adenocarcinomas in the lower esophagus corresponds to that observed in human esophageal adenocarcinomas and probably is related to the greater exposure of the distal esophagus to refluxed juices (Fig. 8).

The admixture of gastric juice with duodenal juice modulated the tumorigenic effects. Specifically, the absence of gastric juice resulted in a threefold increase in the prevalence of adenocarcinoma (Fig. 9), whereas the absence of gastric juice did not augment squamous cancers (Fig. 10). The protective effect of the stomach appears to be related to the secretion of acid because there was a progressive increase in the prevalence of esophageal adenocarcinoma as the amount of gastric acid that was permitted to reflux with duodenal juice into the esophagus was reduced (Fig. 11). The specificity of this effect is underscored by the lack of augmentation of squamous cancers under the same circumstances (Fig. 12).

Kauer et al.¹⁵ have shown that 58% of patients with gastroesophageal reflux disease reflux a mixture of gastric and duodenal juice. The greatest exposure to duodenal juice occurred in patients with Barrett's specialized in-

testinal epithelium. Several other investigators have reported an increased esophageal exposure to duodenal juice in these patients as well.^{12,13,16,17} Champion et al.³⁰ reported that omeprazole therapy reduced esophageal exposure to acid and duodenal juice. However, although acid exposure decreased to within the normal range, the exposure to duodenal juice was reduced but remained elevated. This indicated that, while omeprazole therapy is used, esophageal acid exposure is reduced and removes the sting of reflux but duodenal juice with a lower acid content continues to reflux into the esophagus. Consequently, acid suppression therapy affects mainly the acid component of the refluxed juice and allows the other component to persist. In view of the findings of the current study, such a modulation may be detrimental.

The rise in sales of acid suppressant medications parallel with the rising incidence of adenocarcinoma of the esophagus and cardia have given rise to speculation that the medications may be linked to the development of the tumors. This association may be a chance phenomenon, or alternatively, medication use is increasing as both disease and its tumor-associated consequences become more common. Another possibility is that the use of acid suppressant therapy is contributing to the rising tumor incidence. The findings of the current study provide experimental evidence to support the latter because suppression of gastric acid secretion encouraged esophageal metaplasia and tumorigenesis when duodenogastroesophageal reflux was present.

A report by Colin-Jones et al.³¹ suggests that this may be occurring. In this prospective study, 9928 patients receiving cimetidine were followed. The initial observed-to-expected ratio of gastric and esophageal cancers was high, suggesting that some patients with cancer were misdiagnosed and treated as if they had a benign condition. Over the next few years, the observed-to-expected ratio for gastric cancer decreased to normal levels, as did the ratio for esophageal cancer. However, a worrisome observation was a significant increase in the observed-to-expected ratio for esophageal tumors after 7 to 8 years of drug therapy. Further follow-up of these patients is awaited.

In a more recent study, Chow et al.³² compared acid suppression therapy in 196 patients with adenocarcinoma of the esophagus and gastric cardia with a matched population. There was a fourfold increase in the risk of adenocarcinoma in patients who had received four or more prescriptions for H₂ antagonists, (odds ratio 4.0, with a 95% confidence interval of 1.3–12.4). The authors question the significance of this finding by presenting a multivariate analysis model to control for the effects of hiatal hernia, esophagitis, or ulceration and difficulty swallowing. The authors observed that these factors were more common in patients with adenocarcinoma than in

the matched population. This makes it difficult to determine if the tumorigenesis was associated with reflux or the taking of acid suppressant therapy in patients with reflux. As expected, the multivariate analysis showed that H₂ antagonist use did not significantly increase the risk of adenocarcinoma. In attempting to control for these factors, the authors acknowledge that reflux disease is a major risk factor for adenocarcinoma. If the observed increased use of H₂ receptor antagonists in the patients with cancer was due to reflux disease, then one must question whether the medication was effective in controlling reflux. If reflux was controlled, one must question whether the medication contributed to adenocarcinoma. The authors conclude that their results reassure that H₂ antagonist use does not increase the risk of adenocarcinoma. However, they also concede that the study may not have been able to fully examine the late effects of H₂ antagonist use. More research is needed.

It is difficult to separate the effects of acid suppressant therapy in patients with gastroesophageal reflux disease from the effects of the disease itself. The best way to address the question about the tumorigenic effect of acid suppressant therapy is to perform a long-term follow-up study in a population of patients with gastroesophageal reflux—some treated with acid suppressant therapy and some treated with antireflux surgery. Unfortunately, this study has not been performed.

McCallum et al.³³ published data from a registry showing that patients with reflux disease and Barrett's metaplasia who continued with medical therapy are significantly more likely to progress to dysplasia and adenocarcinoma than patients who undergo surgical therapy.

Peters et al.³⁴ reported that 27 of 52 (52%) patients treated for esophageal adenocarcinoma or high-grade dysplasia were taking chronic prescribed acid suppressant medications and a further 6 were taking over-the-counter antacids on a long-term basis. In contrast, it is much rarer to encounter an esophageal adenocarcinoma in patients who have undergone a competent antireflux repair. As best as we can determine, in our unit, adenocarcinoma has developed in only 1 patient of more than 500 patients with Barrett's esophagus treated with an antireflux procedure. This patient had Barrett's metaplasia indefinite for dysplasia before surgery. Repeat biopsy showed no evidence of dysplasia. Four years after a technically adequate antireflux repair, foci of intramucosal cancer were identified. The patient underwent esophagectomy with a satisfactory result.

Two patients have been referred to us with esophageal adenocarcinoma after antireflux procedures. The first patient had undergone cholecystectomy and an antireflux repair 21 years before he was referred with adenocarcinoma. On endoscopy, the repair appeared intact but had retracted into the chest, suggesting an ineffective

repair. The second patient was referred to us with high-grade dysplasia, having undergone three previous antireflux repairs that failed soon after surgery. The last of these attempts at repair occurred 12 years before the diagnosis of Barrett's esophagus. Two years later, high-grade dysplasia was discovered on surveillance. We extensively rebiopsied the Barrett's epithelium and discovered no evidence of invasive cancer. Histologic examination of the esophagus resected from this patient showed intramucosal cancer. Close examination of patients such as these shows that there is doubt about the adequacy of the antireflux repair or that the patient had pre-existing dysplasia that progressed to cancer after the operation. In Hameeteman's⁶ longitudinal follow-up of patients with Barrett's esophagus, there was an interval of up to 6 years from the identification of low-grade dysplasia until adenocarcinoma was found. This suggests that a patient in whom adenocarcinoma develops within 6 years after surgery had unstable epithelium before surgery.

The safety of omeprazole in prerelease studies was focused on its endocrine effects, and little attention, if any, was paid to its ability to alter intraluminal pH. This is surprising because of the known relationship between achlorhydria and foregut cancer, including esophageal cancer.³⁵ The question about the safety of chronic omeprazole therapy is demonstrated further by the recent report examining the prevalence of atrophic gastritis in reflux patients infected by *Helicobacter pylori*. The prevalence of atrophic gastritis was significantly higher in patients treated with omeprazole than in patients treated by antireflux surgery without omeprazole.³⁶ This raises concern about the initiation of a cascade of events leading to gastric cancer. The findings of the current study should stimulate a re-evaluation of the safety of this medication, particularly because of its widespread use for maintenance therapy.

It is difficult to extrapolate the results from an animal experiment to the human situation. However, the current study raises concern about continuous profound acid suppressant therapy in patients with gastroesophageal reflux disease, particularly when there is increased esophageal exposure to duodenal juice. However, an effectively performed antireflux procedure, which in most situations can be performed laproscopically, re-establishes the barrier between the esophagus and stomach and prevents esophageal exposure to both gastric and duodenal juice. The availability of this alternative requires that further studies on the safety of continuous profound acid suppressant therapy in humans be conducted before their widespread use in maintenance therapy is advocated.

References

1. Hesketh PJ, Clapp RW, Doos WG, Spechler SJ. The increasing frequency of adenocarcinoma of the esophagus. *Cancer* 1989; 64: 526-530.

2. Blot WJ, Devesa SS, Kneller RW, Fraumeni JF Jr. Rising incidence of adenocarcinoma of the esophagus and gastric cardia. *JAMA* 1991; 265:1287-1289.
3. Blot WJ, Devesa SS, Fraumeni JF Jr. Continuing climb in rates of esophageal adenocarcinoma: an update. *JAMA* 1993; 270:1320.
4. Ollyo JB, Monnier P, Fontollet C, et al. The natural history, prevalence and incidence of reflux oesophagitis. *Gullet* 1993; 3:3-10.
5. Spechler SJ, Goyal RK. Barrett's esophagus. *N Engl J Med* 1986; 315:362-371.
6. Hameeteman W, Tytgat GN, Houthoff HJ, van den Tweel JG. Barrett's esophagus: development of dysplasia and adenocarcinoma. *Gastroenterology* 1989; 96:1249-1256.
7. Helsing N. Oesophageal lesions following total gastrectomy in rats: 1, development and nature. *Acta Chir Scandinav* 1959/1960; 118:202-216.
8. Leverat M, Guichard A, Lambert R. Une oesophagite experimentale chez la rongeur: etude histopathologique. *Ann dAnatomie Pathol* 1961; 6:175.
9. Levrat M, Lambert R, Kirshbaum G. Esophagitis produced by reflux of duodenal contents in rats. *Am J Dig Dis* 1962; 7:564-573.
10. Lambert R. Relative importance of biliary and pancreatic secretions in the genesis of esophagitis in rats. *Am J Dig Dis* 1962; 7:1026-1033.
11. Hamilton SR, Yardley JH. Regeneration of cardiac type mucosa and acquisition of Barrett mucosa after esophagogastrectomy. *Gastroenterology* 1977; 72:669-675.
12. Ifikhar SY, Ledingham S, Steele RJC, et al. Bile reflux in columnar lined Barrett's oesophagus. *Ann R Coll Surg Engl* 1993; 75:411-416.
13. Stein HJ, Feussner H, Kauer W, et al. Alkaline gastroesophageal reflux: assessment by ambulatory esophageal aspiration and pH monitoring. *Am J Surg* 1994; 167:163-168.
14. Kauer WK, Burdiles P, Ireland AP, et al. Does duodenal juice reflux into the esophagus of patients with complicated GERD: evaluation of a fiberoptic sensor for bilirubin. *Am J Surg* 1995; 169:98-103.
15. Kauer WKH, Peters JH, DeMeester TR, Ireland AP, Bremner CG, Hagen JA. Mixed reflux of gastric and duodenal juices is more harmful to the esophagus than gastric juice alone: the need for surgical therapy re-emphasized. *Ann Surg* 1995; 222:525-531.
16. Vaezi MF, Richter JE. Synergism of acid and duodenogastroesophageal reflux in complicated Barrett's esophagus. *Surgery* 1995; 117:699-704.
17. Caldwell MT, Lawlor P, Byrne PJ, Walsh TN, Hennessy TP. Ambulatory oesophageal bile reflux monitoring in Barrett's oesophagus. *Br J Surg* 1995; 82:657-660.
18. Gillison EW, DeCastro YAM, Nyhus LM, et al. The significance of bile in reflux esophagitis. *Surg Gynecol Obstet* 1972; 134:419-424.
19. Gillison EW, Kusakari K, Bombeck CT, Nyhus LM. The importance of bile in reflux oesophagitis and the success in its prevention by surgical means. *Br J Surg* 1972; 59:794-798.
20. Henderson RD, Mugashe FL, Jeejeebhoy KN, et al. Synergism of acid and bile salts in the production of experimental esophagitis. *Can J Surg* 1973; 16:12-17.
21. Kivilaakso E, Fromm D, Silen W. Effect of bile salts and related compounds on isolated esophageal mucosa. *Surgery* 1980; 87:780-785.
22. Lillemoe KD, Gadacz TR, Harmon JW. Bile absorption occurs during disruption of the esophageal mucosal barrier. *J Surg Res* 1983; 35:57-62.
23. Schweitzer EJ, Harmon JW, Bass BL, Batzri S. Bile acid e-ux precedes mucosal barrier disruption in the rabbit esophagus. *Am J Physiol* 1984; 247:G480-G485.
24. Pera M, Cardesa A, Bombi JA, et al. Influence of esophagojejunostomy on the induction of adenocarcinoma of the distal esophagus in Sprague-Dawley rats by subcutaneous injection of 2,6-dimethyl-nitrosomorpholine. *Cancer Res* 1989; 49:6803-6808.
25. Attwood SE, Smyrk TC, DeMeester TR, et al. Duodenoesophageal reflux and the development of esophageal adenocarcinoma in rats. *Surgery* 1992; 111:503-510.
26. Pera M, Trastek VF, Carpenter HA, et al. Influence of pancreatic and biliary reflux on the development of esophageal carcinoma. *Ann Thorac Surg* 1993; 55:1386-1392.
27. Clark GW, Smyrk TC, Mirvish SS, et al. Effect of gastroduodenal juice and dietary fat on the development of Barrett's esophagus and esophageal neoplasia: an experimental rat model. *Ann Surg Oncol* 1994; 1:252-261.
28. Bulay O, Mirvish SS. Carcinogenesis in rat esophagus by intraperitoneal injection of different doses of methyl-n-amyl nitrosamine. *Cancer Res* 1979; 39:3644-3646.
29. Mirvish SS. Role of N-nitroso compounds (NOC) and N-nitrosation in etiology of gastric, esophageal, nasopharyngeal and bladder cancer and contribution to cancer of known exposures to NOC. *Cancer Letters* 1995; 93:17-48.
30. Champion G, Richter JE, Vaezi MF, et al. Duodenogastroesophageal reflux: relationship to pH and importance in Barrett's esophagus. *Gastroenterology* 1994; 107:747-754.
31. Colin-Jones D, Langman M, Lawson D, et al. Post-cimetidine surveillance for up to ten years: incidence of carcinoma of the stomach and oesophagus. *Q J Med New Series* 1991; 78:13-19.
32. Chow WH, Finkle WD, McLaughlin JK, et al. The relation of gastroesophageal reflux disease and its treatment to adenocarcinomas of the esophagus and gastric cardia. *JAMA* 1995; 274:474-477.
33. McCallum RW, Polepalle S, Davenport K, et al. Role of antireflux surgery against dysplasia in Barrett's esophagus. *Gastroenterology* 1991; 100:A121 (abstract).
34. Peters JH, Clark GW, Ireland AP, et al. Outcome of adenocarcinoma arising in Barrett's esophagus in endoscopically surveyed and nonsurveyed patients. *J Thorac Cardiovasc Surg* 1994; 108:813-821.
35. Hsing AW, Hansson LE, Ekblom A, et al. Pernicious anemia (PA) and cancer risk: a cohort study in Sweden. *Gastroenterology* 1991; 100:A371 (abstract).
36. Kuipers EJ, Lundell L, Klinkenberg-Knol EC, et al. Atrophic gastritis and *Helicobacter pylori* infection in patients with reflux esophagitis treated with omeprazole or fundoplication. *N Engl J Med* 1996; 344:1018-1022.

Discussion

DR. CLAUDE H. ORGAN, JR. (Oakland, California): It was Mr. Allison who set off a series of investigative concerns regarding the organ that looked like the esophagus on the outside but was really stomach on the inside.

The gut laboratory at the University of Southern California has continued its active research efforts in studying the many mechanisms that are at play in the foregut. This is an extension of long-term studies by this group and others to define specifically the role of gastric juice, duodenal juices, and both in the reflux esophagitis mechanism. Previous studies have well documented the transition from normal mucosa to metaplasia to dysplasia to carcinoma.

This is an intriguing and innovative set of experiments that Dr. DeMeester's group has carried out. These data have hard conclusions that would make one agree that there has been a