

Ultrastructure of rabbit semilunar cartilages

F. N. GHADIALLY, I. THOMAS, N. YONG AND J-M. A. LALONDE

*Department of Pathology, University Hospital,
University of Saskatchewan, Saskatoon, Saskatchewan, Canada, S7N 0W0*

(Accepted 22 February 1977)

INTRODUCTION

Such knowledge as we have of the fine structure of intra-articular discs and menisci is derived from, (1) an excellent paper on the transmission electron microscopic appearance of the temporomandibular disc of the guinea-pig (Silva, 1969), (2) an abstract commenting on the function of collagen fibrils in the menisci of the knee and temporomandibular discs of monkeys, cats and guinea-pigs (Silva, 1970), (3) four scanning electron microscopic studies commenting on the manner in which collagen fibrils, fibres and lamellae are deployed in human semilunar cartilages and how tears occur in these structures (Inoue *et al.* 1971; Cameron & MacNab, 1972, 1973; Refior & Fischer, 1974) and (4) a study, difficult to comprehend, on fibrillogenesis (intracytoplasmic filaments and collagen fibrils in the matrix) utilizing the rabbit semilunar cartilages as a model (Okada, 1967).

The purpose of this paper is to record our observations on the morphology of rabbit semilunar cartilages as seen with the light and transmission electron microscopes.

MATERIALS AND METHODS

Four rabbits of both sexes between 6 and 8 months old were used in this study. Tissue from one knee joint of each animal was used for light microscopy while that from the contralateral knee was used for transmission electron microscopy.

Light microscopy

From two knees the tibial plateau with accompanying menisci was removed and decalcified in Perenyi's fluid (Lynch *et al.* 1969) and from the other two knees the menisci were detached from the tibial plateau and cut into three approximately equal parts (anterior, middle and posterior). The specimens were then processed in conventional manner for light microscopy, sections being stained with haematoxylin and eosin.

Electron microscopy

Each medial and lateral meniscus was divided into three parts by two transverse cuts and each piece so obtained was further divided into two parts by a cut along its long axis, thus yielding six portions which were designated as, (1) inner anterior, (2) outer anterior, (3) inner middle, (4) outer middle, (5) inner posterior and (6) outer posterior. Samples from each portion were cut into small pieces or strips less than 1 mm thick. Some of these were fixed in 2% osmium tetroxide in cacodylate buffer, while others were fixed in 2% glutaraldehyde in cacodylate buffer followed by post-fixation in 2% osmium buffered with cacodylate.

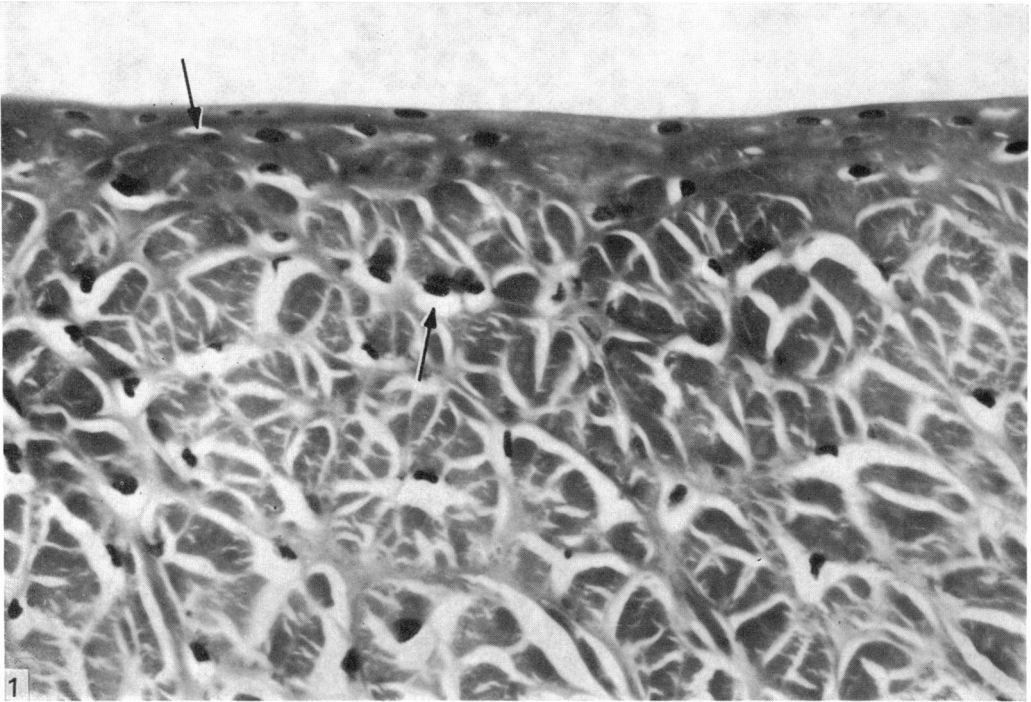


Fig. 1. In this haematoxylin and eosin-stained transverse section from a paraffin-embedded meniscus the shrunken cells appear to lie in clear lacunae (arrows). The superficial zone with its oval or elongated cells is easily distinguished from the deep or middle zone containing transversely cut collagen fibres and fibre bundles. Note the somewhat irregular, slightly curved surface. $\times 450$.

Tissues were then dehydrated in increasing concentrations of ethanol, cleared in propylene oxide, embedded in Epon or an Epon-Araldite mixture, and sectioned with glass or diamond knives. Semithin sections stained with toluidine blue were examined with the light microscope, while ultrathin sections were mounted on uncoated copper grids, stained with uranium and lead and examined in an electron microscope.

RESULTS

Gross examination and light microscopy

On naked eye examination the surface of menisci *in situ* appeared smooth and glistening like the surface of articular cartilage. Detached menisci tend to shrink and curl during processing so that the superior surface develops systems of ridges and undulations which lie mainly parallel to the long axis of the meniscus. Such a phenomenon, but to a much lesser degree, was evident also in menisci left *in situ* on the tibial plateau. Since the ridges run parallel to the main axis, it is mainly in transverse sections that the surface appears somewhat irregular.

In paraffin sections the cells were seen to lie in lacunae (Fig. 1). That such an appearance is largely an artefact due to cell shrinkage is evidenced by the fact that in plastic-embedded material this feature can hardly be discerned (Fig. 2). However, in some instances one could see a specialized area of fine textured metachromatic matrix surrounding the cell. This could be designated as the territorial matrix.

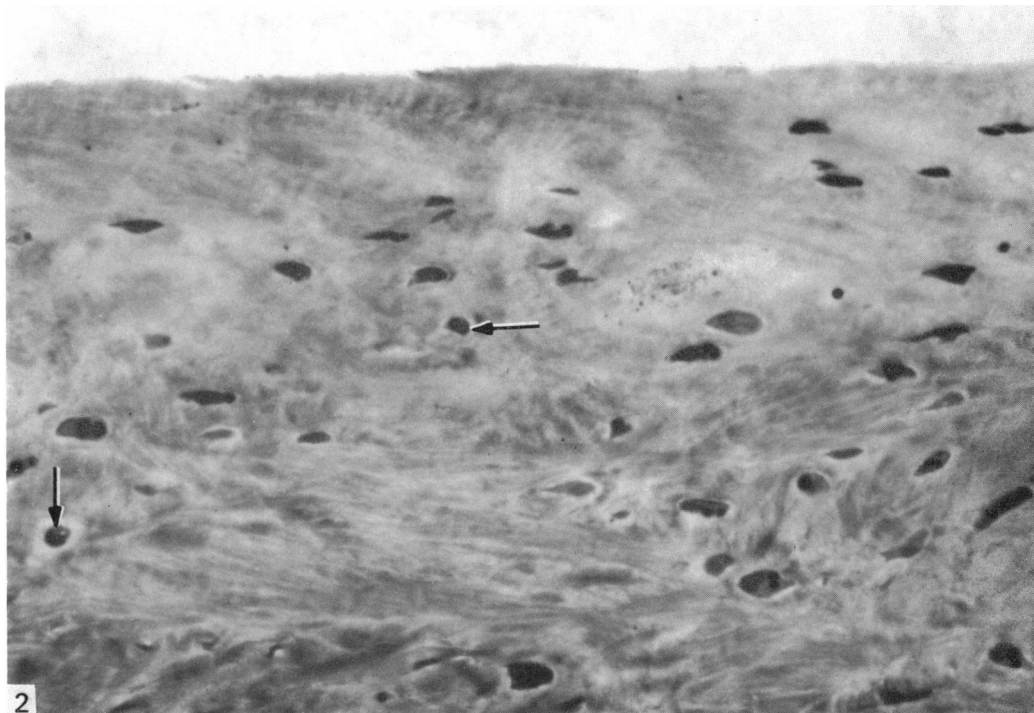

Fig. 2. In this toluidine blue-stained section from an Epon-Araldite-embedded meniscus the shrinkage is minimal so that lacunae of the type seen in Fig. 1 are not evident, but a collar of paler looking (metachromatic) territorial matrix can be seen around a few cells (arrows). Collagen fibres are not as well visualized as in Fig. 1. However, a close comparison between the two figures is not warranted because of differences in the site and the plane of sectioning. Note that, except for a few small blemishes, the surface is quite smooth. $\times 450$.

Collagen fibres and bundles of such fibres of the general or interterritorial matrix were more easily visualized in paraffin than in plastic-embedded material. The major fibre orientation is circumferential as evidenced by the fact that bundles of transversely cut fibres are seen in transverse sections through the menisci (Fig. 1).

Our studies confirm two well known facts: namely, (1) that synovial membrane overlaps the peripheral part of the meniscus and (2) that the peripheral part of the meniscus has a blood supply, but the rest is avascular.

Electron microscopy

A study of sections obtained from the six regions of each medial and lateral semilunar cartilage (as described in Materials and Methods) showed no constant regional differences worthy of note except that blood vessels were found only in the outer portions and there were variations in the distribution of elastic fibres which will be commented upon later.

However, morphological differences were found between the surface layers (superior and inferior), and the deeper or middle parts, in all regions of the meniscus. These will be referred to as the superficial and the deep zones of the meniscus. Further division into a superficial zone adjacent to the superior surface and another adjacent to the inferior surface is not warranted on the basis of the present study, for all surfaces encountered showed similar features.

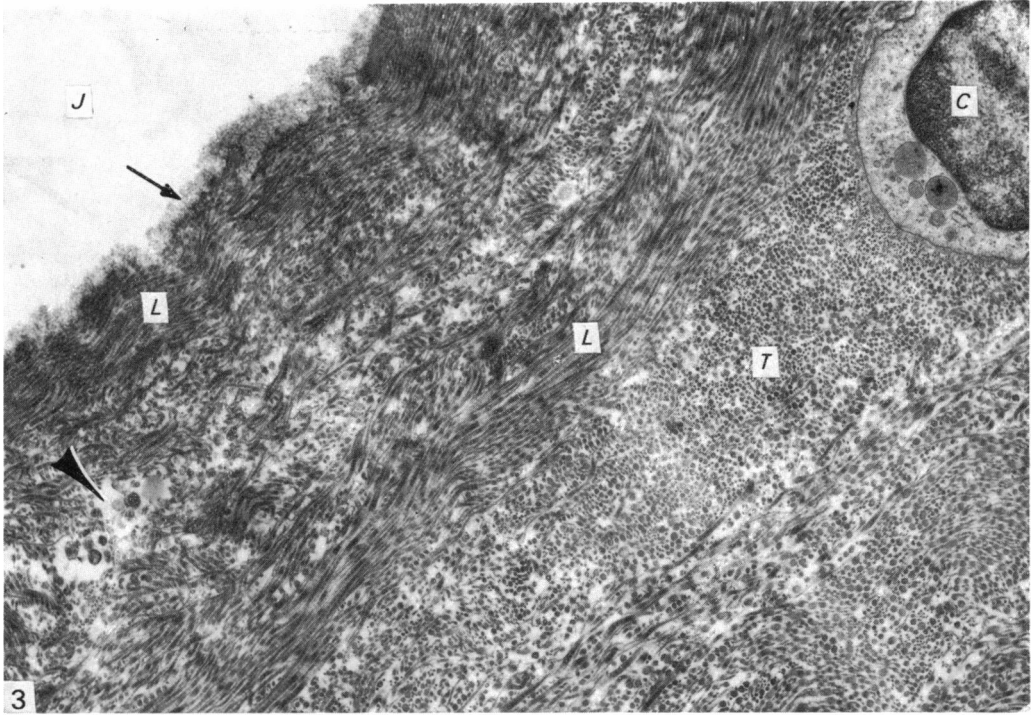


Fig. 3. Superficial zone of meniscus, showing surface covered by amorphous material (arrow) adjacent to the joint space (*J*). Collagen fibrils cut in transverse (*T*) and longitudinal (*L*) planes are seen set in an electron-lucent interfibrillary matrix. Also present is a rounded chondrocyte (*C*) and a lacuna containing lipidic debris (arrowhead). $\times 12000$.

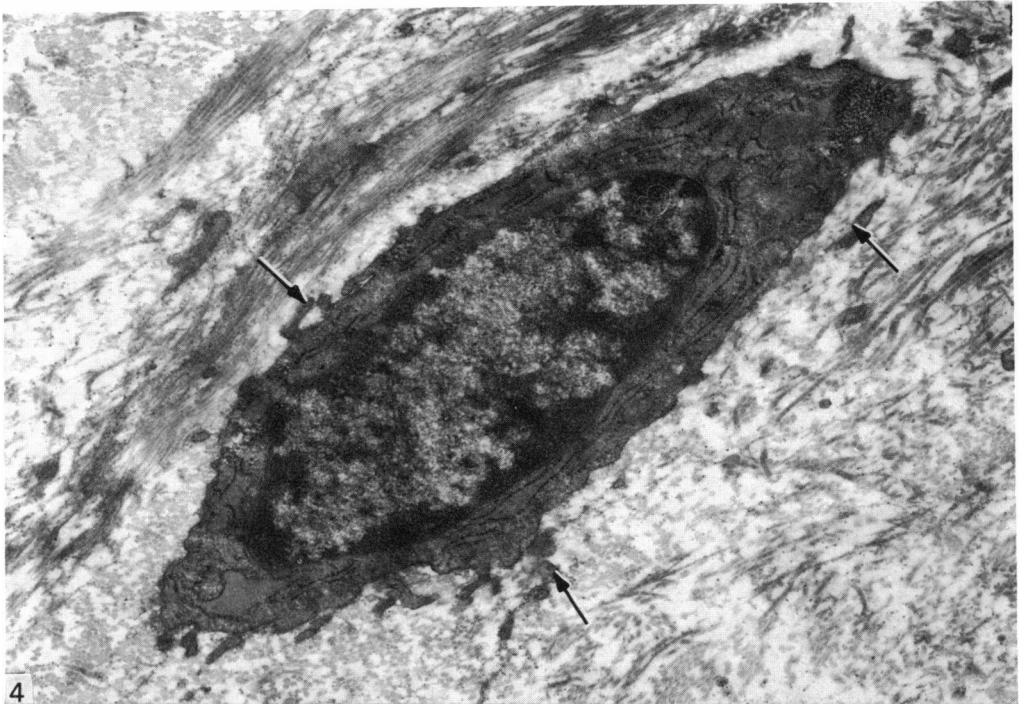

Fig. 4. An oval chondrocyte with short cell processes (arrows) found in the superficial zone of a meniscus. $\times 18000$.

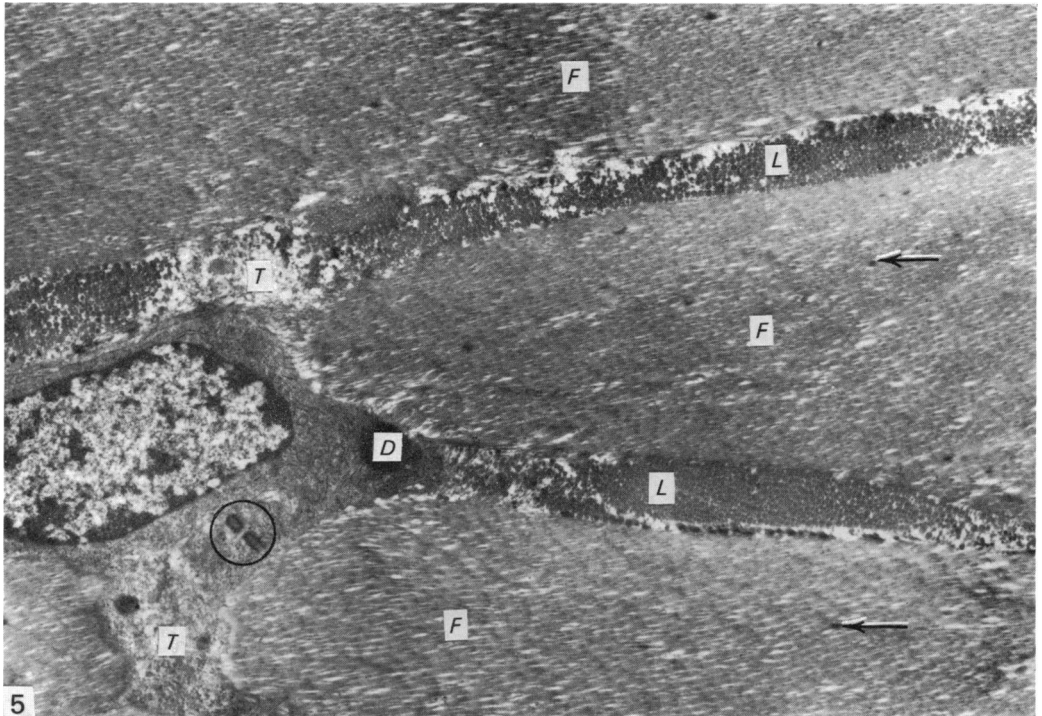


Fig. 5. Deep (middle) zone of meniscus showing obliquely and almost longitudinally cut collagen fibres (*F*) alternating with transversely cut lamellae (*L*). At higher magnifications the small electron-dense spots (arrows) are seen to be aggregates of electron-dense filaments similar to those depicted in Fig. 16. A small amount of territorial matrix (*T*) is seen adjacent to a chondrocyte but the collagen fibrils of the general matrix abut against most of the cell circumference. An electron-dense lipid droplet (*D*) and a pair of centrioles (circle) are seen in the chondrocyte. $\times 5500$.

Even with the high magnification employed in electron microscopy the surfaces of the menisci appeared remarkably smooth. No constantly recurring irregularity of the surface which could be unequivocally attributed to the tissue itself, or which could be regarded as reflecting an *in vivo* state, was detected except for an occasional scalloping of the surface (Fig. 3), which probably reflects the undulations and ridges produced by curling and tissue shrinkage.

At times a shallow depression, slight elevation, a minute crack, or other such small irregularity, was seen on an otherwise flat surface, but here again the explanation is most likely to be damage engendered by handling, processing and cutting the tissue.

Glutaraldehyde-fixed material allowed good demonstration of fine details in the intercellular matrix (e.g. filaments and protein-polysaccharide particles) but the cells were at times rather dense so that it was difficult to photograph the intracellular details. Conversely, osmium-fixed material permitted excellent visualization of intracellular structures, but the intercellular matrix did not show the wealth of detail seen with glutaraldehyde fixation.

Cells

The cells in the superficial zone (Figs. 3 and 4) were usually, but not invariably, oval or fusiform with a few short cell processes. The scant cytoplasm made the

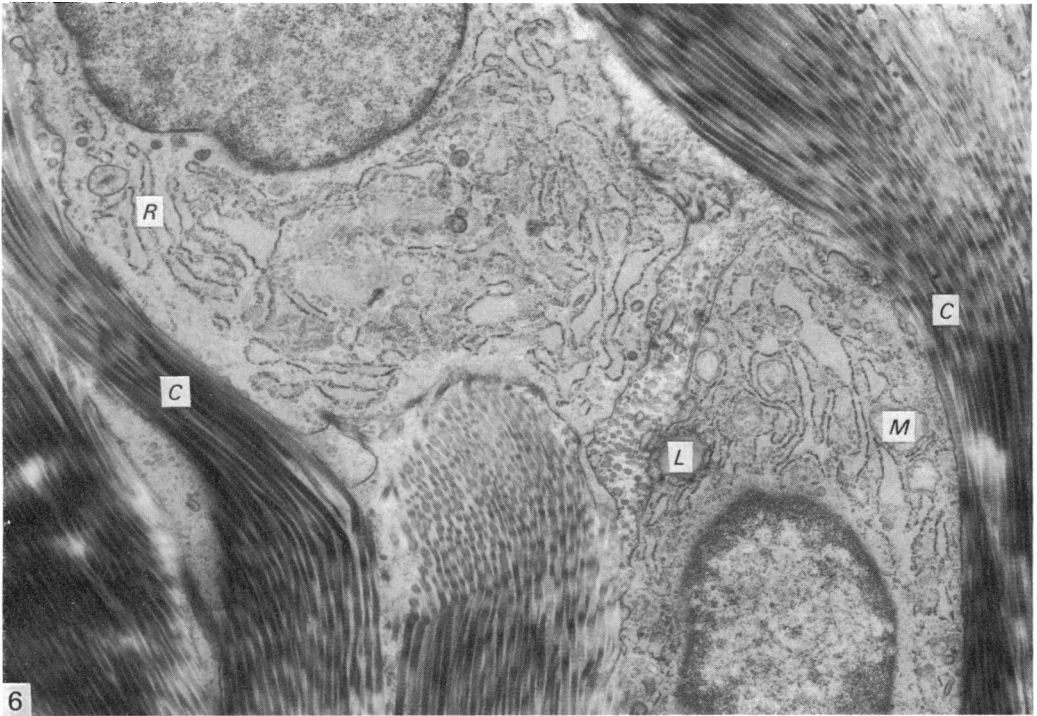


Fig. 6. A chondrocyte pair from the deep (middle) zone showing collagen fibrils (C) adjacent to the cell surfaces. A distinct territorial matrix is hard to discern; even the matrix between the two chondrocytes contains collagen fibrils. Mitochondria (M), rough endoplasmic reticulum (R) and a medium density lipid droplet (L) can be seen in the chondrocytes. $\times 13\,000$.

nucleus appear rather large and prominent. Organelles such as an occasional mitochondrion and elements of the rough endoplasmic reticulum and Golgi complex could be identified. Lipid droplets were sometimes seen, but glycogen particles were not detected.

A majority of cells in the deep zone had a rounded or polygonal form (Figs. 5, 7). Mostly the cells were solitary, but an occasional pair of cells or three cells in a group were seen. Compared to the chondrocytes in hyaline articular cartilage these cells appeared to be poorly endowed with cell processes and pinocytic and micro-pinocytic vesicles, but coated vesicles were sometimes found (Fig. 8). However, these cells were singularly well endowed with rough endoplasmic reticulum (Figs. 6, 9), more so than the chondrocytes of hyaline articular cartilage (Ghadially & Roy, 1969). The Golgi complex was also very well developed and in rare instances its sacs and vesicles contained aggregates of filamentous material (Fig. 9). Mitochondria with lamellar cristae and an occasional matrical dense granule were present. Some of the mitochondria appeared swollen, but this probably reflected poor or delayed penetration of fixative solutions (Ghadially, 1975). Intracytoplasmic lipid droplets, at times multiple, were present in some cells (Figs. 6, 7). A few cells contained aggregates of monoparticulate glycogen (β -particles) and some intracytoplasmic filaments.

A peculiar feature of the cytoplasm of a few cells was the presence of membranous tubular structures containing what looked like collagen fibrils (Fig. 10). However, in no instance did we visualize an uninterrupted membrane completely surrounding the fibrils, but this is to be expected from a long tubular structure where the chances of

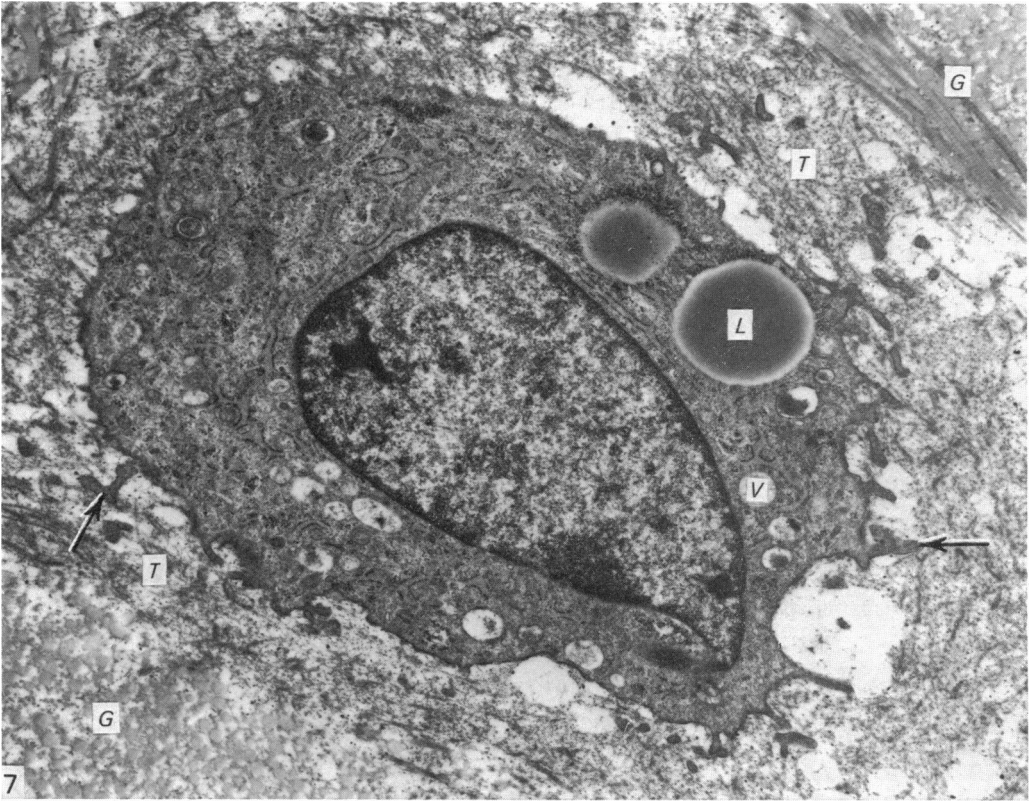


Fig. 7. A chondrocyte from the deep (middle) zone is seen set in a fine textured territorial matrix (*T*) which is easily distinguished from general matrix (*G*) containing collagen fibrils. Filaments, unbanded fibrils and protein-polysaccharide particles are just discernible in the territorial matrix, but these features are more clearly illustrated at a higher magnification in Fig. 19. Note also the cell processes of the chondrocyte (arrows), lipid droplets (*L*) and presumably secretory vacuoles (*V*) containing material similar to that seen in the territorial matrix. $\times 12000$.

its lying parallel to the plane of sectioning and being cut along its entire length are remarkably small. Such presumably membrane-bound fibrils at times occurred in cells where the Golgi complex contained filamentous material (Fig. 9).

The nuclei in these cells showed the usual double-membraned nuclear envelope and nuclear pores. In a few nuclei a nuclear fibrous lamina (Fig. 8) similar to that described in other tissues, including articular cartilage (Ghadijally, Bhatnager & Fuller, 1972; Oryschak, Ghadijally & Bhatnager, 1974), was easily seen. Nucleoli were rarely encountered.

Besides the viable chondrocytes described above, a few chondrocytes which had suffered *in situ* necrosis were found (Fig. 11). Such cells had a pyknotic crenated nucleus and markedly altered cytoplasmic organelles. Further stages of cell disintegration (Ghadijally & Roy, 1969; Ghadijally, 1975) leading to the formation of electron-dense membranous and granular lipidic debris were found both within lacunae (Fig. 12) and dispersed in the general matrix (Fig. 13).

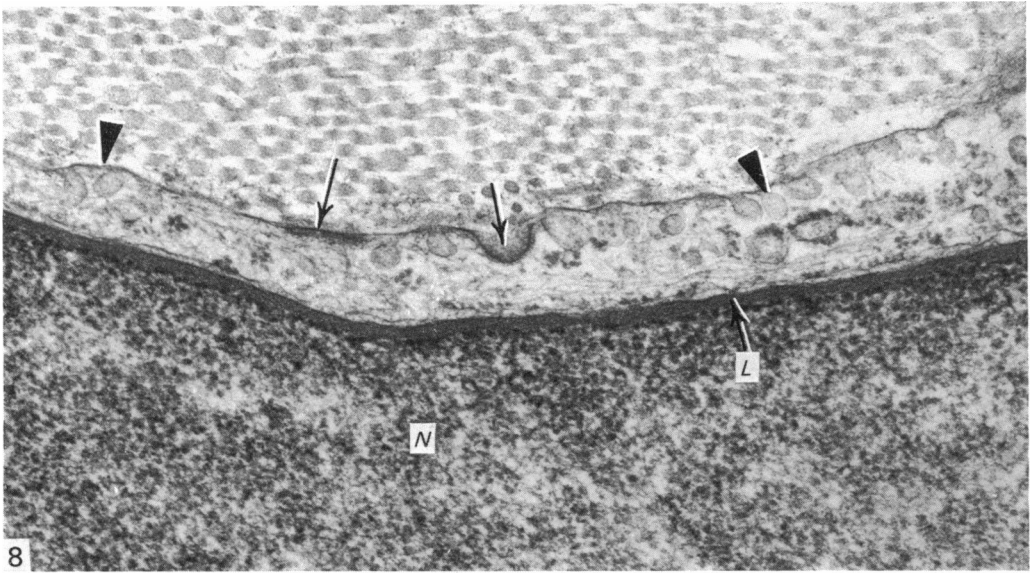


Fig. 8. Stages in the development of coated vesicles (arrows) and some micropinocytotic vesicles (arrowheads) are seen at the cell surface. A nuclear fibrous lamina (*L*) is evident in the nucleus (*N*). $\times 45\,000$.

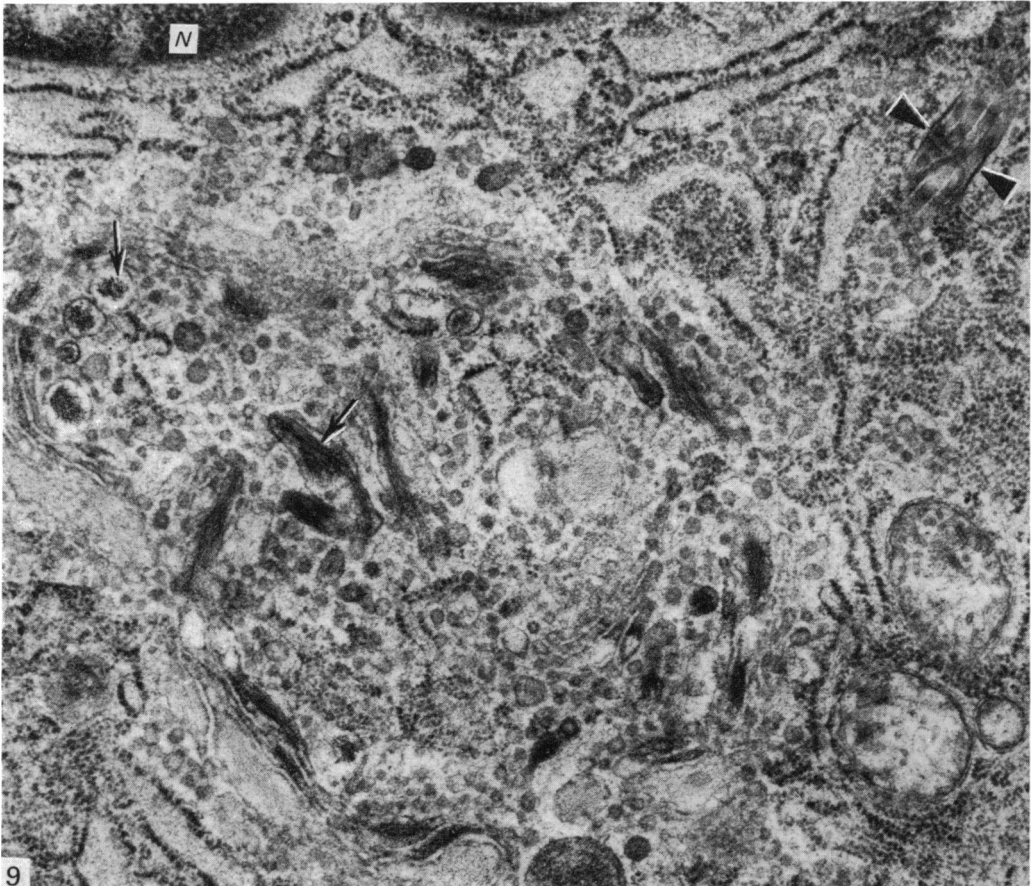


Fig. 9. A Golgi complex containing electron-dense filamentous material (arrows) is seen adjacent to a nucleus (*N*). Also seen are some obliquely cut collagen fibrils flanked by membranous profiles (arrowheads). $\times 35\,000$.

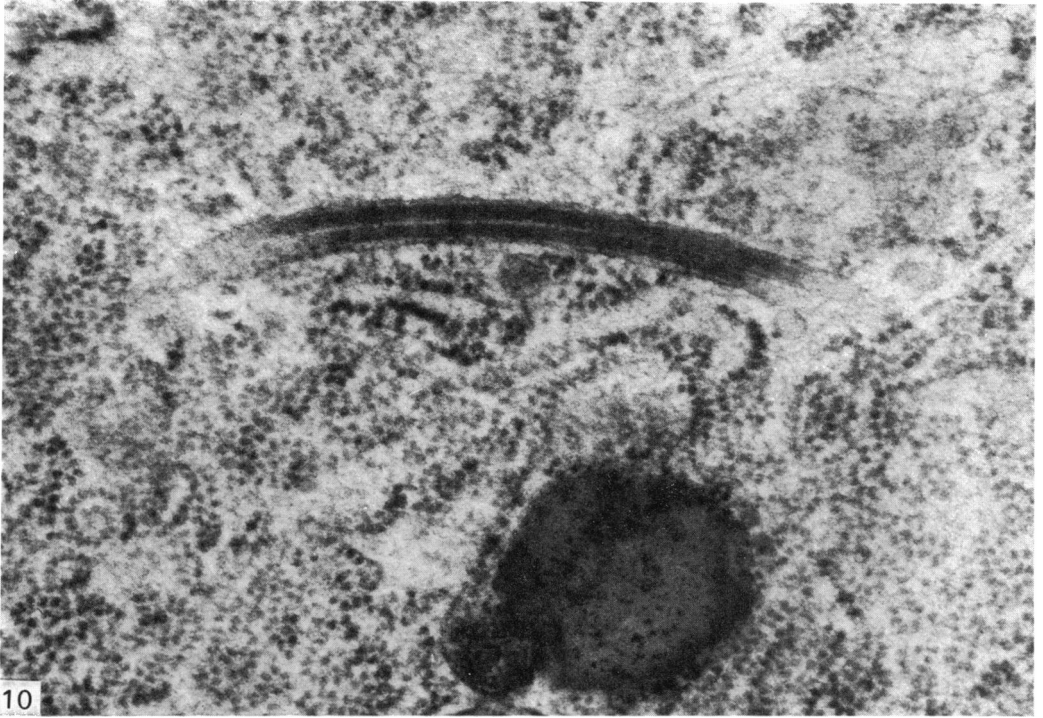

Fig. 10. A tubular structure containing two collagen fibrils found deep in the cytoplasm of a chondrocyte. Faint striations suggesting collagen-type banding are just discernible in some parts of the fibrils. $\times 68\,000$.

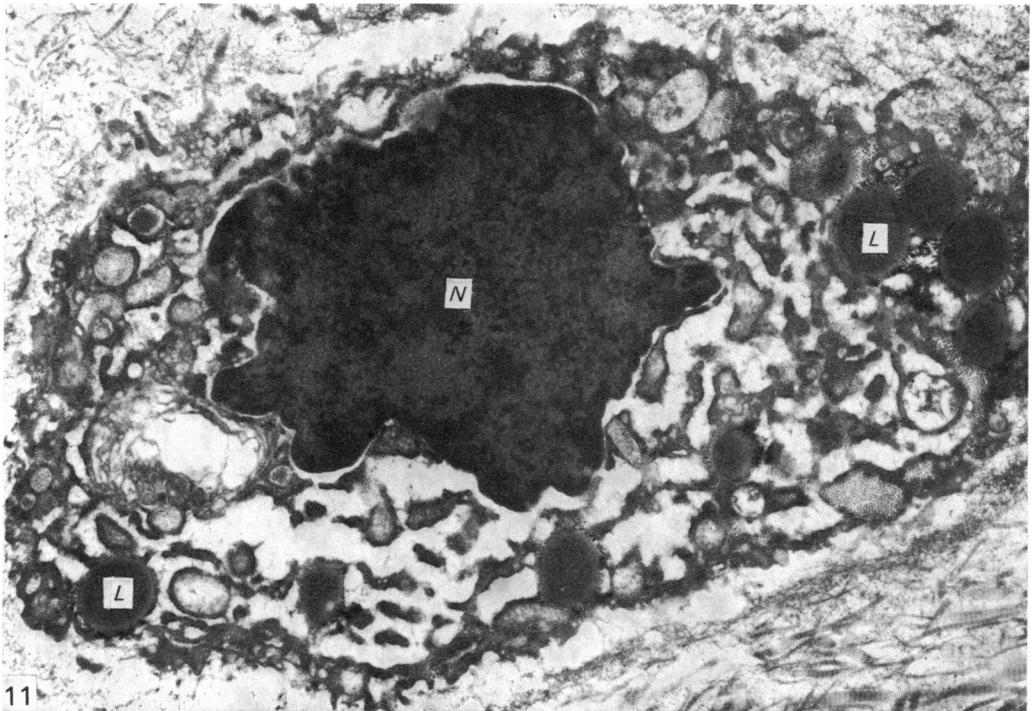


Fig. 11. A chondrocyte showing *in situ* necrosis. Note pyknotic nucleus (*N*), lipid droplets (*L*) and disorganized cytoplasmic contents. $\times 15\,000$.

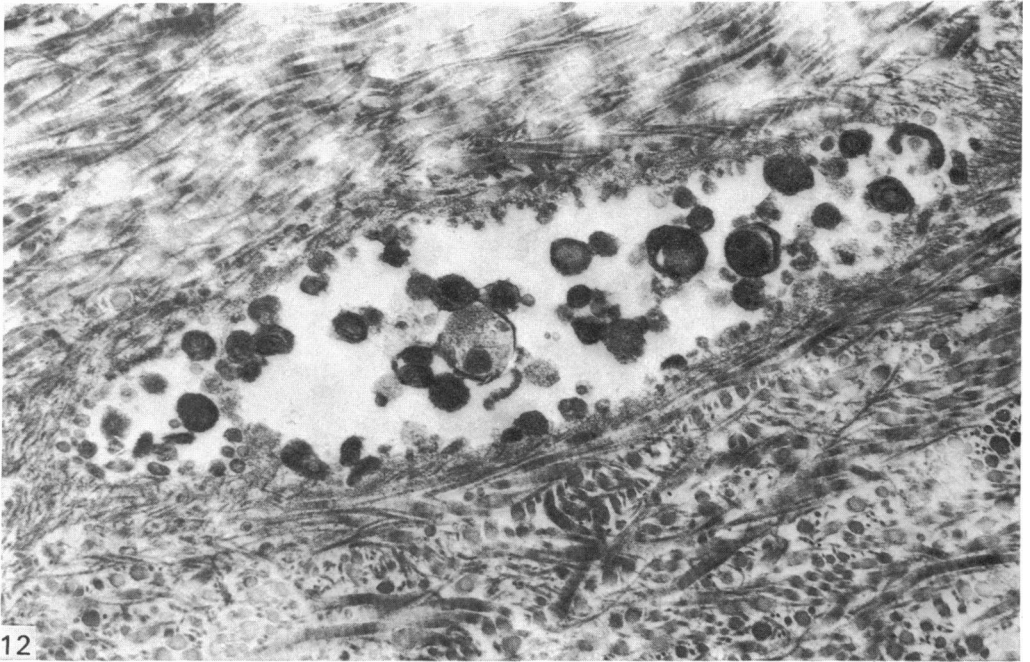


Fig. 12. A lacuna containing membranous and granular debris. $\times 31\,000$.

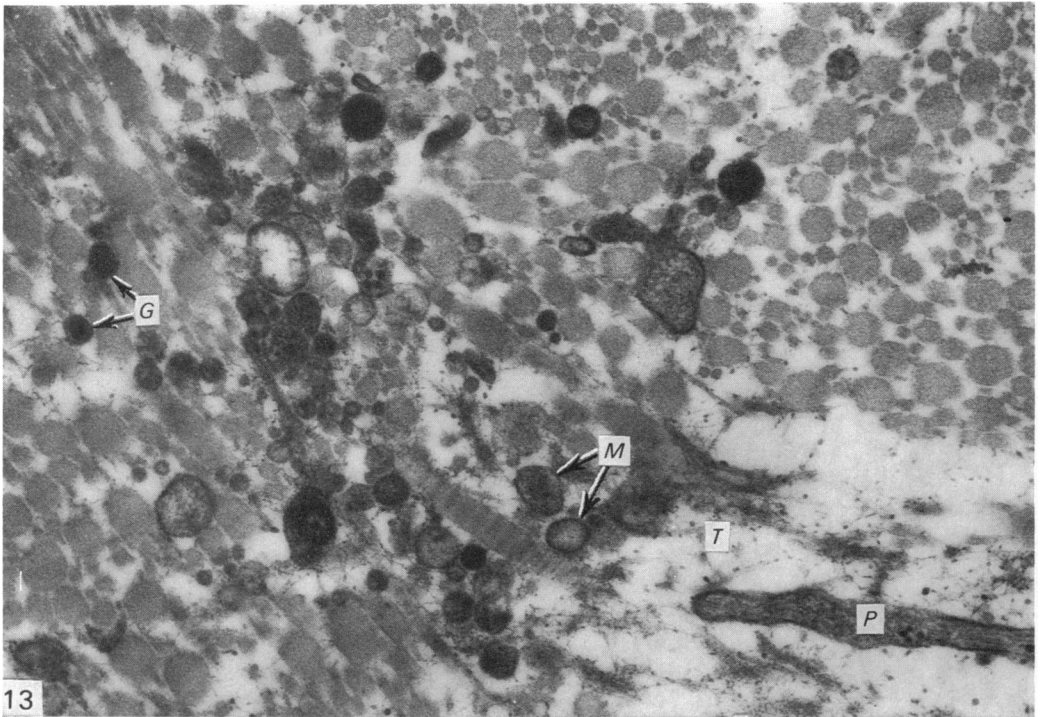


Fig. 13. Granular (*G*) and membranous (*M*) debris is seen amongst the collagen fibrils of the general matrix. Also seen is the cell process (*P*) of a chondrocyte and adjoining territorial matrix (*T*). $\times 44\,000$.




Fig. 14. An electron-lucent interfibrillary matrix containing protein-polysaccharide particles (arrows) and associated filaments is seen between the collagen fibrils (C) which show the characteristic major and minor bands. $\times 36000$.

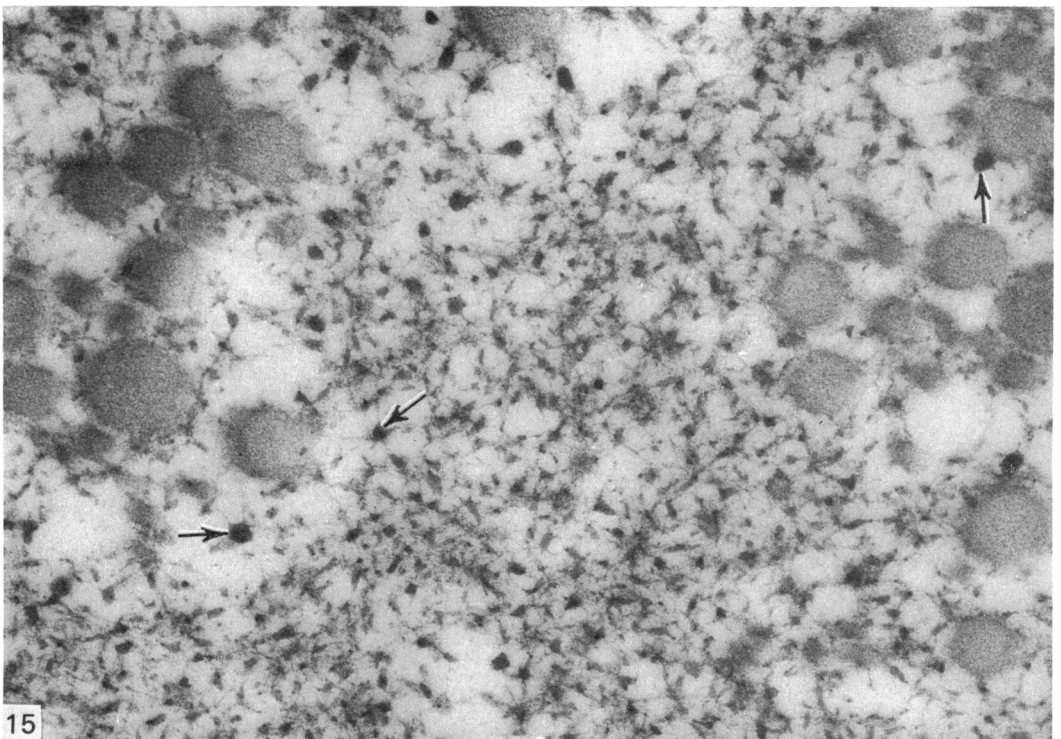


Fig. 15. High power view of interfibrillary matrix showing protein-polysaccharide particles (arrows) and associated filaments. $\times 77000$.

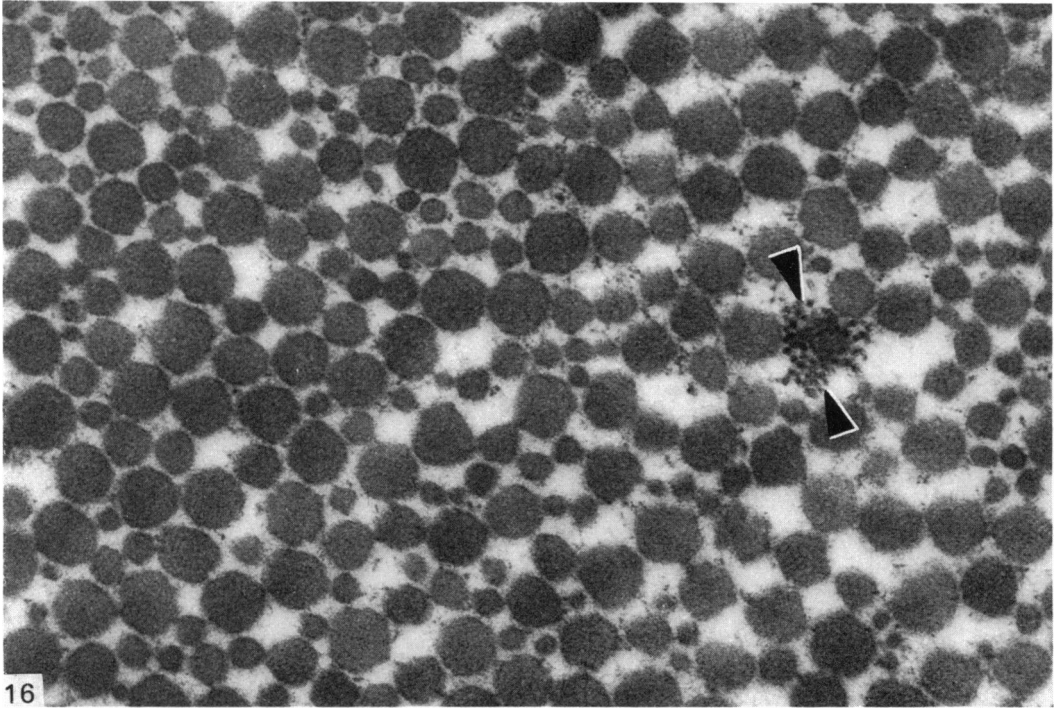


Fig. 16. Transverse section through collagen fibrils of the general matrix. Note marked variation in fibril diameter. A focal aggregate (between arrowheads) of transversely cut electron-dense filaments is also present. $\times 55000$.

General matrix

The collagen fibrils comprising the major component of this tissue were set in a sparse interfibrillary matrix where protein-polysaccharide particles and associated filaments could be discerned (Figs. 14, 15). Most, but not all, fibrils showed the characteristic banded pattern of collagen.

In the superficial zone such fibrils formed fibres or lamellae deployed parallel to the surface, but separated from the joint space by a thin layer of amorphous material which largely, but perhaps not entirely, represents precipitated synovial fluid (Fig. 3). In the deep zone the pattern was more variable and complex and absolute fibre orientation could not be determined from the small blocks of tissue used for transmission electron microscopy, but a regular feature, shown in Figure 5, may be interpreted as stout fibres separated by slender lamellae, with the component fibrils of the fibres and lamellae running almost, but not quite, at right angles to one other. Another point of interest was that collagen fibrils of markedly different thicknesses were mingled together in the fibres and lamellae (Fig. 16).

Dotted amongst the collagen fibrils in the deep zone one could discern aggregates of short electron-dense filaments which probably represent an early stage in the development of elastic fibres (Figs. 5, 16, 17), for rare elastic fibres with an electron-lucent core and an array of such filaments around the periphery were also detected (Fig. 18). It was our impression that these aggregates of electron-dense filaments occurred mainly in the deep zone of the meniscus, and certainly in this study elastic fibres with a clearly defined electron-lucent core were found only in this zone.

Membranous and granular debris (often referred to as 'matrical lipidic debris')




Fig. 17. A rather large focal aggregate of electron-dense filaments (between arrowheads) is seen lying parallel to the collagen fibrils. The possibility that this is a section through the periphery of an elastic fibre cannot be ruled out. $\times 65\ 000$.

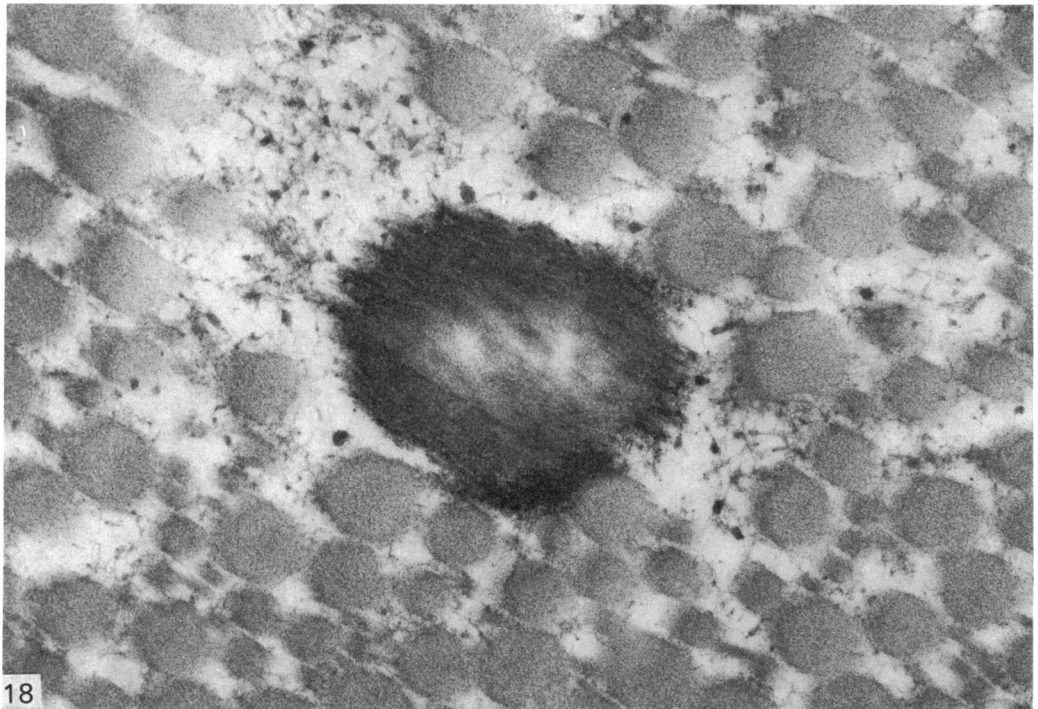


Fig. 18. In the centre of the picture is seen an obliquely cut elastic fibre with a lucent core and a peripheral zone of electron-dense filaments. Note also the protein-polysaccharide particles and associated filaments in the interfibrillary matrix. $\times 65\ 000$.

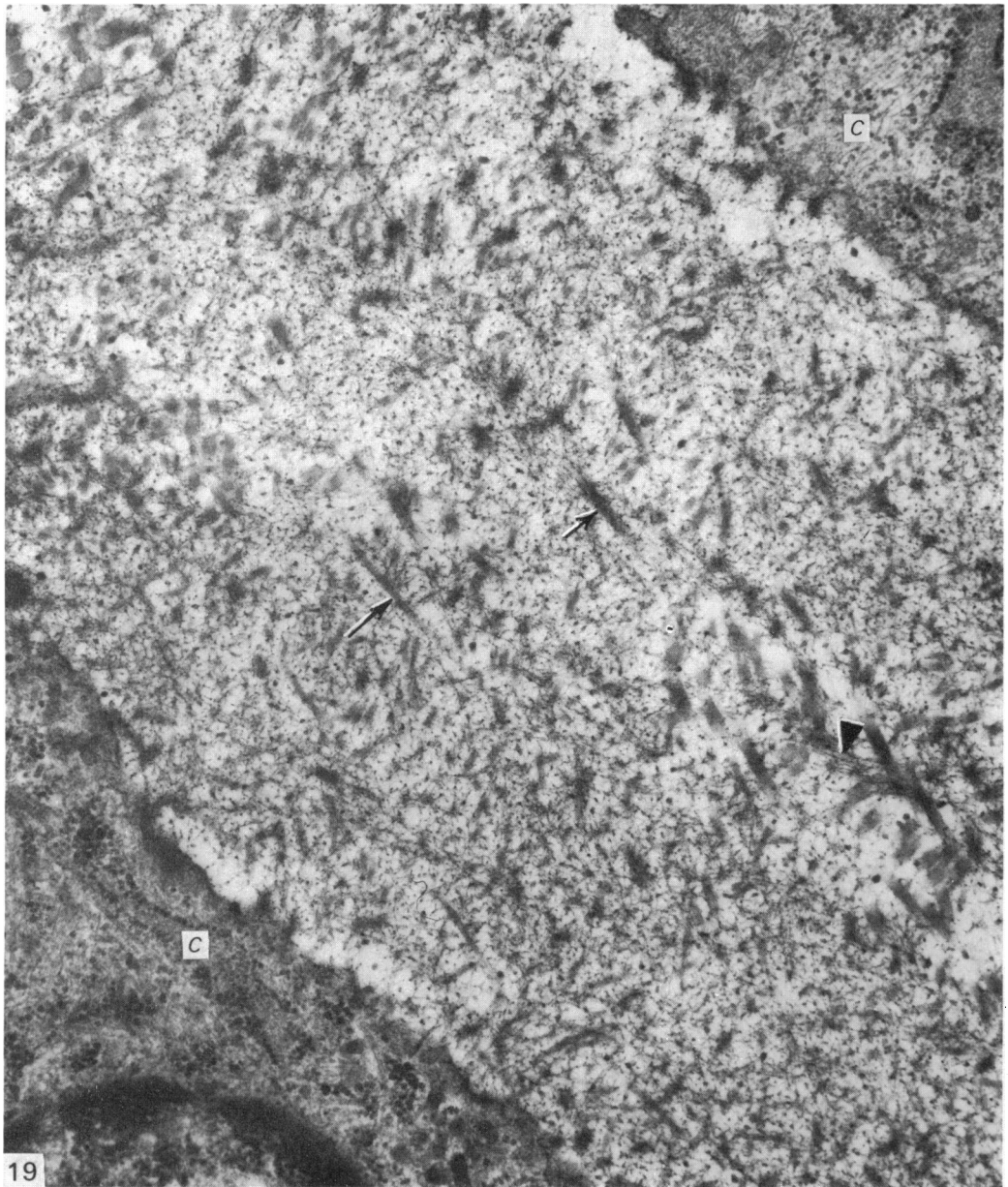


Fig. 19. Territorial matrix between two chondrocytes (C), showing filaments (arrowhead), unbanding fibrils of varying thickness (arrows) and protein-polysaccharide particles of a morphology similar to that shown in Fig. 15. $\times 36000$.

similar to that found in hyaline articular cartilage and thought to be derived by a shedding of cell processes and *in situ* necrosis of chondrocytes (Ghadially, Meachim & Collins, 1965; Ghadially & Roy, 1969) was also seen in the general matrix (Fig.13).

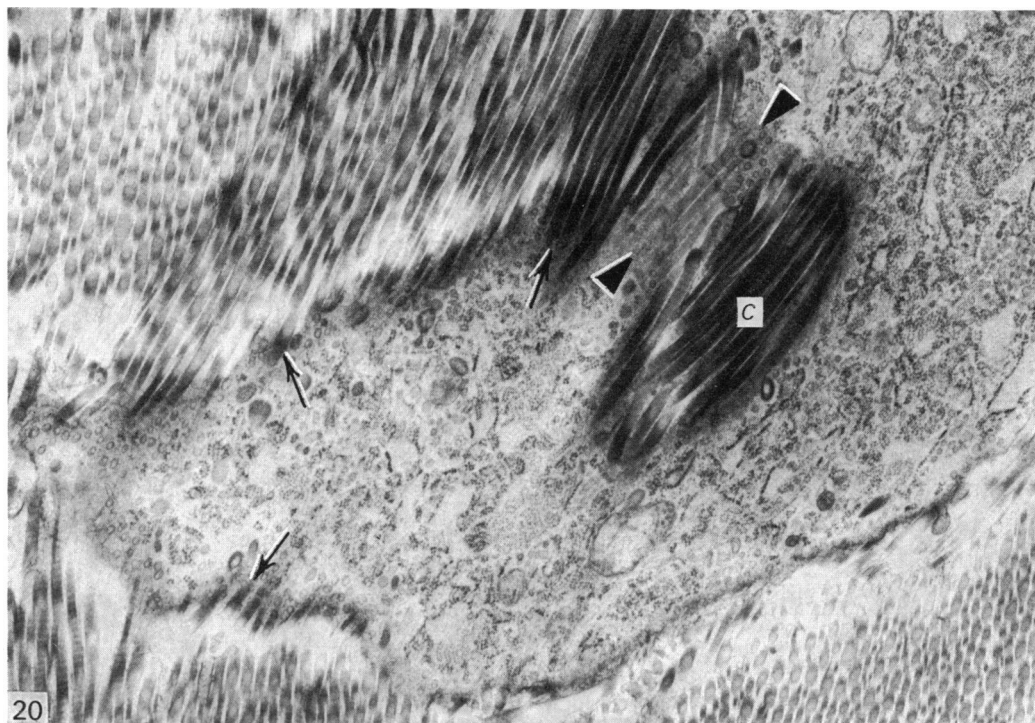


Fig. 20. Close association of collagen fibrils with this chondrocyte has resulted in an overlaying of collagen fibrils on the cell (between arrowheads) within the narrow confines of the section thickness. An appearance is also created as if collagen fibrils are sprouting from the cell surface (arrows). The appearance of an island of collagen fibrils (C) lying within the cell is due to a section through a shallow depression of the cell surface. The expected membrane surrounding the collagen fibrils is not visualized because of tangential sectioning but its presence is indicated by a moderately electron-dense rim around the fibrils. $\times 21\,000$.

Territorial matrix

The territorial matrix, where present, was fine textured, electron-lucent and contained protein-polysaccharide particles with associated short filaments and unbanded fibrils (Fig. 19). In rare instances this specialized matrix completely surrounded a cell (Fig. 7), but more often than not the coarse banded collagen fibrils of the general matrix were directly apposed to some part of the cell membrane (Figs. 5 and 6), sometimes giving the impression that the fibrils were sprouting from the cell surface, or even lying within the cytoplasm (Fig. 20).

DISCUSSION

Nature of cells and tissue

Light microscopists have long wondered whether the tissue comprising discs and menisci contains fibroblasts or chondrocytes or a mixture of both, and whether it should be classified as fibrous tissue or fibrocartilage (e.g. Collins, 1949; Davies, 1969). For example, Davies (1969) states "histologically the discs and menisci of man are predominantly composed of closely interweaving white collagenous fibrous bundles with a few cartilage cells and many fibrocytes". A similar dilemma exists at

the ultrastructural level. This is evidenced by the statement made in a brief abstract by Silva (1970) who states "ultrastructural studies carried out on the intra-articular menisci of the knee joint and the temporomandibular joint of monkeys, cats and guinea pigs revealed that all joints consisted in large part of either dense fibrous tissue or areas of dense fibrous tissue and islands of fibro-cartilage".

However, on the basis of our present study we are inclined to think that the rabbit semilunar cartilages are populated by chondrocytes, and the tissue is best regarded as fibrocartilage. The reasons for this belief are as follows: (1) the cells in the rabbit semilunar cartilages more resemble chondrocytes than fibroblasts because most of them are rounded and have short cell processes on their surface; (2) the oval and elongated cells seen mainly near the surface (which would probably be regarded as fibroblasts by light microscopists) more resemble Zone I chondrocytes of hyaline articular cartilage than fibroblasts; (3) characteristic protein-polysaccharide particles as seen in hyaline articular cartilage and epiphysial cartilage are found in the interfibrillary matrix and territorial matrix; (4) although the territorial matrix is sparse, it does occur, and can be demonstrated in most instances.

Intracellular collagen

The occurrence of single or multiple collagen fibrils within smooth membrane-bound tubular structures (Fig. 10) raises the possibility that these fibrils may be truly intracellular and that fibrillogenesis had occurred within the cell. Support for this idea comes from our observation of fibrillary material in the Golgi sacs and vacuoles of some cells and the fact that such cells often contained membrane-bound collagen as well (Fig. 9).

However, before accepting these observations as proof of intracellular synthesis of collagen fibrils, alternative explanations have to be considered, including (1) phagocytosis of matrical collagen, (2) polymerization of collagen from precursor molecules after removal of tissue from the body, (3) an overlay of collagen fibrils on the cell within the section thickness and (4) the collagen fibrils are really in a bay, invagination or deep infolding of the cell membrane.

Phagocytosis of collagen and its degradation in lysosomes has been witnessed in situations where resorption and remodelling of tissues occur (for references and review see Ghadially, 1975), for example in wound healing and post-partum involution of the uterus. Since the cells we are dealing with are not macrophages, and we found neither evidence of disintegration of collagen nor anything but a rare body acceptable as a lysosome, we are inclined to disregard this explanation.

The second possibility appears untenable because of the rapidity with which tissues were fixed. Further if such a mechanism of post-mortem polymerization of collagen existed one would see intracellular collagen quite frequently in many sites, and this would have been reported in many studies by now, but this is not so.

The third possibility appears also untenable because it is difficult to see how an overlaying of collagen fibrils over a cell surface would give a 'membrane-bound' appearance (Fig. 10) to the fibril. The appearance when collagen overlays a cell margin is depicted in Figure 20: no membrane surrounding the fibrils is evident.

The fourth possibility cannot be so readily dismissed, but one can argue that, since some of the collagen is seen well within the cell, even close to the juxtannuclear Golgi complex, while the membrane surrounding the fibril is sharply defined, it is unlikely that we are witnessing a section through a bay or invagination of the cell membrane.

Further, one can argue that the cells seen in this tissue have a fairly smooth surface interrupted by only a few cell processes, and that deep invaginations are not evident.

Thus, although one cannot be absolutely certain, it does seem that at least some of the membrane-bound collagen we have seen was probably formed within the cell. Support for this idea comes also from two other observations made in this study, namely (1) fibrillary material was found in Golgi sacs and vacuoles which could be interpreted as an early stage of collagen synthesis and polymerization and (2) 'intracellular collagen' was found in cells where the Golgi complex contained filaments.

Mature banded collagen fibrils are believed not to form within normal vertebrate fibrogenic cells, but intracytoplasmic collagen fibrils (not membrane-bound) have been demonstrated in the common garden snail, *Helix aspersa* (Meek, 1968). Membrane-bound collagen of the type described in this paper has been seen in pathological fibroblasts from benign tumour-like or hyperplastic lesions of man designated as desmoid fibromatoses or desmoid fibroblastoma (Welsh, 1966; Allegra & Broderick, 1973). On the basis of their findings, and review of the literature, these authors concluded that collagen fibrils were being formed within Golgi derived smooth membrane-bound tubular structures. Further, Welsh (1966) comments that "intracytoplasmic collagen formation did not represent a normal process, since it has never been described in many excellent studies on the subject". The finding of a similar situation in the normal rabbit meniscus, with the added evidence of filaments in the Golgi complex, supports the idea that there may well be situations where assembly of collagen fibrils occurs prematurely within the cells of even normal tissues.

Collagen fibres

A point of considerable interest is that in rabbit menisci collagen fibrils of markedly different thicknesses were found mingled together to form the fibres and lamellae. Silva (1969, 1970) noted a similar situation in discs and menisci, pointing out that such an arrangement makes these structures efficient *broad-banded* shock absorbers, absorbing energy over a wide range of vibration frequencies.

Past light and scanning electron microscopy studies (Bullough *et al.* 1970; Cameron & MacNab, 1972) have shown that the principal fibre orientation in semilunar cartilages in man is circumferential (i.e. along the length of the meniscus) but that radial and oblique fibres are also present. Our light microscopic observations (Fig. 1) on rabbit menisci are essentially similar, for here too most of the fibres were found to be grouped into bundles which have a circumferential orientation. Electron microscopic observations are in keeping with such an idea, but they cannot bear significantly on this point because of the small size of the samples and the random planes of sectioning.

Elastic fibres

It is now well known that elastic fibres have two components, a central amorphous electron-lucent core and a peripheral zone of short electron-dense filaments about 10 nm in diameter. Further, studies on consecutive stages of elastogenesis in various sites have shown that the filamentous component appears first and that the amorphous component is deposited amongst the filaments, ultimately forming quite a large electron-lucent core (Albert, 1972; Ross, 1973).

Fibres with a central electron-lucent core acceptable as mature elastic fibres were of rare occurrence in rabbit semilunar cartilages, but collections of 10 nm thick

electron-dense filaments acceptable as young or immature elastic fibrils were quite numerous. However, one wonders whether all these fibrils would evolve into mature elastic fibres with the passage of time because this does not appear to be so in the skin (Cotta-Pereira, Guerra-Rodrigo & Bittencourt-Sampaio, 1976).

Collections of electron-dense filaments similar to those seen by us in rabbit menisci were noted by Silva (1969) in the temporomandibular disc of the guinea-pig, but fully formed elastic fibres with a lucent core were not found. The occurrence of elastic fibres in semilunar cartilage seems not to have been noted by light microscopists, but this is easy to understand because mature elastic fibres are sparse and immature ones are too small to be detectable by light microscopy.

SUMMARY

A light and transmission electron microscopical study of 6 to 8 months old rabbit semilunar cartilages has shown that the cells in this tissue resemble chondrocytes more than fibroblasts. The prominent organelles in these cells were rough endoplasmic reticulum and the Golgi complex. An unusual finding was the occurrence of filamentous material in Golgi sacs and vesicles, and collagen fibrils within smooth membrane-bound tubular structures, apparently within the cells. Collagen fibrils forming fibres, fibre bundles and lamellae constituted the major component of the menisci. Protein-polysaccharide particles and associated fine filaments were found in the interfibrillary matrix and in the sparse territorial matrix adjacent to the chondrocytes. Numerous immature elastic fibrils, and rare mature elastic fibres with an electron-lucent amorphous core, were also found in the general matrix amongst the collagen fibrils.

This work was supported by grants from the Medical Research Council of Canada and the Canadian Arthritis and Rheumatism Society.

REFERENCES

- ALBERT, E. N. (1972). Developing elastic tissue. An electron microscopic study. *American Journal of Pathology* **69**, 89-102.
- ALLEGRA, S. R. & BRODERICK, P. A. (1973). Desmoid fibroblastoma, Intracytoplasmic collagenosynthesis in a peculiar fibroblastic tumor: light and ultrastructural study of a case. *Human Pathology* **4**, 419-429.
- BULLOUGH, P. G., MUNUERA, L., MURPHY, J. & WEINSTEIN, A. M. (1970). The strength of the menisci of the knee as it relates to their fine structure. *Journal of Bone and Joint Surgery* **52B**, 564-567.
- CAMERON, H. U. & MACNAB, I. (1972). The structure of the meniscus of the human knee joint. *Clinical Orthopaedics and Related Research* **89**, 215-219.
- CAMERON, H. U. & MACNAB, I. (1973). Lesions of the menisci in man: a scanning electron microscope study. In *Scanning Electron Microscopy*. (ed. O. Johari & I. Corvin). Chicago: IIT Research Institute.
- COLLINS, D. H. (1949). *The Pathology of Articular and Spinal Diseases*. London: E. Arnold.
- COTTA-PEREIRA, G., GUERRA-RODRIGO, F. & BITTENCOURT-SAMPAIO, S. (1976). Oxytalan, elaunin and elastic fibers in the human skin. *Journal of Investigative Dermatology* **66**, 143-148.
- DAVIES, D. V. (1969). The Biology of Joints. In *Textbook of the Rheumatic Diseases* (ed. W. S. C. Copeman), Ch. IV, pp. 40-86. London and Edinburgh: Livingstone.
- GHADIALLY, F. N., MEACHIM, G. & COLLINS, D. H. (1965). Extracellular lipid in the matrix of human articular cartilage. *Annals of the Rheumatic Diseases* **24**, 136-146.
- GHADIALLY, F. N. & ROY, S. (1969). *Ultrastructure of Synovial Joints in Health and Disease*. London: Butterworths.
- GHADIALLY, F. N., BHATNAGER, R. & FULLER, J. A. (1972). Waxing and waning of nuclear fibrous lamina. *Archives of Pathology* **94**, 303-307.
- GHADIALLY, F. N. (1975). *Ultrastructural Pathology of the Cell*. London: Butterworths.
- INOUE, H., ISOMAKI, A. M., OKA, M. & VAINIO, K. (1971). Scanning electron microscopic studies. Fibrocartilage degeneration in rheumatoid arthritis. *Acta rheumatologica scandinavica* **17**, 187-194.

- LYNCH, M. J., RAPHAEL, S. S., MELLOR, L. D., SPARE, P. D. & INWOOD, M. J. H. (1969). In *Medical Laboratory Technology and Clinical Pathology*, 2nd edn, p. 1053. Philadelphia and London: Saunders.
- MEEK, G. A. (1968). Apparent intracellular collagen synthesis. In *Cell Structure and its Interpretation*. (ed. S. M. McGee-Russell & K. F. A. Ross). London: E. Arnold.
- OKADA, A. (1967). Electron microscopic observations on the fibrillogenesis in the fibro-cartilage. *Medical Journal of Osaka University* **18**, 141-154.
- ORYSCHAK, A. K., GHADIALLY, F. N. & BHATNAGER, R. (1974). Nuclear fibrous lamina in the chondrocytes of articular cartilage. *Journal of Anatomy* **118**, 511-515.
- REFIOR, H. J. & FISCHER, H. (1974). Vergleichende mikrostrukturelle Untersuchungen zur Degeneration der Kniegelenksmenisken. *Zeitschrift für Orthopaedie und ihre Grenzgebiete* **112**, 128-133.
- ROSS, R. (1973). The elastic fiber - a review. *Journal of Histochemistry and Cytochemistry* **21**, 199-208.
- SILVA, D. G. (1969). Further ultrastructural studies on the temporomandibular joint of the guinea pig. *Journal of Ultrastructure Research* **26**, 148-162.
- SILVA, D. G. (1970). The fine structure of intra-articular menisci in the knee joint and temporo-mandibular joint in monkeys, cats and guinea pigs. *Anatomical Record* **166**, 2.
- WELSH, R. A. (1966). Intracytoplasmic collagen formations in desmoid fibromatosis. *American Journal of Pathology* **49**, 515-535.