

Peripartum heart disease: an endomyocardial biopsy study

J E SANDERSON,* E G J OLSEN,† D GATEI‡

*From the Departments of Medicine, *St Mary's Hospital Medical School, London; and the †University of Nairobi Medical School, Kenya; and the ‡Department of Histopathology, the National Heart Hospital, London*

SUMMARY Endomyocardial biopsies were performed in 11 African women in Nairobi who presented with the clinical features of peripartum cardiomyopathy. The samples were studied by light and electron microscopy. In five patients there was evidence of a "healing myocarditis", that is the presence of a mild inflammatory cell infiltration within the myocardium with foci of necrosis and variable amounts of hypertrophy and fibrosis. Of the nine patients who were followed up, three out of four with myocarditis had persistent heart failure and four out of five without myocarditis improved. Peripheral blood T lymphocyte cell subsets were measured in nine patients by means of monoclonal antibodies. A high helper:suppressor T cell ratio was found in three patients.

Almost half of this group of patients with peripartum cardiomyopathy had myocarditis in their biopsy specimens. The myocarditis may have been due to an inappropriate immunological reaction in some patients.

Postpartum or peripartum heart disease, defined as unexplained cardiac failure occurring during late pregnancy or after childbirth, is a well recognised but rare condition in Europe and North America. It appears to be more common in African women than in white women.^{1,2} Both the cases in the original descriptions by Hull and Hafkesbring and Hull and Hidden occurred in black patients,^{3,4} and most of the patients in Meadows's major review in 1957 of 50 patients were black Americans.⁵ The condition in East Africa is similar to that described in black Americans and it presents as a typical dilated cardiomyopathy. This resembles cases reported by Brockington⁶ and others⁷ in southern parts of Nigeria but is quite different from the condition in northern Nigeria in which the predominant feature is fluid retention and which probably is caused by local postpartum rituals.^{8,9} Postpartum hypertension^{6,10} and malnutrition¹¹ may be contributory factors. Recently three patients with peripartum

cardiomyopathy were found by histological examination of endomyocardial biopsy specimens to have myocarditis. Immunosuppressive treatment resulted in a pronounced clinical improvement.¹² Because of these findings we performed endomyocardial biopsies on 11 patients in East Africa who presented with features typical of peripartum heart disease.

Patients and methods

Thirteen patients were identified with peripartum heart disease but in two of these further studies were not possible. The remaining 11 patients who presented with unexplained congestive cardiac failure within six months of delivery were studied further. Full history, examination, echocardiography, and cardiac catheterisation were done on all patients.

PATIENTS (TABLE 1)

Eleven women of mean (SD) age 27 (6) years were studied further. The mean time of onset of symptoms after delivery was 7 (6) weeks. Parity varied from one to eight with median of three. All patients had symptoms and signs of biventricular cardiac failure and on admission the mean blood pressure was 115 (25)/75 (13) mm Hg. The patients came from all

Requests for reprints to Dr J E Sanderson, Taunton and Somerset Hospital (Musgrove Park), Taunton, Somerset TA1 5DA.

Accepted for publication 28 April 1986

Table 1 *Clinical data*

Case No	Age	Parity	Time of onset after delivery (weeks)	Blood pressure on admission (mm Hg)
1	33	5 + 0	1	90/65
2	30	3 + 0	22	120/80
3	25	2 + 0	5	96/70
4	18	2 + 0	12	90/60
5	35	3 + 0	12	115/70
6	24	2 + 0	8	110/80
7	18	1 + 0	6	155/95
8	30	4 + 0	1.5	160/100
9	20	1 + 0	4	88/60
10	32	6 + 0	7	120/80
11	32	8 + 0	2	120/68
Mean (1 SD)	27 (6)		7 (6)	115 (25)/75 (13)

the major tribal groups. Table 2 shows the results of M mode echocardiography which was carried out on all patients. The mean left ventricular end diastolic dimension was 6.3 (0.6) cm and was greater than the normal range in all but one patient. The mean fractional shortening was 18 (3) % (normal > 32). Patient 9 had a left ventricular end diastolic dimension of 5.5 cm, which is just within normal limits, but left ventricular function was considerably reduced with a fractional shortening (per cent change in dimension) of 19% and she was therefore included in the study. The left atrium was enlarged in six of 11 patients. All the patients had normal mitral and aortic valves, both clinically and on echocardiography. The normal values for echocardiographic measurements were derived from normal subjects studied at Kenyatta National Hospital; these resembled those in Europeans.

Table 2 *Echocardiographic data*

Case No	LVEDD (cm)	% Δ dimension (fractional shortening)	LA (cm)
1	7.2	22	5.9
2	5.6	18	3.2
3	6.1	18	4.4
4	7.0	16	4.7
5	6.0	18	3.2
6	6.4	11	2.4
7	7.2	17	4.6
8	5.7	19	3.4
9	5.5	19	3.8
10	6.1	21	4.2
11	6.7	22	4.8
Mean (1 SD)	6.3 (0.6)	18 (3)	4.0 (1.0)

LA, left atrial dimension; LVEDD, left ventricular end diastolic dimension; LVESD, left ventricular end systolic dimension.

$$\% \Delta \text{ dimension} = \frac{\text{LVEDD} - \text{LVESD}}{\text{LVEDD}}$$

CARDIAC CATHETERISATION

Cardiac catheterisation was carried out on all 11 patients. In patient 7 a right heart study only was undertaken and a right ventricular biopsy specimen was taken. In all the other subjects left ventricular catheterisation was carried out by the femoral route and left ventricular biopsy specimens were taken. The King's biptome and long sheath technique were used, as previously described.^{13,14} At least three to four specimens were taken from different sites in the left ventricle. Two specimens for light microscopy were placed in formol saline and embedded in paraffin. Ribbons of 5 μ m thick sections were stained with haematoxylin and eosin, Miller's elastic, and van Gieson stains. Another whole specimen was examined by electron microscopy. This was fixed in cacodylate buffered glutaraldehyde. After fixing the specimen for one hour at 4°C, we washed off the fixative and the specimens were transported in buffered sucrose solution. They were then post fixed in 1% osmium tetroxide, processed by the standard technique, and finally embedded in Epon. Sections were cut on an ultra microtome and stained with toluidine blue. Ultra thin sections were stained with uranyl acetate and lead citrate. In some patients frozen sections were also taken for further immunological studies.

T LYMPHOCYTE SUBSETS

Peripheral blood T lymphocyte subsets were measured in nine of the 11 patients by means of Ortho monoclonal antibodies to identify the total number of T cells (OKT3), percentage of helper T cells (OKT4), and suppressor-inducer T cells (OKT8) and hence the helper:suppressor ratios. This has been described in detail elsewhere.¹⁵ The helper:suppressor ratio (OKT4:OKT8) is a measure of activity of the immunological system. Routine viral serology, including measurement of Coxsackie B antibodies, was carried out by standard techniques.

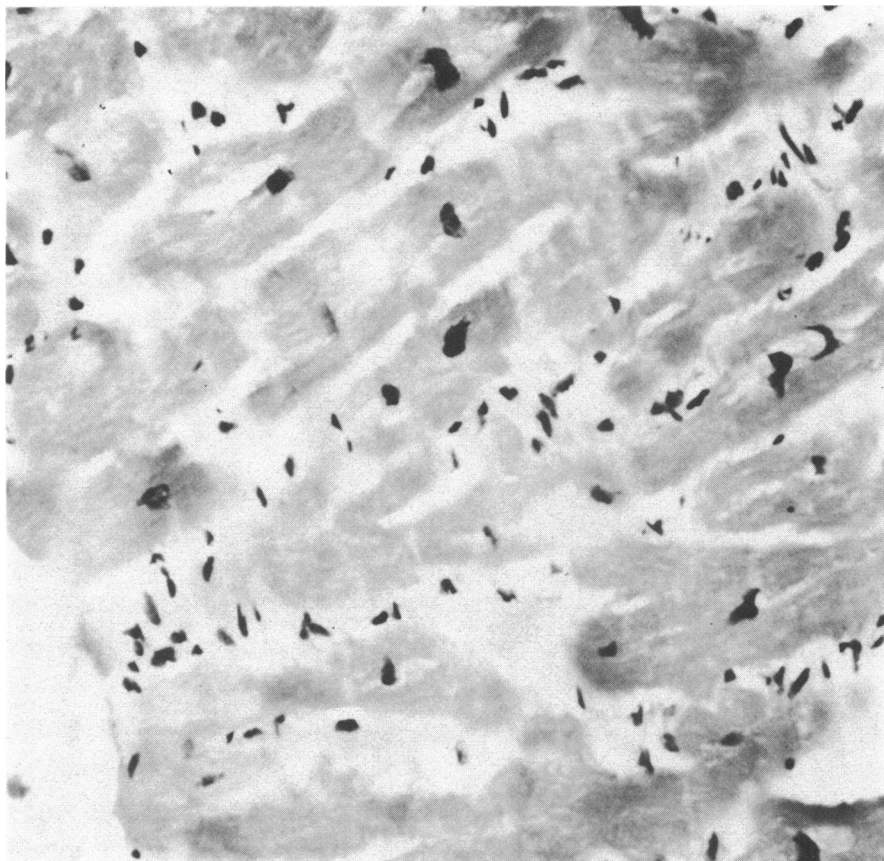


Fig 1 Photomicrograph of an endomyocardial biopsy specimen from a patient that shows evidence of healing myocarditis. Myocardial fibres are regularly aligned and show evidence of hypertrophy (pyknosis) of the nuclei. In the interstitium, chronic inflammatory cells are clearly seen in close contact with adjacent myocardial fibres but there is no damage to the contour of these fibres. Haematoxylin and eosin.

Results

BIOPSY SPECIMENS (FIGS 1, 2, AND 3)

Table 3 summarises the biopsy reports. Biopsy specimens from five patients showed evidence of healing myocarditis. This was a mild cellular inflammatory infiltrate, predominantly of lymphocytes, located in the widened interstitium of the myocardium. Adjacent myocardial fibres showed evidence of necrosis (fraying) in some foci. There was also a variable but usually mild increase of interstitial collagen tissue. Perivascular infiltration and a variable extent of focal myocytolysis was seen. The myocardial fibres were normally aligned and showed evidence of hypertrophy and attenuation. The endocardium was increased in thickness in some cases due to a focal increase of the smooth muscle

component, indicating that left ventricular dilatation had been present for some time. The remaining six patients showed non-specific changes of a hypertrophied, frequently dilated myocardium, with or without mild fibrosis in the interstitium. There were no changes that could positively be attributed to past myocarditis.

Nine patients were available for follow up (minimum six months), and three of the four with myocarditis in their biopsy specimens had persistent heart failure. In contrast four out of the five patients without myocarditis made a good recovery.

T CELL SUBSETS

Table 4 shows the results in the patients studied. There was a considerable increase in the percentage of helper cells (OKT4). Three of the patients had

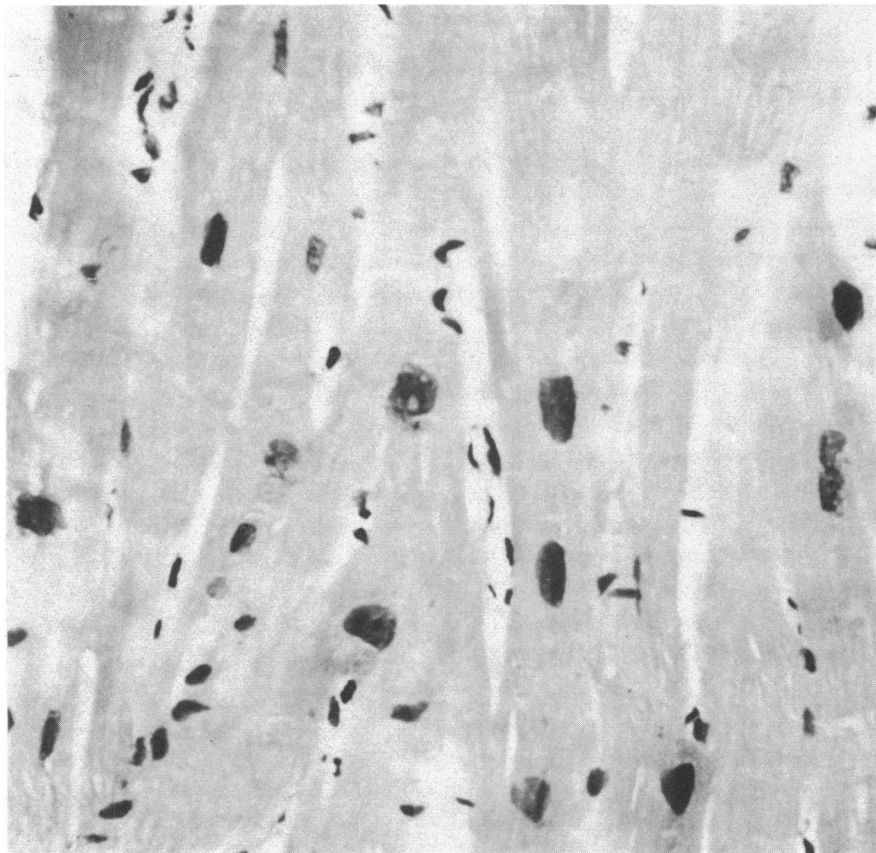


Fig2 Photomicrograph of a patient with hypertrophy and dilatation of the myocardium but no evidence of myocarditis. These changes are non-specific and are similar to those seen in patients with dilated cardiomyopathy. Haematoxylin and eosin.

high helper: suppressor ratios. In the patient with the highest helper: suppressor ratio in the study, however, the biopsy specimen did not show evidence of myocarditis.

VIRAL SEROLOGY

Routine testing for the common viruses was negative and Coxsackie B antibodies were not detected.

Discussion

This is the first study of endomyocardial biopsy specimens from patients with peripartum heart disease studied in East Africa. Nearly half the patients had some evidence of a previous myocarditis. This diagnosis of myocarditis is based on the presence of an inflammatory cell infiltration within the myocardium associated with varying

amounts of myocardial fibre hypertrophy, oedema, degeneration, and fibrosis. These changes are often mild. Myocarditis is one of the most difficult diagnoses to make on morphological examination, especially in the small tissue samples recovered by biptome. A group of pathologists met in Dallas in 1984 to discuss specifically the problems of myocarditis (ME Billingham, E G J Olsen, JJ Fenoglio Jr, *et al*, personal communication). The following definition was formulated: "Myocarditis is characterised by an inflammatory infiltrate and by injury to adjacent myocardial cells that is not typical of infarction".

The commonest finding, however, is a healing (resolved) form of myocarditis which implies that the inflammatory infiltrate has abated. The interstitium may be normal or fibrotic. An increase of fibrous tissue by itself is insufficient evidence of myocarditis



Fig 3 Electronmicrograph showing regular alignment of myocardial fibrils. In the interstitial space, lymphocytes and bundles of collagen can be identified. These changes indicate that the healing phase of myocarditis has been reached. Lead citrate and uranyl acetate.

but the presence of conspicuous chronic inflammatory cells, even on a first biopsy specimen, suggests the possibility of a previous myocarditis. Sampling errors may be a problem because of the small size of the samples obtained by bioptome. It has, however, been shown that if five or more biopsy specimens are taken from a ventricle, then these specimens probably accurately reflect the rest of the myocardium,¹⁶ although the Dallas panel recommends a minimum of three specimens, as were obtained in this study; therefore the presence of focal myocarditis in the "non-myocarditic" group remains a possibility.

Before making the diagnosis of peripartum heart disease we excluded other causes of heart failure such as excessive alcohol intake, previous hypertension, and other systemic diseases. Coronary angiography was not done on these young women; their age, sex, and African origin make it highly unlikely that important coronary artery disease was present.

The cause of the myocarditis is unknown. It is unlikely to be a direct or persisting viral infection *per se*. Tests for Coxsackie antibodies and viral serology were negative in all these patients and there was no sign of viral particles on the electron microscopy specimens. There are some reports, however, that cardiomyopathy may on rare occasions follow a viral infection.^{17,18} In most patients with cardiomyopathy and in the patients studied here the disease is clearly not a straightforward virus myocarditis. The myocardial damage may be secondary to an abnormal immunological reaction. Experimentally, and in the occasional patient, circulatory antimyocardial antibodies, interstitial deposits of immunoglobulins and complement, and cytotoxic lymphocytes directed against autologous myocytes have been demonstrated.^{19,20} It has been suggested that there may be a disturbance of immunoregulation in patients with dilated cardiomyopathy that may be either a primary defect or may merely reflect a persistent immune reaction to an antigen within the heart muscle, possi-

Table 3 Biopsy results

Case No	Time of biopsy after onset of illness (weeks)	Report	Outcome
1	28	Hypertrophied myocardial fibres. No myocarditis	Symptomatic improvement but heart remained enlarged
2	2	No myocarditis (frozen sections only)	Full recovery. Normal left ventricular function at 3 month follow up
3	28	"Healing myocarditis" with hypertrophied myocardial fibres	Continuing heart failure
4	32	"Healing myocarditis". Hypertrophied myocardial fibres with degenerative changes	Lost to follow up
5	8	Hypertrophied fibres. Sparse chronic inflammatory infiltration	Good recovery but blood pressure up (130/100 mm Hg)
6	8	Mild hypertrophied fibres only (non-specific)	Lost to follow up
7	5	(Right ventricular biopsy). No inflammation. Hypertrophied fibres, occasional attenuation	Continuing heart failure
8	3	Mild increase of chronic inflammatory cells. Hypertrophied fibres with evidence of attenuation. "Healing myocarditis"	Continuing heart failure
9	1.5	Hypertrophied fibres. Focal increase in chronic inflammatory cells. "Healing myocarditis"	Recovered
10	11	Hypertrophied fibres only	Heart reduced in size and left ventricular function returned to normal but still some dyspnoea
11	14	Hypertrophied fibres. Increase in chronic inflammatory cells. "Healing myocarditis"	Continuing heart failure
Mean (1 SD)	13(11)		

bly derived from the previous infection. T suppressor cell function is defective in some patients with dilated cardiomyopathy.²¹ Our work on patients with dilated cardiomyopathy in East Africa has shown that the percentage of helper inducer cells in the peripheral blood was significantly higher in the cardiomyopathy group than in normal individuals, and eight out of 20 of the patients had a helper:suppressor cell ratio higher than normal range.¹⁵ These results support the concept that the myocardial damage in dilated cardiomyopathy may be secondary to an immune reaction against the myocardial fibres. In this group of postpartum patients, three had high helper:suppressor ratios. Nevertheless, the biopsy specimen from the patient with the highest helper:suppressor ratio did not show evi-

dence of myocarditis. These T cell data may, however, suggest the involvement of an abnormal immune reaction in causing the myocardial damage in this type of cardiomyopathy.

The question of treatment at the stage of healing myocarditis remains. In the three patients described by Melvin *et al* the myocarditis was much more florid and all three patients were treated with immunosuppressive drugs and there was a pronounced improvement in their symptoms.¹² Demakis and Rahimtoola found that about 50% of patients with postpartum cardiomyopathy improve spontaneously, however,²² and four of our patients recovered almost completely; one had some slight shortness of breath (despite a normal heart size and left ventricular function on the echocardiogram), and another developed mild hypertension. It seems best to reserve the more vigorous treatment for those with florid myocarditis. The presence of healing myocarditis in the biopsy specimens in our patients was generally associated with persisting heart failure; however, the numbers are too small for any definite conclusions. It is of some concern that in the very early stages, when the virus will still be present, treatment with steroids might encourage persistence of the virus and impede the immunological reaction directed at the virus particles themselves.

There are several possible explanations of why this type of cardiomyopathy should develop in the peripartum period. Firstly, it has been shown that if a viral myocarditis is present increase in the cardiac workload will increase the degree of myocardial

Table 4 T cell subsets

Case No	OKT3	OKT4	OKT8	OKT4:OKT8
1	79	43	25	1.7
2	—	—	—	—
3	63	41	39	1.05
4	81	51	34	1.5
5	75	58	39	1.5
6	80	40	32	1.25
7	69	45	33	1.4
8	54	44	27	1.6
9	72	47	31	1.5
10	62	55	13	4.2
11	—	—	—	—
Mean (SEM)	62(3.1)	47.1(2.1)	30.3(2.7)	1.74(0.3)
Normals (n = 20)				
Mean (SEM)	64(2)	32(2)	34(2)	1.0(0.07)

damage.²³ It may be, therefore, that these women had a mild viral myocarditis due to a common virus which would have been cleared under normal circumstances, but that the increased workload of pregnancy and labour led to more myocardial damage than would otherwise have occurred. Secondly, if the disease is due to an abnormal immune reaction to a new virus induced antigen on the myocardial fibres, the immunological changes of pregnancy may favour such a reaction. Certain other immunological diseases occur more commonly after delivery, for example postpartum Graves's disease and thyroiditis,²⁴ and it appears that the fetus may pass suppressor cells or suppressor factor to the mother during the third trimester, and a rebound of helper T cells may occur two to six months after delivery²⁵; this is also the most common time for the presentation of peripartum heart disease. "Blocking" antibodies may also be involved.²⁶

In conclusion, this study has shown that about half the patients in East Africa that we studied by endomyocardial biopsy had evidence of a healing myocarditis and that in some this was associated with other indicators of an excessive immune reaction (high T cell helper:suppressor ratios). These findings support the notion that in some cases peripartum heart disease may be due to myocarditis. In the remainder, an explanation other than myocarditis must be sought.

This study was part of a collaborative programme of the Department of Medicine, St Mary's Hospital, London, the University of Nairobi Medical School, and the Clinical Research Centre, Nairobi that was funded by the Wellcome Trust and a British Heart Foundation grant.

References

- 1 Cardiomyopathies; report of a WHO Expert Committee. *WHO Tech Rep Ser* 697. Geneva: World Health Organisation, 1984.
- 2 Homans DC. Peripartum cardiomyopathy. *N Engl J Med* 1985;312:1432-7.
- 3 Hull E, Hafkesbring E. "Toxic" postpartal heart disease. *New Orleans Med Surg J* 1937;89:550-7.
- 4 Hull E, Hidden E. Postpartal heart failure. *South Med J* 1938;31:265-75.
- 5 Meadows WR. Idiopathic myocardial failure in the last trimester of pregnancy and the puerperium. *Circulation* 1957;15:903-14.
- 6 Brockington IF. Postpartum hypertensive heart failure. *Am J Cardiol* 1971;27:650-8.
- 7 Falase AO. Cardiomegaly of unknown origin among Nigerian adults: role of hypertension in its aetiology. *Br Heart J* 1977;39:671-9.
- 8 Davidson NMCD, Parry EHO. Peripartum cardiac failure. *Q J Med* 1978;47:431-61.
- 9 Sanderson JE, Adesanya CO, Anjorin FI, Parry EHO. Postpartum cardiac failure—heart failure due to volume overload? *Am Heart J* 1979;97:613-21.
- 10 Stout ML. Hypertension 6 weeks postpartum in apparently normal patients. *Am J Obstet Gynecol* 1934;27:730-3.
- 11 Blegen SD. Postpartum congestive heart failure. Beri-beri heart disease. *Acta Med Scand* 1965;178:515-24.
- 12 Melvin KR, Richardson PJ, Olsen EGJ, Daly K, Jackson G. Peripartum cardiomyopathy due to myocarditis. *N Engl J Med* 1982;307:731-4.
- 13 Richardson PJ. King's endomyocardial biopome. *Lancet* 1974;i:660-1.
- 14 Brooksby IAB, Swanton RH, Jenkins BS, Webb-Peploe MM. Long sheath technique for introduction of catheter tip manometer or endomyocardial biopome into left or right heart. *Br Heart J* 1974;36:908-12.
- 15 Sanderson JE, Koech D, Iha D, Ojiambo HP. T-lymphocyte subsets in idiopathic dilated cardiomyopathy. *Am J Cardiol* 1985;55:755-8.
- 16 Baandrup U, Florio RA, Olsen EGJ. Do endomyocardial biopsies represent the morphology of the rest of the myocardium? A quantitative light microscopic study of single versus multiple biopsies with the King's biopome. *Eur Heart J* 1982;3:171-8.
- 17 Obeyesekere I, Hermon Y. Arbovirus heart disease: myocarditis and cardiomyopathy following dengue and chikungunya fever—a follow-up study. *Am Heart J* 1973;85:186-94.
- 18 Cambridge G, MacArthur CGC, Waterson AP, Goodwin JF, Oakley CM. Antibodies to Cocksackie B viruses in congestive cardiomyopathy. *Br Heart J* 1979;41:692-6.
- 19 Kawai C, Takatsu T. Clinical and experimental studies on cardiomyopathy. *N Engl J Med* 1975;293:592-7.
- 20 Anonymous. Virus, immunology and the heart. *Lancet* 1979;ii:1111-3.
- 21 Fowles RE, Beiber CP, Stinson EB. Defective in vitro suppressor cell function in idiopathic congestive cardiomyopathy. *Circulation* 1979;59:483-91.
- 22 Demakis JG, Rahimtoola SH. Peripartum cardiomyopathy. *Circulation* 1971;44:964-8.
- 23 Woodruff JF. Viral myocarditis. A review. *Am J Pathol* 1980;101:425-84.
- 24 Amino N, Mori H, Iwatani Y, et al. High prevalence of transient postpartum thyrotoxicosis and hypothyroidism. *N Engl J Med* 1982;306:849-52.
- 25 Froelich CJ, Goodwin JS, Bankhurst AD, Williams RC. Pregnancy, a temporary fetal graft of suppressor cells in autoimmune disease? *Am J Med* 1980;69:329-31.
- 26 Faulk WP, Johnson PM. Immunological studies of human placentae: basic and practical implications. In: Thompson RA, ed. *Recent advances in clinical immunology*. Vol. II. Edinburgh: Churchill Livingstone, 1980;1-31.