CASE REPORTS

Refer to: Shanley JD, Cline MJ: Phagocytosis of hematopoietic cells by blast cells in blast crisis of chronic myelocytic leukemia. West J Med 126:139-141, Feb 1977

Phagocytosis of Hematopoietic Cells by Blast Cells in Blast Crisis of Chronic Myelocytic Leukemia

JOHN D. SHANLEY, MD
MARTIN J. CLINE, MD
Los Angeles

PHAGOCYTOSIS of formed bone marrow elements by neoplastic cells is generally associated with monocytic-histiocytic disorders,[1-6] although it has been described as a rare event in other neoplastic conditions.[7-9] We recently saw a patient with Philadelphia-chromosome-positive chronic myelocytic leukemia in whom there was striking phagocytosis of cellular elements during blast crisis.

Report of a Case

A 23-year-old Vietnamese woman was in good health until December 1974 when she noted the onset of mild fatigue, easy bruising and mild sternal tenderness. In February 1975 a routine blood count showed anemia and a leukocyte count of 104,000 per microliter (μl) with all developmental stages of the granulocytic series present on peripheral blood smear. Evaluation at that time showed an undetectable leukocyte alkaline phosphatase, a normal liver-spleen scan, and a bone marrow aspirate and peripheral blood smear consistent with chronic myelocytic leukemia.

Busulfan therapy was carried out for three weeks, and by May 1975 the blood counts had returned to within normal limits. However, in September the leukocyte count again began to rise, and the patient was referred to the University of California Medical Center at Los Angeles.

On initial evaluation the patient complained of frequent bifrontal headaches and occasional fever, but was otherwise asymptomatic. Findings on physical examination were unremarkable. Laboratory studies showed the following values: hematocrit reading, 39 percent; leukocyte count, 21,000 per μl; platelets, 400,000 per μl; leukocyte alkaline phosphatase, 28 (normal, 50 to 150). Values for serum electrolytes, glucose and creatinine, and findings on roentgenogram of the chest were all normal. Stool specimens were negative for ova and parasites. Skin tests for coccidioidomycosis and with tuberculin were negative, but mumps skin test was positive. Karyotype analysis of the bone marrow showed cells with 46 chromosomes and a single Philadelphia chromosome.

The patient left the hospital and therapy was resumed with busulfan, 2 mg per day, and allopurinol, 300 mg per day. During the next three weeks she noticed increasing headaches, the development of scalp tenderness and temperatures of 102°F (38.9°C). In addition, hepatosplenomegaly developed. Leukocyte count increased to 53,000 per μl with an increasing number of blast forms present on blood smear. In early November 1975 she reentered the hospital for evaluation of fever, headache and failure to respond to chemotherapy. Findings on cerebrospinal fluid analysis, computerized cerebral tomography, sinus and skull films, upper gastrointestinal series, abdominal ultrasound and mammogram studies were within normal limits. Urine and serum muramidase, and urine vanillylmandelic acid were also normal. Bone marrow examination showed a pattern consistent with the accelerated phase of chronic myelocytic leukemia with scattered nests of myeloblasts. Numerous large immature cells with basophilic cytoplasm, homogeneous nuclear chromatin, nucleoli and phagocytized intact cellular elements were present (see Figures 1 through 3). These primitive cells did not stain for peroxidase or for alpha naphthyl butyrase, a marker for mononuclear phagocytes.

From the Division of Hematology-Oncology, Department of Medicine, University of California, Los Angeles, School of Medicine.

Supported by USPHS Grants CA 15688 and CA 15619.
Submitted February 20, 1976.

Reprint requests to: Martin J. Cline, MD, Department of Medicine, UCLA Center for the Health Sciences, Los Angeles, CA 90024.

Karyotyping of the bone marrow at this time showed three abnormal cell populations. One showed 46 chromosomes with the XX pattern and one Philadelphia chromosome. One possessed 48 chromosomes with two Philadelphia chromosomes and an acrocentric marker. The last contained 49 chromosomes with the same pattern as the population with 48, but contained an additional C-group chromosome.

Evaluation of the patient's headache and fever, and an extensive search for a possible second neoplasm were negative. She was treated for two weeks with high-dose busulfan without improvement. Therapy was then changed to 6-mercaptopurine, 150 mg per day, but the development of pancytopenia during the subsequent three weeks limited further treatment. Repeat bone marrow aspiration and biopsy study at this time showed a highly cellular marrow of predominantly immature cells. Most myeloid cells were either blast cells or promyelocytes, and numerous blast cells contained ingested erythrocytes.

In December 1975 therapy with vincristine, 1.8 mg per week, and prednisone, 60 mg per day, was initiated, but produced no beneficial effect during a three-week course. During this period, blast cells containing ingested erythrocytes were observed in the peripheral blood smear. The patient remained pancytopenic and required both antibiotics and multiple transfusions of platelets and red blood cells. In early January blood loss into the subarachnoid space occurred and the patient died from subsequent respiratory arrest. An autopsy was not done.

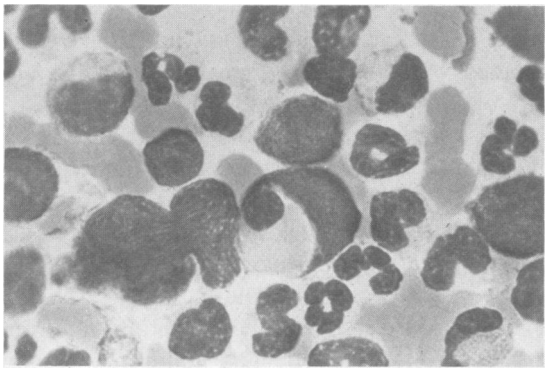

Figure 1.—An acidophilic normoblast engulfed by a blast cell in the bone marrow.

Discussion

A striking and unusual feature of this case of Philadelphia-chromosome-positive chronic myelocytic leukemia was the intense phagocytosis of blood cells that developed during blast crisis. Phagocytosis of various marrow elements by neoplastic cells was seen repeatedly in bone marrow aspirates, and erythrophagocytosis was present in peripheral blood smears. The phagocytic cells were morphologically primitive cells with prominent nucleoli and without granulation. They failed to stain for either alpha naphthyl butyrase (lipase) or peroxidase. Urine and serum muramidase were within the normal range. Using light microscopy and histochemistry it was not possible to determine the line of origin of these blast cells.

Phagocytosis is a well-recognized function of the granulocytic and mononuclear phagocytic cell series. In general, this capacity is associated with increasing maturation of granulocytes,[10,11] although myelocytes[10] and even myeloblasts[12] have been observed to ingest microorganisms or particles. However, immature granulocytes perform this function poorly. No reports of ingestion of cellular elements by granulocytes could be found in a search of the literature.

Phagocytosis of cellular elements is a characteristic feature of the monocytic-histiocytic disorders,[1-6] although it has been reported to occur

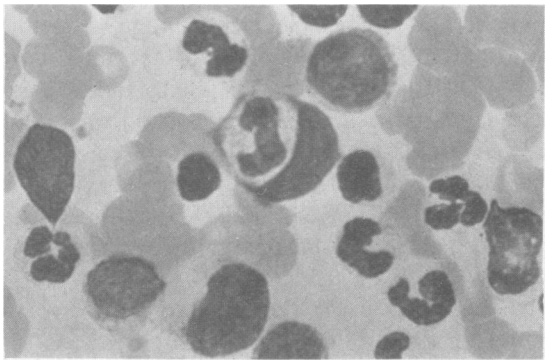

Figure 2.—A phagocytized neutrophilic band cell within a blast cell.

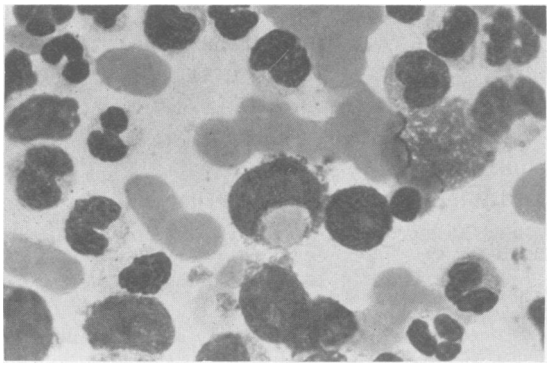

Figure 3.—An erythrocyte ingested by a leukemic cell in the bone marrow.

occasionally in normal bone marrow[13] and in hemolytic anemia.[14,15] Active phagocytic activity in mononuclear leukemia is well described.[1,3,16] Phagocytosis of cellular elements is common in histiocytic medullary reticulosis[1-6] and may be an occasional feature of histiocytic lymphoma. Other sporadic instances of phagocytosis of cellular components have been reported. Three cases of erythrophagocytosis in plasma cell leukemia have been described.[7,8] Two cases of red cell ingestion by carcinoma infiltrating the bone marrow have been reported.[9] However, no cases of this form of phagocytic activity in chronic myelocytic leukemia were found.

It is interesting to speculate on the significance of the development of phagocytosis during the evolution of chronic myelocytic leukemia. Current evidence suggests that chronic myelocytic leukemia is a clonal disorder of a pluripotential hematopoietic stem cell[17] since the Philadelphia chromosome marker can be found not only in polymorphonuclear leukocytes but also in precursors of red cells, eosinophils and platelets.[17-19] The disorder may involve mononuclear phagocytes as well, given the close relation between the developing granulocytic and monocytic series.[20] Phagocytosis may be a feature of very primitive mononuclear phagocytes[1,21] and may account for the striking ingestion of hematopoietic elements observed in this case.

Summary

In a patient with Philadelphia-chromosome-positive chronic myelocytic leukemia in blast crisis there was intense phagocytosis of formed blood elements by undifferentiated blast cells. Primitive cells containing ingested leukocytes, erythrocytes and platelets were seen in both the bone marrow and the peripheral blood. The possible implications of this unusual finding during blast crisis in chronic myelocytic leukemia are discussed.

REFERENCES

1. Cline MJ, Golde DW: A review and reevaluation of the histiocytic disorders. Am J Med 55:49-60, 1973
2. Lynch EC, Alfrey CP Jr: Histiocytic medullary reticulosis. Hemolytic anemia due to erythrophagocytosis by histiocytes. Ann Intern Med 63:666-671, 1965
3. Strumia MM, Boerner F: Phagocytic activity of circulating cells in the various types of leukemia. Am J Path 13:335-349, 1937
4. Natelson EA, Lynch EC, Hettig RA, Alfrey CP: Histiocytic medullary reticulosis. Arch Intern Med 122:223-229, 1968
5. Friedman RM, Steigbigel NH: Histiocytic medullary reticulosis. Am J Med 38:130-133, 1965
6. Shreiner DP: Acute lymphoblastic leukemia terminating as histiocytic medullary reticulosis. JAMA 231:838-840, 1975
7. Abramson N, von Kapff C, Ginsburg AD: The phagocytic plasma cells. N Engl J Med 283:248-250, 1970
8. Butterworth CE Jr, Frommeyer WB Jr, Riser WH Jr: Erythrophagocytosis in a case of plasma cell leukemia. Blood 8: 519-523, 1953
9. Spivak JL: Phagocytic tumor cells. Scand J Haemat 11: 253-256, 1973
10. Altman AJ, Stossel TP: Functional immaturity of bone marrow bands and polymorphonuclear leucocytes. Br J Haemat 27:241-245, 1974
11. Lichtman MA, Weed RI: Alteration of the cell periphery during granulocyte maturation: Relationship to cell function. Blood 39:301-316, 1972
12. Whang-Peng J, Perry S, Knutsen T: Maturation and phagocytosis by chronic myelogenous leukemia cells in vitro—A preliminary report. J Natl Cancer Inst 38:969-972, 1967
13. Martin PF: Erythrophagocytosis in the human bone marrow. Scand J Haemat 7:177-183, 1970
14. Rappaport H, Crosby WH: Auto-immune hemolytic anemia —II. Morphologic observations and clinicopathologic correlations. Am J Path 33:429-457, 1957
15. Dameshek W, Schwartz SO: Acute haemolytic anemia (acquired hemolytic icterus, acute type). Medicine 19:231-237, 1940
16. Lichtman MA, Weed RI: Peripheral cytoplasmic characteristics of leukocytes in monocytic leukemia: Relation to clinical manifestations. Blood 40:52-61, 1972
17. Boggs DR: Hematopoietic stem cell theory in relation to possible lymphoblastic conversion of chronic myeloid leukemia. Blood 44:449-453, 1974
18. Whang-Peng J, Frei E III, Tjio JH, et al: The distribution of the Philadelphia chromosome in patients with chronic myelocytic leukemia. Blood 22:664, 1963
19. Chervenick PA, Ellis L, Pan S, et al: The Philadelphia chromosome in in vitro colonies from patients with chronic myelocytic leukemia. Science 174:1134, 1971
20. Metcalf D, Moore MAS: Haemopoietic Cells. North-Holland Publishing Co., Amsterdam, 1971
21. Cline MJ: Defective mononuclear phagocyte function in patients with myelomonocytic leukemia and in some patients with lymphoma. J Clin Invest 52:2185-2190, 1973

Refer to: Johnston JG, Robertson WO: Fatal ingestion of table salt by an adult. West J Med 126:141-143, Feb 1977

Fatal Ingestion of Table Salt by an Adult

JOHN G. JOHNSTON, MD
WILLIAM O. ROBERTSON, MD
Seattle

In 1963 sodium chloride poisoning was well publicized after the tragic deaths of six infants fed formulas inadvertently prepared with table salt instead of sugar.[1] Nonfatal salt poisoning has been described in a set of 14-month-old twins who consumed some from a box of commercial salt.[2] Fatal salt poisoning due to gastric lavage with hypertonic salt has been described in a 2-year-old and a 22-month-old child.[3] Moreover, the danger of using salt as an emetic both in children and in adults has been underscored by reported fatali-

From the Department of Pediatrics, University of Washington School of Medicine, and the Poison Control Center, Children's Orthopedic Hospital and Medical Center, Seattle.

Submitted, revised, February 5, 1976.

Reprint requests to: William O. Robertson, MD, Children's Orthopedic Hospital and Medical Center, P.O. Box 5371, Seattle, WA 98105.