

CASE REPORTS

Refer to: Burbige EJ, Bedine MS, Handelsman JC: Adenocarcinoma of the small intestine in Crohn disease involving the small bowel. *West J Med* 127:43-45, Jul 1977

Adenocarcinoma of the Small Intestine in Crohn Disease Involving the Small Bowel

EUGENE J. BURBIGE, MD
Martinez, California

MARSHALL S. BEDINE, MD
JACOB C. HANDELSMAN, MD
Baltimore

CHRONIC INFLAMMATORY DISEASE predisposes the development of carcinoma in the colon in persons with ulcerative colitis^{1,2} and perhaps also in those with Crohn disease of the colon.³ The relationship between carcinoma of the small intestine and Crohn disease, however, is not clear. It has been suggested that the finding of adenocarcinoma in the small bowel in association with Crohn disease may be of statistical significance.⁴

We have recently found adenocarcinoma of the small intestine in a patient with long-standing Crohn disease. We have reviewed the experience with small bowel adenocarcinoma and Crohn disease at The Johns Hopkins Hospital and in the literature in order to help establish the frequency of this occurrence.

Report of a Case

A 43-year-old white man had a 20-year history of cramping and diarrhea. Admission to hospital was required in 1957 at which time no operative procedure was done. In 1960 a mass was drained

From the Department of Medicine, Division of Gastroenterology, and the Department of Surgery, The Johns Hopkins University, Baltimore. Dr. Burbige is now with the University of California, Davis, School of Medicine and the Veterans Administration Hospital in Martinez, California.

Submitted, revised, July 27, 1976.

Supported in part by NCI Grant # CA 14925-02.

Reprint requests to: Eugene J. Burbige, MD, Veterans Administration Hospital, 150 Muir Road, Martinez, CA 94553.

in the right lower quadrant without resection. In March 1961 ileal resection and an ileotransverse colostomy were carried out. Postoperatively, a fistula developed. An attempt at repair in 1963 was unsuccessful and a long enterocutaneous fistula developed. This was eventually repaired successfully. The patient was readmitted to The Johns Hopkins Hospital in July 1973 for evaluation of abdominal cramping and bloating occurring six to eight hours after meals. This was associated with fever to 102° F. Findings on a small bowel series included two areas of moderate narrowing at the anastomotic site with friable mucosa around the anastomosis. Biopsy studies of specimens obtained at colonoscopy showed acute and chronic inflammation with increased crypt mitoses. Specimens of both colonic and ileal mucosa were obtained.

Because of persistent obstructive symptoms, laparotomy was done. An abscess was drained from the mesentery of the terminal ileum with a fistula between the ileum and abscess noted. Approximately 25 cm of ileum was resected and an ileostomy was carried out. On pathologic examination of the removed portion of ileum, changes were noted that were consistent with Crohn disease. The ileum was notably thickened with an ulcerated wall containing sinus tracts, abscesses, chronic inflammation and scarring in all layers. A focus of adenocarcinoma (Figure 1) was found which seemed to arise in the base of an ulcer in the diseased part of ileum. The carcinoma was moderately well-differentiated and invaded the bowel wall, scar tissue, smooth muscle and perineural lymphatics. The carcinoma did not, however, reach the serosa. The ileal mucosa showed extensive pyloric metaplasia, but no epithelial changes resembling the "precancer" changes seen in ulcerative colitis.

The patient's subsequent course was complicated by several episodes of nephrolithiasis. The ileostomy was later taken down and continuity of the bowel reestablished. The patient has had an uncomplicated course since that time.

The Johns Hopkins Hospital Experience

From 1964 through 1973 there were 495 admissions for regional enteritis to The Johns Hop-

CASE REPORT

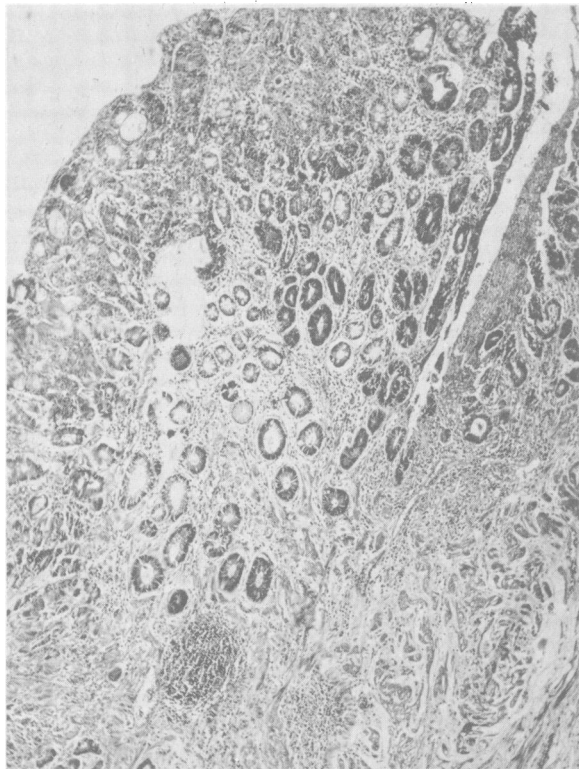


Figure 1.—Photomicrograph of resected ileum showing a focus of invasive adenocarcinoma (Hematoxylin and eosin, reduced from 50 \times).

kins Hospital. During that same period, there were 68 small bowel resections done in 64 patients with regional enteritis. There were two surgical specimens of duodenum, two of jejunum and 66 of ileum. The average age of this group of patients was 32.8 years. There were 34 females and 30 males. In one female there were three resections of the ileum and in two males there were two resections each of ileum. The most frequent reason for surgical intervention was the presence of fistula, second most common was obstruction and third was the presence of a mass. Carcinoma was found in only one resected specimen, that of the patient described in the above case report. During that same period, 11 primary adenocarcinomas of the small intestine were seen. There were two in the duodenum, five in the jejunum and four in the ileum. The average age at discovery was 53.7 years. There were four females and seven males.

Discussion

The first reported case of adenocarcinoma of the small bowel occurring in a patient with Crohn disease was described by Ginzburg and co-work-

ers in 1956.⁵ Since then, there have been 41 cases reported of adenocarcinoma of the small intestine in patients with Crohn disease.⁵⁻¹⁷

Carcinoma of the small bowel occurs with an incidence of 0.3 per 100,000 population per year.¹⁸ The prevalence of Crohn disease is approximately 9 per 100,000.¹⁹ The chances of the two diseases occurring simultaneously is put at no more than one in 1,000 million.⁵ Fielding and associates⁴ reviewed their experience with 295 patients having Crohn disease and found the incidence of malignancy higher than expected, but this was based on finding only one case. In their series of patients with Crohn disease several different malignant lesions were found, but only the higher incidence of cancer of the pancreas and small intestine were statistically significant (at the 5 percent level).

There are some striking differences between patients with primary small bowel malignancies and patients with Crohn disease in whom carcinoma of the small intestine developed. The average age of patients with small bowel tumors is 55 years and the duration of symptoms is 14 months. The mean survival has been described to be 32 months.¹² In 486 cases of primary small intestinal tumors, 215 occurred in the duodenum, 172 in the jejunum and 90 in the ileum.²⁰ In patients with Crohn disease in whom adenocarcinoma developed, the average age is 43.3 years, duration of symptoms is 14.5 months and average survival is only six months. In patients with Crohn disease, carcinoma developed more often in the ileum, a pattern more consistent with the distribution of Crohn disease rather than primary small bowel carcinoma. In 44 percent of reported cases, the carcinoma was found in a bypassed segment.¹⁵

Even a high index of suspicion may not increase the frequency of diagnosis. Radiologic investigation of surgically excluded segments of small intestine is quite difficult. Surgical operation may not be helpful, and the diagnosis is frequently made postoperatively by pathological examination, as was seen in the present case. One case was suspected preoperatively,⁸ five cases were diagnosed at operation,^{6,7,11-13} two cases were diagnosed postmortem and the remainder postoperatively. The most frequent reason for operation was intestinal obstruction in long-standing regional enteritis.

Although the number of cases reported in the literature suggests that this complication occurs more frequently than by chance alone, no indi-

CASE REPORT

cation of the true incidence can be obtained. Aside from the study by Fielding and co-workers,⁴ reports have not given any indication of the population at risk. Since referral centers usually deal with more severe disease, the experience at one institution may not relate to all patients with regional enteritis. In order to obtain an idea of the incidence of this complication, the population at risk should be identified whenever a case is reported. The series reported here deals only with inpatients and since the follow-up of each patient is incomplete, only those operated on can be excluded as not having carcinoma. In order to obtain the incidence of adenocarcinoma in regional enteritis detailed studies of large groups, perhaps combining several institutions, with long periods of follow-up are necessary.

How regional enteritis predisposes to carcinoma is unknown. It may be that as in long-standing ulcerative colitis, long-standing inflammation leads to carcinoma. Weingarten and Weiss,⁷ and Berman and Prior,⁹ felt that long-standing inflammation preceding the malignant change served as evidence of an etiological relationship and suggested that the disease caused chronic irritation in the way that ulcerative colitis predisposes to carcinoma of the colon. The situation is not entirely analogous since no premalignant changes have been described in regional enteritis as they have been in some cases of ulcerative colitis. A possible explanation for the development of carcinoma is bile acid alteration resulting from bacterial flora changes and stasis. This may help explain the frequent occurrence in bypassed segments. A similar mechanism has recently been suggested as possibly playing a role in the development of colonic carcinoma.²¹

Malignant lesions other than small bowel tumors have been reported in association with regional enteritis. Carcinoma of the colon has occurred in patients with granulomatous colitis.^{10,22,23} Three cases of reticulum cell sarcoma^{4,24,25} in association with Crohn disease as well as one of carcinoid²⁶ have been reported. In addition, pancreatic carcinoma, carcinoma of the ampulla of Vater and esophageal carcinoma have been reported to occur in association with regional enteritis. At present, too few data are available to

assess whether all these malignancies are related to the granulomatous process.

Patients with regional enteritis in whom adenocarcinoma of the small intestine develops are those with long-standing disease (more than ten years in most cases). They present with fistulae, intestinal obstruction, abdominal mass or with general deterioration. These factors should be considered by physicians caring for patients with chronic regional enteritis. When surgical operation is indicated bypass procedures should be avoided, if possible.

REFERENCES

1. Goldgraber MB, Humphreys EM, Kirsner JB, et al: Carcinoma and ulcerative colitis: A clinical pathologic study—Statistical analysis. *Gastroenterology* 34:840-846, 1958
2. Morson BC: Cancer in ulcerative colitis. *Gut* 7:425-426, 1966
3. Weedon DD, Shorter RG, Ilstrup DM, et al: Crohn's disease and cancer. *N Engl J Med* 289:1099-1103, 1973
4. Fielding JF, Prior P, Waterhouse JA, et al: Malignancy in Crohn's disease. *Scand J Gastroenterol* 7:3-7, 1972
5. Ginzburg L, Schneider KM, Dreizin DH, et al: Carcinoma of the jejunum occurring in a case of regional enteritis. *Surgery* 39:347-351, 1956
6. Kornfeld P, Ginzburg L, Aldersberg D: Adenocarcinoma occurring in regional jejunitis. *Am J Med* 23:493-498, 1957
7. Weingarten B, Weiss J: Malignant degeneration in chronic inflammatory disease of the colon and small intestine. *Am J Gastroenterol* 33:203-207, 1960
8. Zisk J, Shore JM, Rosoff L, et al: Regional ileitis complicated by adenocarcinoma of the ileum—A report of two cases. *Surgery* 47:970-974, 1960
9. Berman LG, Prior JT: Adenocarcinoma of the small intestine occurring in a case of regional enteritis. *J Mt Sinai Hosp* 31:30-37, 1964
10. Sheil R, Clark CG, Goligher JC: Adenocarcinoma associated with Crohn's disease. *Br J Surg* 55:53-58, 1968
11. Magnes M, DeBell P: Carcinoma associated with terminal ileitis. *J Med Soc New Jersey* 66:573-577, 1969
12. Papp JP, Pollard HM: Adenocarcinoma occurring in Crohn's disease of the small intestine. *Am J Gastroenterol* 56:149-156, 1971
13. Farmer RG, Hawk WA, Turnbull RB: Carcinoma associated with regional enteritis: Report of two cases. *Am J Dig Dis* 15:365-371, 1970
14. Lear PE: The physiological basis for the surgical management of regional enteritis. *Surg Clin North Am* 38:535-559, 1958
15. Dikman SH, Toker C: Enteroblastoma complicating regional enteritis. *Gastroenterology* 65:462-466, 1973
16. Greenstein AJ, Janowitz HD: Cancer in Crohn's disease. *Am J Gastroent* 65:122-124, 1976
17. Lightdale CJ, Sternberg SS, Posner G, et al: Carcinoma complicating Crohn's disease. *Am J Med* 59:262-268, 1975
18. Does Crohn's disease predispose to intestinal cancer? *Br Med J* 4:3-4, 1973
19. Evans JG, Acheson ED: An epidemiological study of ulcerative colitis and regional enteritis in the Oxford area. *Gut* 6:311-324, 1965
20. Bockus HD: *Gastroenterology*, Vol 2. Philadelphia, WB Saunders Co. 1964, p 178
21. Hill MJ, Drasar BS, Aries V, et al: Bacteria and etiology of cancer of the large bowel. *Lancet* 1:95-100, 1971
22. Warren S, Somers SC: Pathogenesis of ulcerative colitis. *Am J Path* 25:657-680, 1949
23. Van Patter WN, Barger JA, Dockerty MB, et al: Regional enteritis. *Gastroenterology* 26:347-450, 1954
24. Hughes RK: Reticulum cell sarcoma: A case possibly originating in regional enteritis. *Am J Surg* 21:770-773, 1955
25. Wyburn-Mason R: Crohn's disease and carcinoma of the colon. *Br Med J* 2:697, 1968
26. Wood WJ, Archer R, Schaefer JW, et al: Coexistence of regional enteritis and carcinoid tumor. *Gastroenterology* 59:265-269, 1970