

# Skin and Soft Tissue Polymicrobial Infections From Intravenous Abuse of Drugs

DAVID WEBB, MD, and HARAGOPAL THADEPALLI, MD, Los Angeles

*Skin and soft tissue infections were studied in 21 seriously ill narcotic addicts who had been admitted to hospital. Subcutaneous abscesses were present in 14 patients; cellulitis was noted in 3, pyomyositis in 2 and necrotizing fasciitis in 2. In four patients there was septicemia. Infections in 14 patients (66.6 percent) were associated with anaerobic bacteria, which were the exclusive isolates in 6 patients. In seven patients (33.3 percent) isolates were exclusively aerobic bacteria and in eight both aerobes and anaerobes were present. The anaerobic isolates were clostridia (six), peptostreptococci (five), bacteroides (five), peptococci (three), and one of each of Veillonella, Propionibacterium, Eubacterium, Fusobacterium and Actinomyces. Staphylococcus aureus, generally thought to be the most common cause of subcutaneous infections in addicts, was found only in four (19 percent) patients. The other aerobic isolates were Klebsiella (five) and Enterobacter (four) species. When clinical features or the Gram stain of pus suggest that anaerobic bacteria may be present, antibiotic therapy should be directed against both aerobic and anaerobic bacteria until culture results are available.*

THE SYSTEMIC AND LOCAL infectious complications of narcotic addiction are well known.<sup>1</sup> Among the more common but less well-studied are skin and soft tissue infections such as subcutaneous

abscess, cellulitis, pyomyositis and necrotizing fasciitis. Hussey and Katz<sup>2</sup> noted skin abscess in 26 percent of 263 heroin addicts. Vollum<sup>3</sup> reported that 65 percent of 54 heroin addicts had a history of skin abscesses. Louria and Hensle<sup>4</sup> described skin abscess of cellulitis in 21 (22 percent) of 96 addicts they studied over three years. Despite the frequent occurrence of soft tissue infections in heroin addicts, relatively little is known

From the Division of Infectious Diseases, Department of Internal Medicine, Martin Luther King, Jr., General Hospital; Charles R. Drew Postgraduate School of Medicine, and University of Southern California School of Medicine, Los Angeles.

Submitted June 13, 1978.

Reprint requests to: Haragopal Thadepalli, MD, Chief, Div. of Infectious Diseases, Martin Luther King, Jr., General Hospital, 12021 S. Wilmington Ave., Los Angeles 90059.

INTRAVENOUS ABUSE OF DRUGS

about the bacteriology of such infections. Louria and Hensle<sup>4</sup> reported that in their series, Staphylococcus aureus was the most common pathogen. Anaerobic bacteria were rarely mentioned as causative agents of such infections; this may be because of inadequate culture techniques being employed. We have, therefore, studied skin or soft tissue infections in 21 drug addicts with careful anaerobic culture techniques.

**Patients and Methods**

Medical records of all drug abusers taking drugs parenterally admitted to Martin Luther King, Jr. General Hospital (Los Angeles, California) and seen by the Infectious Disease Service for consultation between July 1973 and July 1977 were reviewed. Included were all such drug abusers (taking heroin, methylphenidate hydrochloride [Ritalin], amphetamines or cocaine) who

had a skin or soft tissue infection, and in whom at least one culture was drawn and the infected site cultured for aerobes and anaerobes before antibiotic therapy. Both pus and subcutaneous tissue specimens were cultured in cases of necrotizing fasciitis and pyomyositis. They were also Gram stained before culture to check to see if all morphotypes of bacteria were recovered and identified.

*Bacteriology*

Blood cultures were inoculated at the bedside into trypticase soy broth (Baltimore Biological Laboratories [BBL], Cockeysville, MD) and thioglycolate media (BBL) and incubated at 37°C. Pus from the infected sites was obtained either by needle aspiration or surgical drainage and placed immediately in oxygen-free containers (Anaport bottles or Anaswab Tubes, Scott Laboratories,

TABLE 1.—Clinical Diagnosis and Culture Results in Skin and Soft Tissue Infections in 21 Drug Addicts

Patient No.	Anaerobic bacteria	Aerobic bacteria
<b>SUBCUTANEOUS ABSCESS</b>		
1	None	Serratia, Klebsiella, Enterobacter
2	Bacteroides	Group A Streptococcus
3	None	Serratia
4	Eubacterium* (pus also), Peptostreptococcus parvulus,* Propionibacterium acnes*	None
5	None	Staphylococcus aureus, Klebsiella, Enterobacter
6	Clostridium septicum, Bacteroides*	None
7	Clostridium perfringens	None
8	Clostridium perfringens	None
9	Veillonella	Staphylococcus aureus* (pus also), Alpha hemolytic Streptococcus, Neisseria
10	Bacteroides, Peptostreptococcus intermedius	Klebsiella
11	Clostridium septicum	None
12	None	Klebsiella
13	None	Group A Streptococcus
14	Actinomyces naeslundii, Bacteroides fragilis, Peptococcus variabilis, Peptostreptococcus intermedius	None
<b>PYOMYOSITIS</b>		
15	None	Staphylococcus aureus
16	Peptostreptococcus intermedius	Enterococcus
<b>NECROTIZING FASCIITIS</b>		
17	Bacteroides biacutus, Clostridium perfringens, Clostridium bifermentans, Peptostreptococcus species	Enterobacter
18	Peptococcus species	Proteus
<b>CELLULITIS</b>		
19	Peptococcus magnus	Citrobacter, Enterobacter
20	Fusobacterium	Escherichia coli, Staphylococcus aureus, Klebsiella
21	None	Group A Streptococcus* (pus also)

\*Positive blood cultures

Fiskeville, Rhode Island). The anaerobic cultures were processed as described in the *Anaerobe Laboratory Manual* of the Virginia Polytechnic Institute.<sup>5</sup> The aerobes were cultured in the conventional manner.

### Therapy

All patients were treated with clindamycin and gentamicin. Concomitant surgical drainages also were done in all instances. After two days if no anaerobes were isolated, administration of clindamycin was discontinued; gentamicin therapy was stopped if the cultures failed to show aerobic Gram-negative bacilli.

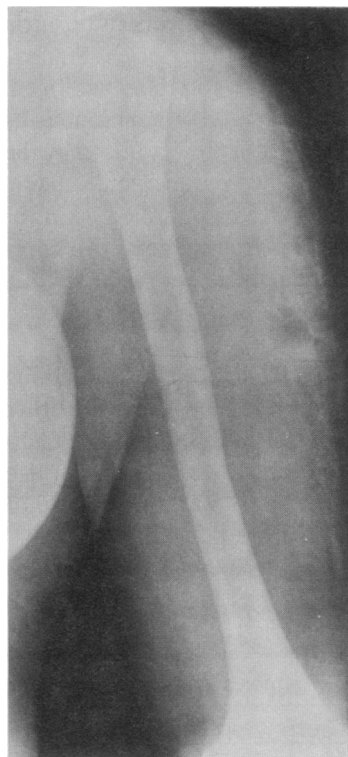
### Results

#### Types of Infection

Twenty-one patients met the criteria for inclusion into the study as shown in Table 1. Although all of them admitted to intravenous abuse of drugs, mainly of heroin, they denied "skin popping" or subcutaneous injection. All presented with skin or soft tissue infection serious enough to require admission to hospital. There were 11 women and 10 men. They were all febrile with temperatures greater than 38.3°C (101°F) and had leukocytosis. Fourteen patients had subcutaneous abscesses, three had cellulitis. Cellulitis is defined as inflammation of the skin which is tender but with no evidence of gangrene. Two patients had pyomyositis as evidenced by pus drained from the muscle substance, two patients had necrotizing fasciitis defined as rapidly spreading inflammation associated with gangrene of the skin or subcutaneous fascia (or both) but no evidence of gangrene of the muscle tissue. Soft tissue gas was shown by plain roentgenograms in three of them (cases 4, 15 and 16). In 15 of the patients foul-smelling pus was present.

#### Bacteriology

The culture results were as listed in Table 1. Four patients were in an extremely toxic condition as evidenced by body temperatures greater than 38.9°C (102°F), rapid thready pulse and sweating associated with leucocytosis and shift to the left and hypotension. Blood cultures were positive. In 14 patients there were anaerobic bacteria at the site of infection and, in fact, anaerobes were the only isolates in 6 patients. In the eight other patients anaerobes were found mixed with aerobic bacteria. In seven patients (33.3



**Figure 1.**—Note the gas bubbles in the subcutaneous tissue of the patient's arm in a case of subcutaneous abscess, due to intravenous abuse of drugs, caused by *Peptostreptococcus parvulus* and other bacteria (case 4, Table 1).

percent) isolates were exclusively aerobic bacteria. Excellent correlation was noted between the Gram stain of the pus and tissue smears and the results of final culture in all patients.

In all there were 48 bacterial isolates of which 24 were anaerobic and 24 aerobic. There were from one to five bacteria isolated from each patient (average 2.3). The most frequent anaerobic isolates were clostridia (including *Clostridium perfringens*), peptostreptococci and *Bacteroides* species (including one *B. fragilis*). In addition, there were three peptococci and one each of *Veillonella*, *Propionibacterium*, *Eubacterium*, *Fusobacterium* and *Actinomyces*. The aerobes were as listed in Table 1. Included are *Klebsiella* species (four cases), and *Enterobacter* species (four cases), *Staphylococcus aureus* (four) and group A beta hemolytic streptococci in three. The following case report is provided as an example. The therapeutic efficacy of clindamycin and gentamicin in some of these cases were reported before.<sup>6,7</sup> Briefly, the therapeutic responses were considered satisfactory in all instances after an average duration of five days of intravenous treatment with antibiotics. There were no failures, and no difference in outcome was noted between those who were infected with anaerobic bacteria and those infected with aerobic bacteria.

### Report of a Case

A 25-year-old woman, a heroin addict, was admitted because of chills and fever of two days duration associated with swelling of the upper part of the left arm. The woman (patient 4, Table 1) appeared to be in a toxic condition. Her temperature was 39.4°C (103°F). The upper left arm was notably swollen and erythematous, but no crepitations could be felt. The plain roentgenogram, however, showed soft tissue swelling and air bubbles (Figure 1). Blood cultures yielded *Peptostreptococcus parvulus*, *Eubacterium lentum* and *Propionibacterium acnes* (two separate sets). The laboratory values were within normal limits except that the leukocyte count was 15,900 per cu mm with a pronounced shift to the left. A deep incision was made from the lower lateral aspect of the upper arm to the shoulder, and a large volume of foul-smelling pus was drained. This pus on culture grew *Eubacterium lentum*. The patient was treated with clindamycin and gentamicin for seven days and recovery was uneventful.

### Discussion

Skin and soft tissue infections in heroin addicts are generally thought to be caused by *Staphylococcus aureus*.<sup>4,8</sup> Lerner and co-workers, for instance, found that all but one of the eight skin abscesses they cultured were caused by *S. aureus*.<sup>9</sup> Only one patient in their study had a *Bacteroides* infection of the neck. Necrotizing fasciitis and pyomyositis in drug addicts have been reported to be caused by both aerobic and anaerobic bacteria.<sup>10,11</sup>

Lewis and Gorbach,<sup>11</sup> utilizing proper anaerobic culture techniques, reported that these infections were associated with *Staphylococcus aureus*, streptococci and peptostreptococci and other anaerobes. As shown in our study, nearly two thirds of the heroin addicts' skin and soft tissue infections were caused by anaerobic bacteria. In fact, in six patients (28 percent) there were pure anaerobic infections.

Anaerobic infection of soft tissue may be suggested by radiological evidence of free air bubbles or air in the fascial planes and the characteristic foul smell produced by anaerobes. These signs are not always present in anaerobic infections; furthermore, they can be misleadingly present in exclusive aerobic infections as well. In our study only three patients had radiologically shown free air bubbles in the tissues; in several there was no

foul odor. Roentgenographic evidence of free air and foul odor when present strongly suggest anaerobic infection.

The Gram stain is a simple technique that can be extremely valuable in the diagnosis of anaerobic infections. The presence of multiple morphological types of bacteria in Gram stains of pus is characteristic of anaerobic infection. In contrast, most aerobic infections, such as those caused by *S. aureus* or *Pseudomonas* are of a singular morphotype showing either Gram-positive cocci or Gram-negative bacilli, as the case may be. The presence of both cocci and bacilli together in the same Gram-stained smear should suggest anaerobic infection or mixed aerobic-anaerobic infection. In our study excellent correlation was noted between Gram stains and final culture results; all morphotypes of bacteria seen on Gram stain were accounted for by culture results. The Gram stain features, soft tissue gas and foul smell, if all present together, make the diagnosis of anaerobic infection very likely. If careful anaerobic culture techniques are utilized in processing specimens taken from such patients, the diagnosis can be confirmed.

Most of the patients in our study were heroin addicts. Methylphenidate abuse as reported by Brooks and associates<sup>12</sup> was associated with soft tissue infections due to *Eikenella corrodens*, an aerobic Gram-negative rod resistant to clindamycin. They reported that anaerobic bacteria were infrequently associated with *E. corrodens* infections. Apparently abuse of different substances may predispose to different types of infections.

In contrast to findings in previous studies of skin and soft tissue infections in drug addicts the overall incidence of *S. aureus* in our study was only 19 percent; only four of 21 patients were infected with this organism. A recent study<sup>13</sup> of cutaneous abscesses in nonaddicts found *S. aureus* in only 24 percent. Anaerobes were frequently isolated from the remainder. The patients were all well enough to be treated as outpatients. These results were similar to ours, although our study involved only seriously ill patients who had been admitted to hospital. There was no correlation between a specific diagnostic category and the microbiologic findings in our study. However, precise understanding of the microbiology of severe skin and soft tissue lesions in drug addicts is of obvious importance to select optimum therapy. Although surgical drainage is imperative, concomitant antibiotic therapy is needed to allay

## INTRAVENOUS ABUSE OF DRUGS

systemic toxicity and hasten recovery. When features such as soft tissue gas or foul smell are present, or when the Gram stain of pus shows different morphotypes of bacteria, antibiotic therapy should be directed against anaerobic as well as aerobic bacteria until the culture results are available. Pus from all such lesions should be cultured using proper anaerobic techniques.

### REFERENCES

1. Cherubin CE: The medical sequelae of narcotic addiction. *Ann Intern Med* 67:23-33, 1967
2. Hussey HH, Katz S: Infections resulting from narcotic addiction, report of 102 cases. *Am J Med* 9:186-195, 1950
3. Vollum D: Skin lesions in drug addicts. *Br Med J* 2:647-650, 1970
4. Louria D, Hensle T: The major medical complications of heroin addiction. *Ann Intern Med* 67:1-22, 1967
5. Holdeman LV, Moore WEC (Eds): *Anaerobe Laboratory Manual*. Blacksburg, Virginia, Virginia Polytechnic Institute and State University, 1972
6. Gorbach SL, Thadepalli H: Isolation of *Clostridium* in human infections—Evaluation of 114 cases. *J Infect Dis* 131:581-585, 1975
7. Thadepalli H, Huang JT: Treatment of anaerobic infections—Carbencillin alone compared with clindamycin and gentamicin. *Curr Ther Res* 22:549-555, 1977
8. Geelhoed G, Joseph W: Surgical sequelae of drug abuse. *Surg Gynecol Obstet* 139:749-755, 1974
9. Lerner A, Oerther F: Characteristics and sequelae of paregoric abuse. *Ann Intern Med* 65:1019-1030, 1966
10. Finegold SM: Anaerobic bacteria in human disease. New York, Academic Press, 1977, chap 13
11. Lewis R, Gorbach S: New aspects of infectious disease—Complications in heroin addicts. Twelfth Interscience Conference on Antimicrob. Agents & Chemother. Atlantic City, New Jersey, 1972, p 92
12. Brooks GF, O'Donoghue JM, Peter J, et al: *Eikenella corrodens* a recently recognized pathogen. *Medicine* 53:325-342, 1974
13. Meislin HW, Lerner SA, Graves MH, et al: Cutaneous abscesses—Anaerobic and aerobic bacteriology and outpatient management. *Ann Intern Med* 87:145-149, 1977

## Overlooked Causes of an Ischemic Leg

ONE SOMETIMES OVERLOOKED cause of an ischemic leg is a diabetic person with a neuropathy who grinds a hole into the skin of his foot and infection develops, superimposed on that. He may have perfectly good pulses and perfectly good arterial supply. Infection develops superimposed on this kind of trauma and then ischemia and gangrene develop, indeed secondary to the infection. This is a variant and a peculiar one. This lends itself to radical debridement, just as one would a carbuncle. Sometimes, one does the radical debridement because the same type of necrotizing infection will occur in the presence of occluded arteries. And this is what one gets when one has occluded arteries—gets a necrotizing infection, clears it out in order to control the infection and then ischemia takes over.

—ANTHONY M. IMPARATO, MD, *New York City*  
Extracted from *Audio-Digest Surgery* Vol. 24, No. 17, in the Audio-Digest Foundation's subscription series of tape-recorded programs. For subscription information: 1577 East Chevy Chase Drive, Glendale, CA 91206