ANNALS OF SURGERY
Vol. 219, No. 5, 527-537

Intrahepatic Stones

The Transhepatic Team Approach

Henry A. Pitt, M.D.,* Anthony C. Venbrux, M.D.,† JoAnn Coleman, R.N.,* Carol A. Prescott, R.N.,† Matthew S. Johnson, M.D.,† Floyd A. Osterman, Jr., M.D.,† and John L. Cameron, M.D.*

From the Departments of Surgery and Radiology,† The Johns Hopkins Medical Institutions, Baltimore, Maryland*

Objective
The authors reviewed the combined interventional radiologic and surgical management of 54 patients with intrahepatic stones at the Johns Hopkins Hospital. The team approach used large-bore transhepatic stents to access the intrahepatic ducts until they were stone free.

Summary Background Data
Intrahepatic stones are uncommon in western countries. As a result, few American institutions have had much experience, and multiple management algorithms have been suggested. Nonoperative, operative, and combination surgical and nonoperative approaches have been advocated. At Johns Hopkins, combined surgical and percutaneous management has been used for 18 years.

Methods
This team approach includes (1) percutaneous placement of transhepatic access catheters, (2) surgery for underlying biliary disease and stone removal, and, when necessary (3) postoperative percutaneous choledochoscopy and stone removal through the transhepatic stents.

Results
The median age of the 54 patients was 50 years, and 32 were men. Biliary disease included 27 benign strictures, 7 sclerosing cholangitis, 5 choledochal cysts, 5 parasitic infections, 5 choledocholithiasis, and 5 biliary tumors. Fourteen patients (26%) were treated exclusively with percutaneous techniques. Forty patients (74%) had surgery, including 36 Roux-en-Y hepatico- or choledochojejunostomies with large-bore transhepatic stents. Eighteen of these 40 patients (45%) with multiple intrahepatic stones, strictures, or both required additional procedures after operation. No hospital deaths occurred after any of the percutaneous or surgical procedures. With a mean follow-up of 60 months, 94% of patients were stone free, 87% of patients were symptom free, and 73% have had their transhepatic stents removed.

Conclusions
A combined radiologic and surgical approach with transhepatic stents is a safe and effective method for managing intrahepatic stones.

Intrahepatic stones or hepatolithiasis is prevalent in Asia but uncommon in western countries, and thus most American institutions have little experience in treating this condition. Furthermore multiple treatment algorithms have been suggested and can be categorized as surgical, nonsurgical, or a combination of both surgical and nonoperative techniques. Surgical options include choledochotomy, sphincteroplasty, choledochoduode-

nostomy, choledocho- or hepaticojejunostomy with or without transhepatic stents or hepaticocutaneous jejunostomy, and liver resection. Nonsurgical alternatives include endoscopic or percutaneous transhepatic choledochoscopy with or without stents, electrohydraulic lithotripsy, or chemical dissolution; extracorporeal shock wave lithotripsy, and oral bile acid therapy.

In the past 18 years, 54 patients with intrahepatic stones have been treated at the Johns Hopkins Medical Institutions. A combined interventional radiologic and surgical regimen using transhepatic stents has evolved. This team approach includes (1) percutaneous placement of transhepatic access catheters, (2) surgery for underlying biliary disease and stone removal, and, when necessary (3) postoperative percutaneous choledochoscopy and residual stone removal through transhepatic stents. This combined radiologic and surgical transhepatic approach has been a safe and effective method to manage intrahepatic stones.

METHODS

Patients

From 1976 through 1993, 54 patients with intrahepatic stones were treated at the Johns Hopkins Medical Institutions. Patients included in this analysis had benign postoperative strictures (n = 27), sclerosing cholangitis (n = 7), choledochal cysts (n = 5), parasitic infections (n = 5), choledocholithiasis (n = 5), or biliary tumors (n = 5). The parasitic infections were caused by *Clonorchis sinensis*. The tumors included two cholangiocarcinomas, one hepatic cystadenoma, one ampullary adenoma, and one duodenal leiomyoma. The years of presentation are listed in Figure 1. From 1976 through 1988, an average of 1.7 patients per year were treated. Since 1989, an average of 6.4 patients have been treated per year.

Patient characteristics are presented in Table 1. Mean age for the 54 patients was 50 years, with a range of 21 to 75 years. Patients with choledochal cysts were the youngest, whereas those with biliary tumors were the oldest. Thirty-two of the patients (59%) were men, including all seven patients with sclerosing cholangitis. Forty-one patients (76%) were Caucasian. All of the patients with biliary parasites were originally from Korea. Five patients (9%) had established cirrhosis, whereas only one patient with sclerosing cholangitis also had ulcerative colitis.

Presented at the 105th Annual Scientific Session of the Southern Surgical Association, December 5–8, 1993.

Address reprint requests to Henry A. Pitt, M.D., Blalock 688, Johns Hopkins Hospital, 600 N. Wolfe Street, Baltimore, MD 21287-4688.

Accepted for publication January 12, 1994.

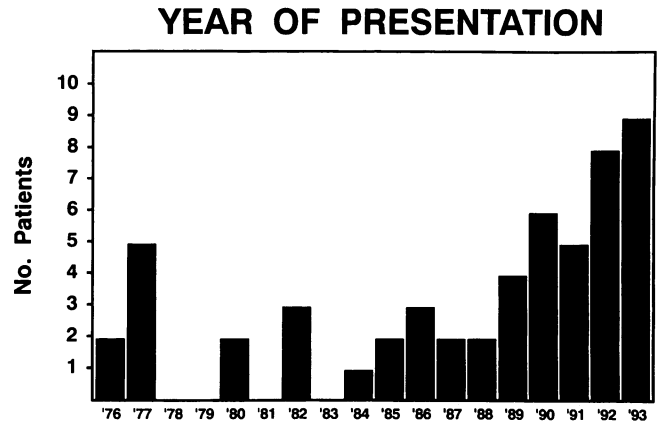

Figure 1. Year of presentation.

Forty-nine of the patients (91%) previously had one or more biliary tract (n = 69), abscess drainage (n = 4), gastric (n = 2), colonic (n = 2), hepatic (n = 1), or splenic (n = 1) operations. The most common biliary tract operations were hepatico- or choledochojejunostomy (n = 20), cholecystectomy (n = 19), choledochotomy (n = 12), and choledochoduodenostomy (n = 9).

Symptoms, Diagnoses, and Stone Locations

Symptoms of the 54 patients are displayed in Table 2. Cholangitis (67%), pain (63%), and jaundice (39%) were the most common. Diagnoses were usually established by cholangiography. Intrahepatic stones were usually identified before referral by endoscopic retrograde cholangiopancreatography (Fig. 2) in 23 patients (43%) or by T-tube cholangiography in 1. Percutaneous transhepatic cholangiography confirmed or established the diagnosis in 42 patients (78%). The presence and location of stones was also frequently accessed by ultrasound or computed tomographic scans. Stone locations are listed in Table 3. Thirty patients (55%) had stones in both the right and left intrahepatic ducts. Sixteen patients (30%) had only left-sided stones, whereas eight patients (15%) had only right-sided stones.

Initial Percutaneous Procedures

Fourteen of the 54 patients (26%) were treated exclusively with percutaneous techniques. In 10 of these 14 patients (71%), initial percutaneous transhepatic drainage was performed at Johns Hopkins. In addition, since 1984 percutaneous transhepatic drainage has been performed routinely before surgery when the intrahepatic ducts must be accessed. As a result, 22 of the 40 patients (55%) treated surgically at Johns Hopkins had percutaneous transhepatic drainage before surgery. Thus 32 of

Table 1. PATIENT CHARACTERISTICS

	Benign Strictures (n = 27)	Sclerosing Cholangitis (n = 7)	Choledochal Cysts (n = 5)	Biliary Parasites (n = 5)	Choledocholithiasis (n = 5)	Biliary Tumors (n = 5)	Total (n = 54)
Age (yr)							
Mean	49	52	34	47	58	62	50
Range	21–75	37–64	25–45	43–49	42–72	45–73	21–75
Gender							
Male	13	7	2	3	4	3	32
Female	14	0	3	2	1	2	22
Race							
White	23	5	4	0	5	4	41
Black	4	1	0	0	0	1	6
Korean	0	0	0	5	0	0	5
Asian	0	1	1	0	0	0	2
Associated conditions							
Cirrhosis	3	1	1	0	0	0	5
IBD	0	1	0	0	0	0	1
Prior surgery							
None	0	1	0	1	1	2	5
1	13	5	1	3	4	2	28
2	10	0	2	1	0	1	14
3	2	1	1	0	0	0	4
4	1	0	1	0	0	0	2
>5	1	0	0	0	0	0	1

IBD = inflammatory bowel disease.

the 54 patients (59%) had percutaneous transhepatic drainage (Table 4). These procedures were performed using standard techniques as previously described.[1-3]

The 14 patients who were treated only with percutaneous techniques usually had upsizing of their percutaneous catheter(s) to at least 16F during an initial hospital admission. Then they returned for further procedures 5 or 6 weeks later, when the tube tract would be mature. During the early years of this analysis, most of the stone removal procedures were done using fluoroscopic guidance. More recently, a combination of fluoroscopy and percutaneous choledochoscopy has been used.[1-3]

The 14 patients treated only with percutaneous techniques had a total of 21 stone removal procedures (Table 4). Twelve of these 14 patients (86%) had 21 choledochoscopies to aid in stone removal or to survey or biopsy the ducts before stent removal. In addition, 12 of the 14 patients (86%) had 18 balloon dilatations for intrahepatic ductal strictures. In general, patients requiring balloon dilatation had stents left in place for 12 months before removal was considered. However, in patients with sclerosing cholangitis, the policy has been to leave the stents in place indefinitely. Only 1 of these 14 patients required electrohydraulic lithotripsy for dislodgement and fragmentation of a large impacted stone. In all patients with stents, elective change was done routinely at approximately 3-month intervals.

Surgical Procedures

Forty of the 54 patients (74%) had surgical procedures at Johns Hopkins (Table 5). Thirty-seven of these 40 pa-

Table 2. PRESENTING SYMPTOMS

	Benign Strictures (n = 27)	Sclerosing Cholangitis (n = 7)	Choledochal Cysts (n = 5)	Biliary Parasites (n = 5)	Choledocholithiasis (n = 5)	Biliary Tumors (n = 5)	Total (n = 54)
Cholangitis	17	7	4	4	1	3	36
Pain	17	2	3	4	3	5	34
Jaundice	12	3	2	1	1	2	21
Pruritis	2	1	0	0	0	0	3

Figure 2. A: Endoscopic retrograde cholangiogram shows a stricture of the right hepatic duct caused by a cholangiocarcinoma with intrahepatic stones. B: Percutaneous tube cholangiogram after drainage and stone retrieval. Note the residual stones on the right that were asymptomatic and not addressed because of multiple liver metastases.

tients (93%) had a Roux-en-Y hepaticojejunostomy (33), a choledochojejunostomy (3), or an intrahepatic cholangiojejunostomy (1). Twenty-two of these 37 procedures (59%) were primary, whereas 15 (41%) were revisions of anastomoses performed before referral. These 37 patients had a total of 56 large-bore transhepatic stents placed during operation by techniques that have been previously described.[4-8] During surgery, an aggressive effort was undertaken to clear the intrahepatic ducts of stones with the aid of flexible or rigid choledochoscopy. Hepatic resection was reserved for segments with established cirrhosis and chronic sepsis. As a result, only one patient (3%) had resection of segments II and III.

Postoperative Percutaneous Procedures

Eighteen of the 40 patients (45%) having surgery at Johns Hopkins required further percutaneous procedures after operation to clear their intrahepatic ducts of stones or to manage persistent intrahepatic strictures (Table 6). Of these 18 patients, 15 (83%) had an additional 45 stone removal procedures, 11 (61%) had 26 percutaneous choledochoscopies, and 6 (33%) had 14 balloon dilatations. Two of these patients also required electrohydraulic lithotripsy to fragment large intrahepatic stones. These 18 patients tended to have the most stones and strictures and often required long-term stenting. Nevertheless, complete stone removal without symptoms and with eventual removal of the transhepatic stents was possible in most of these patients (Fig. 3).

Follow-up

Complete follow-up data were obtained in the 54 patients through personal contact with living patients or review of medical records for those who were dead. Postoperative and postprocedural complications were documented by review of hospital and interventional radiology records. Outcome of treatment was only assessed in the 43 patients who had been followed for a minimum of 12 months or had died within this period. Thus for the results of treatment to be considered successful, patients had to (1) be followed for a minimum of 12 months, (2) have no recurrent stones, and (3) have not died from progressive liver failure, sepsis, or both. The need for further treatment of intrahepatic strictures in the absence of stones was not considered to be a failure.

Table 3. STONE LOCATION

	Benign Strictures (n = 27)	Sclerosing Cholangitis (n = 7)	Choledochal Cysts (n = 5)	Biliary Parasites (n = 5)	Choledocholithiasis (n = 5)	Biliary Tumors (n = 5)	Total (n = 54)
Left and right	15	4	3	1	3	4	30
Left only	8	2	1	3	2	0	16
Right only	4	1	1	1	0	1	8

Table 4. INITIAL PERCUTANEOUS PROCEDURES

	Benign Strictures (n = 27)	Sclerosing Cholangitis (n = 7)	Choledochal Cysts (n = 5)	Biliary Parasites (n = 5)	Choledocholithiasis (n = 5)	Biliary Tumors (n = 5)	Total (n = 54)
PCT*	24 (29)	5 (5)	3 (3)	5 (5)	1 (1)	4 (4)	42 (46)
PTD†	14 (16)	5 (5)	3 (3)	5 (5)	1 (1)	4 (4)	32 (34)
Stone Removal	5 (6)	3 (3)	1 (2)	2 (2)	2 (6)	1 (2)	14 (21)
Choledochoscopy	4 (5)	2 (3)	1 (1)	2 (3)	2 (7)	1 (2)	12 (21)
Balloon Dilatation	5 (10)	2 (2)	1 (1)	2 (2)	0 (0)	2 (3)	12 (18)

* PTC = percutaneous transhepatic cholangiography; †PTD = percutaneous transhepatic drainage.
Numbers in parentheses are procedures.

RESULTS

Procedural Morbidity

A summary of the procedures performed is presented in Figure 4. Fourteen patients (26%) were treated using only percutaneous techniques. Forty patients (74%) had surgery and 18 patients (33%) had postoperative percutaneous procedures. In addition to the percutaneous procedures outlined in Table 4, the 14 patients treated only by percutaneous techniques had 78 tube cholangiogram and change procedures. Similarly, beyond the procedures outlined in Table 6, the 40 patients having surgery had a total of 234 tube cholangiogram and change procedures. Mild cholangitis was a frequent occurrence, but severe sepsis requiring prolonged hospitalization occurred in only two patients after percutaneous procedures. One patient who had percutaneous transhepatic drainage the day before surgery developed severe pancreatitis that was evolving during surgery and subsequently required debridement. In addition, two patients with sclerosing cholangitis who have long-term stents have had liver abscesses that required percutaneous drainage. None of the patients had hemobilia requiring transfusion or embolization, and no patient died as the result of any of the percutaneous procedures.

No 30-day or hospital deaths occurred in the 40 patients who had surgery. Fourteen of these 40 patients (35%) had postoperative complications. Postoperative bacteremia due to cholangitis occurred in three patients (8%). Three patients (8%) had wound infections, and three (8%) developed bile fistulas that subsequently closed spontaneously. Postoperative pancreatitis developed in two patients (5%), including the one mentioned above, which probably resulted from preoperative tube placement. One patient who had takedown of a choledochoduodenostomy bled after operation from the gastroduodenal artery and required emergency re-exploration. One patient had a postoperative gastrointestinal hemorrhage that required transfusion.

Late Follow-up

The eventual outcome of treatment is presented in Table 7. The overall mean and median lengths of follow-up

Table 5. OPERATIVE PROCEDURES

	Benign Strictures (n = 27)	Sclerosing Cholangitis (n = 7)	Choledochal Cysts (n = 5)	Biliary Parasites (n = 5)	Choledocholithiasis (n = 5)	Biliary Tumors (n = 5)	Total (n = 54)
Hepaticojejunostomy							
Primary	9	4	3	2	0	1	19
Secondary	11	0	1	2*	0	0	14
Choledochojejunostomy							
Primary	1	0	0	0	0	1	2
Secondary	0	0	0	0	1	0	1
Choledochotomy	0	0	0	0	1†	1	2
Cholangiojejunostomy	1	0	0	0	0	0	1
Choledochoduodenostomy	0	0	0	0	1	0	1

* One includes resection of hepatic segments II and III; †includes local resection of ampullary tumor.

Table 6. POSTOPERATIVE PERCUTANEOUS PROCEDURES

	Benign Strictures (n = 27)	Sclerosing Cholangitis (n = 7)	Choledochal Cysts (n = 5)	Biliary Parasites (n = 5)	Choledocholithiasis (n = 5)	Biliary Tumors (n = 5)	Total (n = 54)
Stone Removal	6 (25)	3 (11)	2 (4)	2 (3)	2 (2)	0 (0)	15 (45)
Choledochoscopy	2 (9)	2 (6)	2 (4)	2 (3)	2 (3)	1 (1)	11 (26)
Balloon Dilatation	3 (7)	3 (7)	0 (0)	0 (0)	0 (0)	0 (0)	6 (14)

Numbers in parentheses are procedures.

were 60 and 36 months, respectively. Forty-seven of the 54 patients (87%) are alive. Five of the 27 patients (19%) with benign postoperative strictures died. These five patients were among the nine initially treated between 1976 and 1980. These five patients died a mean of 64 months (range, 9 to 120 months) after the initiation of therapy. The cause of death was liver failure, sepsis, or both. Of the 45 patients treated since 1980, only 2 (4%)

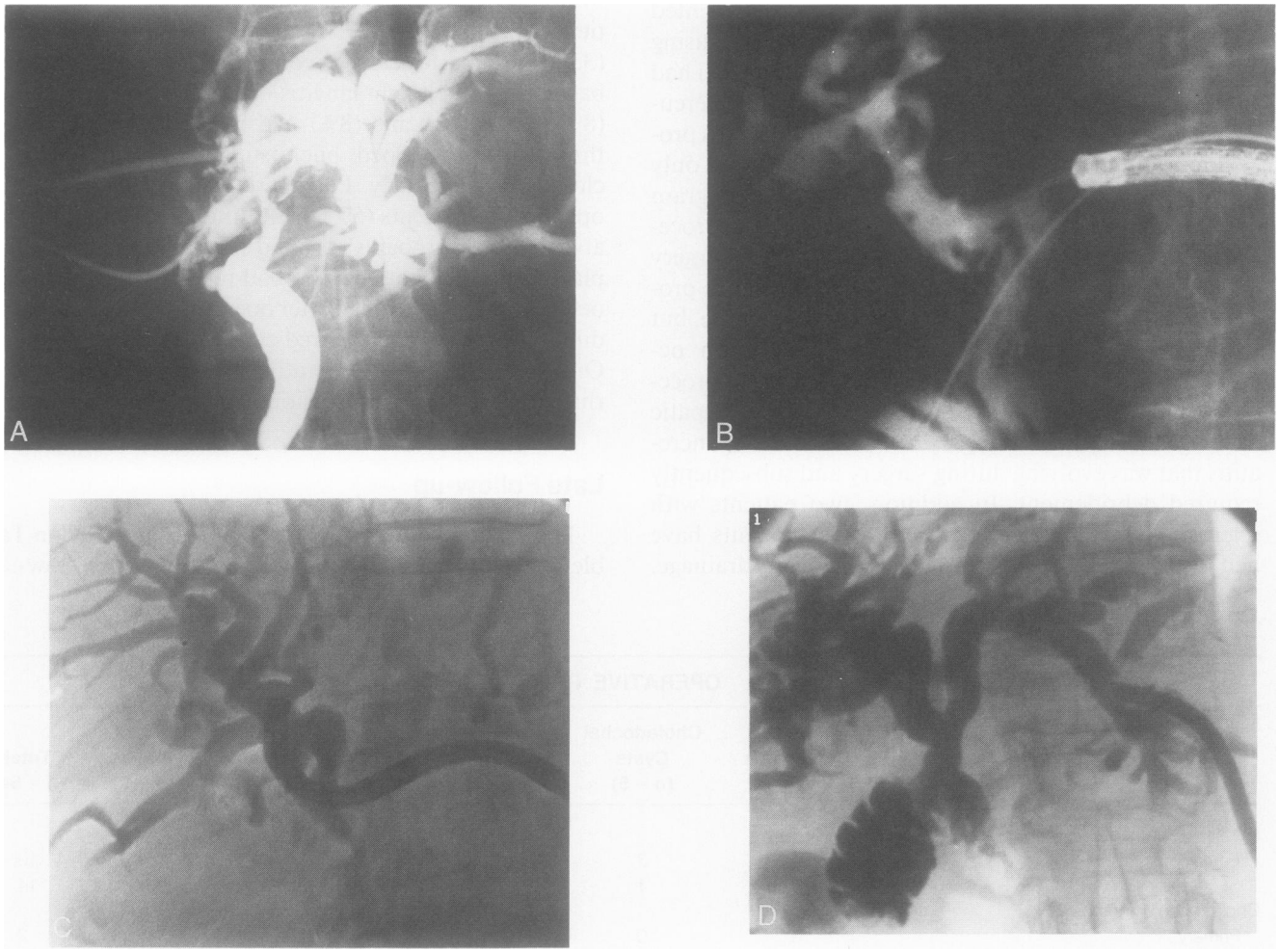

Figure 3. A: Percutaneous tube cholangiogram shows a stricture of the common hepatic duct with multiple right intrahepatic stones after cholecystectomy. B: Cholangiogram during percutaneous choledochoscopy 3 months after choledochojejunostomy shows residual stones on the right. C: Cholangiogram during percutaneous choledochoscopy 9 months after surgery shows clearance of the right biliary system. D: Cholangiogram through left transhepatic stent tract 14 months after surgery shows no residual stones and a patent anastomosis. The transhepatic stent was removed at that time.

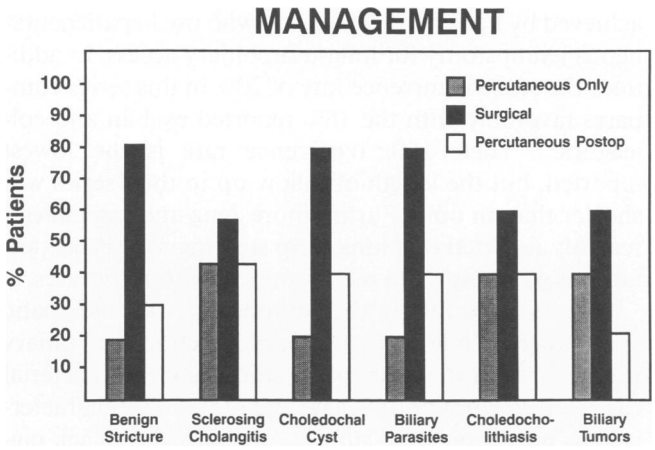

Figure 4. Percentage of patients treated only percutaneously (26% overall), surgically (74% overall), and by postoperative percutaneous techniques (33% overall).

have died. Both of these patients had unresectable cholangiocarcinomas and died 12 and 9 months, respectively, after initiation of treatment.

Three of the seven patients who died were not free of stones at their deaths 16, 9, and 9 months, respectively, after treatment began. However, complete stone clearance was achieved in the remaining 51 patients (94%). Furthermore the 47 surviving patients are free of symptoms of cholangitis, pain, and jaundice (Table 7). However, recurrent stones developed in 11 patients (20%) and 10 patients (19%) have been treated for recurrent strictures. Only one of these patients with recurrent problems required reoperation for revision of a hepaticojejunostomy after 8 years. The remaining patients have been treated percutaneously, usually through existing transhepatic stents. If the 7 patients with sclerosing cholangitis and the 2 who died at 9 months are excluded, 33 of the remaining 45 patients (73%) have had stent removal.

Overall 31 of the 43 evaluable patients (72%) had a successful outcome (Fig. 5). Long-term outcome was successful in only 15 of the 23 evaluable patients (65%) with postoperative strictures. Three of these patients died of later liver failure, sepsis, or both, whereas recurrent stones developed in five. Three of the seven patients with sclerosing cholangitis also developed recurrent stones, and one of four evaluable patients with choledochal cyst disease, hepatic fibrosis, and recurrent stones eventually required liver transplant. The remaining nine evaluable patients with biliary cysts, choledocholithiasis, or biliary tumors had successful outcomes.

DISCUSSION

Intrahepatic stones or hepatolithiasis is endemic in East Asia.[9] In the United States, this phenomenon is rare and the reported experience is small.[10–12] Furthermore, in the largest of these American series,[10] many of the patients had emigrated from East Asia. However, intrahepatic stones are associated with common problems such as benign postoperative strictures, sclerosing cholangitis, and biliary tract tumors. Thus at Johns Hopkins 54 patients with intrahepatic stones were treated during an 18-year period. Only seven of these patients were from Asia, and only five Korean patients had biliary parasites.

At Johns Hopkins a combined interventional radiology and surgical approach has been used. This team approach uses transhepatic catheters to access the intrahepatic ducts and, when necessary, stenting of intrahepatic strictures. In a collaborative effort, percutaneous transhepatic catheters are placed initially. In approximately one fourth of the patients, stone removal with the aid of choledochoscopy and fluoroscopy is achieved without surgery. In the remaining patients, surgery is used to treat biliary disease, for stone removal, and for placement of large-bore transhepatic stents. In patients with a huge stone burden or multiple intrahepatic strictures, postoperative percutaneous choledochoscopy, balloon dilatation, electrohydraulic lithotripsy, and long-term stenting are used as necessary. With this team approach and a mean follow-up of 60 months, 94% of patients were

Table 7. OUTCOME

	Benign Strictures (n = 27)	Cholangitis (n = 7)	Choledochal Cysts (n = 5)	Biliary Parasites (n = 5)	Choledocholithiasis (n = 5)	Biliary Tumors (n = 5)	Total (n = 54)
Follow-up (mo)							
Mean	78	71	52	37	24	11	60
Median	66	39	40	27	24	9	36
Alive	22	7	5	5	5	3	47
Stone Free	25	7	5	5	5	4	51
Symptoms Free	20	7	5	5	5	5	47
Recurrent Stones	7	3	1	0	0	0	11
Recurrent Strictures	6	3	1	0	0	0	10

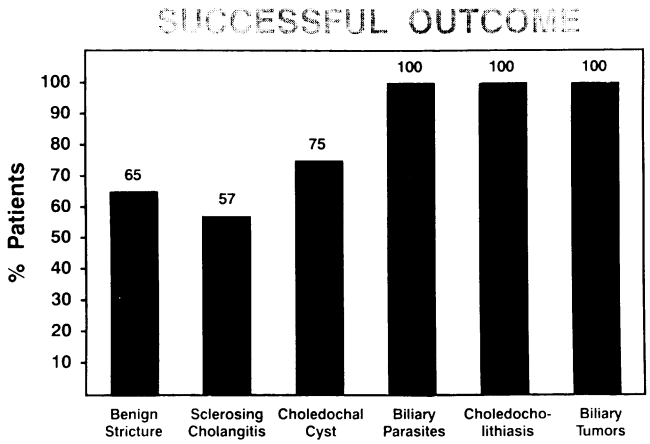

Figure 5. Percentage of patients who had successful outcomes by underlying disease.

stone free, 87% were symptom free, and 73% have had their transhepatic stents removed.

This combined effort is similar to the approach described in recent years by several groups from East Asia with much larger experiences with intrahepatic stones.[13-21] Postoperative flexible choledochoscopy used to manage hepatolithiasis has been reported by several authors.[13-16] The 94% stone clearance rate in this report compares favorably with the 90% rate reported by Fan and associates[13] and the 89% rate documented by Yamakawa.[15] Jeng and colleagues[16,17] also used balloon dilatation in these patients. However they have had more problems with hemobilia than were observed in our series. Several groups have also used electrohydraulic[13,18-20] or extracorporeal shock wave[21] lithotripsy. In our series, however, electrohydraulic lithotripsy was only needed in three patients.

The type of surgery needed to remove intrahepatic stones should be individualized. Historically, many of these patients were treated with a choledochotomy with or without a sphincteroplasty or choledochoduodenostomy.[22-24] However, the need for long-term access to the intrahepatic ducts has been appreciated in recent years. Some groups have advocated hepaticocutaneous jejunostomy for this purpose.[25-27] Furthermore segmental hepatic resection has been used in many patients by some groups.[24,28,29] In comparison, hepatic resection was used very infrequently in our series, perhaps because of differences in underlying disease and somewhat earlier presentation without cirrhosis and chronic sepsis.

As with hepaticocutaneous jejunostomy, hepaticojejunostomy and transhepatic stents provide long-term access to the intrahepatic ducts. The overall success rate of 72% in our series compares with the 71% rate reported by Sato and coworkers[23] and to the 72% rate reported by Koga and associates.[24] As noted above, the stone clearance rate in our series (94%) was also the same as achieved by Fan and colleagues,[27] who use hepaticocutaneous jejunostomy for long-term biliary access. In addition, the stone recurrence rate of 20% in this series compares favorably with the 16% reported by Fan and colleagues.[27] Their 16% recurrence rate is the lowest reported, but the length of follow-up in their series was shorter than in ours. Furthermore Jeng and associates[30] recently reported that long-term stenting may be advantageous with respect to recurrent stones and strictures.

Factors important in the pathogenesis of intrahepatic stones include bile stasis, bacterial infection, and biliary mucin.[31,32] Most intrahepatic stones contain bacterial casts and calcium bilirubinate and are usually characterized as brown pigment stones. As opposed to black pigment stones, which have only 1% to 2% cholesterol by weight, brown pigment stones contain 13% cholesterol by weight.[33] In addition, in recent years an increased incidence of cholesterol stones was reported in patients with hepatolithiasis.[31] Furthermore successful ursodeoxycholic acid treatment of primary hepatolithiasis in Caroli's syndrome was recently reported.[34] In that report, stones dissolved, symptoms improved, and liver function tests returned to normal. Thus ursodeoxycholic acid should be considered as an adjuvant to percutaneous and surgical treatment for hepatolithiasis in the future.

In East Asia, the association between cholangiocarcinoma and hepatolithiasis is well recognized. In one report from China of 20 patients with peripheral intrahepatic cholangiocarcinomas, 16 patients (80%) had associated intrahepatic stones.[35] In comparison, the late development of cholangiocarcinoma after treatment for hepatolithiasis is less well documented. In a report by Sheen-Chen and coworkers[36] from Taiwan, five cases of intrahepatic cholangiocarcinoma were found among 101 patients with hepatolithiasis. Similarly, Chijiiwa and associates[37] reported eight cases in Japan of cholangiocarcinoma developing in 109 patients with intrahepatic stones. The mean interval from stone treatment to development of cholangiocarcinoma was 8 years. In our series, cholangiocarcinoma caused hepatolithiasis in two patients, but bile duct malignancy has not developed in any of the remaining 52 patients. Again differences in underlying disease and time of initial presentation may explain the low incidence of late cholangiocarcinoma in our series.

The approach taken in our series to manage intrahepatic stones differs from those used in East Asia because large-bore transhepatic stents were used for long-term access to the intrahepatic ducts. In addition, most patients had benign postoperative strictures or sclerosing cholangitis and were managed surgically with a Roux-en-Y hepaticojejunostomy. Fewer patients required hepatic resection, relatively more balloon dilatations were performed, and electrohydraulic lithotripsy was used

sparingly. With the aid of intra- and postoperative flexible choledochoscopy, stone clearance was achieved in 94% of patients and 87% were symptom free. An overall successful outcome was achieved in 72% of patients, with a mean follow-up of 5 years. Furthermore, transhepatic stents could be removed in 73% of eligible patients. A combined radiologic and surgical transhepatic approach is a safe and effective method to manage hepatolithiasis.

Acknowledgments

The authors thank George Tudder for assistance with data management and Lori Davenport for preparing the manuscript.

References

1. Venbrux AC, Robbins, KV, Savader SJ, et al. Endoscopy as an adjuvant to biliary radiologic intervention. Radiology 1991; 180: 355–361.
2. Venbrux AC, Savader SJ, Osterman FA Jr. Percutaneous choledochoscopy. Lippincott's Reviews: Radiology. 1992; 1:156–179.
3. Venbrux AC. Interventional radiology in the biliary tract. Current Opinion in Radiology 1992; 4:83–92.
4. Lillemoe KD, Pitt HA, Cameron JL. Current management of benign bile duct strictures. In Cameron JL, ed. Advances in Surgery. Vol. 25. Chicago: Mosby Year Book, 1992, pp. 119–174.
5. Pitt HA, Kaufman SL, Coleman J, White RI, Cameron JL. Benign postoperative biliary strictures: operate or dilate? Ann Surg 1989; 210:417–427.
6. Pitt HA. Biliary cysts: choledochal cysts and Caroli's disease. *In* Cameron JL, ed. Current Surgical Therapy. 4th ed. St. Louis: Mosby Year Book, 1992, pp. 367–372.
7. Ahrendt SA, Pitt HA. Cholangiocarcinoma. *In* Niederhuber JE, ed. Current Therapy in Oncology. St. Louis: Mosby Year Book, 1993, pp. :410–414.
8. Cameron JL, Pitt HA, Zinner MJ, Kaufman SL, Coleman J. The management of proximal cholangiocarcinomas by surgical resection and radiotherapy. Am J Surg 1990; 159:91–98.
9. Nakayama F. Hepatolithiasis: an update. J Gastroenterol Hepatol 1988; 3:279–285.
10. Carmona RH, Crass RA, Lim RC Jr, Trunkey DD. Oriental cholangitis. Am J Surg, 1984; 148:117–124.
11. Pridgen JE Jr, Aust JB, McInnis WD. Primary intrahepatic gallstones. Arch Surg 1977; 112:1037–1043.
12. Adson MA, Nagorney DM. Hepatic resection for intrahepatic ductal stones. Arch Surg 1982; 117:611–616.
13. Fan ST, Choi TK, Lo CM, et al. Treatment of hepatolithiasis: improvement of result by a systematic approach. Surgery 1991; 109: 474–480.
14. Choi TK, Fok M, Lee MJR, Lui R, Wong J. Postoperative flexible choledochoscopy for residual primary intrahepatic stones. Ann Surg 1986; 203:260–265.
15. Yamakawa T. Percutaneous cholangioscopy for management of retained biliary tract stones and intrahepatic stones. Endoscopy 1989; 21:333–337.
16. Jeng KS, Chiang HJ, Shih SC. Limitations of percutaneous transhepatic cholangioscopy in the removal of complicated biliary calculi. World J Surg 1989; 13:603–610.
17. Jeng KS, Yang FS, Ohta I, Chiang HJ. Dilatation of intrahepatic biliary strictures in patients with hepatolithiasis. World J Surg 1990; 14:587–593.
18. Bonnel DH, Liguory CE, Cornud FE, Lefebvre JFP. Common bile duct and intrahepatic stones: results of transhepatic electrohydraulic lithotripsy in 50 patients. Radiology 1991; 180:345–348.
19. Chen MF, Jan YY. Percutaneous transhepatic cholangioscopic lithotripsy. Br J Surg 1990; 77:530–532.
20. Yoshimoto H, Ikeda S, Tanaka M, Matsumoto S, Kuroda Y. Choledochoscopic electrohydraulic lithotripsy and lithotomy for stones in the common bile duct, intrahepatic ducts, and gallbladder. Ann Surg 1989; 210:576–582.
21. Ker CG, Hwang CH, Chen JS, Lee KT, Sheen PC. Extracorporeal shockwave lithotripsy for treatment of intrahepatic stones: in vitro and in vivo studies. Hepatogastroenterology 1993;40:159–162.
22. Chen HH, Zhang WH, Wang SS, Caruana JA. Twenty-two year experience with the diagnosis and treatment of intrahepatic calculi. Surg Gynecol Obstet 1984; 159:519–524.
23. Sato T, Suzuki N, Takahashi W, Uematsu I. Surgical management of intrahepatic gallstones. Ann Surg 1980; 192:28–32.
24. Koga A, Miyazaki K, Ichimiya H, Nakayama F. Choice of treatment for hepatolithiasis based on pathological findings. World J Surg 1984; 8:36–40.
25. Fang K, Chou TC. Subcutaneous blind loop—a new type of hepaticocholedochojejunostomy for bilateral intrahepatic calculi. Chin Med J 1977; 3:413–418.
26. Hutson DG, Russell E, Schiff E, et al. Balloon dilatation of biliary strictures through a choledochojejuno-cutaneous fistula. Ann Surg 1984; 199:637–647.
27. Fan ST, Mok F, Zheng SS, et al. Appraisal of hepaticocutaneous jejunostomy in the management of hepatolithiasis. Am J Surg 1993; 165:332–335.
28. Choi TK, Wong J. Partial hepatectomy for intrahepatic stones. World J Surg 1986; 10:281–286.
29. Fan ST, Lai ECS, Wong J. Hepatic resection for hepatolithiasis. Arch Surg 1993; 128:1070–1074.
30. Jeng KS, Yang FS, Chiang HJ, Ohta I. Bile duct stents in the management of hepatolithiasis with long-segment intrahepatic biliary strictures. Br J Surg 1992; 79:663–666.
31. Ohta T, Nagakawa T, Takeda T, et al. Histological evaluation of the intrahepatic biliary tree in intrahepatic cholesterol stones, including immunohistochemical staining against apolipoprotein A-1. Hepatology 1993; 17:531–537.
32. Saito K, Nakanuma Y. Lactoferrin and lysozyme in the intrahepatic bile duct of normal livers and hepatolithiasis. an immunohistochemical study. Hepatology 1992; 15:147–153.
33. Kaufman HS, Magnuson TH, Lillemoe KD, Frasca P, Pitt HA. The role of bacteria in gallbladder and common duct stone formation. Ann Surg 1989; 209:584–592.
34. Ros E, Navarro S, Bru C, et al. Ursodeoxycholic acid treatment of primary hepatolithiasis in Caroli's syndrome. Lancet 1993; 342: 404–406.
35. Chen MF, Jan YY, Wang CS, Jeng LB, Hwang TL. Clinical experience in 20 hepatic resections for peripheral cholangiocarcinoma. Cancer 1989; 64:2226–2232.
36. Sheen-Chen SM, Chou FF, Eng HL. Intrahepatic cholangiocarcinoma in hepatolithiasis: a frequently overlooked disease. J Surg Oncol 1991; 47:131–135.
37. Chijiiwa K, Ichimiya H, Kuroki S, Koga A, Nakayama F. Late development of cholangiocarcinoma after the treatment of hepatolithiasis. Surg Gynecol Obstet 1993; 177:279–282.

Discussion

DR. THOMAS R. GADACZ (Augusta, Georgia): It's a very remarkable series by Dr. Pitt. The approach to bile duct stones requires a multi-disciplinary approach, not only of a surgeon and radiologist but also the endoscopist and, possibly, the