

# Nonoperative Management of Solid Organ Injuries in Children

## Is it Safe?

J. Alex Haller, Jr., M.D., Pat Papa, R.N., George Drugas, M.D., and Paul Colombani, M.D.

*From the Department of Pediatric Surgery, The Johns Hopkins Hospital, and Emergency Medical Services for Children, Baltimore, Maryland*

---

### Objective

The authors reviewed their experience with life-threatening blunt injuries in approximately 2900 children (0-14 years) admitted to the designated state pediatric shock trauma unit between 1990 and 1993.

### Methods

During this time, the authors treated all severely injured children with a prospective, nonoperative protocol if they were hemodynamically stable after less than 40 mL/kg fluid replacement, had proven evidence of solid organ injuries and remained stable in the pediatric intensive care unit under surgical management.

### Results

Twenty-eight children had computed tomography (CT) or operatively proven lacerations of the spleen, 25 had lacerations of the liver, 18 had lacerations of the kidney, 7 had lacerations of the pancreas, and 11 had two or more solid organ injuries. Three of the 28 children with injured spleens required laparotomy (two splenectomy, one splenorrhaphy). Two of the 25 children with liver injuries required laparotomy (one suturing, one partial resection). One of the 18 children with kidney injuries required laparotomy (nephrectomy), and 3 of the 7 children with pancreas injuries required laparotomy (two resection, one pseudocyst). There were three deaths after laparotomy (two head, one chest/abdominal). There were no deaths in the children managed nonoperatively, and there were no immediate or long-range complications.

### Conclusions

Comparison of the authors' data with the National Pediatric Trauma Registry shows similar results. The authors believe that nonoperative management of solid organ injuries under careful surgical observation in a pediatric intensive care unit is safe and appropriate.

---

After the remarkable report of their nonoperative management of children with ruptured spleens by pediatric surgeons at The Hospital for Sick Children in To-

ronto in 1978,<sup>1</sup> the risks associated with this unorthodox mode of treatment have been much discussed, often with considerable fervor.<sup>2-5</sup> This Canadian approach was a giant step in the evolution from another important conclusion made a decade earlier. At that time, surgeons realized that they should not remove a ruptured spleen, if it could be salvaged, because of the well-documented

---

Address reprint requests to J. Alex Haller, Jr., M.D., Room 7-113, CMSC, The Johns Hopkins Hospital, Baltimore, MD 21287-3716.  
Accepted for publication January 1, 1994.

danger of overwhelming infection in infants and young children who had undergone splenectomy.<sup>6-9</sup> This rare complication of overwhelming postsplenectomy infection (OPSI) alerted surgeons and pediatricians to the critically important role of the spleen in the immunologic system of young children. Thus, an extension of this "save our spleens (SOS)" concept to include avoiding unnecessary laparotomy was alluring; however, what were the risks of persistent life threatening hemorrhage, of delayed rupture of injured spleens, and of eventual splenic abscesses?<sup>10,11</sup> Thoughtful protocols have since evolved that define the parameters of "safe," nonoperative treatment of children with ruptured spleens,<sup>12</sup> but what are the additional risks of trauma to other abdominal organs that may further endanger the victims of blunt abdominal trauma?<sup>13</sup>


To address these major concerns in nonoperative management of blunt abdominal trauma in children, we developed a prospective protocol that ensures that these injured children are treated by a surgical team that carefully selects patients who fulfill the following criteria:

1. Hemodynamic stability after replacement of no more than 40% blood volume loss with crystalloid solution (Ringers' lactate or normal saline)
2. Documentation of the extent of solid organ injuries by a CT scan;<sup>8,14-16</sup>
3. Admission to a pediatric intensive care unit under continued observation and management by a trauma team that includes a trauma surgeon and a staff member of the pediatric intensive care unit;
4. Urgent exploratory laparotomy if, at any time, the child deteriorates, becomes hemodynamically unstable, and requires blood transfusion, (preserving the spleen if at all possible).<sup>13</sup>

We have completed a 3-year prospective study using these stringent criteria for the nonoperative management of children with blunt abdominal injuries. These results constitute the basis for our report.

From July 1, 1990, to April 1, 1993, (33 months) 2887 children from 1 day through 14 years of age were admitted to the designated Maryland State Pediatric Shock Trauma Unit in the Johns Hopkins Children's Center. Seventy-eight patients (2.7% of all trauma admissions) had life-threatening blunt abdominal trauma and were treated by the aforementioned protocol for nonoperative treatment in our emergency room and pediatric intensive care unit, under pediatric surgical supervision (Fig. 1).<sup>17</sup>

Twenty-eight children had CT or laparotomy proven lacerations of the spleen, 25 had lacerations of the liver, 18 had lacerations of the kidney, and 7 had lacerations of the pancreas. Eleven of these children had two or more solid organ injuries. Three of 28 children with ruptured

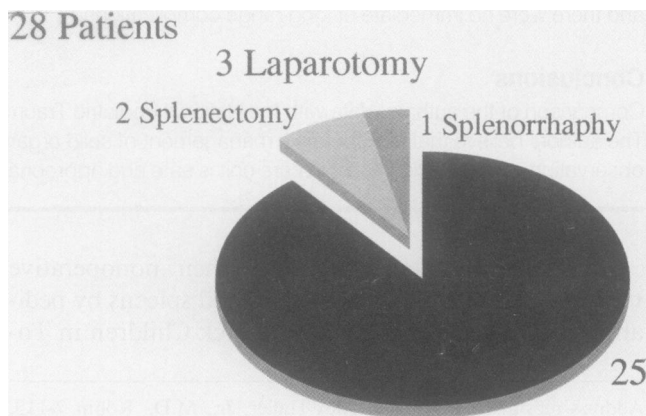


**Figure 1.** Management protocol for blunt abdominal trauma. The surgeon continues observation of monitored patient in pediatric intensive care unit to be prepared for emergency laparotomy if the injured child deteriorates and becomes hemodynamically unstable. (Adapted and used with permission from Karp et al.<sup>19</sup>)

spleens required laparotomy (two splenectomy, one splenorraphy) (Fig. 2).<sup>18</sup> Two of the 25 children with lacerations of the liver required laparotomy (one suturing, one partial resection) (Fig. 3).<sup>4,17-19</sup> One of the 18 children with kidney injuries required laparotomy (nephrectomy) (Fig. 4), and 3 of the 7 children with pancreas injuries required laparotomy (two resection, one pseudocyst drainage) (Fig. 5). Thus, 9 of 78 children in the initial nonoperative protocol eventually required laparotomy.

There were no deaths in children who were successfully managed nonoperatively and there were no immediate or long-range complications.<sup>20,21</sup> There were three deaths after laparotomy (two from associated head injuries and one from chest/abdominal injuries). (Fig. 6)

The one child who died from extensive chest and abdominal injuries presented as follows: A 4-year-old, 20 kg girl was crushed by a 500 lb mantel as she was placing Christmas ornaments on it. The marble mantel fell



**Figure 2.** Laceration of spleen.

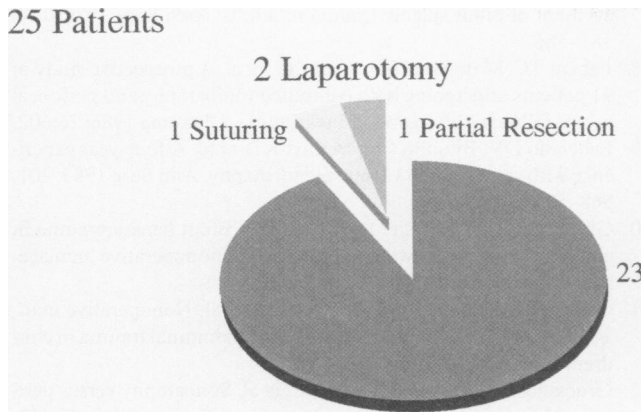


Figure 3. Laceration of liver.

across her abdomen and epigastrium, and she was found unconscious and hypotensive by paramedics (blood pressure = 40/60 systolic). Medical antishock trousers were applied, and leg portions were inflated. Helicopters were not flying because of bad weather, so she was transported to the nearest community hospital. She was pale and diaphoretic, with a blood pressure of 60 systolic. She was semiconscious, but following commands. Within 45 minutes, she was transferred to The Johns Hopkins Hospital by land transport. On arrival she was awake and alert, very pale, with a pulse rate of 180 and a blood pressure of 70/p. A right femoral line was placed for intravenous access, and fluid resuscitation began with lactated Ringers. The right hemidiaphragm appeared elevated on plain x-ray films. She was intubated and breath sounds were equal bilaterally to auscultation. Her head CT scan was normal. Her abdominal CT scan showed massive rupture of her entire liver and questionable retroperitoneal central bleeding. Blood transfusions were started during the CT procedure, and she was taken to the operating room 40 minutes after arrival at the Johns Hopkins Emergency Room.

On entering the abdomen, the aorta was cross-clamped. The liver was ruptured massively and the ret-

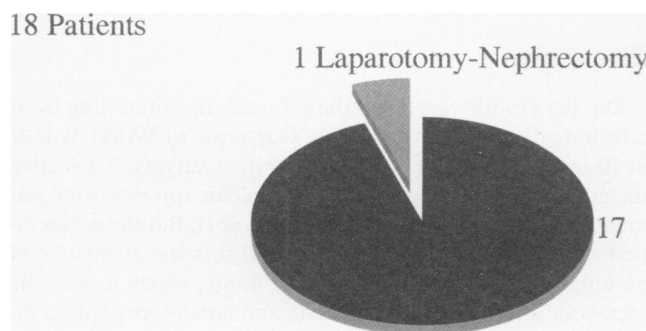


Figure 4. Kidney injuries.




Figure 5. Pancreas injuries.

rohepatic inferior vena cava was torn in multiple sites. A right atrial venocaval shunt was placed. Transections of the common hepatic artery and common bile duct were identified. Pancreatic contusion also was present. The right hepatic lobe was resected. The hepatic veins, portal veins, and caval lacerations were oversewn. After 34 units of blood, 15 units of fresh frozen plasma and 20 liters of lactated Ringers, the child's blood pressure could not be maintained and she had a cardiac arrest. Open cardiac massage was performed intraoperatively; however, the patient could not be resuscitated. The quality improvement discussion concluded that this was a non-preventable death caused by lethal injuries. A more rapid direct transport from injury site to operating room might have given this child a chance.

To give a broader perspective on the prevalence of nonoperative treatment over a wider geographic area, we obtained similar data for comparison from the National Pediatric Trauma Registry.<sup>22</sup> Eight hundred sixty-seven cases in the national registry, during the same time frame, met the above criteria of life-threatening blunt abdominal trauma. These patients are derived from all

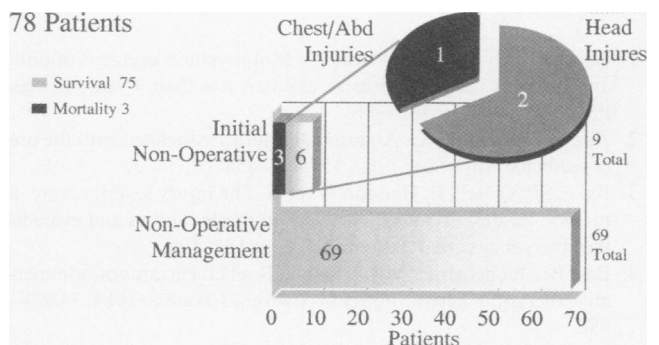


Figure 6. No deaths occurred in children who were successfully managed nonoperatively. Five of the 12 children who failed the nonoperative protocol died during or after laparotomy. Four of the five died of concomitant head injuries; one child could not be salvaged from massive liver and retroperitoneal injuries (see patient scenario in text).

types of trauma centers, including community hospitals, university hospitals and children's hospitals.<sup>10,11,23</sup> Sixty-two per cent (537/867) were not operated on with the following organ-specific break down of nonoperative management:

1. Spleen (151/235)
2. Kidney (101/136)
3. Liver (178/266)
4. Pancreas (12/19)
5. Multiple organs (95/211)

No exact cause of death can be obtained from the national registry; however, the vast majority of patients died from concomitant head injuries. This is not a precise comparable group of trauma patients because the data are not gathered prospectively and they are not from institutions which use the identical protocol we have recommended.<sup>24</sup> The National Pediatric Trauma Registry recorded a mean injury severity score<sup>3</sup> of 8 and a mean PTS<sup>22</sup> of 9, which suggests less severe trauma than our study group.<sup>6</sup>

Nevertheless, the low incidence of laparotomy (38%) in this national group and 12% (9/78) in our own carefully selected trauma patients, as well as the absence of any mortality related to the initial nonoperative management, have convinced us of the efficacy of this protocol. Therefore, we believe that, for children with blunt abdominal injuries, nonoperative management to solid organs is safe and appropriate if carried out under careful continuous surgical observation in a pediatric intensive care unit.

## Acknowledgment

The authors thank Dr. Carla DiScala for the National Pediatric Trauma Registry data.

## References

1. Agran PF, Dunkle DE, Winn DG. Motor vehicle accident trauma and restraint usage patterns in children less than 4 years of age. *Pediatrics* 1985; 76:382-386.
2. Appleby JP, Nagy AG. Abdominal injuries associated with the use of seatbelts. *Am J Surg* 1989; 157:457-458.
3. Baker SP, O'Neill B, Haddon W, et al. The injury severity score: a method for describing patients with multiple injuries and evaluating emergency care. *J Trauma* 1974; 14:187-196.
4. Bass BL, Eichelberger MR, Schisgall R, et al. Hazards of nonoperative therapy of hepatic injury in children. *J Trauma* 1984; 24:978-982.
5. Eichelberger ML, Randolph JR. Pediatric trauma—an algorithm for diagnosis and therapy. *J Trauma* 1983; 23:91-97.
6. Eichelberger MR, Gotschall CS, Sacco WJ, et al. A comparison of the trauma score, the revised trauma score, and the pediatric trauma score. *Ann Emerg Med* 1989; 18:1053-1058.
7. Elmore JR, Clark DE, Isler RJ, et al. Selective nonoperative man-

- agement of blunt splenic trauma in adults. *Arch Surg* 1989; 124: 581-586.
8. Fabian TC, Mangiante EC, White TJ, et al. A prospective study of 91 patients undergoing both computed tomography and peritoneal lavage following blunt abdominal trauma. *J Trauma* 1986; 26:602.
9. Feliciano DV, Bitondo CG, Mattox KL, et al. A four-year experience with splenectomy versus splenorrhaphy. *Ann Surg* 1985; 201: 568-575.
10. Giacomantonio M, Filler RM, Rich RH. Blunt hepatic trauma in children: experience with operative and nonoperative management. *J Pediatr Surg* 1984; 19:519-522.
11. Grisoni ER, Gauderer MWL, Ferron J, et al. Nonoperative management of liver injuries following blunt abdominal trauma in children. *J Pediatr Surg* 1984; 19:515-518.
12. Gruessner R, Mentges B, Dueber C, et al. Sonography versus peritoneal lavage in blunt abdominal trauma. *J Trauma* 1989; 29:242.
13. Henneman PL, Marx JA, Moore EE, et al. Diagnostic peritoneal lavage: accuracy in predicting necessary laparotomy following blunt and penetrating trauma. *J Trauma* 1990; 30:1345.
14. Hoffman MA, Spence LJ, Wesson DE, et al. The pediatric passenger: trends in seatbelt use and injury. *J Trauma* 1987; 27:974-976.
15. Meyer DM, Thal ER, Weigelt JA, et al. Evaluation of computed tomography and diagnostic peritoneal lavage in blunt abdominal trauma. *J Trauma* 1989; 29:1168.
16. Wesson DE, Filler RM, Ein SH, et al. Ruptured spleen—impact of CT for blunt abdominal trauma. *AJR Am J Roentgenol* 1985; 145: 1191-1194.
17. Karp MP, Cooney DR, Berger PE, et al. The role of computed tomography in the evaluation of blunt abdominal trauma in children. *J Pediatr Surg* 1981; 16:316.
18. Morgenstern L, Shapiro SJ. Techniques of splenic conservation. *Arch Surg* 1979; 114:449-454.
19. Oldham KT, Guice KS, Ryckman F, et al. Blunt liver injury in childhood: evolution of therapy and current perspective. *Surgery* 1986; 100:542-549.
20. Pearl RH, Wesson DE, Spence LJ, et al. Splenic injury: a year update with improved results and changing criteria for conservative management. *J Pediatr Surg* 1989; 24:121-125.
21. Buntain WL, Gould HR, Maull KI. Predictability of splenic salvage by computed tomography. *J Trauma* 1988; 28:24-34.
22. Tepas JJ, Mollitt DL, Talbert JL, et al. The pediatric trauma score as a predictor of injury severity in the injured child. *J Pediatr Surg* 1987; 22:14-18.
23. The Splenic Injury Study Group. Splenic injury: a prospective multicentre study on non-operative and operative treatment. *Br J Surg* 1987; 74:310-313.
24. Velanovich V, Tapper D. Decision analysis in children with blunt splenic trauma: the effects of observation, splenorrhaphy, or splenectomy on quality adjusted life expectancy.

## Discussion

DR. EDWIN IDE SMITH (Dallas, Texas): It's interesting from a historical standpoint to realize that prior to World War II in Begger & Horsley's book on operative surgery, a selective including nonoperative approach to splenic injuries is recommended. It later changed with World War II. But the preservation of the spleen is important. But also is the avoidance of an unnecessary anesthesia and laparotomy, which lessens the metabolic stress—or the anesthesia and laparotomy would increase the metabolic stress on a potentially injured CNS system. And I think this is one area that needs considerably more