

## Changes in the dendritic organization of neurons in the cerebral cortex following deafferentation

BY W. HEDLEY JONES\* AND D. BRYNMOR THOMAS†

*Department of Anatomy, University College London*

Degenerative changes in the deafferentated neurons of the lateral geniculate body have been demonstrated (Le Gros Clark & Penman, 1933) and similar dependence of neuron populations on the integrity of their afferent input has been sought elsewhere in the central nervous system. Allison (1954) has described changes in the neurons of the prepiriform cortex after degeneration of the olfactory tract, in Nissl-stained preparations. In the present study we have examined Golgi-Cox preparations of the prepiriform cortex of the rat brain after olfactory bulb resection. Whereas previous investigators have focused their attention on the perikaryon, we have been concerned primarily with the behaviour of the dendrite network.

The prepiriform cortex lends itself readily to this investigation. The origin of its principal group of afferent fibres is known (Brodal, 1947) and these can be interrupted by a relatively easy surgical operation, which involves minimal trauma to the adjacent neural tissue. Further, the arrangement of the neurons in this region (Cajal, 1955) is especially convenient as the dendrites, which pass from a discrete layer of pyramidal cells to make axo-dendritic synapses with the axons of the lateral olfactory tract (Le Gros Clark & Meyer, 1947) are conveniently studied in the deep zone of the plexiform layer, where no other structures confuse the histological picture (Text-fig. 1).

### MATERIAL AND METHODS

The study was based on the histological examination of Golgi-Cox preparations of twenty-three rat brains. Eleven of these were from animals autopsied at varying intervals after olfactory bulb resection (Table 1), on one side only in eight and on both sides in three, and twelve were from normal adult rats, the ages of which at the time of autopsy were comparable with those of the animals in the experimental group.

*Procedure.* Under general anaesthesia the brain was, in each case, completely exposed and, after transection of the brain-stem and cranial nerves, placed momentarily in warm saline and transferred to Golgi-Cox fixative (Sholl, 1953). The delay between death of the animal, indicated by cessation of the heart beat, and introduction of the isolated brain into the fixative ranged from 1 to 15 min. The brains were left in the fixative, undisturbed and in the dark, for periods of from 6 to 8 weeks. The final stages of the Golgi-Cox technique (Sholl, 1953) were then completed, each brain being cut in its entirety into coronal sections at 150  $\mu$ .

The brains of the animals in the experimental group were prepared in an identical manner, following autopsy after survival periods of from 91 to 492 days.

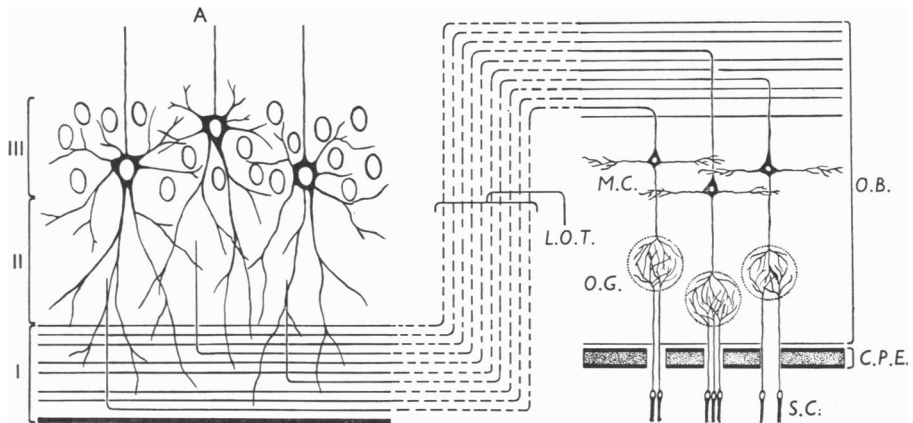
\* Present address: Brompton Hospital, London, S.W. 3.

† Present address: Institute of Pathology, The Royal Infirmary, Cardiff.

Table 1. *Experimental material*

Series no.	Survival time after operation (days)	Operation—olfactory bulb resection	Age at operation (days)	Asystole-fixation interval (min.)	Fixation time (weeks)
R. 1	91	Left	Uncertain*	6	7
R. 2	309	Bilateral	44	10	7
R. 3	309	Left	44	10	7
R. 4	309	Left	44	5	7
R. 5	309	Left	44	7	7
R. 6	310	Bilateral	44	7	7
R. 7	427	Left	Uncertain*	15	6
R. 8	428	Bilateral	Uncertain*	10	6
R. 9	491	Left	41	1	8
R. 10	491	Left	41	4	8
R. 11	492	Left	41	5	6

\* Approximately 40 days.

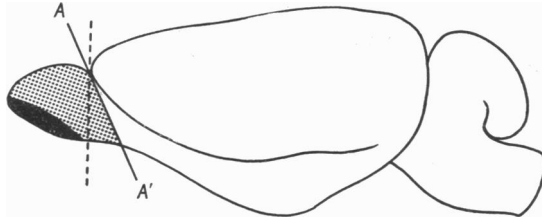


Text-fig. 1. Schematic representation of the principal olfactory pathway from the sensory epithelium of the nose to the pyramidal cells of the prepiriform cortex. The fibres course from the sensory cells (*S.C.*) in the olfactory epithelium of the nose, through the cribriform plate of the ethmoid (*C.P.E.*), to enter the olfactory bulb (*O.B.*) and reach the olfactory glomeruli (*O.G.*) where the first synapse is situated. From the olfactory glomeruli the dendrites of the mitral cells (*M.C.*) continue centrally to their perikarya, many of the axons of which without further synapse form the lateral olfactory tract (*L.O.T.*) which passes caudally as the superficial layer of the prepiriform region. These axons are met by ascending dendrites of the pyramidal cells of the prepiriform cortex in the second synapse of the main pathway. The outer three layers of the prepiriform cortex (*A*) are indicated: I. Outer fibre layer. II. Plexiform layer. III. Pyramidal cell layer.

*Operative technique.* General anaesthesia was induced with intraperitoneal Nembutal (45 mg./kg. body weight) and maintained with open ether. A median incision was made through the skin, subcutaneous and muscular layers on the dorsal aspect of the head, extending backwards for approximately 2 cm. from a point 1 cm. caudal to the tip of the snout. The wound edges were retracted and the periosteum of the anterodorsal aspect of the skull incised in the mid-line, and elevated from the

underlying bone. Burr holes were made in the bone over the olfactory bulbs, using a dental drill, and the exposure of the operative field was completed using a fine bone-nibbling forceps, great care being taken to avoid the major venous sinuses, haemorrhage from which cannot be satisfactorily controlled.

Through the meninges the olfactory peduncle was sectioned obliquely using an ophthalmic knife (Text-fig. 2), so that the dorsal part of the incision was immediately anterior to the anterior limit of the ipsilateral cerebral hemisphere, passing ventro-caudally. In this way the olfactory bulb, together with the olfactory nerve bundles entering it by way of the cribriform plate of the ethmoid bone, was isolated from the cerebral hemisphere. After transection of the olfactory nerve bundles the olfactory bulb was removed together with any adherent meningeal attachments. Gelatin sponge moistened in thrombin solution was packed into the cavity and pressure on this maintained until haemostasis was secured, when more of the same material was inserted and left in position. The periosteal flaps were approximated with catgut sutures and the superficial tissues closed as one layer with simple interrupted silk sutures.



Text-fig. 2. Lateral projection of a rat brain to illustrate the obliquity of the plane of transection  $AA'$  of the olfactory peduncle and the extent of the surgical lesion inflicted. The shaded area represents that part of the olfactory bulb receiving the afferent olfactory nerve bundles, and the dotted area the remainder of the resected olfactory bulb together with a portion of the olfactory peduncle.

#### OBSERVATIONS

The twenty-three brains examined can be conveniently considered as three separate groups:

I, twelve brains obtained from normal adult rats;

II, three brains obtained from rats subjected to *bilateral* olfactory bulb resection;

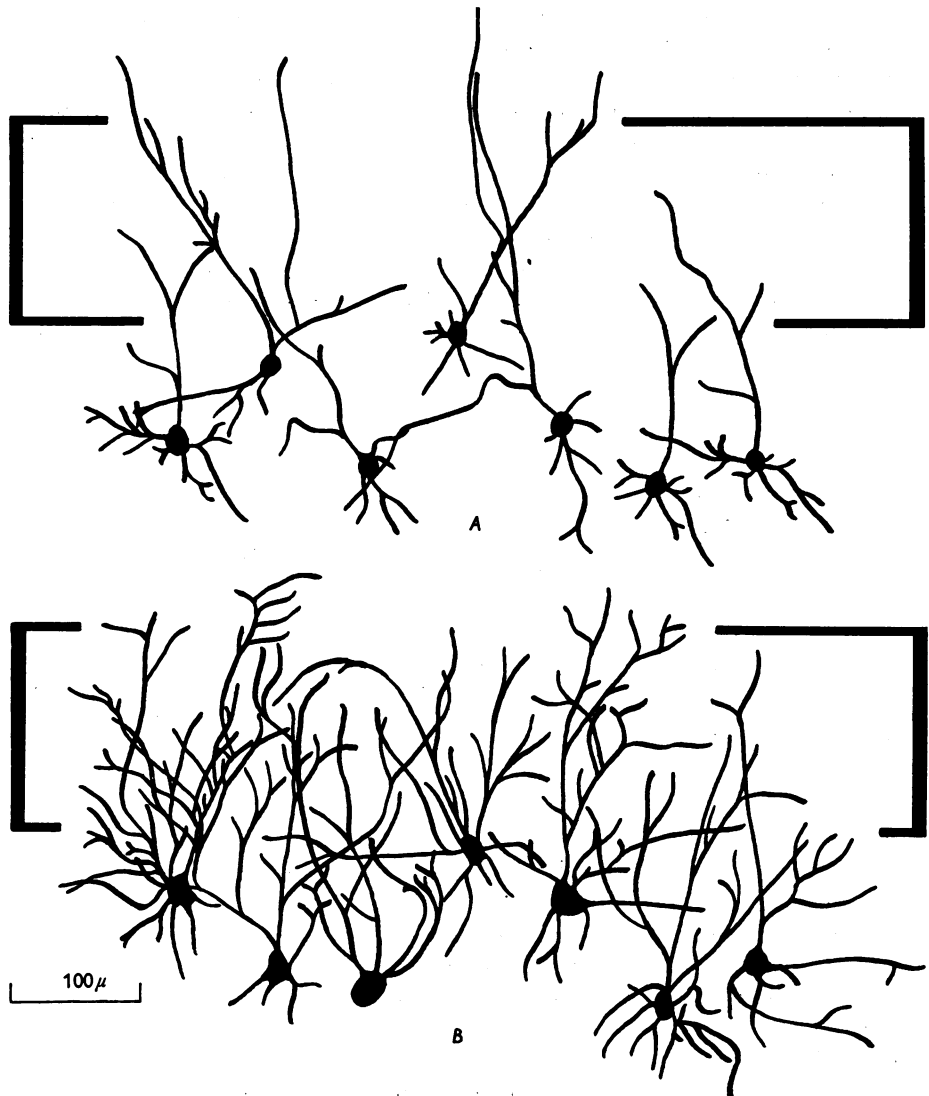
III, eight brains obtained from rats subjected to *unilateral* olfactory bulb resection.

*Group I.* The prepiriform cortex of the twelve normal rat brains of the series reveals a constant pattern of impregnation and no variation has been observed between any two brains or the two sides of any one brain. The dendrites of the prepiriform pyramidal cells, as they pass through the plexiform layer (Text-fig. 1 and Plate) are seen as a fibre network of constant organization. In each case the general uniformity of the impregnation has been confirmed by examination of the neocortex where no irregularities of fibre impregnation are present.

*Group II.* In animals subjected to bilateral olfactory bulb resection the appearance of the prepiriform cortex differs in a striking fashion from that described above,

the network of dendrites being very much more sparse. Again a conspicuous feature is the constancy of pattern in each of the six hemispheres included in this group.

*Group III.* In each of the eight brains obtained from animals that had been subjected to unilateral olfactory bulb resection the prepiriform cortex on the side

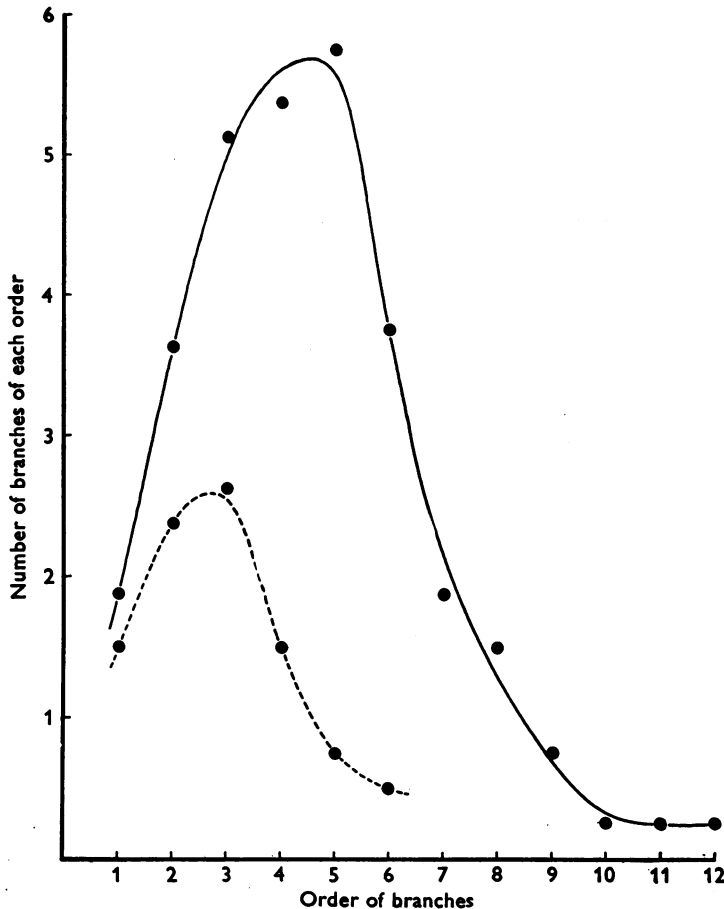


Text-fig. 3. Reconstruction of the prepiriform cortex of the rat to show the pyramidal cell bodies, synthesized from microprojector tracings: *A*, following 91 days deafferentation; *B*, normal. The plexiform layer of the prepiriform cortex is indicated by square brackets. (Compare with Pl. 1.)

corresponding to the operation is essentially similar to that observed in the brains of group II, whereas the prepiriform cortex on the other side conforms exactly with that described for group I (Plate). In this series, as in the other two, uniformity

of impregnation has been checked by reference to the neocortex and found to be perfectly even.

These appearances demonstrate conclusively the presence of fewer pyramidal cell dendrites in the plexiform layer of the prepiriform cortex following olfactory bulb resection. The question arises as to whether this is due to there being fewer pyramidal neurons each with a normal complement of dendritic branches, *or* to



Text-fig. 4. Graph to illustrate the failure of the dendrites arising from deafferentated neurons to branch as frequently as those of normal neurons. The number of branches of each order is plotted against the order. Average values for sixteen neurons from the two sides of a rat brain autopsied 91 days after unilateral olfactory bulb resection. ●—●, Normal; ● - - - ●, following deafferentation.

there being fewer branches arising from any given perikaryon, the total number of neurons being unchanged, *or* to a combination of both these factors. Matthews, Cowan & Powell (1960) in their study of Nissl preparations of the monkey lateral geniculate body report 'a slight but significant loss of neurons in lamina 6' 4 months

after eye enucleation. In Nissl-stained preparations made after olfactory bulb resection, with known survival periods of from 127 to 310 days we have not observed any obvious reduction in the pyramidal cell population.

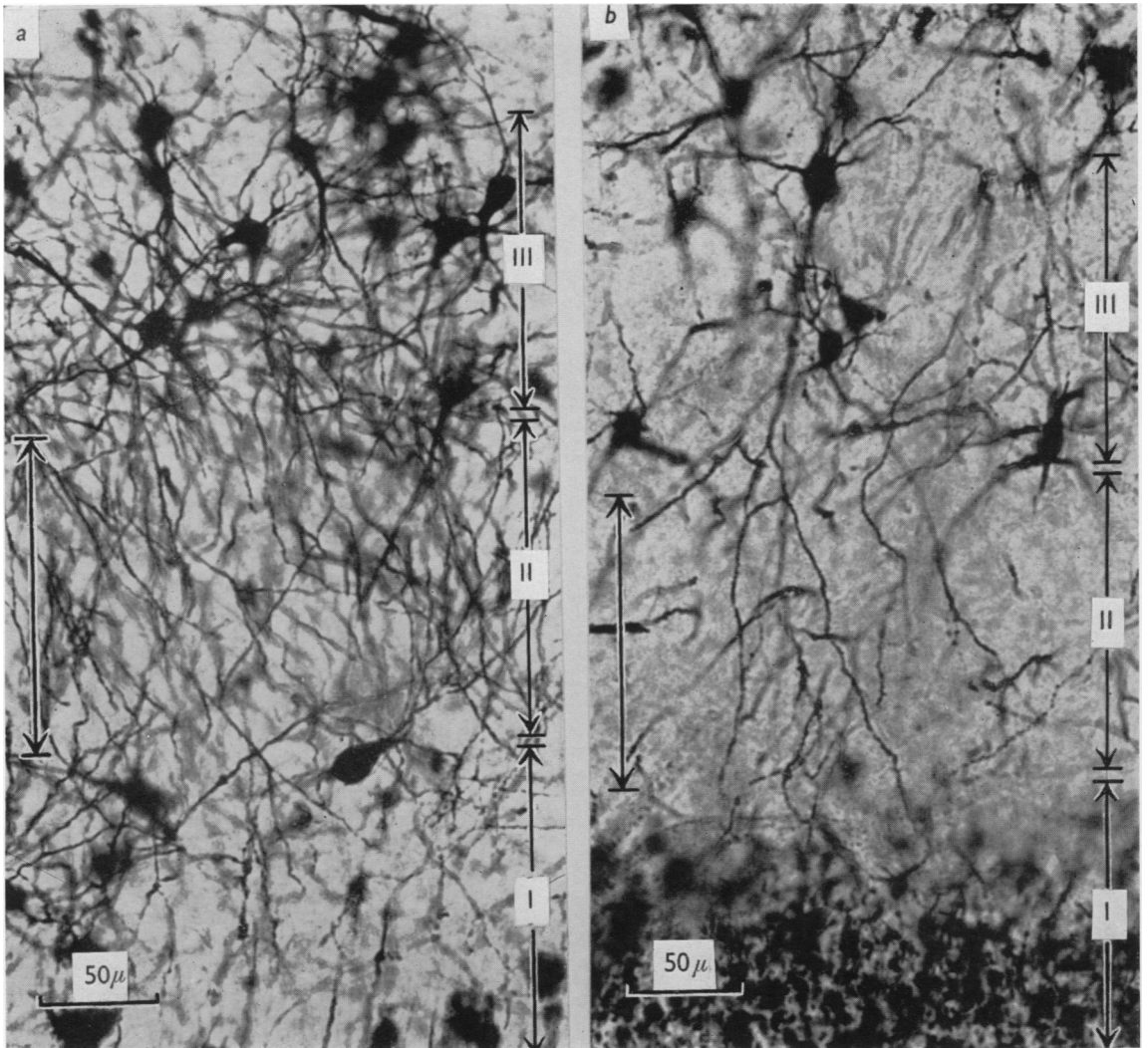
Microprojector tracings of neurons (Text-fig. 3) that appeared to be completely impregnated and which were selected at random, demonstrate clearly a reduction in the number of branches arising from neurons on the side corresponding to the operation (Jones & Thomas, 1956). Typically two apical dendrites, sometimes one or three, arise from each normal perikaryon: these divide repeatedly to produce a dense cluster of branches, passing towards the lateral olfactory tract. An average of fifteen branching points has been counted in the apical dendritic fields of eight such neurons in the brain of a rat subjected to unilateral olfactory bulb resection, whereas in a comparable series of neurons from the other side of the brain, corresponding to the operation, the apical dendritic field of each neuron contained an average of only four branching points but the primary dendrites arising from these cells were not reduced in number. The failure of the dendrites of deafferentated neurons to divide is illustrated in the graph (Text-fig. 4).

The dendrites arising from normal perikarya double their number at their primary division and continue to become more numerous up to the division of the branches of the fifth order, when a gradual decrease commences. The dendrites arising from deafferentated perikarya, however, although increasing slightly in number by their primary and secondary divisions, have very few tertiary divisions, so that there is a rapid decrease in the number of branches in the higher orders. The basal dendrites of the deafferentated neurons branch in the same way as do those of normal cells.

#### DISCUSSION

It may be that we have been observing changes that form but part of a sequence culminating in the complete disappearance of deafferentated neurons. Further observations will be necessary before this problem can be resolved.

The role of afferent input in the development and subsequent maintenance of neuronal organization is at the present time uncertain, and the precise mechanism by which the activity of afferent fibres influences the morphology of the neurons in their field of innervation is a matter for conjecture. The changes observed may be due exclusively to a reduction in the number of impulses reaching the prepiriform pyramidal cells from the sensory cells of the nasal epithelium, or they may be due at least in part to isolation of the pyramidal cells from some controlling influence responsible for the maintenance of their morphology, exerted by the mitral cells of the olfactory bulb. If the absence of sensory stimuli from the nasal epithelium is solely responsible for the changes that we have observed, surgical lesions at any site along the nervous pathway would presumably produce similar changes in the dendritic network of the pyramidal cells. Thus transection of the olfactory nerve bundles as they enter the olfactory bulb from the cribriform plate of the ethmoid, with preservation of the normal relationship between the olfactory bulb and the prepiriform cortex, would produce effects similar to those following olfactory bulb resection. However, if the dendritic pattern is also directly influenced by the mitral cells of the olfactory bulb, interruption of the nerve pathway peripheral to the mitral



cells might lead to changes in the dendritic organization of the pyramidal cells less obvious than those observed after olfactory lobectomy. This is being investigated by us at the present time.

## SUMMARY AND CONCLUSION

1. The dendritic organization of the pyramidal neurons of the rat prepiriform cortex has been studied after reduction of their afferent input, by olfactory bulb resection, and compared with the normal.

2. The dendrites have been examined in Golgi-Cox preparations of forty-six cerebral hemispheres; thirty-two of these were in normal association with intact olfactory bulbs and fourteen had been severed from their olfactory input at known intervals before autopsy.

3. Each of the former reveals a constant pattern of dendritic organization in the plexiform layer of the prepiriform cortex, whereas in each of the latter an obvious reduction in the density of this network is consistently observed.

4. It has been shown that this reduction in the density of the dendrite network is due to a decrease in the number of dendritic branches arising from each pyramidal cell, most marked among dendritic branches of the higher orders without any obvious reduction in the number of primary dendrites.

We conclude that the preservation of the normal pattern of dendritic organization of the pyramidal neurons in the prepiriform cortex of the rat brain is dependent upon the integrity of their afferent input.

We are deeply indebted to Prof. J. Z. Young, who placed at our disposal the facilities for this investigation, for his generosity, encouragement and advice. It is a pleasure to record the invaluable help of Mr J. Armstrong the Principal Technician, and of his assistants Miss Pamela Hines, Miss Thelma Marchment and Miss Betty Shirra.

## REFERENCES

- ALLISON, A. C. (1954). The secondary olfactory areas in the human brain. *J. Anat., Lond.*, **88**, 481-488.
- BRODAL, A. (1947). The hippocampus and the sense of smell. *Brain*, **70**, 179-222.
- CAJAL, RAMON Y S. (1955). *Studies on the Cerebral Cortex*. London: Lloyd-Luke, Ltd.
- JONES, W. HEDLEY & THOMAS, D. BRYNMOR (1956). Trans-synaptic atrophy in the cerebral cortex. *Nature, Lond.*, **178**, 47-48.
- LE GROS CLARK, W. E. & MEYER, M. (1947). The terminal connexions of the olfactory tract in the rabbit. *Brain*, **70**, 304-328.
- LE GROS CLARK, W. E. & PENMAN, G. G. (1933). The projection of the retina in the lateral geniculate body. *Proc. Roy. Soc. B*, **114**, 291-313.
- MATTHEWS, MARGARET R., COWAN, W. M. & POWELL, T. P. S. (1960). Transneuronal cell degeneration in the lateral geniculate nucleus of the Macaque monkey. *J. Anat., Lond.*, **94**, 145-169.
- SHOLL, D. A. (1953). Dendritic organization in the neurons of the visual and motor cortices of the cat. *J. Anat., Lond.*, **87**, 387-406.

## EXPLANATION OF PLATE

The prepiriform cortex taken from coronal sections of a rat brain, autopsied 91 days after unilateral olfactory bulb resection (Golgi-Cox impregnation). I. Outer fibre layer. II. Plexiform layer. III. Pyramidal cell layer.

- (a) From the side corresponding to the intact olfactory bulb.  
 (b) From the side corresponding to the resected olfactory bulb.