

A study of the melanocytes and melanin in a healing deep wound

By R. S. SNELL

Department of Anatomy, Medical School, King's College, Newcastle upon Tyne 1

The histological changes which occur in the healing of a skin wound by secondary intention have been the subject of many investigations. Only recently, however, has any work been carried out on the activity of the melanocytes and the appearances of melanin during this process. The present experiment is a study of the density and morphology of the melanocytes and the amount of free melanin present in different areas of a deep skin wound in the guinea-pig during the repair process.

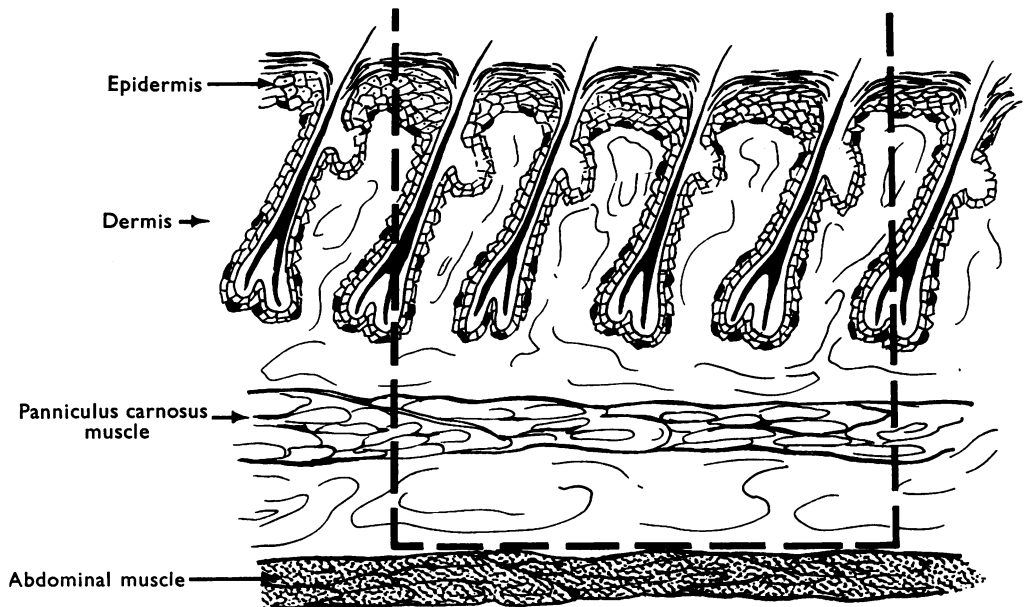
MATERIALS AND METHODS

Forty-two male guinea-pigs weighing between 255 and 940 g. were used. They were divided into groups, each consisting of two pure black and one pure red animal. Under general anaesthesia, the skin of the thoraco-lumbar region was shaved and cleaned with Cetrimide and Dettol. A square formica template measuring 4 cm.² was placed on the skin surface and the area to be removed was marked out with a pen. The site of the area was midway between the last rib and the iliac crest and was situated about 1 cm. from the spines of the lumbar vertebrae. A clean scalpel incision was then made and the skin removed, the line of cleavage occurring in the connective tissue situated between the panniculus carnosus and the posterior layer of the thoraco-lumbar fascia (Text-fig. 1). In this manner, all the hair follicles were removed. The wound bed was sprayed with penicillin G., and sulphadiazine powder and covered with tullegras. A further gauze dressing was applied and covered with elastoplast bandage. This dressing was left in position for a period of up to 5 days, when it was carefully removed. Most of the wounds at this stage had a fully formed eschar. The piece of skin removed constituted the control biopsy specimen.

The groups of animals were then killed at intervals at 1, 4, 6, 9, 12, 14, 16, 19, 23, 27, 30, 36, 58 and 70 days after the operation. The entire wound area, including the bed, was then removed from each animal and this constituted the experimental biopsy specimen. The control and experimental biopsy specimens were processed as follows: immediately after removal, the specimen was placed flat on a glass slide at -20° C. for 4 hr. Five per cent formal saline was then poured on the specimen, which was transferred to a refrigerator (4° C.) and left overnight. This procedure was carried out in order that the specimens should remain intact and absolutely flat. The deeper part of the dermis of the control specimens was then removed by a freezing microtome as described previously (Snell, 1962*a*). In the experimental skin specimens, this was only possible 9 or more days after operation, since before this the granulation tissue in the base of the wound was not sufficiently mature to allow the underlying tissues to be cut away by the microtome knife. All the control and experimental

specimens were treated with the Dopa reagent and post fixed as described previously (Snell & Bischitz, 1960*a*). Each control and experimental specimen was divided into two. Half was mounted in Depex as a whole mount and the remainder was embedded in paraffin and sectioned at 6μ thick. The sections were either left unstained, or stained with eosin or with haematoxylin and eosin.

The sites in the control and experimental wound specimens which were considered to be of special interest for melanocyte study are shown diagrammatically in Text-fig. 2. The morphological appearances of the melanocytes in the control skin



Text-fig. 1. Diagram of skin wound. The interrupted line shows the depth of the wound and the amount of tissue removed.

specimen (site *A*), at the margin of the wound (site *B*), and at the advancing edge of the epithelial ingrowth (site *C*), were compared. Melanocyte counts on the whole mount preparations were carried out in the corresponding areas.

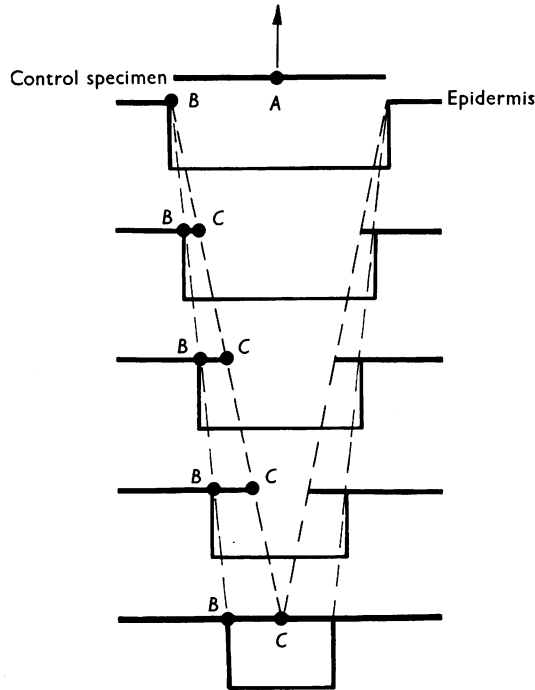
RESULTS

The melanocytes of guinea-pig skin are found in two sites, the hair follicles and the basal layer of the epidermis (Pl. 1, figs. 1, 2). The appearances of the melanocytes and melanin in the skin of the normal guinea-pig at different ages in the two sexes have been reported previously (Bischitz & Snell, 1959; Snell & Bischitz, 1960*b*).

Macroscopical appearances

Immediately after the operation, the wound margins retracted to enclose an area larger than that originally defined. On the fourth day, wound contraction had begun and this process continued throughout the remainder of the experiment. At

first, the wound bed was masked by a soft mixture of blood clot and penicillin and sulphadiazine powder, but after 24 hr. this hardened and formed a tough eschar. At no time during the experiment was the eschar disturbed in order to study macroscopically the progress of the underlying epithelial ingrowth.



Text-fig. 2. Diagrammatic representation of vertical section of healing wound showing sites considered to be of special interest for melanocyte study. *A* = centre of control skin specimen (i.e. skin specimen removed to produce wound). *B* = margin of skin wound (just beyond line of hair follicles). *C* = advancing edge of epithelial ingrowth. Diminishing size of wound base represents contracture. ●, Counting sites.

Microscopical appearances

Epithelial migration. Examination of the vertical skin sections showed that epithelial migration from the wound edge had started in one of the three animals on the fourth postoperative day, but by the sixth day all three animals of the group showed some inward spread. Thereafter, the rate of epithelial advance (Pl. 1, fig. 4) showed individual variation, but on the twenty-third day, resurfacing was complete in all the animals of the group. The advancing epithelial edge was extremely thin, being about two cells thick. At first, the junction between the epithelium and the underlying granulation tissue formed a straight line, but by the ninth day epidermal ridges had started to appear. The covering epithelium of the healed wound was of the stratified squamous type, there being no hair follicles or sebaceous glands present (Pl. 1, fig. 6).

Melanocyte migration. Examination of the vertical skin sections showed that as

soon as the epithelium started to migrate over the wound, melanocytes were present within the new covering epithelium. They were seen in the covering epithelium in one of the animals on the fourth day following the operation, and thereafter were always present. The most advanced melanocyte was usually situated a short distance behind the advancing epithelial edge and was never found in front of the Malpighian cells (Pl. 1, fig. 4). A combined examination of both the vertical sections and whole mounts at different periods revealed the following additional data: in area *C*, i.e. the region of the advancing epithelial edge, the melanocytes were irregularly scattered (Pl. 1, figs. 3, 5). They had cell bodies which were smaller than normal, or very much larger, especially in the case of the black animals. Some of the cell bodies contained less melanin, and some more melanin, than found normally. In many of the specimens, the dendritic processes were absent or few in number. If the dendritic processes were present, they were simple with few branches and stretched out in the line of the advancing epithelium (Pl. 2, fig. 9), or they were short and stumpy (Pl. 1, figs. 3, 5). Some of the melanocytes in this area appeared to be undergoing division, and were tethered together by a single melanin-containing band (Pl. 2, fig. 7). Others appeared to have already undergone division and were lying unattached, but closer together with no dendrites apparent. No mitotic figures were seen. A little free melanin was present in this area. In the red animals it was particularly noted that the melanocytes contained less melanin and were surrounded by less free melanin than in areas *A* and *B*.

In area *B*, i.e. at the wound margin, at 9 days or later after the operation, the melanocytes were similar to those in the control skin. Many of the melanocytes had large cell bodies filled with melanin and long, complex dendritic processes (Pl. 2, fig. 8). The dendritic processes still showed a tendency to lie in the direction of the advancing epithelium, i.e. one set pointing to the wound margin and the other to the centre of the wound. The melanocytes were surrounded by a normal amount of free melanin. In many specimens, the melanocytes were arranged in orderly rows which ran from the wound margin and converged on the wound centre (Pl. 2, fig. 9). The melanocytes were not all situated on the same plane. The vertical sections revealed that the melanocytes in this region were situated on the summit and sides of the newly formed epidermal ridges (Pl. 1, fig. 6; Pl. 2, fig. 11). In many of the wound specimens, especially those of the red animals, a gradient of free melanin concentration existed, being low towards the centre of the wound and rising as the wound margin was approached.

In the specimens which showed complete epithelial coverage, i.e. those taken from animals killed 23 days or longer after operation, the melanocytes in area *C* had a normal appearance and contained a moderate amount of melanin; the dendritic processes were long and complex and were surrounded by a normal amount of free melanin (Pl. 2, figs. 10, 12).

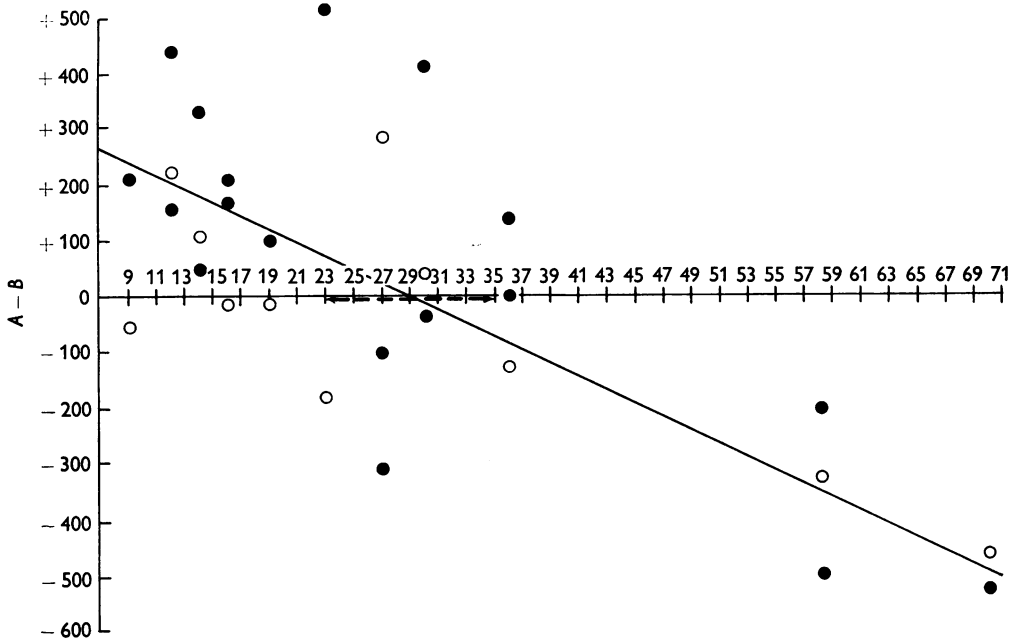
The melanocyte counts on the whole mounts for areas *A*, *B* and *C* are shown in Table 1. No counts for areas *B* and *C* were possible, 1, 4 and 6 days after operation, for technical reasons (see Materials and Methods). A statistical analysis of the figures showed that in the normal skin of the lumbar region (site *A*) the melanocyte counts for the black animals are greater than those for the red. The difference between the mean readings of the black and red animals at site *A* is highly significant

Table 1. *The melanocyte counts at sites A, B and C during the process of healing in a series of deep wounds in the skin of the guinea-pig*

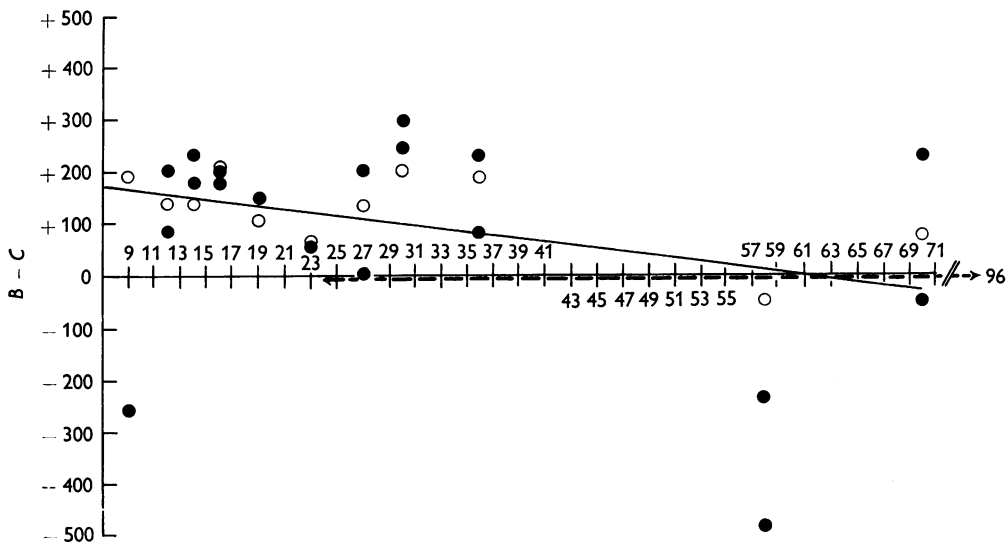
Time interval following operation in days	No. of animal	Colour of animal	Weight of animal (g.)	Site A	Site B	Site C
First	1201	Black	275	918	—	—
	1202	Black	265	886	—	—
	1200	Red	690	603	—	—
Fourth	1204	Black	255	712	—	—
	1205	Black	285	767	—	—
	1203	Red	695	397	—	—
Sixth	1189	Black	760	685	—	—
	1190	Black	475	959	—	—
	1188	Red	665	342	—	—
Ninth	1195	Black	295	699	493	753
	1196	Black	380	671	—	—
	1194	Red	385	507	562	370
Twelfth	1186	Black	425	932	493	288
	1187	Black	425	685	534	451
	1185	Red	870	675	452	315
Fourteenth	1183	Black	495	932	603	370
	1184	Black	445	740	699	521
	1182	Red	720	479	370	233
Sixteenth	1192	Black	380	808	603	425
	1193	Black	295	808	644	438
	1191	Red	420	589	603	384
Nineteenth	1180	Black	505	822	—	—
	1181	Black	685	548	452	301
	1179	Red	615	521	534	425
Twenty-third	1177	Black	415	822	—	—
	1178	Black	430	932	411	356
	1176	Red	530	521	699	630
Twenty-seventh	1171	Black	390	575	726	521
	1172	Black	495	863	1178	1178
	1170	Red	500	630	342	205
Thirtieth	1174	Black	515	507	548	301
	1175	Black	405	945	534	233
	1173	Red	495	630	589	384
Thirty-sixth	1168	Black	755	699	699	466
	1169	Black	495	644	507	425
	1167	Red	605	685	808	616
Fifty-eighth	1198	Black	670	905	1123	1357
	1208	Black	580	452	952	1435
	1197	Red	940	437	764	811
Seventieth	1199	Black	650	640	1170	936
	1207	Black	630	686	1357	1404
	1206	Red	660	515	983	905

At control site A. Difference in mean cell counts per mm.² between black and red animals = 219. $t_{40 \text{ d.f.}} = 3.69$. $P < 0.1\%$

The figure given for the melanocyte count at each site represents the average of ten counts taken at random within the site. The counts were carried out with a graticule fitted in the eyepiece of a microscope and a magnification of $\times 353$ was used.



Text-fig. 3. Graph showing the differences between the counts of sites *A* and *B*. ●, Black animals; ○, red animals. Dotted line indicates the range 23–35 days in which counts for the average wound at site *B* could become as large as counts at site *A*. $y = 346.162 - 11.928x$. $r_{28 \text{ d.f.}} = -0.773$. $P < 0.001$.



Text-fig. 4. Graph showing the differences between the counts of sites *B* and *C*. Dotted line indicates the range 24–96 days in which counts for the average wound at site *C* could become as large as counts at site *B*. $y = 195.256 - 3.232x$. $r_{28 \text{ d.f.}} = -0.365$. $P = 0.05$.

(at the 0.1 % level). To equate this difference between black and red animals and, at the same time, to equate other differences between individual animals, each animal was used as its own control. This was achieved by assessing for each animal the difference between counts at the control area (*A*) and the wound margin (*B*).

When the degree of association between the difference in the counts at sites *A* and *B* and time is measured (Text-fig. 3), both the black and red animals show significant negative correlations. The slopes of the lines for black and red animals were compared and found to be not significantly different; the distance between the lines was also not significant. Accordingly, results from black and red animals have been taken together. Ninety-five per cent confidence limits were then fitted to the overall regression line to estimate the range within which it might be expected that the counts for the average of the wounds at site *B* could become as large as counts at site *A*. The regression line for *A* - *B* crossed the 'time' axis at day 29. The fitted 95 % confidence limits showed that counts at site *B* would achieve those at site *A* between days 23 and 35. For individual wounds, melanocyte counts at site *B* could become as large as at site *A* at any time between 0 and 62 days.

To study the differential rates of wound healing, again eliminating the differences between individual animals, further analysis was carried out on the difference between counts at the wound margin (*B*) and the advancing edge of epithelial ingrowth (*C*). The negative correlations of the difference in the counts at sites *B* and *C* and time (Text-fig. 4) were not significant for either the black or the red animals. Assessing the animals together resulted in a negative correlation $r = -0.365$ with 28 d.f., $P = 0.05$, which is statistically significant (at the 5 % level). Comparison of the slopes of the regression lines for the black and red animals showed that they were not statistically different and that the distance between the lines was not significant. Ninety-five per cent confidence limits were then fitted as before to the overall regression line to estimate the range within which it might be expected that the counts for the average wounds at site *C* could become as large as counts at site *B*. The regression line for *B* - *C* crossed the 'time' axis at day 60 and 95 % confidence limits showed that the range within which the counts at site *C* could become as large as those at site *B* was any time between 24 and 96 days. For individual wounds, the time range during which the counts at site *C* could become as large as the counts at site *B* was estimated to be from 0 to 168 days.

DISCUSSION

Pepper (1954) investigated the part played by melanocytes in wound healing in the guinea-pig and found that in the early stages of healing pigmented melanocytes were always fewer in regenerating epithelium than in normal skin, and they became increasingly sparse towards the advancing edge. At later stages of epithelial advance, the melanocytes were more abundant towards the proximal edge of the wound than towards the advancing tip, but nowhere were they equal to that of normal skin. Pepper did not, however, publish melanocyte counts to support these observations. The peripheral part of the wound was found to reach a normal depth of colour by about 30-35 days post-operatively, and the epithelium over the whole area seemed to gain the normal depth of pigmentation by about 40-45 days post-operatively, when the abundance of melanocytes was found to be the same in sheets

of healed and normal epidermis. Most of Pepper's observations were made on vertical sections stained with haematoxylin and eosin in which melanocytes are distinguishable with certainty only when pigmented. Some specimens were treated with Holmes' alkaline silver technique or subjected to the Dopa reaction.

Breathnach (1960) has made observations on the melanocytes of regenerated epidermis covering fresh scars in a male human subject. He found that melanocytes are present in the proximal regions of the regenerated epidermis covering scars two and three weeks old. The melanocytes were fewer in number than in adjacent normal epidermis (here again no figures were published). They were found to be Dopa and silver positive, and apparently were capable of some cytotrine activity. Towards the central area of the scar, progressively fewer active melanocytes were counted, and in regions furthest removed from the edge, none could be demonstrated. Supravital staining of the epidermis from this latter region failed to reveal the presence of quinone-imine dye positive cells. He was of the opinion that no melanocytes were present in the epidermis in this situation in 2- or 3-week-old scars.

In the present work, a comparison of the morphology of the melanocytes situated in the advancing edge region of the epithelium with that of more proximally situated melanocytes produced some interesting findings. In the advancing edge region, the majority of the melanocytes were situated on the same plane and were of simple structure, having rounded cell bodies with few or no dendritic processes. Little cytotrine activity was evident as shown by the relative absence of free melanin. The orientation of the dendrites in the line of advancement was possibly governed by the migratory process or was due to wound contraction. The presence of rounded melanocytes with no dendritic processes lying close together and discrete or joined by a single band would suggest that cell division was taking place. Mitotic figures were not, however, seen since the presence of melanin would completely hide such figures. Billingham & Silvers (1960) described how melanocytes, when they underwent division, normally retracted their processes.

It was interesting to find that in a few of the animals, the melanocytes near the advancing edge of the epithelium contained a reduced amount of melanin, particularly in the red guinea-pigs. In a number of the black guinea-pigs, the melanocytes in this region appeared to contain more melanin than in the normal surrounding skin, even though their dendrites were absent or short and stumpy and they were surrounded by only a small amount of free melanin.

At the margin of the healing wound, it was seen that the melanocytes developed a more normal appearance the more advanced the healing process became. They had large cell bodies, containing a moderate amount of melanin and possessed long complex dendritic processes which extended out in all directions. The melanocytes were no longer lying in the same plane, but were situated in the newly developed epidermal ridges. The cytotrine activity gradually became normal as shown by the presence of a normal amount of free melanin by about the thirtieth post-operative day.

The melanocyte counts for the different stages of wound healing showed interesting results. The degree of association between the difference in the counts at sites *A* and *B* and time for the black and red animals showed significant negative correlations. The regression line for *A* - *B* crossed the time axis at between days 23 and 35. On the other hand, the negative correlations of the difference in counts at sites *B* and *C*

and time were only significant at the 5 % level when the counts for the black and red animals were taken together. The regression line for *B-C* crossed the time axis between days 24 and 96. The slopes of the regression lines for the black and red animals were not significantly different. It is thus seen that the melanocyte numbers in the healing area reach normality sooner at the wound margin than at the wound centre. The results also show that the melanocyte numbers in the newly formed epidermis at 58 and 70 days after operation exceed those of the normal skin. It would be interesting to know whether this overshoot is temporary or permanent. In this connexion, it might be noted that in a previous experiment it has been shown that simple mechanical irritation of normal skin is capable of raising the melanocyte number above the normal level (Snell, 1962*b*):

When estimating melanocyte numbers in a healing wound, one had to consider the possibility that some of the melanocytes were not counted because they were not visible due to low pigmentary activity. This was unlikely in the present experiment since all the specimens had been subjected to the Dopa reaction and only a few animals possessed melanocytes with such a low pigmentary activity as to make counting difficult. Moreover, Pepper (1954) for the guinea-pig, and Breathnach (1960) for the human subject, have made similar observations and have failed to reveal further melanocytes in the migratory epithelium by using quinone-imine dyes and silver staining. (They did not, however, publish their figures for the counts.) It would thus appear that in the guinea-pig, the number of melanocytes in the newly formed epidermis covering the wound bed during the early stages of healing is lower than in normal skin and is lowest towards the centre of the wound.

Pepper (1954), whilst studying shallow wounds, found that black melanocytes were more numerous than red ones in regenerating epithelium of comparable stages. The counts in the present experiment show that in the normal control skin of the lumbar region (*A*) the great majority of the melanocyte counts for the black animals are greater than for the red. In a previous report (Bischitz & Snell, 1959), it was found that the number of melanocytes in the anterior abdominal wall and areolar skin was significantly higher in black than in red guinea-pigs; a similar tendency was noted in the skin of the ear and sole of foot. It was suggested that the differences between melanocyte counts in the black and red guinea-pig might be due to genetical differences between the two strains not necessarily associated with pigmentation as such. The counts taken at different stages of epithelial migration (*B* and *C*) show that there is no difference between the black and red animals. The regression lines for the black and the red animals were compared and found to be not significantly different.

Pepper (1954) reported that melanocytes begin to migrate over the wound as soon as the Malpighian cells, and that single melanocytes could nearly always be seen to occur right up to the adjoining epithelial edge. Breathnach (1960) believes that this is not necessarily true for the human subject, for he found complete absence of melanocytes in the epidermis over the central area of a 3-week-old scar. He put forward the view that it was possible that melanocytes are capable of migrating into a preformed sheet of Malpighian cells and therefore possess a greater degree of independence than is generally believed. In the present work the melanocytes were never found in advance of the migrating epithelial cells and they were usually found a short distance proximal to the epithelial edge.

The relative initial pallor of the epidermis overlying scar tissue can therefore be attributed to the fact that the melanocytes are few in number and possess a low melanogenic activity. Later the pallor largely disappears and the results of the present experiment would indicate that this is due to a rise in the melanocyte count and to an increased production of melanin. However, the epidermis over a scar will always be slightly paler than the surrounding skin, since the avascular nature of the underlying fibrous tissue reduces the contribution of the blood pigments to normal skin colour.

SUMMARY

1. The appearances of the melanocytes and melanin in a healing deep wound in the thoraco-lumbar region has been studied in forty-two male guinea-pigs, which were either pure black or pure red in colour. A deep wound was prepared in each animal, measuring 4 cm.² and was of such a depth that all the hair follicles were removed. The healing process was studied by killing the animals in groups at intervals, over a period of 70 days. The wound specimens were treated with the Dopa reagent and vertical sections and whole mount preparations were studied.

2. The morphology of the melanocytes, the appearances of the free melanin and melanocyte counts were observed in (A) the skin removed to produce the wound, (B) at the margin of the wound, and (C) at the advancing edge of the epithelial ingrowth.

3. The melanocytes were present within the new covering epithelium as soon as this started to migrate over the wound surface (4-6 days), but they were never found in advance of the Malpighian cells.

4. At the advancing edge of the epithelial ingrowth, the melanocytes varied in size and shape and contained a variable amount of melanin. Most possessed a few simple short dendritic processes, while others had none. Very little free melanin was present in this region.

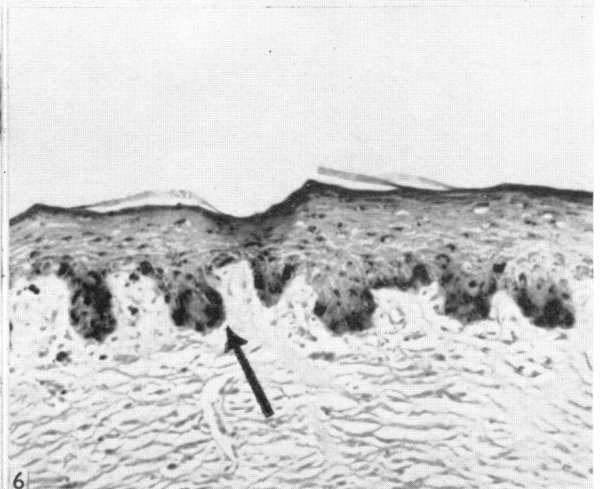
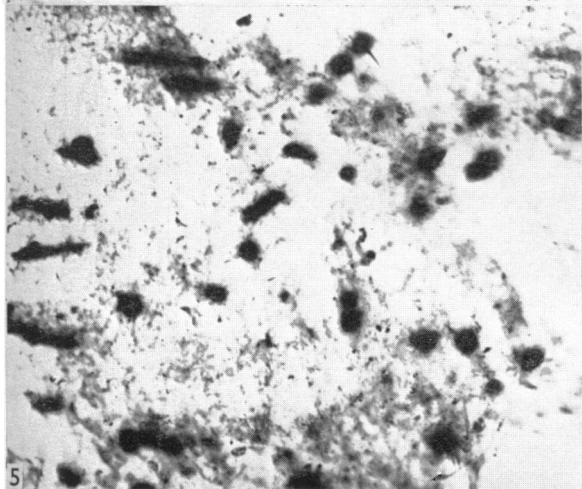
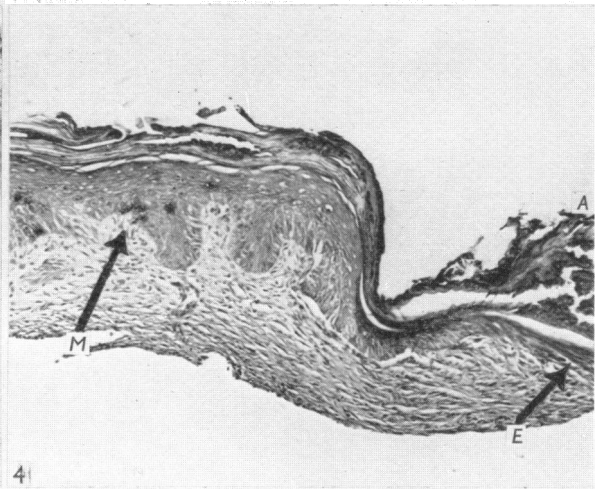
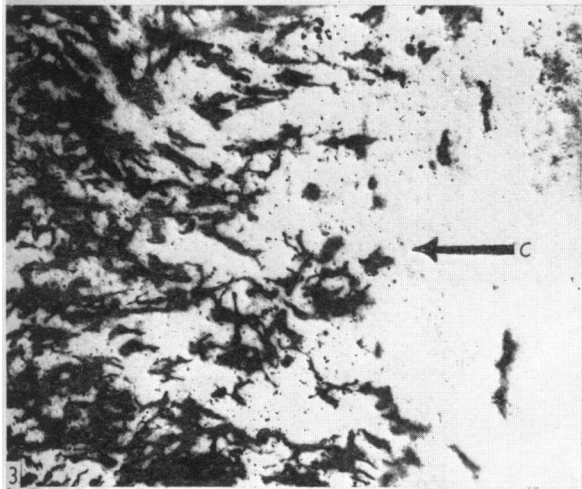
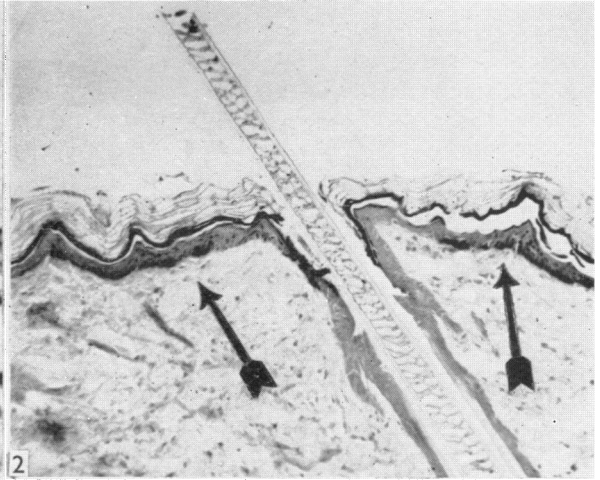
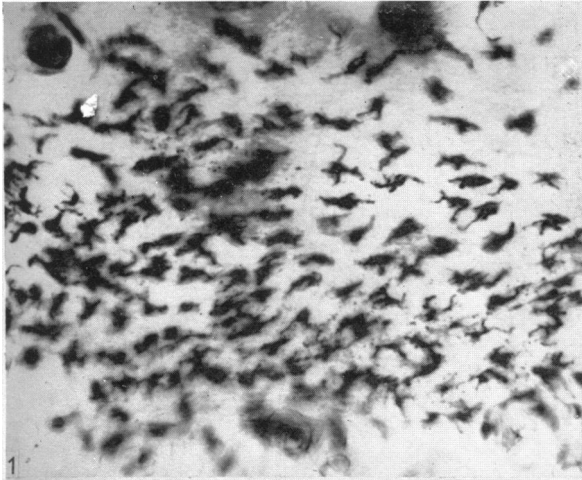
5. At the wound margin at 9 days or later, following the operation, the melanocytes had a normal appearance with long branching dendritic processes and were surrounded by a moderate amount of free melanin.

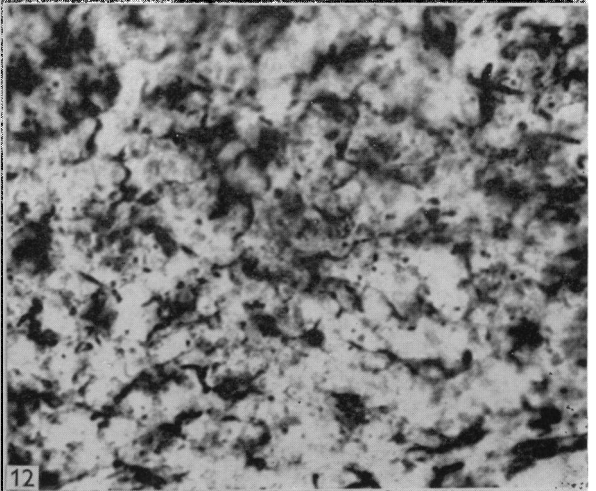
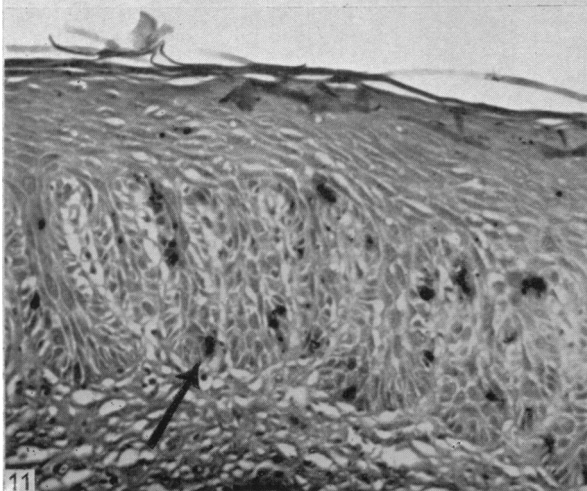
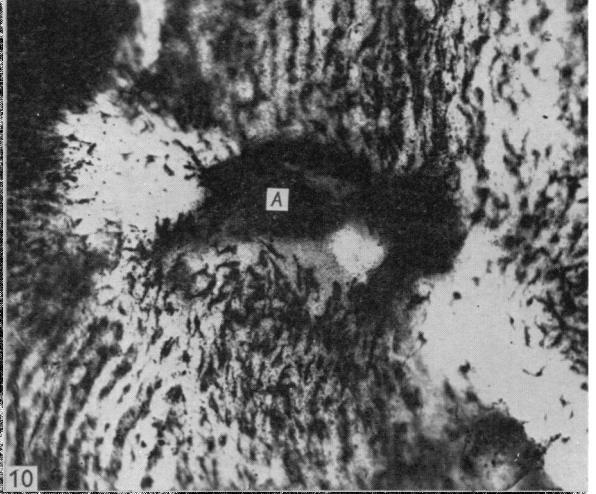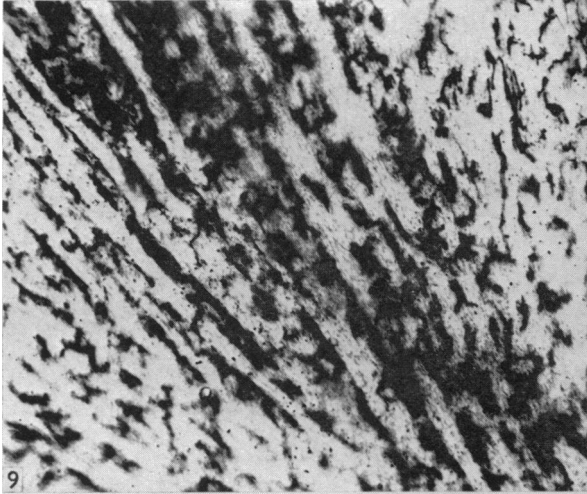

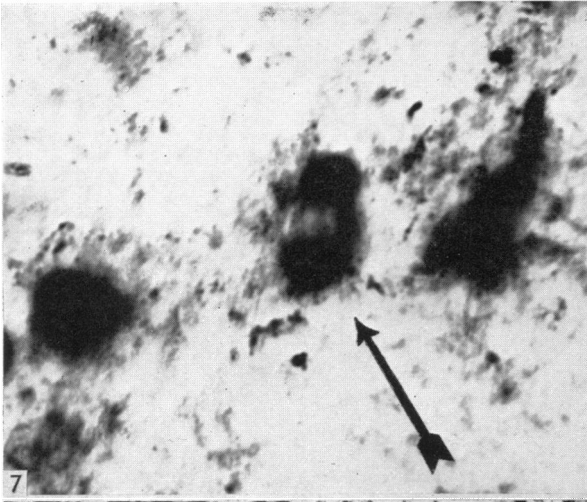
6. The melanocyte counts showed that initially in both the black and red animals the density of the melanocytes was lower in the new epithelial covering, as compared with the normal skin epidermis, being lowest near the advancing epithelial edge. Later, the density of the melanocytes in the epithelial covering rose to exceed that found in the normal surrounding skin.

I gratefully acknowledge financial assistance for this work from the Medical Research Council. I am greatly indebted to Dr D. J. Newell and Mrs D. Weightman of the Department of Industrial Health for their help with the statistical analysis of the melanocyte counts.

REFERENCES

- BILLINGHAM, R. E. & SILVERS, W. K. (1960). The melanocytes of mammals. *Quart. Rev. Biol.* **35**, 1-40.
- BISCHITZ, P. G. & SNELL, R. S. (1959). A study of the melanocytes and melanin in the skin of the male guinea-pig. *J. Anat., Lond.*, **93**, 233-245.
- BREATHNACH, A. S. (1960). Melanocytes in early regenerated human epidermis. *J. Invest. Derm.* **35**, 245-251.





- PEPPER, F. J. (1954). The epithelial repair of skin wounds in the guinea-pig with special reference to the participation of melanocytes. *J. Morph.* 95, 471-499.
- SNELL, R. S. (1962*a*). Further observations on the effect of progesterone on the activity of melanocytes in the skin. *Z. Zellforsch.* 57, 818-826.
- SNELL, R. S. (1962*b*). A study of the effect of chronic irritation on melanogenesis in the skin. *Brit. J. exp. Path.* 43, 581-586.
- SNELL, R. S. & BISCHITZ, P. G. (1960*a*). The effect of large doses of estrogen and estrogen and progesterone on melanin pigmentation. *J. Invest. Derm.* 35, 73-82.
- SNELL, R. S. & BISCHITZ, P. G. (1960*b*). A study of the melanocytes and melanin in the skin of the immature, mature and pregnant female guinea-pig. *Z. Zellforsch.* 51, 225-242.

EXPLANATION OF PLATES

PLATE 1

Fig. 1. Photomicrograph of whole mount preparation of normal skin of lumbar region of red male guinea-pig. Shows melanocytes and melanin to be concentrated in rows which run at right angles to the slope of the hairs. Treated with Dopa reagent. No counterstain. $\times 141$.

Fig. 2. Photomicrograph of vertical section of normal skin of lumbar region of black male guinea-pig. Shows melanocytes to be situated on both sides of the emergent hair and to lie in the basal layer of the epidermis. Treated with Dopa reagent. Counterstained with weak eosin. $\times 117$.

Fig. 3. Photomicrograph of whole mount preparation of wound of black male guinea-pig 16 days after operation. Shows the scattered arrangement of the melanocytes at the advancing edge of epithelial ingrowth (area C). Treated with Dopa reagent. No counterstain. $\times 78$.

Fig. 4. Photomicrograph of vertical section of wound of black male guinea-pig 9 days after operation. The melanocytes (M) in this specimen are lagging behind the advancing epithelial edge (E) which is migrating from left to right in the photograph. A = the scab covering the wound surface. Treated with Dopa reagent. Counterstained with weak haematoxylin and eosin. $\times 78$.

Fig. 5. Photomicrograph of whole mount preparation of wound of black male guinea-pig 12 days after operation. Shows a number of melanocytes in area C with round cell bodies and short, stumpy dendritic processes. Treated with Dopa reagent. No counterstain. $\times 164$.

Fig. 6. Photomicrograph of vertical section of wound of black male guinea-pig 23 days after operation. Shows the wound to be covered with new epithelium and the melanocytes to be situated in the newly formed epidermal ridges. Note the absence of hair follicles and sebaceous glands. Treated with Dopa reagent. Counterstained with haematoxylin and eosin. $\times 163$.

PLATE 2

Fig. 7. Photomicrograph of whole mount preparation of wound of black male guinea-pig 30 days after operation. Shows three melanocytes in area C. One of the melanocytes appears to be undergoing division (arrowed). Treated with Dopa reagent. No counterstain. $\times 613$.

Fig. 8. Photomicrograph of whole mount preparation of wound of black male guinea-pig 16 days after operation. Shows melanocytes in area B having long complex dendritic processes and containing a normal amount of melanin. Note the presence of free melanin between the melanocytes. Treated with Dopa reagent. No counterstain. $\times 134$.

Fig. 9. Photomicrograph of whole mount preparation of wound of black male guinea-pig 30 days after operation. Shows a number of melanocytes arranged in rows which run from the wound margin and converge towards the wound centre. Treated with Dopa reagent. No counterstain. $\times 98$.

Fig. 10. Photomicrograph of whole mount preparation of wound of black male guinea-pig 27 days after operation. Shows the coming together of areas C in the centre of the wound during the later stages of epithelial resurfacing. A = remains of scab at wound centre. Treated with Dopa reagent. No counterstain. $\times 55$.

Fig. 11. Photomicrograph of vertical section of wound (site B) of red male guinea-pig 27 days after operation. Shows the melanocytes (arrowed) to be situated in the sides of the epidermal ridges. Treated with Dopa reagent. Counterstained with weak eosin. $\times 232$.

Fig. 12. Photomicrograph of whole mount preparation of wound of red male guinea-pig 58 days after operation. Shows the arrangement of the melanocytes and free melanin in a completely healed wound. Treated with Dopa reagent. No counterstain. $\times 324$.