

## THE SIGNIFICANCE OF THE 'PERICHONDRIAL ZONE' IN A DEVELOPING LONG BONE OF THE RAT

BY C. W. M. PRATT

*Department of Anatomy, University of Cambridge*

### INTRODUCTION

Ranvier (1873, 1875) described a groove ('encoche d'ossification') in the cartilage at the ends of a growing mammalian long bone which was situated near to its junction with the shaft. Subsequent authors have often referred to Ranvier's ossification groove, but as will be shown later, a phrase of more general application is required, and for this reason the term 'perichondrial zone' will be introduced and employed in this paper. In previous accounts of an ossification groove there have been no descriptions of its early development, nor of the changes occurring in the groove during growth; and what is more surprising, there have been no attempts to define previously what is meant by such a groove.

Some of Ranvier's findings were denied by Schäfer (1878, 1912), who gave a detailed account of an ossification groove. Kollarth (1932), Dahl (1936) and van Wel (1954) described ossification grooves in growing postnatal mammals, but ignored the fibrous architecture and the arrangement of the cells within them. Bausenhardt (1950) described the fibres of a groove as seen by dissection and with polarized light. Langenskiöld (1947) showed how findings in chondrodysplasia may throw light on the normal growth changes occurring in a groove. Langenskiöld & Edgren (1949*a, b*) made similar deductions from the results of local X-ray injury to the epiphysial plate. Lacroix (1949) described a groove in the postnatal rabbit, and summarized his findings of earlier experiments in which he had observed the formation of a groove in transplants of epiphysial cartilage.

The groove is of considerable interest for the connective tissue within it forms a transitional zone between areas of osteogenesis and chondrogenesis. Our knowledge of the growth changes occurring in this region are far from clearly understood, for it is not readily accessible to the experimental methods that are generally used in the study of bone growth. There are several problems which are often ignored: for example, the periosteum is usually described as being inserted in this region, but there is no precise knowledge on this point. The question of appositional growth at the surface of the epiphysial cartilage and epiphysial plate is unsettled. The mode of formation of the extremities of the perichondrial bony collar, and the origin of the extremities of the periosteal bony cylinder, are still debated.

In order to interpret the structure of a groove, it was decided to study the development of the region with special reference to the formation of fibres and their incorporation into specific structures such as bone and cartilage matrix, periosteum, perichondrium, and ligamentous and tendonous attachments. The long bones of the rat proved very suitable in view of their rapid growth and convenient size. The present description is limited to foetal and newborn animals.

## METHODS

Fifteen foetuses of the white rat of known age were obtained from 16 days to birth. The day of finding sperms in the vaginal smear was taken to be day one. The material was fixed in 5% neutral formal-saline, and decalcified in a 10% aqueous solution of the disodium salt of ethylene-diamine-tetra-acetic acid. The hindlimbs were serially sectioned, and stained with Delafield's haematoxylin and eosin, iron haematoxylin and van Gieson, Toluidin blue, or a modification of Long's silver impregnation in which the final stages were omitted.

## OBSERVATIONS

### *(a) On the form and situation of the perichondrial zone*

An examination of the long bones of the hindlimb in a 20-day-old foetus shows that a groove is only seen in certain situations. Thus the presence of a groove is not an essential feature in a growing long bone. Furthermore, a groove can be confined to only one aspect of a cartilage, which contradicts Ranvier's conception of a circular furrow surrounding the cartilage. Sites of well-marked grooves include the proximal tibial cartilage (Pl. 1, fig. 2), and the anterior aspects of the distal femoral and tibial cartilages (Pl. 1, figs. 3, 4). If these grooves are examined certain features are found which are common to all of them.

(1) The groove lies at the level of the junction of the epiphysial cartilage (where the cells are spherical and irregularly arranged) and the diaphysial cartilage (where, prior to maturation, the cells are flattened and regularly orientated with their long axes lying in the transverse plane).

(2) The groove contains the fibres of the perichondrium which are continuous with the fibres of the periosteum.

(3) The diaphysial border of the groove has a gradual slope as there is an increase in the diameter of the diaphysial cartilage at the level of the junction of the proliferative and hypertrophic zones. The groove is therefore adjacent only to the proliferative zone. It contains the osteoblasts concerned in the formation of perichondrial bone.

(4) The epiphysial border projects sharply from the floor of the groove. Most of the fibres of the perichondrium approach the epiphysial cartilage at right angles and penetrate it for variable distances. This border ends abruptly at the level of the attachment of the most superficial fibres of the perichondrium.

In certain situations there appear to be particularly deep grooves, for example adjacent to the neck of the femur and on the posterior aspect of the distal femoral cartilage (Pl. 1, fig. 3). Their depth is due to the extent to which the epiphysial cartilages project out beyond the diaphysial cartilages. Though these areas satisfy the first three criteria of a typical groove, they differ markedly in respect to the fourth, for the fibres of the perichondrium invariably approach the epiphysis obliquely and do not penetrate its substance. The epiphysial border forms a gradual outward curve and continues beyond the point of attachment of the perichondrium. In view of these differences this type of structure will be referred to as a 'false groove'.

Situations presenting the first three features of a typical groove, but without any projection of the epiphysial cartilage, are found in all the long bones whether a groove is present or not. In such places the perichondrium is similar to that of the false groove, that is the fibres approach the epiphysis obliquely and do not enter its substance. Such 'hemi-grooves' are found adjacent to the greater trochanter (Pl. 1, fig. 1), at the distal and proximal ends of the fibula, and at the posterior aspect of the distal end of the tibia (Pl. 1, fig. 4).

It is felt that the term 'ossification groove' should be confined to those situations where a typical groove is found. It is suggested, however, that a more general term should be used to describe this zone, which would be equally applicable to all similar situations including those where no true groove exists. The advantage of such a terminology is that any further changes in the shape of the epiphysial cartilage during growth would not necessitate changes in phraseology with consequent confusion in description. The term 'perichondrial zone' appears to be particularly suitable, as it can be understood to include both the perichondrium and the perichondrial bone.

*(b) On the differentiation of the fibrous structure of the perichondrial zone*

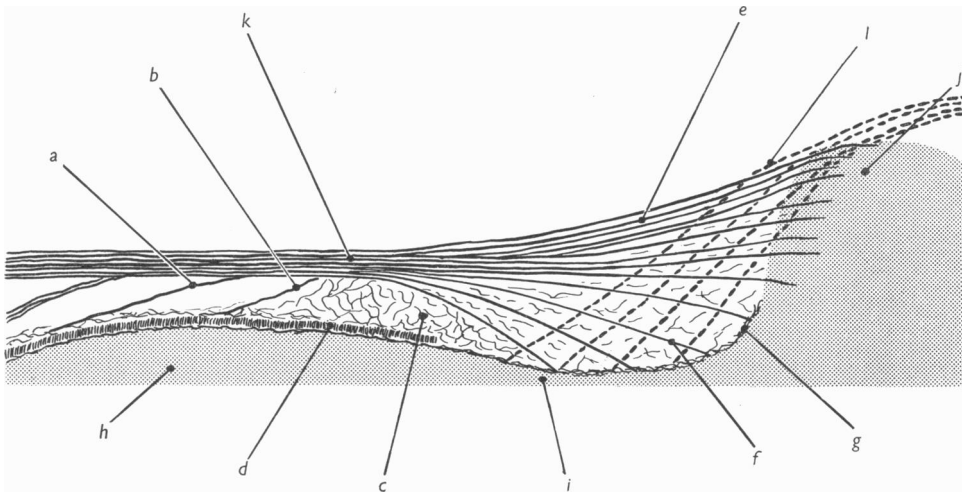
The following account is based on the findings at the distal end of the femur, where anteriorly a typical groove exists, but posteriorly a false groove is formed by the overhanging femoral condyles. The terms periosteum and perichondrium require definition. Both are part of a dense membrane composed of longitudinally running fibres. The term periosteum is used when this is adjacent to bone (i.e. the periosteum surrounds the bony diaphysis), while the term perichondrium is used where this fibrous sheath surrounds the cartilaginous extremity of the bone. It has already been pointed out that in the 20-day-old foetus the extremity of the collar of perichondrial bone lies in the perichondrial zone. Thus the extremities of the perichondrial bone will mark the junction of the periosteum and perichondrium.

In a 17-day-old foetus there is a well-developed sheath of fibres which surrounds the middle of the cartilaginous 'model' of the femur. It is difficult to give a name to this, as it appears before any bone has formed, but nevertheless it marks the zone of preosteoblasts, and therefore it will be referred to as the 'preperiosteum'. The fibres of this structure are coarse, tightly packed, and regularly arranged in a longitudinal direction. At each end it is continuous with the perichondrium. The perichondrium differs in several respects from the preperiosteum. Thus the former membrane consists of a loose irregular network of fine fibres lying in immediate contact with the cartilage, while the preperiosteum is denser, and is separated from the cartilage by the layer of preosteoblasts.

At 18 days the perichondrial bone has appeared and it is possible to define the periosteum. The loose network of fine fibres that previously formed the perichondrium is replaced by coarse longitudinally running fibres. In this and in all later stages it is possible to identify the perichondrium by the loose arrangement of its fibres, in contrast with the fibres of the periosteum which are densely packed.

The epiphysial attachment of the perichondrium is not apparent until the nineteenth day, for the non-articular surface of the epiphysis does not become defined until this stage. It has already been pointed out that the mode of attachment of

the perichondrium to the epiphysis differs in different situations. The perichondrial zone of the anterior aspect of the distal end of the femur has already been defined as a true groove and at 20 days the fibres of the perichondrium may be seen penetrating deeply into the cartilage (Pl. 2, fig. 5), where the fibres appear to break up into bundles of fibrils. Posteriorly the attachment of the perichondrium presents a contrasting picture (Pl. 2, fig. 6). In this situation the fibres of the perichondrium form a superficial network on the surface of the epiphysis, and cannot be traced very far into the cartilage.



Text-fig. 1. A diagram illustrating the arrangement of the fibres of the perichondrial zone as seen in a typical ossification groove. (a) osseous fibre bundle; (b) early osseous fibre bundle; (c) reticulum; (d) perichondrial bone; (e) superficial fibre of bundle of perichondrium; (f) deep fibre bundle of perichondrium; (g) limiting network; (h) hypertrophic zone (of diaphysial cartilage); (i) proliferative zone (of diaphysial cartilage); (j) epiphysial cartilage; (k) periosteum; (l) tendon or ligament fibre bundle. Cartilage stippled. ( $\times 400$ .)

In contrast to the epiphysis, the diaphysial cartilage is sharply demarked from the perichondrial zone. This is due to a fibrillar network which lies immediately adjacent to the diaphysial cartilage. It is apparent at 17 days, and is continuous with the earliest fibres of the developing perichondrial bone. The later perichondrial bone, which consists of short radially directed fibres (Pratt, 1957), is laid down on this fibrillar network (Text-fig. 1). This 'limiting sheath' is illustrated in Pl. 2, figs. 7 and 8, when it may be seen lying on the apparently fibreless cartilage matrix. A similar appearance was seen in sections which had been incubated with hyaluronidase prior to silver impregnation. This was carried out in order to remove any cartilage ground substance that might be obscuring fibres. These findings suggest that it is a definite fibrous limiting sheath rather than an artefact resulting from the leaching out of ground substance from the most peripheral part of the cartilage matrix.

When at 18 days the perichondrium becomes organized into longitudinal bundles of coarse fibres there is to be seen a more loosely fibred area lying deep to the

perichondrium. This area lies between the limiting network of the cartilaginous diaphysis and the perichondrium, and it is continuous with the subperiosteal space. It contains numerous capillaries and an irregular arrangement of very fine fibres. However, by 20 days this zone has increased considerably in depth and two types of organized bundles of fibres have appeared. First, there are bundles of fibres which blend with the fibrous limiting sheath of the diaphysial cartilage, but do not enter the cartilage matrix (Pl. 2, figs. 7, 8). These pass obliquely towards the middle of the bone and join the fibres of the periosteum (Text-fig. 1). Such fibres form the deep part of the perichondrium, and by the 23rd day are found throughout the zone as far as the commencement of the subperiosteal space (Text-fig. 2). There is, however, in certain situations, another type of fibre bundle; this also is attached to the fibrous limiting sheath, but it passes obliquely towards the epiphysis, that is in the opposite direction to the first type of fibre (Pl. 2, fig. 7). In those situations, where the second type of fibre bundle is seen, a lattice effect results (Text-fig. 1). These fibres that are directed towards the epiphysis are invariably found to be continuous with the fibre bundles of a tendon or ligament, and thus may be interpreted as the fibres of attachment of ligaments or tendons.

Irregularly arranged fine fibre bundles are always to be found between the mature osteoblasts. By the 21st day longitudinally running fibre bundles have appeared in the subperiosteal space of the perichondrial zone, which are continuous with the trabeculae or periosteal bone. These fibres pass obliquely towards the epiphysis and join the fibre bundles of the periosteum. There can be no confusion of these osseous fibre bundles with the deep fibre bundles of the perichondrium, because of the difference in their direction. The osseous fibre bundles must be formed within the subperiosteal space of the perichondrial zone, and their formation must be associated with osteoblasts, as these are the only cells found in close relation to them. Their formation can easily be followed (Text-fig. 1), commencing with the fine reticulum seen between the most distal osteoblasts (Pl. 2, fig. 9), which gradually becomes thicker and gains attachment to the fibres of the periosteum, and finally becomes elongated and reinforced (Pl. 2, fig. 10). There are, of course, the fibres of attachment of tendons or ligaments which present similar appearances to the osseous fibre bundle as all run in the same direction. The tendon and ligament fibre bundles, however, appear much earlier in development, are confined to specific situations and if attached to bone are inserted into the perichondrial bone rather than the periosteal trabeculae. In due course both the ligament and the tendon fibre bundles may become incorporated into trabeculae of periosteal bone.

*(c) On the differentiation of the cellular structure of the perichondrial zone*

The terminology suggested by Pritchard (1952) will be used in this account of the distal end of the femur. The cells found adjacent to the epiphysial cartilage will be referred to as perichondrial fibroblasts and prechondroblasts, and the cells adjacent to bone as periosteal fibroblasts, preosteoblasts and osteoblasts. There is, however, no accepted terminology for the cells found in the perichondrial zone, and because of the uncertain potentiality of these cells they will be referred to as perichondrial connective tissue cells.

In a 16-day-old embryo the perichondrial connective tissue cells form a closely

packed zone. These cells are irregular in form, have little cytoplasm and a darkly staining nucleus (Pl. 3, figs. 11, 12). This zone merges imperceptibly into the cartilage model. The cells of the cartilage model (chondroblasts), in contrast to the perichondrial connective tissue cells, have pale staining nuclei, more cytoplasm and are separated by dense intercellular substance. The chondroblasts are irregularly arranged in the epiphysis but are orientated along transversely running arcs in the diaphysis, the junction between these two cartilages lies adjacent to the zone of perichondrial connective tissue cells. The perichondrial connective tissue cells are continuous with the surrounding, but more loosely packed, mesenchymal cells. The former are continuous towards the interzone with the prechondroblasts that lie adjacent to the epiphysal cartilage. These latter cells form a layer of closely packed rounded cells separated by fine argyrophilic fibres. Towards the middle of the cartilage model the perichondrial connective tissue cells are continuous with the layer of elongated cells that lie adjacent to the cartilaginous diaphysis. The latter cells will differentiate into the cells of the periosteum.

A rapid increase in the matrix separating the cells of the diaphysal cartilage now occurs, and this leads to a clear demarcation of the cartilage and the perichondrium. The floor of the perichondrial zone becomes defined; and at the same time the curvature of the floor appears in the posterior part of the zone, i.e. on the back of the femur. The perichondrial connective tissue cells remain densely packed anteriorly, and by 19 days they are limited externally by a zone of perichondrial fibroblasts, which are flattened cells with oval nuclei. It is not possible to say whether these fibroblasts have arisen from the perichondrial connective tissue cells, or from the surrounding mesenchyme. In the posterior part of the perichondrial zone (a false groove) there is no evidence of perichondrial fibroblasts and the perichondrial connective tissue cells are very loosely arranged (Pl. 3, fig. 13). Numerous capillaries lie in this loose connective tissue.

Anteriorly a typical ossification groove has differentiated by 20 days, produced by overgrowth of the epiphysal border of the perichondrial zone (Pl. 3, fig. 14). The increase in the depth of the zone of perichondrial connective tissue cells has resulted in a more loosely arranged tissue. However, the external zone of perichondrial fibroblasts is closely packed and its cells, which show numerous mitotic figures, have become very elongated, and are now indistinguishable from the periosteal fibroblasts. The arrangement of the fibres of the perichondrium is no doubt associated with the laminated structure of this tissue. The epiphysal prechondroblasts which are adjacent to the perichondrial connective tissue also have a laminated arrangement.

It should be pointed out that in situations where the perichondrial zone is in the form of a hemigroove, the cellular structure of the latter resembles the early stage of a typical ossification groove where the perichondrial connective tissue is dense, but not laminated, and has an outer layer of perichondrial fibroblasts.

The differentiation of the osteoblasts found in the perichondrial zone requires further comment. At 17 days the preosteoblasts are confined to the middle of the diaphysal cartilage and are separated from the perichondrial connective tissue cells by a zone of closely packed elongated cells. These latter cells appear to differentiate into preosteoblasts, and then into osteoblasts. The osteoblasts gradually approach

the perichondrial zone, reaching the level of the junction of the hypertrophic and proliferative zones of the diaphysial cartilage at 18 days, and attaining their final extent at 20 days, when they reach the level of the middle of the proliferative zone. By this stage the osteoblasts form a deep and closely packed layer, and remain as such until birth.

Mitotic figures are seen in the perichondrial zone amongst the perichondrial connective tissue cells, perichondrial fibroblasts, prechondroblasts, periosteal fibroblasts, and preosteoblasts. Such mitotic figures appear to be randomly distributed, and are more numerous in the early stages than in the late ones. The greatest mitotic activity is seen at 19 days, the significance of which will be discussed later.

#### DISCUSSION

##### *The structure of the perichondrial zone and the growth of the bone*

It has been shown that at the distal end of the femur the differentiation of the perichondrial zone closely follows the differentiation of the epiphysial and diaphysial cartilages. It is to be expected therefore that the growth of the cartilages will also influence the structure of the perichondrial zone, and this requires comment.

It is convenient to consider the growth of the cartilage in two phases. There is an early phase lasting up to the 19th day during which the cartilage becomes increasingly demarcated from the surrounding tissues, and elongation of the bone is largely a result of changes occurring in the middle of the cartilaginous diaphysis. During the later phase, which occurs after the appearance of a medullary cavity, the elongation of the bone results from changes occurring in the diaphysial cartilages, at the extremity of the shaft. The histological details of these processes will be described elsewhere, and in this discussion it will be assumed that the elongation of the diaphysis is chiefly due to the enlargement of its cartilage cells.

During the early phase of growth the cartilaginous boundaries of the perichondrial zone become defined. As the elongation of the diaphysial cartilage occurs principally in its middle portion it means that the cartilaginous boundaries of the perichondrial zone, though migrating, are not elongating to any extent. The over-all elongation of the bone must, however, effect the fibres of the perichondrium, and it is interesting to note that these become organized into fibre bundles about this time. Though little elongation is occurring in the cartilage adjacent to the perichondrial zone there is, however, some increase in width, particularly in the region of the junction of the proliferative and the hypertrophic zones. The differentiation of the perichondrial zone osteoblasts follows the appearance of this 'diaphysial eminence', and the two features remain associated (probably because hypertrophic cartilage induces the differentiation of osteoblasts).

In the later phase of the growth of the distal femoral cartilage the elongation is occurring principally in the region of the junction of the proliferative and the hypertrophic zones of the diaphysial cartilage. Thus the part of the perichondrial zone lying adjacent to the 'diaphysial eminence' will be undergoing considerable elongation and is due to become incorporated into the bony diaphysis. The remaining portion of the perichondrial zone will be relatively static in terms of longitudinal growth, although the circumference will be increasing. It is not unreasonable to

suggest that the cellular contents of the perichondrial zone will follow any growth changes in the adjacent cartilage. Thus the perichondrial connective tissue cells will form a zone which is being stretched transversely, but not elongated, except for the possible influence of the fibres of the perichondrium. In contrast to this the osteoblasts form a zone which will be stretched both transversely and longitudinally.

*The interpretation of the fibrous structure of the perichondrial zone*

The original account of the structure of an ossification groove by Ranvier (1873) was not illustrated. He described curved fibres ('fibres arciformes') passing from the epiphysal cartilage to the bone of the diaphysis. Two years later (1875) he described these fibres again and used for his illustration the calcaneum of the dog, and showed that these fibres were concave towards the epiphysis. Schäfer (1878) questioned Ranvier's findings and described linear 'longitudinal osteogenic fibres' passing from the epiphysis to the bone of the diaphysis. There is little doubt that these linear fibres correspond to the longitudinally arranged fibres of the perichondrium which have been seen in the rat. Schäfer also observed some other fibres in an ossification groove which crossed the longitudinal fibres, and which he thought might become 'perforating fibres'. Similar fibres have been seen in certain situations in the rat where there is no doubt that they are the fibres of attachment of tendons or ligaments. The direction of these fibres is similar to that of the 'fibres arciformes' described by Ranvier and therefore it is likely that he was observing the attachment of the tendo calcaneus. Lacroix (1949) described an ossification groove in the region of the anterior tubercle of the tibia in a postnatal rabbit, and he distinguishes between the periosteal fibres and the fibres of attachment of the ligamentum patellae.

Ranvier (1873) described the 'fibres arciformes' as being continuous with the matrix of the cartilage. It has been possible to confirm this in both the case of epiphysal attachments of tendons and the epiphysal attachment of the perichondrium. Schäfer (1878), however, claimed it to be exceptional to find the longitudinal fibres penetrating the cartilage. These different findings are explained by the two modes of perichondrial attachment seen in the rat, namely the deeply penetrating parallel fibres, or the more superficial lattice-like arrangement. Dahl (1936) and Policard (1941) believed that the fibres of the perichondrium were formed by the cartilage cells of the epiphysis rather than being preformed and later incorporated into the epiphysis. Neither author, however, described the arrangement of these fibres. The relation of the deep perichondrial fibres and the tendon fibres to the cartilage forming the floor of the perichondrial zone has not been understood in the past. The present investigation shows that they blend with a fibrous limiting network which has not been previously described.

*The relation of the fibres of the perichondrial zone to bone matrix*

Most if not all of the accounts in the past have assumed that the fibres found in the perichondrial zone will become incorporated in due course into bone matrix. Weidenreich (1930) described longitudinal fibres in the matrix of the perichondrial bone of the human foetal femur which he claimed were continuous with the 'fibres arciformes'. The early perichondrial bone of the rat consists of longitudinally arranged fibre bundles. It was possible to trace these fibres into the perichondrial



zone where they were found to be continuous with the limiting network of the floor of the groove, and thus were not directly continuous with 'fibres arciformes'; likewise the late perichondrial bone had no extraneous fibres incorporated into its matrix unless tendon fibres were attached to the underlying fibre network.

The early embryonic woven bone, which is the only periosteal bone formed up to the 20th day, does not reach the perichondrial zone, and there is no question of adventitious fibres being incorporated into it. The late periosteal bone, consisting of needle-like trabeculae, contains coarse longitudinal fibre bundles. These osseous fibre bundles first appear in the subperiosteal space as a fine fibrous connexion between the perichondrial bone and the deep surface of the periosteum. Later they become elongated and thickened. These changes are to be expected because the bone and periosteum elongate in a different manner. The bone elongates by addition to its extremities in the region of the diaphysial cartilage, while the periosteum elongates equally throughout its length, as shown by the experiments of Warwick & Wiles (1934) and Lacroix (1948). In this connexion it is interesting to note that these needle-like trabeculae do not commence to form until the bone growth is confined to the extremities. It is not possible therefore to accept Schäfer's (1878, 1912) description of the 'longitudinal osteogenic fibres', if by this term he meant the fibres of the perichondrium. For he described these fibres as passing into the substance of the periosteal bone.

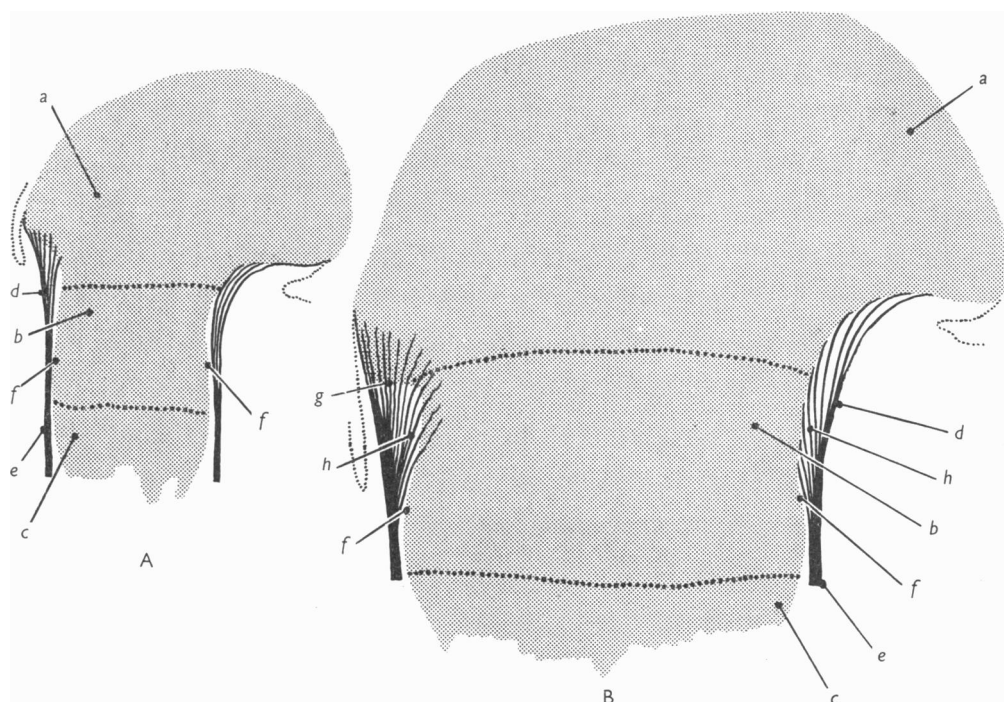
Ranvier (1873, 1875) described the 'fibres arciformes' entering the substance of the periosteal bone. If by 'fibre arciformes' he meant tendon attachments, and by periosteal bone he meant late periosteal bone, then we can agree with these findings. The same comment applies to the accounts of van der Stricht (1889) and Weidenreich (1930). It is significant that all these workers were describing situations where one would expect to find tendon or ligament attachments. Lacroix (1949) pointed out that the state of affairs found in the anterior part of the proximal groove of the rabbit's tibia was unlike that found in other places. Here the fibres of the ligamentum patellae became incorporated into plaques of periosteal bone. Ranvier (1873) described the 'fibres arciformes' as only partially incorporated into bone matrix. This was confirmed by van der Stricht (1889) in the tibia of the calf, but is not seen in the rat, and it may well be a finding that is confined to larger mammals.

#### *The origin and fate of the cells of the perichondrial zone*

The perichondrial connective tissue cells have been occasionally described in the past, but their origin has never been considered. Ranvier (1873) described longitudinal rows of cells in his account of an ossification groove. Most subsequent workers have been content with this brief description but Lacroix (1949) described fine connective tissue cells which continued to divide, and van Wel (1954) referred to a loose connective tissue. It has not been appreciated in the past that the cellular arrangement in the perichondrial zone changes with development, and varies from one situation to another.

Schäfer (1878, 1912), Kollath (1932) and Lacroix (1949) believed that the cells found in the ossification groove differentiated into cartilage cells which became incorporated into the epiphysial cartilage. These views were not backed by any substantial observations and have frequently been denied by workers such as Dahl

(1936), who supported the original suggestion of Ranvier (1873, 1875), which was that the cells of the ossification groove were actually derived from the cartilage by a process of chondrolysis. Similar views were held by Langenskiöld (1947) and Langenskiöld & Edgren (1949*a, b*), who thus interpreted the findings in Ollier's disease, and in a similar condition in rabbits induced by local X-ray injury, where a peripheral defect in the epiphysial plate is repaired by growth from within the cartilage. Van Wel (1954), however, believed that the cells found in the ossification groove were neither derived from cartilage cells nor did they give rise to them.



**Text-fig. 2.** Longitudinal sections through the distal femoral cartilage at 19 days (A) and 23 days (B) showing the changes that occur in the perichondrial zone. Note the migration of the epiphysial lip in the anterior part of the zone (g) and the increase in the deep fibres of the perichondrium (h). ( $\times 96$ .) (a) epiphysial cartilage; (b) proliferative zone (of diaphysial cartilage); (c) hypertrophic zone (of diaphysial cartilage); (d) perichondrium; (e) periosteum; (f) distal extent of osteoblasts.

The present account shows that in the early stages the perichondrial connective tissue cells pass imperceptibly into the zone of prechondroblasts which surround the epiphysial cartilage, but this in itself does not prove that chondrogenesis is occurring. However, the later incorporation of the perichondrial fibre bundles into the substance of the epiphysial cartilage does suggest that chondrogenesis is taking place. The most convincing evidence in support of chondrogenesis is the changes that occur during the late foetal life in the anterior part of the perichondrial zone at the distal end of the femur (Text-fig. 2). At 19 days the epiphysial border of the anterior part of the perichondrial zone lies at the same level as that of the posterior

part. However by the 23rd day the anterior epiphysial border appears to have migrated towards the centre of the bone and now lies at the level of the junction of the epiphysial and diaphysial cartilages. It would thus appear that this extension of the epiphysial cartilage results from a direct transformation of the perichondrial connective tissue cells into cartilage cells, and this is supported by the progressive incorporation of the perichondrial fibre bundles into the cartilage. It is therefore suggested that appositional cartilage growth occurs by the differentiation of the perichondrial connective tissue cells into cartilage cells and that it is particularly marked in those situations where a typical ossification groove exists.

The question now arises—can the perichondrial connective tissue cells differentiate into osteoblasts? Ranvier (1873, 1875), Langenskiöld (1947) and Langenskiöld & Edgren (1949 *a, b*) believed the cells of the ossification groove to be an intermediate stage between chondroblast and osteoblast. Van Wel (1954) believed that these cells were entirely osteoblastic. From what has already been said about the growth processes occurring in the cartilage adjacent to the osteoblastic zone, it would appear that the osteoblasts might soon become exhausted if they are not replaced. There is however no evidence of the former, and at the same time there is little mitotic activity in any part of the zone after 19 days. The perichondrial connective tissue cells become increasingly loosely packed after 19 days, and this is associated with an increase in the capillaries of the area. The former finding could be taken to be that the perichondrial connective tissue cells are migrating into the osteoblastic zone and undergoing differentiation; alternatively the loss of cellular density may be attributed to the increasing depth and circumference of the perichondrial zone. Thus the available evidence suggests that the perichondrial connective tissue cells may differentiate into osteoblasts, but the evidence is not conclusive.

#### SUMMARY

1. The perichondrial zone is defined in the long bones of the hindlimb of the prenatal rat. It includes Ranvier's ossification groove, and other similar areas.
2. The differentiation of the fibres of the perichondrium at the distal end of the femur is described. Attention is drawn to the differences in the mode of attachment of the fibres of the perichondrium to the epiphysial cartilage.
3. The fibres found in the subperichondrial spaces are: (*a*) the deep fibres of the perichondrium, (*b*) the fibres of attachment of tendons or ligaments, (*c*) fine reticular fibres, and (*d*) those of the limiting network which lines the floor.
4. Coarse longitudinal fibre bundles arise *de novo* in the subperiosteal space and are incorporated into bone.
5. The arrangement of the perichondrial connective tissue cells at the distal end of the femur of the prenatal rat is described, and their differentiation is discussed. There is evidence that chondrogenesis takes place in the perichondrial zone.
6. The structure of the tissues of the perichondrial zone is discussed in relation to growth of the bone. It is suggested that the subperichondrial tissues are little affected by longitudinal growth.

The author is grateful to Professor J. D. Boyd for helpful criticism. He is also indebted to Mr J. W. Cash and Miss C. J. Hitchins for technical assistance and to Mr J. F. Crane for the photography.

#### REFERENCES

- BAUSENHARDT, D. (1950). Vergleichend-anatomische Untersuchungen über die Encoche d'ossification. *Verh. anat. Ges. Jena*, **48**, 223-230.
- DAHL, B. (1936). De l'effet des rayons X sur les os longs en développement et sur la formation de cal. Étude radiobiologique et anatomique chez le rat. *Skr. norsk. Vidensk.-Acad. Mat. Nat. Klas.* **1**, 1-149.
- KOLLARTH, W. (1932). Das Wachstumsproblem und die Frage des Zellersatzes in der Vitaminforschung. 11 Mitteilung: Vom normalen Wachstumsvorgang in der Rattenrippe (Histologische Grundlagen der Vitaminversuche). *Arch. exp. Path. Pharmak.* **167**, 478-506.
- LACROIX, P. (1948). Le mode de croissance du périoste. *Arch. Biol., Paris*, **59**, 379-390.
- LACROIX, P. (1949). Origine, structure et valeur de l'encoche d'ossification de Ranvier. *Bull. Histol. Tech. micr.* **18**, 156-169.
- LANGENSKIÖLD, A. (1947). Normal and pathological bone growth in the light of the development of cartilagenous foci in chondrodysplasia. *Acta chir. Scand.* **95**, 367-386.
- LANGENSKIÖLD, A. & EDGREN, N. (1949a). The growth mechanism of the epiphysial cartilage in the light of experimental observations. *Acta orthopaed. Scand.* **19**, 19-24.
- LANGENSKIÖLD, A. & EDGREN, W. (1949b). Imitation of chondrodysplasia by localised Roentogen ray injury—an experimental study of bone growth. *Acta chir. Scand.* **99**, 253-273.
- POLICARD, A. (1941). *L'appareil de croissance des os longs ses mécanismes à l'état normal et pathologique*. Paris: Masson et Cie.
- PRATT, C. W. M. (1957). Observations on osteogenesis in the femur of the foetal rat. *J. Anat., Lond.*, **91**, 533-544.
- PRITCHARD, J. J. (1952). A cytological and histochemical study of bone and cartilage formation in the rat. *J. Anat., Lond.*, **86**, 259-277.
- RANVIER, L. (1873). Quelques faits relatifs au développement du tissu osseux. *C.R. Acad. Sci., Paris*, **77**, 1105-1109.
- RANVIER, L. (1875). *Traité technique d'histologie*. Paris: F. Savy.
- SCHÄFER, E. A. (1878). Notes on the structure and development of osseous tissue. *Quart. J. micr. Sci.* **18**, 132-141.
- SCHÄFER, E. A. (1912). *Textbook of Microscopic Anatomy. Quain's Elements of Anatomy*. 11th ed. vol II, part 1. London: Longmans.
- STRICHT, O. VAN DER (1889). Recherches sur la structure de la substance fondamentale du tissu osseux. *Arch. Biol., Paris*, **9**, 27-51.
- WARWICK, W. T. & WILES, P. (1934). Growth of periosteum in longbones. *Brit. J. Surg.* **22**, 169-174.
- WEIDENREICH, F. (1930). *Das Knochengewebe*. In *Handbuch der Mikroskopischen Anatomie des Menschen*. Band 2, Teil 2. (Ed. W. von Mollendorff.) Berlin: Julius Springer.
- WEL, J. P. W. T. VAN (1954). *Bijdrage tot de kennis van de groei der beenderen en de rol daarbij door de encoche d'ossification van Ranvier gespeeld*. Utrecht: Drukkerij Vims.

## EXPLANATION OF PLATES

Figs. 1–14 show longitudinal sections of the perichondrial zone in the hindlimb of foetal rats. The sections illustrated by figs. 1–10 have been impregnated with silver using an abbreviated Long's method, while figs. 11–14 show sections that have been stained with haematoxylin and eosin.

## PLATE 1

The extent of the perichondrial zone is indicated by arrows. (*a*) epiphysial cartilage; (*b*) proliferative zone (diaphysial cartilage); (*c*) hypertrophic zone (diaphysial cartilage); (*d*) perichondrium; (*e*) periosteum; (*f*) perichondrial bone; (*g*) periosteal bone. ( $\times 48$ .)

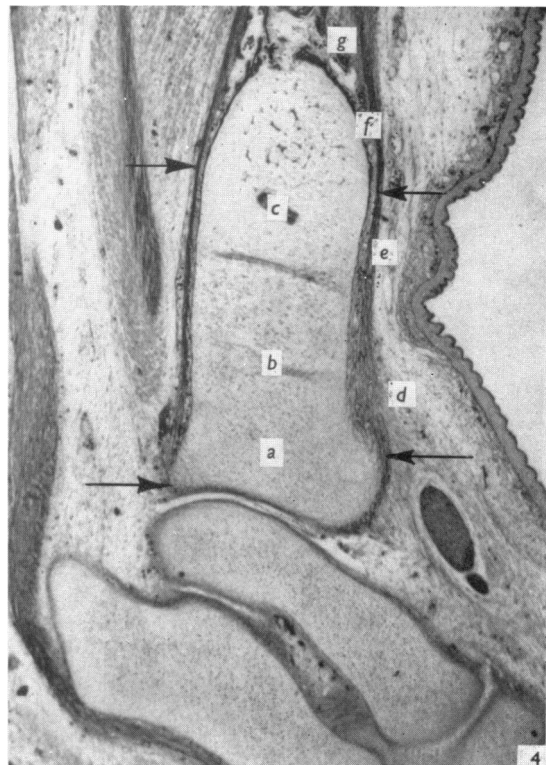
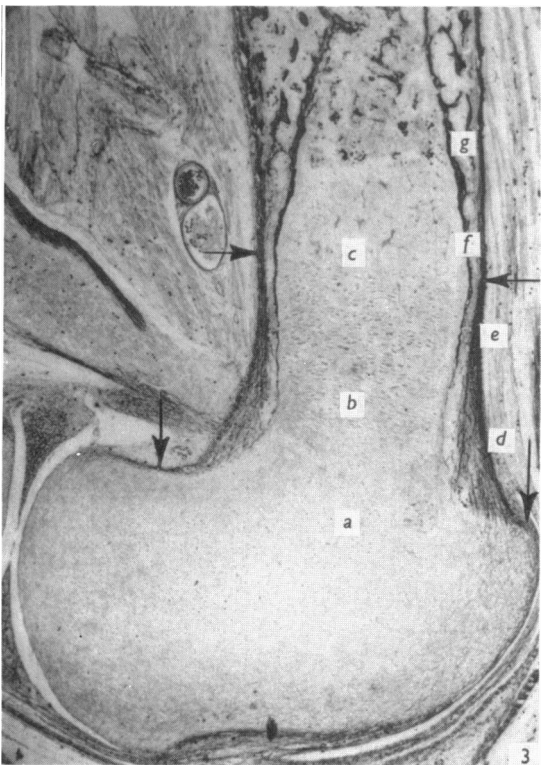
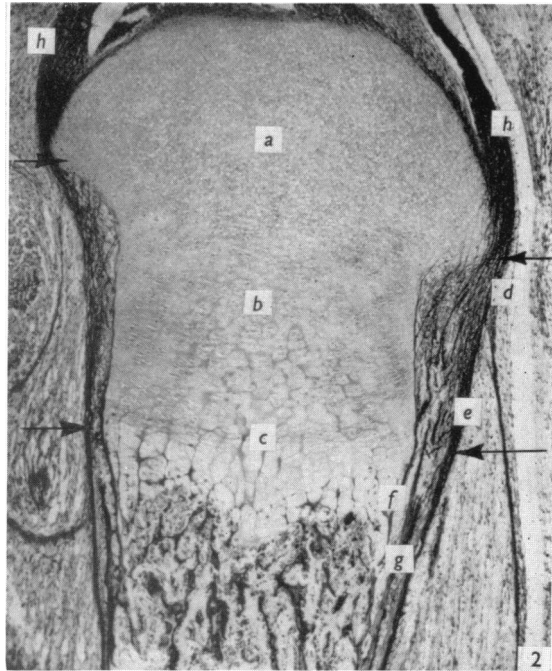
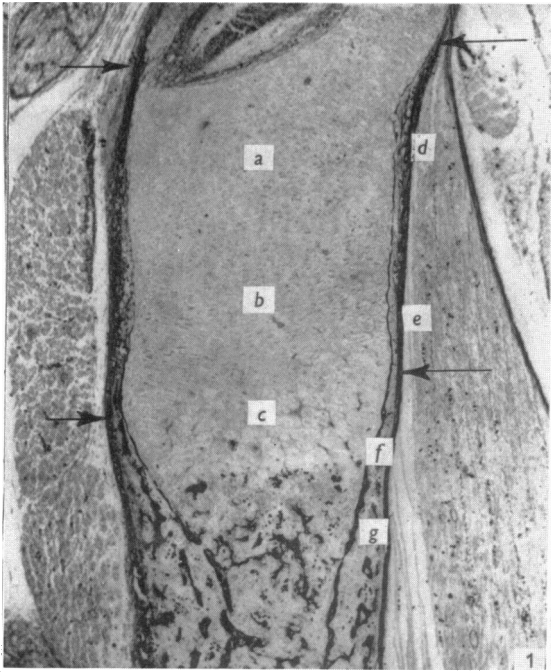
- Fig. 1. Proximal end of femur (20 days) which shows a hemigroove on both aspects.  
 Fig. 2. Proximal end of tibia (22 days) which has a typical ossification groove on both aspects. Note the ligaments (*h*) passing into the perichondrial zone.  
 Fig. 3. Distal end of femur (20 days) which shows a typical ossification groove anteriorly (to the right) and a false groove posteriorly (to the left).  
 Fig. 4. Distal end of tibia (20 days) which has a typical ossification groove anteriorly (to the right) and a hemigroove posteriorly (to the left).

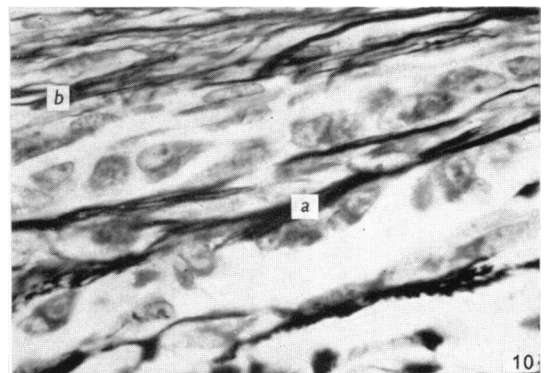
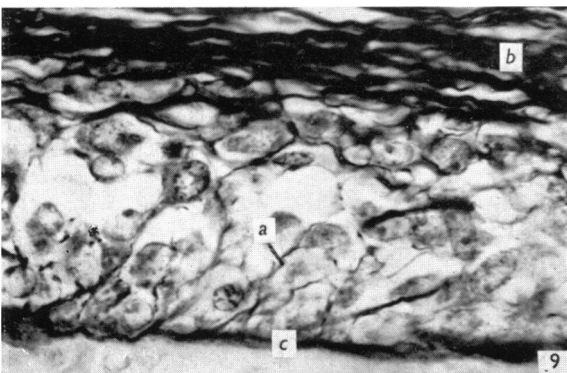
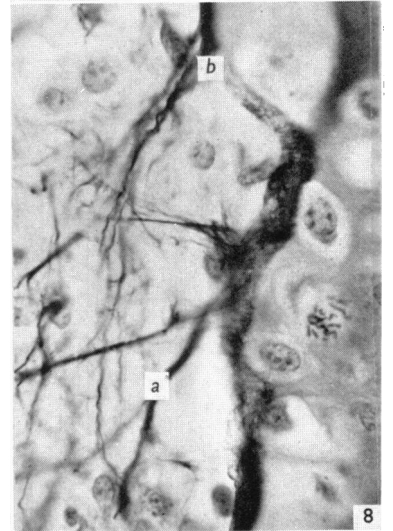
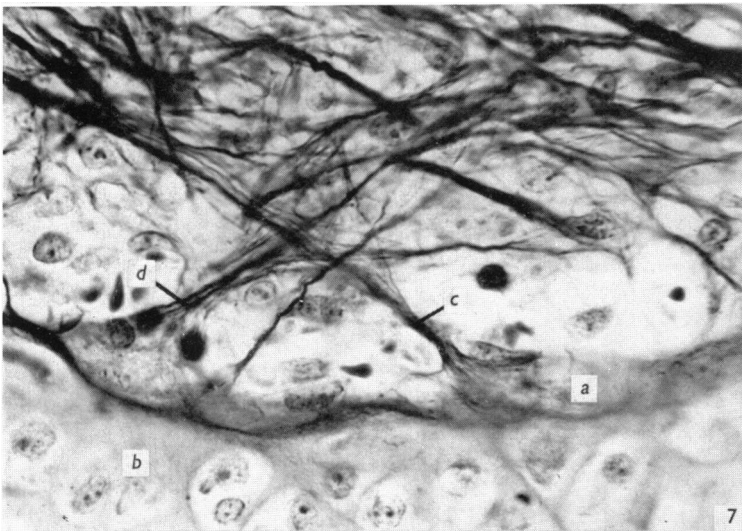
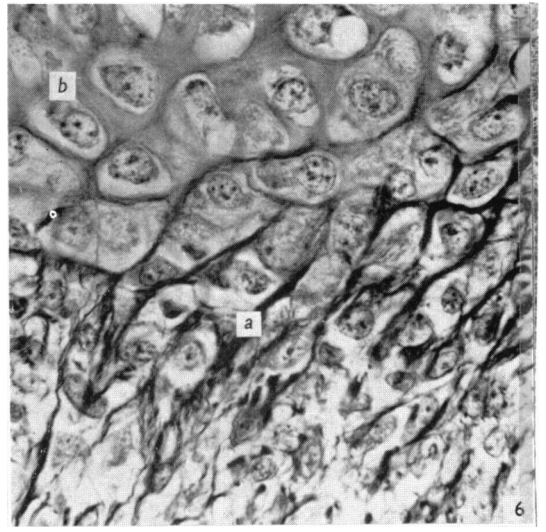
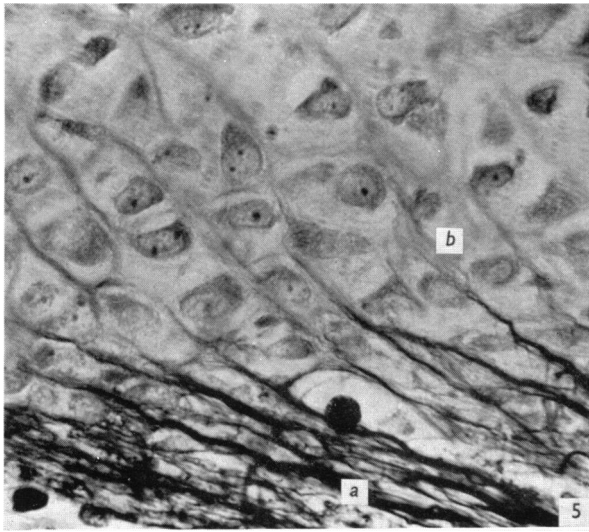
## PLATE 2

- Fig. 5. The epiphysial lip of the anterior part of the distal femoral perichondrial zone at 20 days. Note the linear fibre bundles (*a*) of the perichondrium entering the epiphysial cartilage (*b*). ( $\times 780$ .)  
 Fig. 6. The epiphysial lip of the posterior part of the distal femoral perichondrial zone at 21 days, showing the relation of the perichondrial fibres (*a*) to the cartilage matrix (*b*) of the epiphysis. ( $\times 780$ .)  
 Fig. 7. The floor of the posterior part of the proximal tibial perichondrial zone at 22 days, showing the limiting network (*a*) ensleeving the cartilage of the diaphysis (*b*). Note the decussation of the deep perichondrial fibres (*c*) and the fibres of the posterior cruciate ligament (*d*), both are blending with the limiting network. ( $\times 780$ .)  
 Fig. 8. The floor of the posterior part of the proximal tibial perichondrial zone at 22 days, showing the deep perichondrial fibres (*a*) blending with the limiting network (*b*). There are no tendon or ligament fibres in this region. ( $\times 780$ .)  
 Fig. 9. The diaphysial extremity of the posterior part of the proximal perichondrial zone of the tibia at 22 days, showing the subperiosteal reticulum (*a*) lying between the osteoblasts. These fibres are in contact with both the fibre bundles of the periosteum (*b*) and the perichondrial bone (*c*). ( $\times 780$ .)  
 Fig. 10. The posterior extremity of the bony diaphysis of the tibia at 22 days, showing the coarse osseous fibre bundles (*a*). These bundles are distinct from the fibres of the periosteum (*b*). ( $\times 780$ .)

## PLATE 3

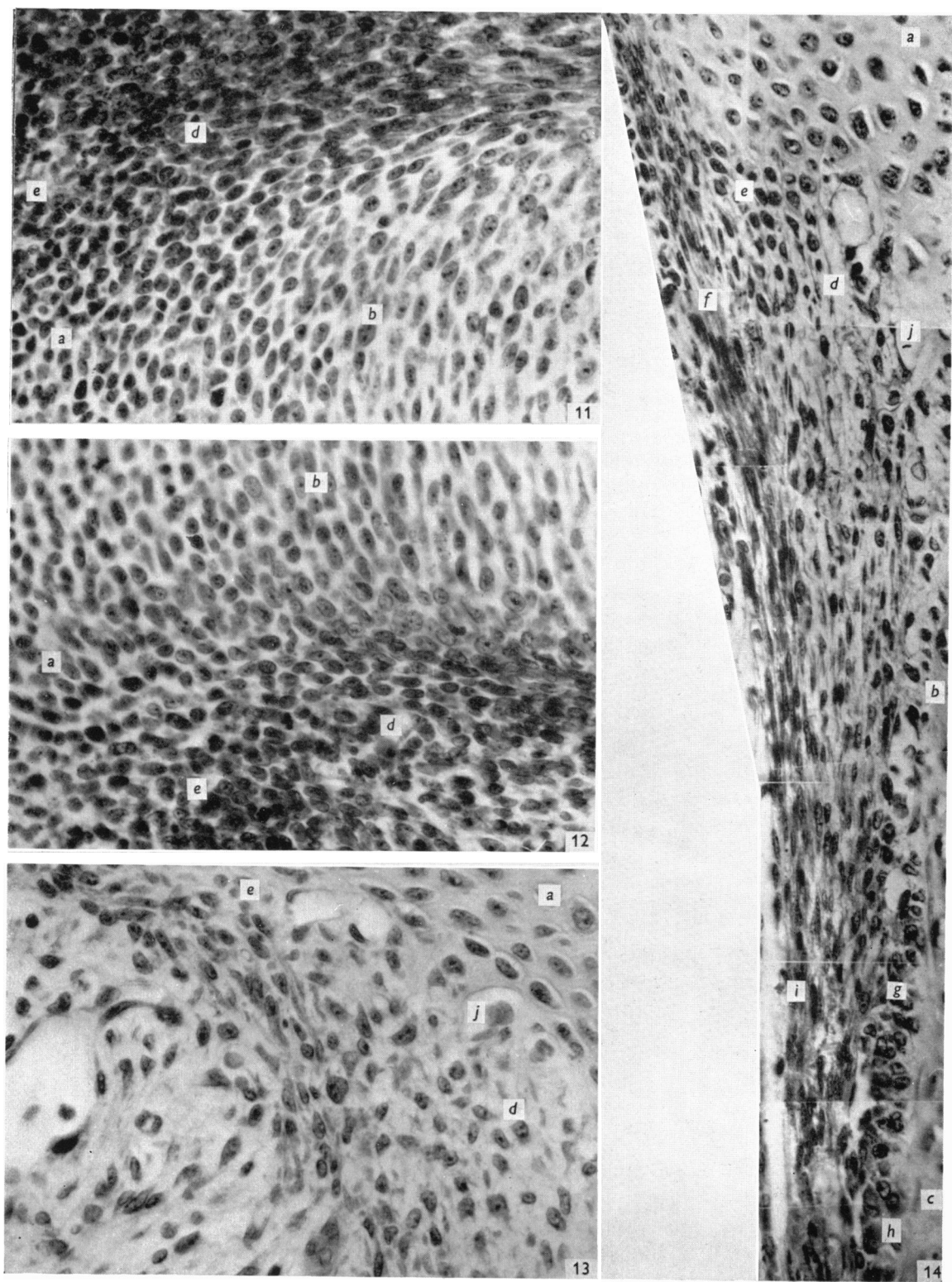
- Figs. 11–14 distal end of femur. (*a*) epiphysial cartilage; (*b*) proliferative zone (diaphysial cartilage); (*c*) hypertrophic zone (diaphysial cartilage); (*d*) perichondrial connective tissue cells; (*e*) prechondroblasts; (*f*) perichondrial fibroblasts; (*g*) preosteoblasts; (*h*) osteoblasts; (*i*) periosteal fibroblasts; (*j*) capillary.  
 Fig. 11. Anterior part of the perichondrial zone (16 days). Note the absence of a distinct floor to the zone in this figure and in fig. 12. ( $\times 375$ .)  
 Fig. 12. Posterior part of the perichondrial zone (16 days). ( $\times 375$ .)  
 Fig. 13. Posterior part of the perichondrial zone adjacent to epiphysial cartilage (20 days). Note the more loose appearance of the subperichondrial tissue as compared with fig. 12. ( $\times 500$ .)  
 Fig. 14. Anterior part of the perichondrial zone (20 days). Note the laminated appearance of the subperichondrial tissue as compared with the irregular arrangement of cells seen in fig. 13. ( $\times 500$ .)





PRATT—'PERICHONDRIAL ZONE' IN A DEVELOPING LONG BONE OF THE RAT





PRATT—'PERICHONDRIAL ZONE' IN A DEVELOPING LONG BONE OF THE RAT